

*Brit. J. Ophthalmol.* (1963) **47**, 331.

## BLINDNESS IN MONGOLISM (DOWN'S SYNDROME)\*†

BY

J. F. CULLEN‡

*The Wilmer Institute, Johns Hopkins University and Hospital, Baltimore, Maryland*

In a previous communication (Cullen and Butler, 1963), the ocular abnormalities encountered in a survey of 143 mongoloids at the Rosewood State Hospital in Maryland were enumerated, and particular attention was drawn to the occurrence of keratoconus in over 5 per cent. of these patients. The purpose of this paper is to elaborate the incidence and causes of blindness in this same group. In the earlier paper no mention was made of the fact that several blind mongoloids were discovered among those examined, and, as the cause of blindness was in all but one instance associated with cataract or keratoconus, they were classified under these aetiological headings.

Earlier surveys of the ocular abnormalities in mongoloids by Ormond (1912), Lowe (1949), Skeller and Öster (1951), and Woillez and Dansaut (1960) do not list any patient as being blind. More recently Eissler and Longenecker (1962) reviewed the ocular findings in 396 mongoloids and, though they made no attempt to compile uncommon ocular conditions, they did not state whether any of this very large number of patients were blind. When one considers that serious ocular conditions occur so commonly in mongoloids, and that the eyes of such patients might be expected to respond unfavourably to trauma or to surgical insult, it is surprising that no reference has hitherto been made to the not unexpected occurrence of blindness, particularly if they survive for more than 30 years.

The diagnosis of blindness was, in our experience, often difficult to establish with certainty, owing to the low mental state of these patients. The presence or absence of light perception was usually not possible to assess by questioning and, in many cases, the pupil reactions could not be relied upon either. In this survey blindness was only accepted when it was quite obvious, as in the case of the phthisical eyes which form the largest group in the series. Indeed, many more of the patients examined would be classified as blind for registration purposes, and others would be graded as partially sighted.

Of the 143 patients examined, seven were blind in both eyes and three others had one blind eye, giving a total of seventeen blind eyes in ten patients. The ages ranged from 14 to 54 years and seven patients were over thirty years old. It must be remembered that mongoloids now often survive beyond their thirties, and that they are then physically older than their years, so that, in

\* Received for publication January 30, 1963.

† This work was supported in part by USPHS Grant No. B2410 (C3), National Institutes of Health, Bethesda, Maryland.

‡ Present address: Department of Ophthalmology, University of Edinburgh.

many cases, progressive mental and physical deterioration has already set in. Many develop the signs of Alzheimer's disease as they grow older, becoming demented and bedridden, and eventually die from some intercurrent infection. It is not surprising, therefore, that degenerative changes should also occur in their already diseased eyes, and it is such changes that result in blindness.

The causes of blindness in the seventeen eyes examined are set out in the Table. It should be noted that eleven eyes were phthisical and five others were blind as a result of acute keratoconus; the changes in these five eyes have already been described (Cullen and Butler, 1963). The remaining eye, which showed uveitis and retinal detachment at the time of examination, may also become phthisical at some later date.

TABLE  
CAUSES OF BLINDNESS IN SEVENTEEN MONGOLOID EYES

Cause	No. of Eyes
Phthisis bulbi resulting from complications of cataract	7
Phthisis bulbi following operation for cataract	4
Acute keratoconus	5
Uveitis and retinal detachment	1

### Discussion

In the case of the phthisical eyes we were able to trace from the case histories that all had at an earlier date shown cataracts of varying degrees of development, and some had been stated to have complete cataracts at the time of examination. No other ocular disease was noted. An interval of up to 20 years had elapsed in some instances since the cataracts were first noted and no active treatment had been advised for a variety of reasons, usually because of the very poor mental status of the patients. When next seen these same eyes were phthisical, and we can only presume that the cataracts had become hypermature, leakage of lens matter had occurred, and a uveitis had been set up, resulting in destruction of the eye and eventual phthisis. Another possibility is that a hypermature cataract may have dislocated into the vitreous and again caused an inflammatory reaction proceeding to phthisis.

It is also noteworthy that four other eyes became phthisical after operation for cataract, and, in fact, we only saw one mongoloid patient at Rosewood who had had a successful cataract operation. This would suggest that operative treatment is not to be lightly undertaken in these patients whose eyes are deformed in many ways and are therefore prone to react unfavourably to operative interference. A typical case history is given below and an example of a phthisical eye as seen in these mongoloids is shown in the Figure (opposite).

### Case Report

A 54-year-old female mongoloid, who was blind, bedridden, and demented, had bilateral phthisis bulbi and was stated to have been blind for some years. Previous ocular examination in 1927 showed essentially normal eyes with only a few lens opacities. In 1940 she was again examined and found to have cataracts in both eyes. No active treatment was advised at that time, and 21 years elapsed before she was seen again and, by this time, bilateral phthisis had occurred. The patient died from an intercurrent infection later in 1961, but permission for autopsy was refused.

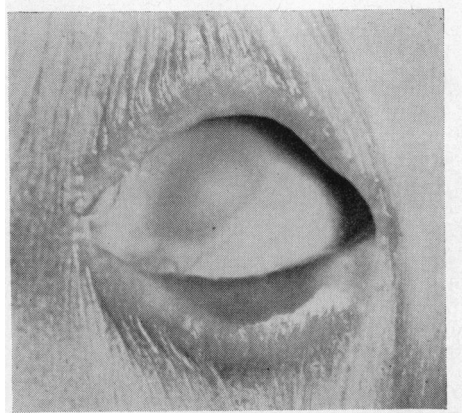


FIGURE.—Phthisical eye in mongoloid patient.

### Summary

Attention is drawn to the occurrence of blindness in almost 5 per cent. of 143 mongoloid patients. In the majority of cases blindness resulted from complications associated with cataracts or their attempted removal. Another relatively common cause of blindness in mongoloids is acute keratoconus which occurs as an acute episode in the course of the simple form of the disease. Both these conditions tend to occur in the older patients, especially in those over 30 years of age, by which time deterioration both physical and mental has set in and degenerative changes have occurred in their already diseased eyes.

I am indebted to Dr. H. G. Butler, Chief of Medical Services, Rosewood State Hospital, for making it possible for me to carry out this survey, and to the nursing staff at Rosewood for their help in examining the patients. I am also indebted to Dr. F. B. Walsh for his encouragement and advice.

### NOTE

Since this paper was submitted for publication a further 63 mongoloids have been examined at Gogarburn Hospital, Edinburgh. Three of these patients (4.7 per cent.) were blind. One had keratoconus, and the others had each had an unsuccessful cataract operation performed on one eye, while the second eye had also become blind as a result of complications associated with a previously noted cataract. In addition, two of the six blind eyes were phthisical.

### REFERENCES

- CULLEN, J. F. and BUTLER, H. G. (1963). *Brit. J. Ophthalm.*, **47**, 321.  
 EISSLER, R., and LONGENECKER, L. P. (1962). *Amer. J. Ophthalm.*, **54**, 398.  
 LOWE, R. F. (1949). *Brit. J. Ophthalm.*, **33**, 131.  
 ORMOND, A. W. (1912). *Trans. ophthalm. Soc. U.K.*, **32**, 69.  
 SKELLER, E., and ÖSTER, J. (1951). *Acta ophthalm. (Kbh.)*, **29**, 149.  
 WOILLEZ, M., and DANSAUT, C. (1960). *Arch. Ophtal. (Paris)*, **20**, 810.



## BLINDNESS IN MONGOLISM (DOWN'S SYNDROME)

J. F. Cullen

*Br J Ophthalmol* 1963 47: 331-333

doi: 10.1136/bjo.47.6.331

---

Updated information and services can be found at:

<http://bjo.bmj.com/content/47/6/331.citation>

---

*These include:*

### References

Article cited in:

[http://bjo.bmj.com/content/47/6/331.citation#related-ur  
ls](http://bjo.bmj.com/content/47/6/331.citation#related-urls)

### Email alerting service

Receive free email alerts when new articles cite this article. Sign up in the box at the top right corner of the online article.

---

### Notes

---

To request permissions go to:

<http://group.bmj.com/group/rights-licensing/permissions>

To order reprints go to:

<http://journals.bmj.com/cgi/reprintform>

To subscribe to BMJ go to:

<http://group.bmj.com/subscribe/>