

Transient ocular hypertension following trabeculectomy

M. PRIALNIC AND H. SAVIR

From the Department of Ophthalmology, Hasharon Hospital, Petah-Tiqva, Israel

SUMMARY A study of the postoperative evolution of 70 eyes subjected to trabeculectomy over a 3-year period is reported. This is the operation of choice in our department in cases of chronic open-angle glaucoma and chronic angle-closure glaucoma. The study showed that in 35.7% of the operated eyes the intraocular pressure was increased on the second postoperative day and became normal within a week. This raised intraocular pressure did not influence the final result of the operation.

Cairns (1968) was the first to introduce the trabeculectomy operation as a most successful form of surgery for primary open-angle glaucoma. The trabeculectomy operation causes a highly significant reduction of the intraocular pressure (IOP) and a parallel rise in aqueous outflow facility (Watson and Barnett, 1975).

Trabeculectomy is increasingly becoming the operation of choice in cases of primary open-angle glaucoma and chronic angle-closure glaucoma. For acute angle-closure glaucoma the usual procedure is still peripheral iridectomy, though it sometimes necessitates further treatment (Wilson, 1977).

Another group of eyes subjected to trabeculectomy are those treated by combined trabeculectomy and cataract extraction (Hilsdorf, 1974; Bregeat, 1975; Witmer and Rohen, 1976). Immediately after the operation, in 25 out of 70 eyes operated on by us the increase of the IOP was transient and had not affected the final result of the operation.

Materials and methods

The operation technique used is as described by Watson (1970), and re-described in a study by Thyer and Wilson (1972) with some minor modifications. The basic points of the operation are: (1) Creation of a conjunctival and Tenon flap placed 7 to 8 mm behind the limbus to keep it so far as possible from the scleral section. (2) Minimal cautery of sclera. (3) Creation of a lamellar scleral flap of 5/5 mm limbus based, one-third to one-half of the scleral thickness. (4) Excision of a 2/2 mm

block of inner sclera from the corneoscleral limbus. (5) Peripheral iridectomy. (6) Closure of the scleral flap with 5 8-0 silk sutures. (7) Stitching of the conjunctiva with 6-0 continuous suture. (8) Dressing with chloramphenicol 5% ointment. (9) Medication from the first postoperative day with homatropine 1% and dexamethasone soluble 0.1% with neomycin 0.5% drops for 6 weeks. All the operations were performed under the surgical microscope.

Results

From May 1974 through May 1977, 70 eyes of 56 patients were subjected to trabeculectomy; 28 were affected by chronic open-angle glaucoma, 39 by chronic angle-closure glaucoma (including acute exacerbation of angle-closure glaucoma), and 3 by secondary glaucoma (2 due to uveitis and 1 due to central vein thrombosis). Five eyes out of 70 were subjected to combined trabeculectomy and cataract extraction.

The follow-up period was 1 to 3 years. Table 1 shows the variations of the IOP during the postoperative period. Out of 70 eyes at the last follow-up 51 (73%) had a normal IOP without medication, while 17 (24.3%) had a normal IOP with medication and 2 had an uncontrolled IOP.

Fig. 1 shows the IOP of 25 eyes on the day of the operation. Their IOP was raised on the second postoperative day. This number represents 35.7% of the operated eyes. Out of 25 eyes with raised IOP on the second postoperative day 11 belonged to the chronic open-angle group and 13 to the chronic angle-closure group. One eye was from the combined trabeculectomy and cataract extraction group.

Table 2 shows the complications we have recorded

Address for reprints: Dr H. Savir, Department of Ophthalmology, Hasharon Hospital, Petah-Tiqva, Israel

in the 70 cases. They were hyphaema, iridocyclitis, development of slight lens opacities, flat anterior chamber, and iris bombé.

Discussion

We agree with Wilson's (1977) opinion that trabeculectomy is a successful operation in patients with chronic open-angle glaucoma and chronic angle-closure glaucoma. Its efficiency in cases of secondary

glaucoma is only partial, and our only case of thrombotic glaucoma was a failure.

Trabeculectomy is free of major operative and postoperative complications (Watson and Barnett, 1975). Many clinicians report in their studies that in comparison with the other filtering procedures trabeculectomy has only a few minor complications (Schwartz *et al.*, 1976). They were rare in our cases.

The most interesting result of this study is the rise of the IOP on the second postoperative day.

Table 1 Range of IOP during the post-trabeculectomy period, in mmHg

	Immediately after operation	One month after operation	Last recordings in patients	
			Without medication No. of eyes	With medication No. of eyes
Chronic open-angle glaucoma (28 eyes)	0-40	0-32	21	7
Chronic angle-closure glaucoma (39 eyes)	0-50	0-21	29	10
Secondary glaucoma (3 eyes)	8-25	8-34	1	2

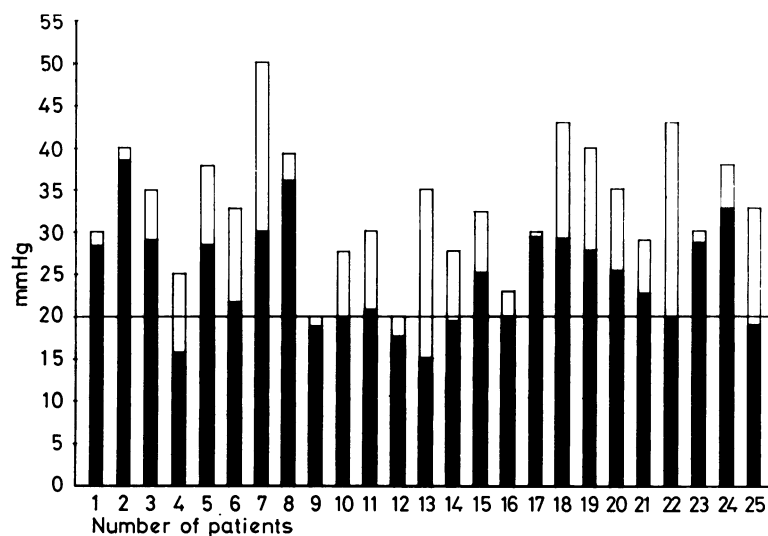


Fig. 1 Intraocular pressures before and after trabeculectomy in 25 patients. Black = IOP on day of operation. White = IOP 2 days after trabeculectomy

Table 2 The postoperative complications recorded in the 70 cases

Type of glaucoma	Type of complications			
	Hyphaema	Iridocyclitis	Slight lens opacities	Flat anterior chamber and iris bombé
Chronic open-angle glaucoma	3	0	5	0
Chronic angle-closure glaucoma	3	2	3	2
Secondary glaucoma	0	0	1	2

This raised IOP lasted from 2 to 7 days and did not affect in any way the final result of the operation, in contrast with Portney's study (Portney, 1977). We presume that the increase of the IOP was caused by our technique of tightly closing the scleral flap by 5 sutures (Fechner, 1975). These sutures do not prevent the formation of a fine filter a few days after the operation, which reduces the IOP to normal. On the other hand the sutures prevent the formation of a flat anterior chamber, which was present in 4 cases only and disappeared after 2 days. The rise of the IOP did not cause an iris reaction stronger than in patients without IOP elevation.

Our follow-up is not as long as the follow-up of Wilson (1977), but he showed too that the number of uncontrolled cases does not increase significantly after 1 year of follow-up (40 to 44 eyes).

References

- Bregeat, P. (1975). Cataract surgery and trabeculectomy at the same time. *Klinische Monatsblätter für Augenheilkunde*, **167**, 505–515.
- Cairns, J. E. (1968). Trabeculectomy: preliminary report of a new method. *American Journal of Ophthalmology*, **66**, 673–679.
- Fechner, P. U. (1975). Trabeculectomy, a fistulizing operation with refixation of the scleral flap. *Klinische Monatsblätter für Augenheilkunde*, **167**, 795–805.
- Hilsdorf, C. (1974). Trabeculectomy and lens extraction, a combined glaucoma and cataract operation. *Klinische Monatsblätter für Augenheilkunde*, **164**, 293–303.
- Portney, G. L. (1977). Trabeculectomy and postoperative ocular hypertension in secondary angle-closure glaucoma. *American Journal of Ophthalmology*, **84**, 145–149.
- Schwartz, P. L., Ackerman, J., Beards, J., Wesseley, Z., Goodstein, S., and Ballen, P. H. (1976). Further experience with trabeculectomy. *Annals of Ophthalmology*, **8**, 207–217.
- Thyer, H. W., and Wilson, P. (1972). Trabeculectomy. *British Journal of Ophthalmology*, **56**, 37–40.
- Watson, P. G. (1970). Trabeculectomy. A modified ab externo technique. *Annals of Ophthalmology*, **2**, 199–205.
- Watson, P. G., and Barnett, F. (1975). Effectiveness of trabeculectomy in glaucoma. *American Journal of Ophthalmology*, **79**, 831–845.
- Wilson, P. (1977). Trabeculectomy: long-term follow-up. *British Journal of Ophthalmology*, **61**, 535–538.
- Witmer, R., and Rohen, J. W. (1976). Combined cataract glaucoma operation. *Transactions of the Ophthalmological Societies of the United Kingdom*, **96**, 256–261.



Transient ocular hypertension following trabeculectomy.

M Prialnic and H Savir

Br J Ophthalmol 1979 63: 233-235

doi: 10.1136/bjo.63.4.233

Updated information and services can be found at:

<http://bjo.bmj.com/content/63/4/233>

References

These include:

Article cited in:

<http://bjo.bmj.com/content/63/4/233#related-urls>

Email alerting service

Receive free email alerts when new articles cite this article. Sign up in the box at the top right corner of the online article.

Notes

To request permissions go to:

<http://group.bmj.com/group/rights-licensing/permissions>

To order reprints go to:

<http://journals.bmj.com/cgi/reprintform>

To subscribe to BMJ go to:

<http://group.bmj.com/subscribe/>