

Allergic conjunctival granulomas

MALCOLM E. CAMERON AND HUGH GREER

From the Brisbane Clinic, 79 Wickham Terrace, Brisbane, Queensland 4000, and the Royal Victorian Eye and Ear Hospital, Melbourne, Australia

SUMMARY Seven cases are reported from Australia of benign granulomas of the conjunctiva occurring principally in children. Conjunctival granulomas of this kind have not previously been recorded in Australia. Both clinically and histologically they are identical to those described by Ashton and Cook¹ as allergic granulomas of the conjunctiva exhibiting the Splendore-Hoepli phenomenon.

Seven cases of a rare type of conjunctival granuloma have come to our notice in Australia over a period of 15 years.

Patients and methods

The patients ranged in age from 4 to 26 years, and 5 of them were under 11 years; there were 2 females and 5 males. They suffered mild conjunctival hyperaemia and irritation and slight discharge from one or both eyes for a week or two before presenting. The granulomatous lesions consisted of 1 or more raised yellow nodules immediately beneath the epithelium of the bulbar conjunctiva (Fig. 1). In the absence of surgical intervention the lesions disappeared spontaneously within a few weeks or months of onset. In 1 of the 7 cases similar

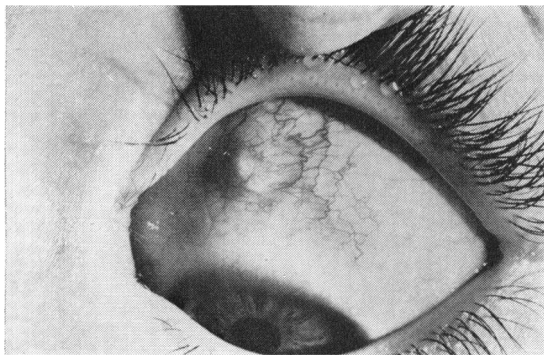


Fig. 1 Typical appearance of granulomas in the bulbar conjunctiva.

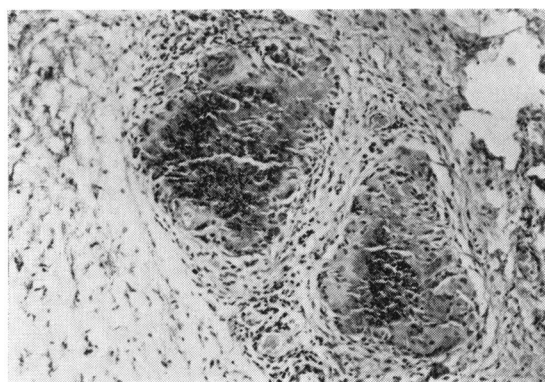


Fig. 2 Photomicrograph of the characteristic granulomatous foci showing nuclear debris and amorphous substance surrounded by epithelioid cells and giant cells (H and E, $\times 200$).

lesions appeared in the contralateral eye 12 months later. The patients were otherwise quite well, and their chest x-rays, blood counts, and erythrocyte sedimentation rates were normal. In the only case so tested the Mantoux reaction was negative.

PATHOLOGY

Sections of the nodules in all the cases showed 1 or more granulomatous inflammatory foci consisting of amorphous eosinophilic material and nuclear debris, closely surrounded by epithelioid cells, giant cells, and eosinophils (Fig. 2). In some instances the epithelioid cells had assumed an elongated form and arranged themselves in a palisade. No foreign bodies, parasites, or organisms of any kind were identified in any of the lesions, and cultures consistently proved negative.

Correspondence to Brisbane Clinic, 79 Wickham Terrace, Brisbane, Queensland 4000, Australia.

Discussion

The granulomas are similar in every way to those described by Ashton and Cook¹ as allergic granulomatous nodules of the conjunctiva showing the Splendore-Hoepli phenomenon. These authors record that the eponym derives from Splendore's first description in 1908 of eosinophilic granulomas around fungal spores and Hoepli's subsequent report of identical reactions around schistosoma eggs. In the 20 conjunctival granulomas painstakingly investigated by Ashton and Cook no ova or spores were found, but 2 granulomas contained

fragments of nematode cuticle. Transmission electron microscopy performed on some of the 20 granulomas revealed abundant amorphous substance thought to be antigen-antibody complex.

We are grateful to Drs Justin Murphy, J. Cairns, P. J. Lewis, J. Roache, C. G. Cullity, and Mark Harrison, who referred cases, and to the Medical Illustration Department of the Royal Victorian Eye and Ear Hospital for help in preparing the photographs.

Reference

¹Ashton N, Cook C. Allergic granulomatous nodules of the eyelid and conjunctiva. *Am J Ophthalmol* 1979; **87**: 1-28.



Allergic conjunctival granulomas.

M E Cameron and H Greer

Br J Ophthalmol 1980 64: 494-495

doi: 10.1136/bjo.64.7.494

Updated information and services can be found at:

<http://bjo.bmj.com/content/64/7/494>

	<i>These include:</i>
References	Article cited in: http://bjo.bmj.com/content/64/7/494#related-urls
Email alerting service	Receive free email alerts when new articles cite this article. Sign up in the box at the top right corner of the online article.

Notes

To request permissions go to:

<http://group.bmj.com/group/rights-licensing/permissions>

To order reprints go to:

<http://journals.bmj.com/cgi/reprintform>

To subscribe to BMJ go to:

<http://group.bmj.com/subscribe/>