

British Journal of Ophthalmology, 1985, **69**, 96–98

Giant retinal tears after central vitrectomy

DAVID McLEOD

From the Surgical Vitreoretinal Unit, Moorfields Eye Hospital

SUMMARY Giant retinal breaks developed in four eyes within two months of pars plana vitrectomy. The pathogenesis and implications of this serious complication are discussed.

Closed vitreous microsurgery may be a hazardous procedure, particularly when it is employed in the management of complicated vitreoretinal pathology. The purpose of this report is to highlight the danger of giant retinal tear formation associated with detachment of residual vitreous cortex in eyes that have previously undergone a 'central' vitrectomy via the pars plana.

Case reports

CASE 1

A 27-year-old patient was referred for anterior segment revision in 1978 nine years after a perforating injury that involved the cornea and lens of his amblyopic left eye. Using the Peyman Vitrophage we removed cortico-capsular remnants via a single incision in the superotemporal pars plana. A 'central' vitrectomy was also done, but, since the vitreous was not detached, the postbasal cortical gel remained in situ. No untoward retinal changes, whether pre-existing or surgically induced, were identified by indirect ophthalmoscopy. Vision improved to 6/60 with an aphakic correction.

Seven weeks postoperatively flashes and floaters in the left eye were followed by profound visual loss, and examination showed complete separation of the mobile cortical gel remnant up to the posterior border of the vitreous base together with a 180° superior giant retinal tear (9.30 o'clock clockwise to 3.30 o'clock). The residual gel was attached to the anterior margin of the tear, which comprised 1.5 mm of peripheral retina and posterior non-pigmented pars plana epithelium. The posterior flap of the tear was inverted over the disc and macula. The patient declined further surgery.

Correspondence to Mr D McLeod, FRCS, Moorfields Eye Hospital, City Road, London EC1V 2PD.

CASE 2

A 24-year-old Malaysian was referred in 1981 for management of a retinal detachment in his myopic right eye (−8.50 D). He was totally blind in his left eye, which had undergone unsuccessful surgery for a retinal detachment two years previously. B-scan ultrasound on the left eye showed a dense cataract and a funnel shaped retinal detachment (triangle sign) but no features that suggested a giant retinal tear. Vision in the right eye was reduced to 6/36 by an inferotemporal retinal detachment just involving the macula. This was identified as being secondary to an unusual posterior retinoschisis, with multiple tiny inner leaf breaks overlying a large outer leaf break raised from the pigment epithelium immediately inferotemporal to the macula. The right eye underwent a central vitrectomy via three pars plana incisions, for which we used the Klotz 20 gauge vitreous stripper. Since it proved impossible at surgery to remove the vitreous cortex from the region of the inner leaf breaks, only partial internal drainage of schitic and subretinal fluid was achieved through the posterior breaks, but it was possible to apply xenon endophotocoagulation burns around the breaks. A fluid/20% SF₆ gas exchange was done together with limited cryotherapy posterior to the pars plana entry sites. Despite appropriate post-operative posturing the breaks reopened once the gas bubble had absorbed. Ten days after the initial surgery, therefore, a further internal drainage was done (again limited by persistent gel attachment around the inner leaf breaks), together with a fluid/silicone oil exchange when three further pars plana incisions were made. Over the next three weeks the retina slowly reattached, and laser photocoagulation was applied through the silicone oil around the outer leaf break to reinforce the previous xenon treatment (acuity 6/18 unaided). The silicone oil was removed three months later by re-exchange for infusion fluid

via two further pars plana incisions. Postoperatively vision was 6/24 with a myopic correction, and the retina was secure.

Two months after the oil removal floaters appeared in the right vision followed the next day by profound visual loss (acuity, hand motion). Examination showed a superotemporal retinal detachment including the macula (but limited in extent by the posterior photocoagulation) secondary to a 100° giant retinal break at the ora serrata (9.30 o'clock clockwise to 1.00 o'clock). The posterior flap of the tear was partially inverted, it being held in one area by a postoral cryo scar. Residual mobile vitreous cortex was completely detached from the retina (including that posterior portion that had previously blocked the inner leaf holes in the schisis) and was suspended from the anterior oral margin of the giant tear. A further closed microsurgical procedure was therefore done via three more pars plana sclerotomies (numbers 9, 10, and 11). The detached vitreous cortex was removed, and the posterior flap of retina was manipulated into place during a second fluid/silicone oil exchange. Cryopexy was applied to the repositioned edge of the posterior flap and through 360°. The retina remained attached (acuity 6/24 unaided), but the eye developed a raised intraocular pressure associated with silicone emulsion in the chamber angle. Further laser applications were applied to the posterior edge of the giant break, and five weeks after the second silicone exchange the silicone oil was removed and a trabeculectomy was done. Eighteen months later right vision was 6/24 with a myopic correction. The intraocular pressure was within normal limits. There was mild cataract, and the retina was entirely attached.

CASE 3

A 23-year-old student with Marfan's syndrome was referred for vitreolensectomy in 1984. He had bilateral superonasal lens subluxations. The inferotemporal equators of the clear lenses crossed the visual axes and interfered with near vision (acuity 6/18, N6 RE; 6/36, N18 LE). A left vitreolensectomy was done. We used the Ocutome and three pars plana incisions (superonasal, superotemporal, and inferotemporal); the cortical gel was left in situ attached to the postbasal retina. Prophylactic monitored 360° confluent cryotherapy was applied immediately posterior to the retroplaced ora serrata. No oral or peripheral retinal abnormality was detected at surgery or initially thereafter. Vision improved to 6/4; N5 with the help of a contact lens.

Two months after surgery floaters became apparent in the left eye, though acuity was unaffected. Examination showed a completely detached mobile vitreous cortex and a 190° giant retinal tear at the ora

serrata (12 o'clock clockwise to 6.30 o'clock) with a raised anterior flap comprising non-pigmented pars plana epithelium from which the gel remnant was suspended. The retina posterior to the tear was entirely attached and secured by the previous cryo scars. No treatment was thought to be necessary, and central vision was maintained at 6/4 six months after giant tear formation with no evidence of epimacular proliferation.

Because of the excellent acuity obtained in his left eye, the patient requested similar surgery for his right eye. Prophylactic 360° postoral cryopexy was performed six weeks prior to right vitreolensectomy via the pars plana. The vitreous cortex was noted to be attached at operation, and since it could not be readily separated from the retina the vitreous 'rim' was left in situ. One month later the patient noticed floaters in his right eye, and examination revealed pigment-cell invasion of the detached vitreous cortex and a virtually 360° giant retinal tear at the ora serrata. As in the left eye, the retina remained attached and vision was maintained at 6/4.

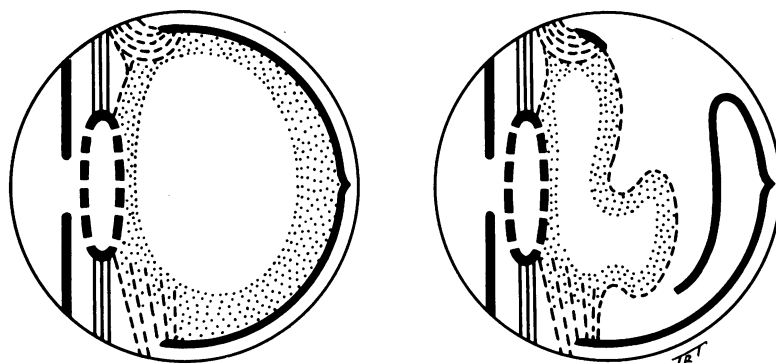
Discussion

The mechanism of formation of giant retinal tears (GRTs) is controversial. While the role of posterior vitreous detachment (PVD) has been questioned in the past,¹ experience during vitrectomy suggests that PVD (and consequent dynamic vitreoretinal traction²) is the predominant pathogenic mechanism except after blunt trauma³ (often associated with extensive vitreous base avulsion—'bucket-handle tears'). GRTs also complicate PVD after posterior penetrating trauma with vitreous incarceration. These two elements—basal gel incarceration (an inevitable complication of pars plana entry wounds) and dynamic vitreoretinal traction (after detachment of retained vitreous cortex posterior to the vitreous base)—appear to have combined to produce the GRTs in these three cases (Fig. 1).

GRTs can occur at the time of vitrectomy⁴ either in the region of an 'active' pars plana entry site (especially during multiple instrument insertions and removals), or elsewhere (especially when inefficient rotary suction cutters are used that cause vitreous 'winding', including anterior vitrectomy procedures via the limbus). This immediate or peroperative mechanism of GRT formation was excluded in all three patients by the routine practice of examination of the oral retina posterior to pars plana entry sites towards the end of the vitrectomy procedures and at early postoperative examinations.

Detachment of retained vitreous cortex in the months or years after surgery is a familiar sequel to central vitrectomy, and is occasionally complicated

Fig. 1 Left: Lacuna after central vitrectomy via the pars plana with basal gel incarceration. Right: Giant retinal tear formation after detachment of residual vitreous cortex.



by formation of juxtabasal or postbasal flap tears or operculated tears owing to dynamic vitreoretinal traction. The GRTs in these three cases may represent an extreme variant of this process possibly related to undue vitreous incarceration in entry sites. In all three cases the site of the giant tear included a vitrectomy wound. Alternatively pre-existing or surgically induced retinal weakness at the posterior border of the vitreous base may be implicated. Whether GRTs occur after vitreous cortex detachment without vitreous base incarceration (for example, after limbal vitreolensectomy) is uncertain. Several such cases have been managed at our unit after referral, but it was not clear whether the GRTs developed at the time of vitreolensectomy or subsequently.

Other types of delayed retinal tearing secondary to basal gel incarceration in pars plana entry sites have been described.⁴ Such juxtabasal tears may even follow posterior or 'complete' vitrectomy made possible by the occurrence of PVD prior to surgery (as is usually the case in vitrectomy for posterior segment pathology). However, giant breaks are not seen in these circumstances.

Vitreolensectomy is becoming an increasingly popular method of treating congenital cataracts because of the optical advantages over simple lens aspiration via the limbus.^{5,6} Girard uses this method for most types of cataract.⁷ However, the degree of prophylactic cryocoagulation of the peripheral retina appropriate after such procedures has seldom attracted much attention. The development of GRTs

in these three reported cases has obvious implications for perhaps all eyes undergoing 'incomplete' vitrectomy (for example, anterior vitrectomy or central vitrectomy), especially via the pars plana. Carefully monitored cryotherapy is recommended across the demonstrable or presumed location of the posterior border of the vitreous base for 30° on each side of all pars plana entry sites, extended to 360° in selected cases.^{8,9}

My thanks are owed to Miss Heather Lucas for typing the manuscript and to Mr Terry Tarrant for the illustrations.

References

- 1 Tolentino FI, Schepens CL, Freeman HM. *Vitreoretinal disorders*. Philadelphia; Saunders, 1976: 391.
- 2 Scott JD. Static and dynamic vitreous traction. *Trans Ophthalmol Soc UK* 1971; **91**: 175-87.
- 3 Cox MS, Schepens CL, Freeman HM. Retinal detachment due to ocular contusion. *Arch Ophthalmol* 1966; **76**: 678-85.
- 4 Michels RG. *Vitreous surgery*. St Louis: Mosby, 1981: 272, 399, 400.
- 5 Peyman GA, Raichand M, Goldberg MF. Surgery of congenital and juvenile cataract: a pars plicata approach with the vitreophage. *Br J Ophthalmol* 1978; **62**: 780-3.
- 6 Taylor D. Choice of surgical technique in the management of congenital cataract. *Trans Ophthalmol Soc UK* 1981; **101**: 114-7.
- 7 Girard LJ. Pars plana lensectomy by ultrasonic fragmentation. I: A versatile and simple technique for cataract removal. *Surv Ophthalmol* 1982; **27**: 96-104.
- 8 McLeod D. A retinal surgeon's view of congenital cataract surgery. *Aust J Ophthalmol* in press.
- 9 Jagger JD, Cooling RJ, Fison LG, Leaver PK, McLeod D. Management of retinal detachment following congenital cataract surgery. *Trans Ophthalmol Soc UK* 1983; **103**: 103-7.



Giant retinal tears after central vitrectomy.

D McLeod

Br J Ophthalmol 1985 69: 96-98

doi: 10.1136/bjo.69.2.96

Updated information and services can be found at:

<http://bjo.bmj.com/content/69/2/96>

References

These include:

Article cited in:

<http://bjo.bmj.com/content/69/2/96#related-urls>

Email alerting service

Receive free email alerts when new articles cite this article. Sign up in the box at the top right corner of the online article.

Notes

To request permissions go to:

<http://group.bmj.com/group/rights-licensing/permissions>

To order reprints go to:

<http://journals.bmj.com/cgi/reprintform>

To subscribe to BMJ go to:

<http://group.bmj.com/subscribe/>