

Control of postoperative astigmatism

A D ATKINS AND M J ROPER-HALL

From the Birmingham and Midland Eye Hospital

SUMMARY Thirty-six eyes with excessive astigmatism following cataract extraction via a corneal section were subjected to suture adjustment. This was performed six to eight weeks postoperatively under topical anaesthesia. The cases were selected from a large volume of corneal section cases because they had over 3.0 dioptres astigmatism. We reduced astigmatism significantly in the majority. There were no serious complications.

Postoperative astigmatism has demanded the attention of surgeons for decades.¹⁻⁴ The subject has been recently reviewed.⁵ Some surgeons have avoided corneal sections because of unacceptable and unpredictable postoperative astigmatism.⁶ However, apart from this aspect the corneal section has considerable advantages. There is negligible bleeding and haemostasis is not necessary. Visibility is excellent during surgery, particularly during insertion of implants. As the wound is 180°, lifting the corneal flap does not cause the lower cornea to bend inwards during the insertion of an implant. The wound can be made (and proved to be) watertight at the end of surgery. Peripheral anterior synechiae to the wound, which might lead to glaucoma and contact between implants and corneal endothelium, are prevented. Contact lenses can be fitted early and are more comfortable owing to the lack of conjunctival oedema. Cataract extractions in patients with functioning filtration blebs are best performed via the corneal route, and some would argue that all chronic simple glaucoma patients should have their cataracts removed through a corneal section.⁷ (Cairns J E, personal communication).

The major objections to the corneal section are slower healing and increased astigmatism. Inert sutures can be left to support the tissues until firm healing has been established. This article shows that postoperative astigmatism can be controlled in corneal section cases.

Patients and methods

Thirty-six patients underwent cataract surgery by a two-step incision with one preplaced 8/0 (0.3 metric)

Correspondence to Mr M J Roper-Hall, FRCS, Birmingham and Midland Eye Hospital, Church Street, Birmingham B3 2NS

silk suture at the 12 o'clock meridian and a post-placed 10/0 (0.2 metric) continuous polyamide suture tied with buried knots at each end (Fig. 1). The technique has been described before.⁸ The interrupted suture is usually removed 10-14 days after surgery at an out-patient visit.

During the 6-8 week period these 36 patients were refracted and found to have astigmatism greater than 3.0 dioptres. They were subjected to adjustment of their continuous suture at the slit-lamp by one of the authors. By this time the corneal epithelium had covered the suture. The epithelium overlying each suture was broken, and the subepithelial portions of the suture were gently grasped with fine plain Pierser forceps and eased loop by loop towards the axis of the positive cylinder (Fig. 1), commencing from each

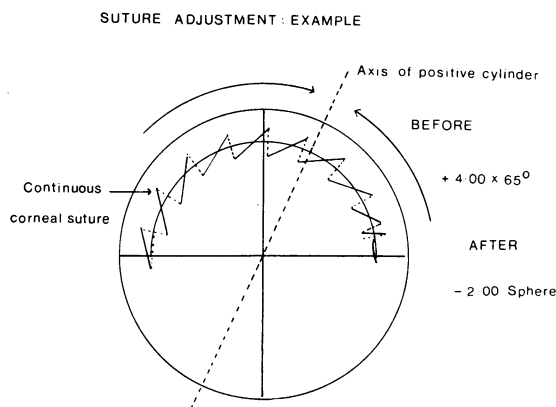


Fig. 1 An example of suture adjustment. This patient had 4.0 dioptres astigmatism at six weeks postoperatively. His continuous suture was eased towards the positive axis of 65° with an immediate result of no astigmatism. This result was maintained until final follow-up of 38 months.

end of the continuous suture. The refraction was then immediately rechecked, and if necessary the suture was adjusted again. This technique is simple to master, but because of the slight risk of breaking the suture we delayed adjustment until the sixth or preferably eighth postoperative week. A one-week course of topical antibiotics is recommended as prophylaxis against infection. The patients were followed up with serial refractions, and when stability was reached spectacles were ordered.

Results

There were 36 patients; 16 males and 20 females. Their ages ranged from 61 to 81 years with an average age of 70.6 years. Follow-up ranged from six to 38 months, average 12 months. Two cases (5 and 6 dioptres at final follow-up) were resutured successfully (see 'Discussion'). The results are best presented with figures considering cylindrical power, axis, and final visual acuity.

CYLINDRICAL POWER

Fig. 2 shows how the power of the cylinders changed before and immediately after suture adjustment. It can be seen from the scattergram that all but one case were the same or had reduced astigmatism. Thirty-three cases (92%) showed a reduction. However, 11 cases (30%) still had more than 3.0 dioptres astigmatism.

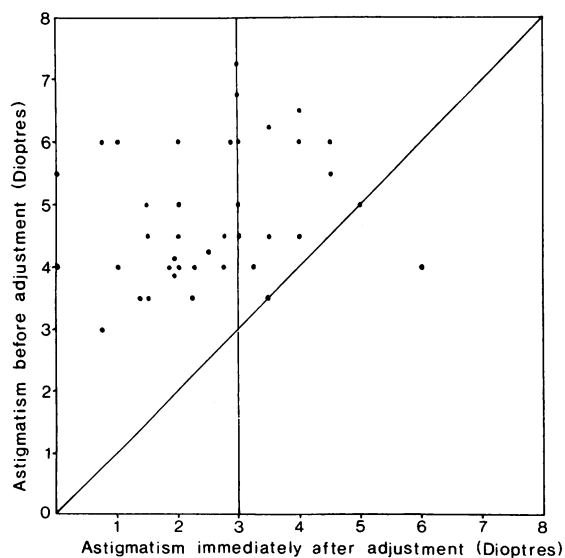


Fig. 2 Scattergram showing the astigmatism before and immediately after suture adjustment. The diagonal represents no change in cylindrical power; above the line represents decrease of power, whereas below the line represents an increase. The vertical line separates cases of less and more than 3 dioptres after adjustment.

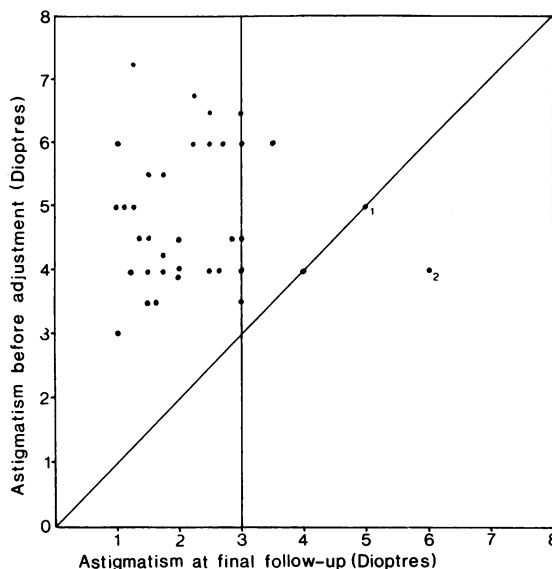


Fig. 3 Scattergram showing the astigmatism before adjustment and at final follow-up. Again results above the diagonal line represent a decrease in cylindrical power, whereas those below it represent an increase. Cases numbered 1 and 2 were resutured with success (see 'Discussion'). Note that all but four cases had 3.0 dioptres or less of astigmatism.

When the final cylindrical power is compared with that before suture adjustment (Fig. 3), it can be seen that 32 cases (89%) had 3.0 dioptres or less of astigmatism. Cases numbered 1 and 2 on the scattergram were resutured (see 'Discussion') with a successful outcome.

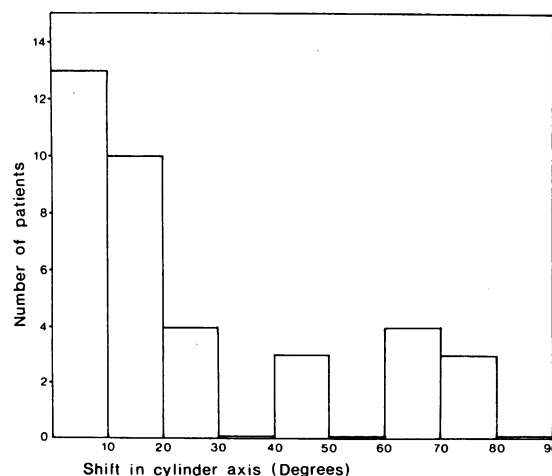


Fig. 4 Histogram showing how the axes of the cylinders shifted before and immediately after suture adjustment. It can be seen that, although the majority of cases had less than 20° shift of axis, a minority had shifts up to 90°.

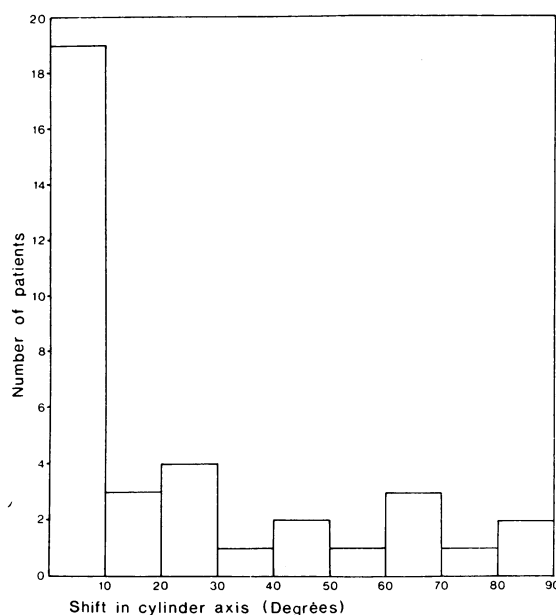


Fig. 5 Histogram showing how the cylinder axis shifted from immediately after suture adjustment until the final follow-up. It can be seen that an even larger majority remained within 20° of that immediately after adjustment, with more falling into the 0 to 10° group.

CYLINDRICAL AXIS

Fig. 4 shows the shift of cylindrical axis before and immediately after suture adjustment. Twenty-three cases (64%) showed 20° or less of axis shift. However, there was a scattering of cases showing shifts up to 90°. For the sake of simplicity we have not shown data correlating the cylindrical power with the cases of nearly 90° axis shift. In Fig. 5 we can see how many cases showed further shift in axis: 19 cases (53%) had 10° or less of shift and 22 cases (61%) less than 20°. There were still some cases shifting up to 90°.

VISUAL ACUITY

All the acuities recorded were with correction. Fig. 6 shows the visual acuities before adjustment and at final follow-up. It is interesting to observe that 21 cases (56%) showed improved visual acuities after adjustment despite the fact that all acuities were with best correction. Ten cases had the same acuity. The acuities of five patients deteriorated during follow-up; this seemed to be unrelated to the adjustment. One had senile macular degeneration, two had cystoid macular oedema (one of these recovered to 6/12 vision at final follow-up), and in two cystoid macular oedema was postulated but not proved by fluorescein angiography (final acuities of 6/6 and 6/9).

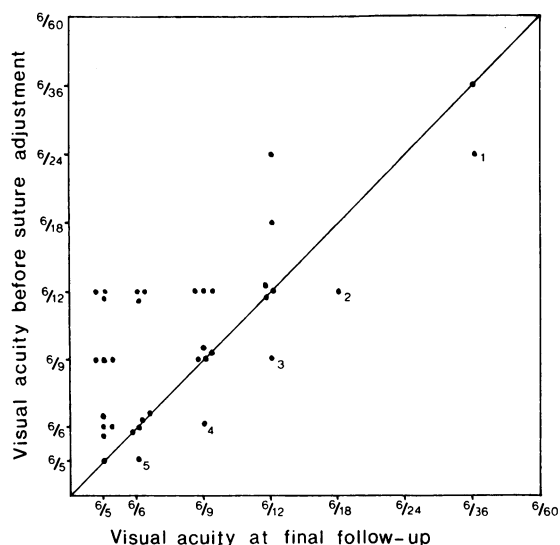


Fig. 6 Scattergram showing the improvement of visual acuities (corrected) from before suture adjustment to final follow-up. Those cases on the diagonal line experienced no change in visual acuity. Those cases above the line showed improvement in vision, whereas those below the diagonal line show a deterioration. These five cases with reduced acuity are numbered. Case 1 had senile macular degeneration, cases 2 and 3 cystoid macular oedema, and cases 4 and 5 presumed cystoid macular oedema.

COMPLICATIONS

Broken suture—2 cases (5.5%). There were two cases of accidental breaking of the continuous 10/0 nylon suture. Both sutures were subsequently removed. The first case was left with 4.0 dioptres astigmatism with 6/5 Snellen acuity. The second stabilised to +1.25 dioptres astigmatism with an acuity of 6/12.

Failed adjustment—2 cases (5.5%). In these cases repeated adjustments failed and the suture was removed. After suture removal the astigmatism remained unacceptable (5.0 and 6.0 dioptres) and did not decrease with time. Both were subjected to surgery consisting of inserting buried tensioning nylon 9/0 sutures around the axis of the negative cylinder, with the intention of leaving them in situ. They achieved final results of +2.50 dioptres with an acuity of 6/6 at 9 months and +3.00 dioptres and a visual acuity of 6/5 at five years after the suturing procedure (see 'Discussion').

There were no other complications—in particular no aqueous leaks or infections were seen following suture adjustment.

Discussion

The advantages and disadvantages of the corneal

cataract incision have been mentioned in the introduction. Astigmatism can be troublesome, though less so with surgical experience. Our results show that a high proportion (89%) of these unfortunate patients had their astigmatism reduced to 3.0 dioptres or less by this simple procedure. One broken suture and two failed adjustments accounted for the remaining three cases with more than 3.0 dioptres astigmatism. Two of these cases (5 and 6 dioptres respectively) were successfully corrected by resuture. This procedure is described by the authors.⁹

The shift in cylindrical axis recorded has been shown in a simple form in the histograms (Figs. 4 and 5). The situation becomes difficult to display when the axis shifts approximately 90°, as the effect of the adjustment is additive, but this was not central to the point of this article. Essentially most cases kept the cylindrical axis they had before adjustment.

The visual acuity fluctuations depicted in (Fig. 6) show essentially that the procedure improves acuity in the majority of cases, and in those cases where the visual acuity fell it was not related to the adjustment.

Readers may be concerned at the risk of breaking the continuous suture during adjustment. We found the procedure straightforward and safe provided that: (1) a fine non-toothed forceps is used, pulling in the long axis of the suture; (2) the patient is relaxed and looking at the fixation lamp of the slit-lamp with his other eye; (3) the patient's eyelids are not inadvertently touched with the forceps, with resulting reflex blepharospasm.

CONCLUSION

A safe, effective, and reliable method of reducing postoperative astigmatism in corneal section cataract patients is described. With this suture adjustment technique available, the advantages of corneal section cataract surgery deserve greater consideration.

Our thanks are due to Dr A J Kempster and Mr A P Tompkin, who performed the majority of the many refractions required, and also to Miss P Quinn, who typed the manuscript.

References

- 1 Bedrossian PB, Sabata G, Troutman RC. Induced astigmatism as a result of surgery. In: Luntz MH, Shapiro HA. *Proceedings of the 1st South African international ophthalmological symposium 1969*. Durban: Butterworth, 1969: 219-25.
- 2 Jaffe N. Corneal astigmatism change related to cataract incision location. In: *Proceedings of the 2nd Biennial cataract surgical congress*. Miami: Educational Press, 1971: 366-9.
- 3 Troutman RC. Corneal astigmatism change related to cataract incision location. In: *Proceedings of the 2nd Biennial cataract surgical congress*. Miami: Educational Press, 1971: 370.
- 4 Troutman RC. Microsurgical control of corneal astigmatism in cataract and keratoplasty. *Trans Am Acad Ophthalmol Otolaryngol* 1973; **77**: 563-72.
- 5 Roper-Hall MJ. Control of astigmatism after surgery and trauma. *Br J Ophthalmol* 1982; **66**: 556-9.
- 6 Jaffe NS. *Cataract surgery and its complications*. St Louis: Mosby, 1976: 83-98.
- 7 Rothkoff L, Biedner B, Blumenthal M. The effect of corneal section on early increased intraocular pressure after cataract extraction. *Am J Ophthalmol* 1978; **85**: 337-8.
- 8 Roper-Hall MJ. Intraocular lens with intracapsular cataract extraction. *Trans Ophthalmol Soc UK* 1981; **101**: 56.
- 9 Roper-Hall MJ, Atkins AD. Control of astigmatism after surgery and trauma: a new technique. *Br J Ophthalmol* 1985; **69**: 352-59.



Control of postoperative astigmatism.

A D Atkins and M J Roper-Hall

Br J Ophthalmol 1985 69: 348-351

doi: 10.1136/bjo.69.5.348

Updated information and services can be found at:

<http://bjo.bmj.com/content/69/5/348>

Email alerting service

These include:

Receive free email alerts when new articles cite this article. Sign up in the box at the top right corner of the online article.

Notes

To request permissions go to:

<http://group.bmj.com/group/rights-licensing/permissions>

To order reprints go to:

<http://journals.bmj.com/cgi/reprintform>

To subscribe to BMJ go to:

<http://group.bmj.com/subscribe/>