

Monitored posterior transcleral drainage of subretinal fluid

DAVID McLEOD

From the Surgical Vitreoretinal Unit, Moorfields Eye Hospital, City Road, London EC1V 2PD

SUMMARY A simple method for drainage of posteriorly-sequestered subretinal fluid following vitrectomy and fluid/gas or fluid/silicone oil exchange is described. Deliberate retinotomy is thereby avoided.

After vitrectomy and membrane dissection for complicated retinal detachments surgeons are sometimes faced with the problem of achieving complete reattachment of bullously elevated retina intraoperatively in order to maximise the efficacy of postoperative internal tamponade of breaks. Internal transretinal drainage of subretinal fluid (SRF), with simultaneous exchange of vitreal fluid for air/gas mixture or silicone oil, offers a safe and simple means of achieving such 'hydraulic reattachment' provided a retinal break is conveniently located posteriorly. Where the causative break is located peripherally, however, it may prove impossible to drain all SRF internally, because the buoyancy of injected gas or silicone oil compresses the anterior retina against the pigment epithelium, with 'posterior sequestration' of SRF. In anticipation of this problem, or confronted with such sequestration, standard transcleral release of SRF or deliberate posterior retinotomy followed by internal SRF drainage has been advocated.^{1,2} But each method is associated with significant risks and practical difficulties. The purpose of this report is to popularise a simple, effective, and safe method of drainage of posteriorly sequestered SRF during common gauge vitreous microsurgery.

Material and methods

Monitored posterior transcleral drainage of SRF with simultaneous intravitreal injection of gas or silicone oil is a modification of the SRF drainage techniques employed for many years by Scott in Cambridge and Wilder in Chicago. The only instrumentation required is a standard 20 gauge hypodermic needle, which offers the best compromise between minimum desirable size and necessary strength of the needle

shaft. The distal 2 mm of the needle is bent with artery forceps to 100° (while the sharpness of the tip is maintained), and the shaft is also gently bent to conform with the contour of the globe (Fig. 1). Attachment of the needle to a 2 ml syringe provides a useful handle for the manipulations.

The procedure is monitored throughout by indirect ophthalmoscopy (though biomicroscopic monitoring

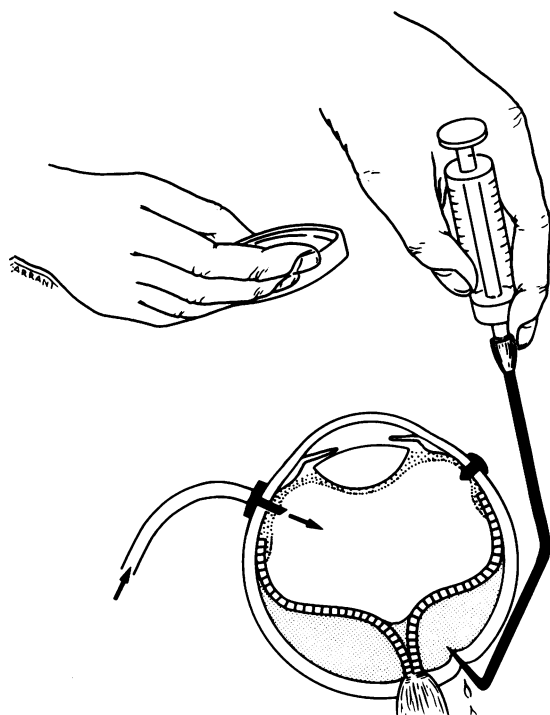


Fig. 1 Monitored transcleral drainage of posteriorly sequestered subretinal fluid.

is also possible). After three-port vitrectomy and membrane dissection, all preretinal fluid is exchanged for the gas mixture or silicone oil with a Charles flute needle or linear suction device.¹ The two active sclerotomies are then temporarily plugged. The 'ankle' of the bent needle is slid posteriorly through Tenon's space just below the medial rectus (any vortex veins being thus avoided) and the sharp tip is then directed normal to the sclera. An indentation is created and can be observed under the retina some 3 or 4 mm inferonasal to the optic disc, that is, peripheral to the site of penetration of the short posterior ciliary arteries. With the eye tension 'firmed' by gas or oil injection (so that scleral indentation and possible retinal apposition to the pigment epithelium at the sclerotomy site are minimised) the sclera is penetrated by a sharp tug on the bent needle, and 'flashing steel' is observed in the subretinal space. Myopic eyes are most readily penetrated owing to the thinness of the sclera. SRF drains round the needle, and the retina progressively flattens in a controlled fashion while intravitreal injection proceeds. Visualisation and control are easier with silicone oil than with gas. Drainage usually continues after removal of the needle tip from the subretinal space, though gentle massage of the area round the sclerotomy is occasionally required to flatten the retina completely. No retinal coagulation is used at the sclerotomy site.

Further internal drainage of preretinal fluid over the optic disc is generally necessary in order completely to fill the vitreous cavity with silicone oil. During gas exchange in phakic eyes, however, an incomplete preretinal fill is desirable in order to reduce the risk of gas induced cataract postoperatively. Nevertheless the extent of gas filling of the globe is such that no more than 20% sulphahexa fluoride gas/air mixture is used so as to preclude postoperative expansion of the gas bubble.

Results

Of the 21 operations in which posterior transcleral SRF drainage was attempted the retina completely reattached intraoperatively in all but one; the exception was a prephthisical eye with very thick sclera and choroid. The nature of the retinal detachment had no influence on the effectiveness of the procedure, whether due to diabetic combined rhegmatogenous and traction detachment, giant retinal tear, or rhegmatogenous retinal detachment with or without massive periretinal proliferation.

In only two procedures did significant subretinal bleeding result (and this mainly drained outside the eye). Retinal tearing or incarceration in the posterior sclerotomy was not seen. There were no late compli-

cations (such as fibrovascular ingrowth), and the only persistent sign of posterior drainage was a focal 0.5 mm white spot marking the defect in the pigment epithelium, Bruch's membrane, and choroid.

Discussion

At first sight posterior SRF drainage unguarded by sclerotomy sutures would appear to be a dangerous method of SRF release. This has not proved to be the case in practice. The risk of choroidal haemorrhage is reduced by the maintenance of intraocular pressure throughout the procedure, the sharp choroidal penetration (thus avoiding tractional rupture of veins), the site of drainage away from large choroidal vessels, and the absence of choroidal congestion induced by prior cryotherapy. If there is bleeding into the subretinal space, the blood tends to be evacuated along with SRF while choroidal vascular thrombosis becomes established. The risk of retinal incarceration and prolapse is reduced by the ophthalmoscopic monitoring, the controlled intravitreal injection, and the small size of the sclerotomy (which nevertheless stays open until all SRF is expressed, because the contour of the scleral envelope is maintained). In addition the retina is stretched out beneath the vitreal gas or silicone oil globule. A similar effect is utilised to 'reduce' vitreoretinal prolapse through a pars plana entry site during vitrectomy for bullous retinal detachment.²

Monitored posterior SRF drainage is therefore preferred over other sequential or simultaneous techniques of transcleral drainage and intravitreal injection. It obviates the need for deliberate posterior retinotomy and internal SRF drainage, with its attendant risks of bleeding, postoperative reopening of the retinotomy, and stimulation of periretinal membrane proliferation. Postoperative positioning of the patient can then be directed entirely to tamponade of the causative breaks rather than to an additional iatrogenic hole. The complete retinal reattachment facilitates cryocoagulation of breaks and localisation of episcleral buckles, minimises pigment fallout under the retina or production of folds of redundant retina, and maximises the efficacy of postoperative internal tamponade (which is especially valuable for inferiorly located breaks unsupported on a buckle).

I am grateful to Miss Heather Lucas for preparing the manuscript and Mr Terry Tarrant for the illustration.

References

- 1 Charles S. *Vitreous microsurgery*. Baltimore: Williams and Wilkins, 1981.
- 2 Michels RG. *Vitreous surgery*. St Louis, Toronto, London: Mosby, 1981.



Monitored posterior transcleral drainage of subretinal fluid.

D McLeod

Br J Ophthalmol 1985 69: 433-434

doi: 10.1136/bjo.69.6.433

Updated information and services can be found at:

<http://bjo.bmj.com/content/69/6/433>

These include:

References

Article cited in:

<http://bjo.bmj.com/content/69/6/433#related-urls>

Email alerting service

Receive free email alerts when new articles cite this article. Sign up in the box at the top right corner of the online article.

Notes

To request permissions go to:

<http://group.bmj.com/group/rights-licensing/permissions>

To order reprints go to:

<http://journals.bmj.com/cgi/reprintform>

To subscribe to BMJ go to:

<http://group.bmj.com/subscribe/>