

Extracapsular lens extraction and posterior chamber intraocular lens insertion combined with trabeculectomy

JEFFREY L JAY

From the Tennent Institute of Ophthalmology, University of Glasgow

SUMMARY Trabeculectomy for primary glaucoma was successfully combined with extracapsular lens extraction and insertion of a Pearce tripod posterior chamber lens in seven eyes of five patients. The results were similar to those expected from each component of the operation when performed alone, and all eyes achieved visual acuity of 6/9 or better with control of intraocular pressure below 22 mmHg without supplementary medical treatment. The incidence of mild anterior uveitis (three out of seven eyes) and hyphaema (two out of seven eyes) was greater than usual with this type of cataract extraction but no more than expected after trabeculectomy. Mydriatic drops may be used to treat postoperative iritis without danger to the stability of this pattern of implant. In addition the anterior chamber cannot become shallow, as the rigid legs of this lens extend behind the iris beyond the periphery of the cornea and prevent forward movement of the implant even if there is excessively free drainage of aqueous after the operation.

In recent years authors from many countries have considered it an advantage to combine simultaneous trabeculectomy with lens extraction when cataract surgery becomes necessary in patients with glaucoma.¹⁻⁹ Earlier reports justified this combined operation only in cases where the intraocular pressure had been difficult to control medically, but recently the indications have widened to include cases where medical control has appeared satisfactory before cataract surgery. The risks and successes of the combined procedure are those of each component separately, and it reduces the chance of having to deal with the considerable problems in management of uncontrolled glaucoma in an aphakic eye.

The safety and optical advantages of intraocular lens implantation are now widely recognised, and, although Stiegler¹⁰ has reported favourable results combining the insertion of a Kelman II anterior chamber lens when intracapsular extraction is combined with trabeculectomy, many surgeons would still hesitate to add lens implantation to the operation of cataract extraction combined with trabeculectomy.

In 1979 Percival¹¹ succinctly summarised the practical problems, and de Heer¹² reviewed the limited reports on various lens types.

This paper describes the initial experience of satisfactory insertion of a single plane, rigid posterior chamber intraocular lens when trabeculectomy is combined with extracapsular lens extraction.

Material and methods

SURGICAL TECHNIQUE

The operation is essentially a combination of Watson's trabeculectomy¹³ and extracapsular lens extraction with insertion of a sutureless Rayner-Pearce vaulted tripod posterior chamber lens in the capsular bag.¹⁴ An adequate operating microscope with coaxial illumination is therefore essential to display the dissection of the lens capsule against the red reflex. Chloramphenicol eye drops are applied four times in the 24 hours before operation, and the pupil is fully dilated with 1% cyclopentolate and 10% phenylephrine immediately before surgery. This is supplemented with a subconjunctival injection of 0.25 ml of Mydracaine No. 2 (atropine, procaine, adrenaline), once the patient has been anaesthetised, so that full mydriasis is maintained during the

Correspondence to Dr J.L. Jay, Tennent Institute of Ophthalmology, Church Street, Glasgow G11 6NT.

intraocular dissection. It is wise to avoid dilating the pupil as part of the admission examination, because this preliminary exposure often renders the pupil refractory to subsequent dilatation at the time of operation. An outer scleral flap 4×4 mm is fashioned under a fornix based conjunctival flap, and the remainder of the corneoscleral incision for cataract extraction extends a further 6 mm to one side of the trabeculectomy site, so that the peripheral iridectomy at the trabeculectomy fistula will not coincide with the tip of the upper leg of the implant. After raising the superficial scleral flap and completing the corneoscleral ab-externo groove, the anterior chamber is entered in the depth of the groove with an irrigating cystitome through a puncture incision small enough to ensure a watertight seal. The D shaped anterior capsulotomy is then completed to fashion a deep inferior pocket before the inner corneoscleral block of the trabeculectomy is excised. Peripheral iridectomy is performed at the trabeculectomy site, and the trabeculectomy opening is then extended along the ab-externo groove incorporating the entry puncture used for capsulotomy. Thereafter the anterior capsule is removed, the pupil is swept behind the upper denuded part of the lens, and the lens is removed with an irrigating vectis. Any remaining cortex is aspirated manually with a coaxial aspiration-irrigation cannula, care being taken to preserve the posterior capsule. A sutureless Pearce tripod vaulted intraocular lens of suitable power is inserted into the inferior capsular pocket, and the upper leg (6.5 mm) is slipped behind the pupil into the iridociliary sulcus at the 12 o'clock meridian. The incision is closed with 10-0 nylon interrupted sutures at the corners of the trabeculectomy flap and along the corneoscleral wound.

Postoperative treatment consists of chloramphenicol and betamethasone drops applied four times daily with a mydriatic regimen of once daily intensive dilatation of the pupil with cyclopentolate and phenylephrine drops combined with a regular prescription for cyclopentolate or atropine as necessary. The eye is bandaged for the first two days, and the patient is discharged between the 3rd and 6th day, depending on home circumstances.

PATIENTS

The operation was performed on seven eyes of five consecutive patients who had primary glaucoma requiring treatment and who were otherwise suitable for extracapsular lens extraction with intraocular lens implantation. There were four female and one male patient, whose ages ranged between 68 and 81 years (mean 73 years). Four had primary open angle glaucoma and one had chronic angle closure glaucoma with 30% peripheral anterior synechiae.

Visual field analysis with a Tubingen perimeter had suggested arcuate visual field defects diagnostic of glaucoma in four patients when first examined and before the development of dense cataract. The fifth patient had advanced cataract when first examined and accurate visual field testing was not possible. For each eye the maximum intraocular pressure without medical therapy ranged from 24 to 36 mmHg (average 28 mmHg). No eye had had previous surgery.

Results

Patients have been followed up for two to 36 months (mean 18 months). In all eyes vision was restored to 6/9 or better, and the intraocular pressure was reduced to below 22 mmHg without supplementary medical therapy. Fig. 1 shows the maximum untreated preoperative intraocular pressure and the postoperative levels. The effect of this combined operation, as demonstrated by the straight line relating the reduction in intraocular pressure to the initial maximum untreated pressure, is similar to that found when trabeculectomy alone was carried out in

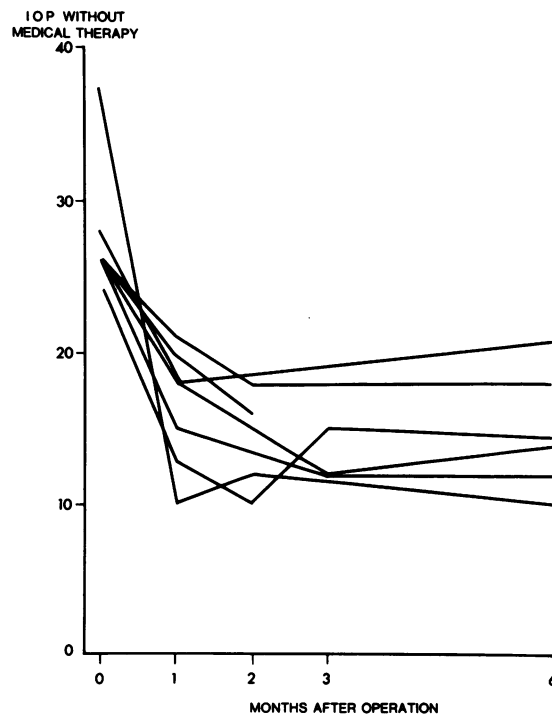


Fig. 1 Reduction of intraocular pressure from untreated preoperative levels after trabeculectomy combined with extracapsular lens extraction and insertion of a Pearce tripod posterior chamber lens. No medication was required to reduce the postoperative intraocular pressure.

primary open angle glaucoma where the intraocular pressure is lowered to the physiological range irrespective of the preoperative pressure.¹⁵ The observed visual field improvement was probably a result of improved retinal illumination following removal of the cataractous lens.

After trabeculectomy the risk of shallow or flat anterior chamber in the presence of an intraocular lens might be hazardous, but the Pearce tripod lens is a single plane lens with no component in front of the pupil, and its rigid legs act as radial struts to stop the implant moving forwards even with excessive drainage of aqueous. This implant will therefore prevent the anterior chamber becoming shallow (Fig. 3), a feature which is also useful when intraocular lens insertion is combined with penetrating keratoplasty. It is not known whether posterior chamber lenses with flexible loops will prove stiff enough to prevent loss of the anterior chamber in this manner, and for various reasons iris plane lenses and rigid angle supported lenses are best avoided in glaucomatous eyes.¹⁶

Many glaucoma patients may have used miotic drops for years before surgery, and adequate dilatation of the pupil for extracapsular cataract may be impossible. In these cases the pupil may be enlarged surgically during the operation by a radial iridotomy from iris root to pupil, and after insertion of the implant the pupil is restored by suturing the iris.

It seems that, where a surgeon is experienced in this technique of cataract surgery, it is now possible to offer patients the benefit of combining intraocular lens implantation with glaucoma surgery. It is, however, still necessary to select patients with caution, as

experience is limited to seven eyes which were eventually found to have good residual optic nerve function.

References

- 1 Galin MA, Hung PT, Obstbaum SA. Cataract extraction in glaucoma. *Am J Ophthalmol* 1979; **87**: 124-9.
- 2 Collado Hornillos JA, López I, Izaquime J, Velarde R, et al. Results of trabeculectomy combined with cataract extraction. *Arch Soc Esp Ophthalmol* 1980; **40**: 1271-9.
- 3 Edwards RS. Trabeculectomy combined with cataract extraction: a follow-up study. *Br J Ophthalmol* 1980; **64**: 720-4.
- 4 Grizalbo MP, Gomez ML, López A, Ferrer C, Honrubia FM. *Arch Soc Esp Ophthalmol* 1980; **40**: 469-75.
- 5 Luntz MH, Berlin MS. Combined trabeculectomy and cataract extraction. *Trans Ophthalmol Soc UK* 1980; **100**: 533-41.
- 6 Scuderi G, Balestrazzi E, Scorcio G. Combined operations for cataract and glaucoma. *Clin Oculist Patol Oculare* 1980; **1**: 5-16.
- 7 Wechsler A, Robinson LP. Simultaneous surgical management of cataract and glaucoma. *Aust J Ophthalmol* 1980; **8**: 151-60.
- 8 McPherson S. Combined trabeculectomy and cataract extraction. *Int Ophthalmol Clin* 1981; **21**: 87-92.
- 9 Klemetti A, Kalina T. Combined trabeculectomy and cataract operation. A follow-up study. *Acta Ophthalmol (Kbh)* 1982; **60**: 259-66.
- 10 Stiegler G. Combined trabeculectomy: intracapsular cataract surgery with lens implantation. *Klin Monatsbl Augenheilkd* 1981; **179**: 456-60.
- 11 Percival P. Policy on cataract with glaucoma. *Contact Intraocular Lens Med J* 1981; **7**: 71-2.
- 12 De Heer LJ. Glaucoma as a problem in intraocular lens implantation. *Doc Ophthalmol* 1980; **49**: 337-46.
- 13 Watson PG. Trabeculectomy. A modified ab-externo technique. *Ann Ophthalmol* 1970; **2**: 199-205.
- 14 Pearce JL. Experience with 194 posterior chamber lenses in 20 months. *Trans Ophthalmol Soc UK* 1977; **97**: 258-64.
- 15 Jay JL, Murray SB. Characteristics of reduction of intraocular pressure after trabeculectomy. *Br J Ophthalmol* 1980; **64**: 432-5.
- 16 Layden WE. Pseudophakia and glaucoma. *Ophthalmology (Rochester)* 1982; **89**: 875-9.



Extracapsular lens extraction and posterior chamber intraocular lens insertion combined with trabeculectomy.

J L Jay

Br J Ophthalmol 1985 69: 487-490

doi: 10.1136/bjo.69.7.487

Updated information and services can be found at:
<http://bjo.bmj.com/content/69/7/487>

References

These include:

Article cited in:

<http://bjo.bmj.com/content/69/7/487#related-urls>

Email alerting service

Receive free email alerts when new articles cite this article. Sign up in the box at the top right corner of the online article.

Notes

To request permissions go to:
<http://group.bmj.com/group/rights-licensing/permissions>

To order reprints go to:
<http://journals.bmj.com/cgi/reprintform>

To subscribe to BMJ go to:
<http://group.bmj.com/subscribe/>