

## *Pasteurella multocida* endophthalmitis

MARC E HOFFMAN,<sup>1</sup> EDWARD M SORR,<sup>1</sup> AND MICHAEL BARZA<sup>2</sup>

From the <sup>1</sup>Department of Ophthalmology, Central Medical Center and Hospital, Pittsburgh, PA and the <sup>2</sup>Department of Medicine, New England Medical Center, Boston, MA, USA

**SUMMARY** We have recently seen an unusual case of endophthalmitis secondary to *Pasteurella multocida* infection. Unlike previously reported cases this patient had no previous history of animal bites or scratch wounds. Treatment included subconjunctival, parenteral, and intravitreal administration of ampicillin. Although the eye was sterilised, the patient's vision remained poor owing to the extensive amount of retinal necrosis.

*Pasteurella multocida* is a Gram-negative coccobacillus found in the upper respiratory tract of healthy domestic animals. The organism is transmitted to humans primarily via cat and dog bites or scratch wounds. We present the third reported case of *Pasteurella multocida* endophthalmitis and the first in which no animal contact had occurred.

### Case report

A 61-year-old white male presented in February 1986 complaining of sudden loss of vision in his right eye. The patient's past medical history was significant for a seizure disorder, cirrhosis and chronic cellulitis of his left leg for the past four years. The patient denied a history of animal bites or trauma.

He had undergone phacoemulsification with implantation of an iris plane lens in the right eye in November 1977. Vitreous humour was lost at the time of surgery, so that he required an anterior vitrectomy. Postoperatively the patient developed mild cystoid macular oedema. However, his vision stabilised to 20/50. At the time of presentation his visual acuity was light perception in the right eye and 20/60 in the left eye.

Slit-lamp examination revealed a 2 mm hypopyon with heavy fibrin accumulation in the anterior segment and synechiae to the intraocular lens preventing pupillary dilatation (Fig. 1). Tensions by applanation were 34 mm Hg in the right eye and 14 mm Hg in the left eye. No red reflex was noted. B scan ultrasonography revealed dense vitreous debris, with the retina appearing flat. The clinical diagnosis was bacterial endophthalmitis.

Correspondence to Marc E Hoffman, DO, Central Medical Center and Hospital, 1200 Centre Avenue, Pittsburgh, PA 15219, USA.

Pars plana vitrectomy was performed three hours after presentation, but owing to poor visualisation of the posterior segment a total vitrectomy was not possible. Specimens collected at the time of surgery revealed no fungi, though many Gram-negative pleomorphic rods and polymorphonuclear leucocytes were present. Gentamicin 100 µg and cefazolin 2250 µg were injected intravitreally at the time of surgery. Cultures of the aspirated aqueous and vitreous humour were positive for *Pasteurella multocida*. The organism was isolated on blood and chocolate agar. There was no growth on EMB agar. Biochemical reactions were positive for glucose, sucrose, sorbitol,

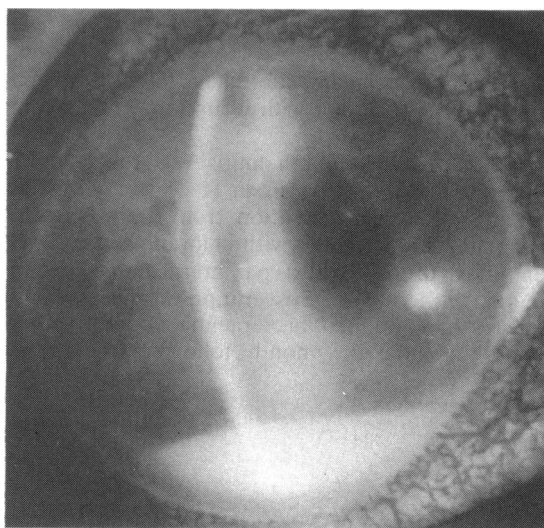


Fig. 1 20% anterior chamber hypopyon with fibrin covering the iris plane lens.

urease, indole, nitrate, and oxidase. The patient was given 1000 µg of ampicillin intravitreally via a pars plana injection on the second postoperative day as well as intravenous ampicillin 3 g every six hours and prednisone 80 mg per day by mouth for 10 days. An additional 100 mg of ampicillin was injected subconjunctivally.

Topical therapy included prednisolone acetate 1% hourly and cyclopentolate four times a day. A second intravitreal injection of ampicillin 1000 µg was given on the third postoperative day, and two additional subconjunctival injections were administered on the third and fifth postoperative days. Three days postoperatively a vitreous tap was repeated and was found to be negative for organisms on culture and Gram stain. The anterior segment and anterior vitreous cleared three days after vitrectomy; however, only hand motions vision was achieved in this eye. Organisation of the posterior vitreous prevented visualisation of retinal detail. Cultures from the area of cellulitis of the patient's leg yielded a heavy growth of *Proteus mirabilis* and a light growth of *Staphylococcus epidermidis*, but there was no evidence of *Pasteurella multocida*.

Several weeks later repeat pars plana vitrectomy was performed to remove the vitreous opacification and explore the retina. At the time of surgery extensive vitreous strands and debris as well as severely necrotic retina were found. Repeat Gram stain and culture and sensitivity tests at this time were negative. The patient's visual acuity remained light perception six months postoperatively.

## Discussion

To our knowledge only two other cases of *Pasteurella multocida* endophthalmitis have been reported. Serious *P. multocida* infections have previously been reported in association with wound infections from animal bites.<sup>1,2</sup>

*P. multocida* endophthalmitis was reported by Galloway and Robinson<sup>2</sup> in an 11-year-old girl who sustained a scleral laceration from a cat scratch. This patient was treated with chloramphenicol and gentamicin drops as well as parenteral ampicillin and gentamicin. However, evisceration was necessitated because of continued bacteraemia and refractory endophthalmitis one month following the initial injury.

Weber *et al.*<sup>1</sup> reported the first case of *P. multocida* endophthalmitis in which excellent vision was preserved. The patient was a 10-year-old male who had multiple corneal lacerations due to a cat scratch. There were no signs of anterior or posterior segment infection at the time of surgical repair. However, *P. multocida* was grown from the vitreous and iris specimens. This patient responded to systemic ampicillin and cefazolin and never received the drug either intravitreally or subconjunctivally.

The decision to give our patient ampicillin was made because previous studies reported extreme sensitivity of this organism to the drug.<sup>3</sup> The hypopyon and anterior vitritis cleared, suggesting that therapeutic levels of ampicillin were achieved in the aqueous through intravitreal, parenteral, and subconjunctival routes. Ampicillin has only rarely been used clinically in the vitreous cavity. Peyman experimentally has found that up to 10 mg of ampicillin given intravitreally is not toxic to the retina.<sup>4</sup>

So far there have been no reported cases of *Pasteurella multocida* endophthalmitis in a patient lacking a previous history of animal bites or trauma. This would suggest that the infection in this patient might have been endogenous. However, there was no evidence of another nidus for this infection and no leucocytosis was present. With aggressive antibiotic and surgical intervention, sterilisation of the eye was achieved. However, owing to the severity of the endophthalmitis at the time of presentation, the visual outcome was poor.

In summary, we present an unusual case of *Pasteurella multocida* endophthalmitis in a patient with chronic cirrhosis and lower limb cellulitis. We advise intravitreal ampicillin early in the course of this infection to eradicate the organism.

## References

- 1 Weber DJ, Wolfson JS, Swartz MN, Hooper DC. *Pasteurella multocida* infections. Report of 34 cases and review of the literature. *Medicine (Baltimore)* 1984; **63**: 133-54.
- 2 Galloway NR, Robinson GE. Panophthalmitis due to *Pasteurella septica*. *Br J Ophthalmol* 1973; **57**: 153-5.
- 3 Weinstein L. Antimicrobial agents. In: Goodman LS, Gilman A, eds. *The pharmacological basis of therapeutics*. New York: Macmillan, 1975: 1010-912.
- 4 Peyman GA, Schulman JA. *Intravitreal surgery: principles and practice*. New York: Appleton-Century-Crofts, 1985: 411.

Accepted for publication 2 September 1986.



## **Pasteurella multocida endophthalmitis.**

M E Hoffman, E M Sorr and M Barza

*Br J Ophthalmol* 1987 71: 609-610  
doi: 10.1136/bjo.71.8.609

---

Updated information and services can be found at:  
<http://bjo.bmj.com/content/71/8/609>

---

### **References**

*These include:*

Article cited in:  
<http://bjo.bmj.com/content/71/8/609#related-urls>

### **Email alerting service**

Receive free email alerts when new articles cite this article. Sign up in the box at the top right corner of the online article.

---

### **Notes**

---

To request permissions go to:  
<http://group.bmj.com/group/rights-licensing/permissions>

To order reprints go to:  
<http://journals.bmj.com/cgi/reprintform>

To subscribe to BMJ go to:  
<http://group.bmj.com/subscribe/>