

## LETTERS TO THE EDITOR

### Adverse effects of subconjunctival injections of mydriatic agents

SIR,—The adverse effects of mydriatic agents are well documented. When using these drugs one must carefully consider the relevant medical history. The uveitic patient with early posterior synechiae and concomitant systemic disease is illustrative of this problem. We report a serious complication in a patient treated with mydriatic agents.

A 26-year-old male had a 10-day history of photophobia, fatigue, and fevers for several months. On examination his vision was 20/40 and the pupils were constricted secondarily to 270° posterior synechiae. He had hyperaemic conjunctivae, diffuse 'mutton-fat' keratic precipitates, and 3+ cells. Dilatation with topical and pledget soaked tropicamide 1% and phenylephrine 2.5% was unsuccessfully attempted. The patient returned 24 hours later, and a mixture of two drops (100 µl) each of tropicamide 1%, atropine 1%, and phenylephrine 10% was injected subconjunctivally at the inferior limbus of the right eye. This mixture comprised 7 mg of phenylephrine, 1 mg of atropine, and 1 mg of tropicamide. The patient immediately developed severe headache, dyspnoea, and diaphoresis. His pulse was 110 per minute and blood pressure of 160/110 mmHg.

He was taken to the emergency room, where he was found to be in respiratory failure. Chest x-ray revealed diffuse interstitial infiltrates not present on the previous day's films. The patient was intubated, and Swan-Ganz catheterisation revealed a pulmonary wedge pressure of 8 mm. He was transferred to the intensive care unit for management of non-cardiogenic pulmonary oedema. Subsequent diagnostic testing was consistent with a diagnosis of sarcoidosis. The pulmonary oedema resorbed and the patient was discharged on topical steroids with subsequent resolution of the iritis.

This is the first reported case of non-cardiogenic pulmonary oedema associated with the use of mydriatic drugs. Both atropine and tropicamide are anticholinergic drugs whose actions include relaxation of the circular muscle of the iris and paralysis of the ciliary muscle. The principal adverse cardiopulmonary effect of these drugs is tachycardia. Phenylephrine, a potent, direct-acting, and selective  $\alpha_1$  agonist exerts its main mechanism of action by stimulation of  $\alpha$  receptors of the dilator pupillae.<sup>1</sup> Stimulation of these receptors can cause constriction of the systemic, pulmonary, and coronary arteries, leading to severe hypertension, headache, ventricular arrhythmias, myocardial infarction, and cardiac arrest.<sup>2</sup> It is conceivable that in our patient phenylephrine may have produced severe pulmonary vasoconstriction leading to alveolocapillary damage and consequent non-cardiogenic pulmonary oedema. In addition our patient had pre-existing pulmonary sarcoidosis, which may have increased his susceptibility to lung injury from other insults.

Subconjunctival injections of mydriatic agents to forcibly dilate pupils with synechiae is recommended<sup>3</sup> and is commonly used in several eye centres. These injections, especially in hyperaemic conjunctivae, can lead to enhanced systemic absorption and serious complications. We advise extreme caution

when using this method of administering dilating agents.

ILAN HARTSTEIN  
11949 Goshen Avenue 301,  
Los Angeles, CA 90049,  
USA  
NICHOLAS DEUTSCH  
UCLA Medical Center,  
Los Angeles, CA 90024,  
USA

Requests for reprints to:  
Ilan Hartstein.

- 1 Lamberts DW, Potter ED. *Clinical ophthalmic pharmacology*. Boston: Little, Brown, 1987: 321.
- 2 Fraunfelder FT, Scafidi AF. Possible adverse effects from topical ocular 10% phenylephrine. *Am J Ophthalmol* 1978; 85: 447.
- 3 Duane TD. *Clinical ophthalmology*. Revised ed. Philadelphia: Lippincott, 1988: 4: chapter 43: 3.

### Branch retinal artery occlusion in toxoplasma retinochoroiditis

SIR,—Although toxoplasma retinochoroiditis may cause retinal vein occlusion, vascular remodelling, and even retinochoroidal anastomosis,<sup>1,2</sup> retinal artery obstruction is rare.<sup>3,5</sup> We have recently studied a patient suffering from such a complication.

An 18-year-old student attended in March 1989, 24 hours after the sudden loss of inferotemporal field in the right eye, which was confirmed by automated perimetry. A branch artery occlusion was found in a corresponding area of focal retinochoroidal inflammation. Some areas of periphlebitis were also seen peripherally. Fluorescein angiography confirmed occlusion of the artery within the area of inflammation (Fig 1). Antibodies to toxoplasma were detected by latex agglutination at serum dilutions of more than 1:1000.

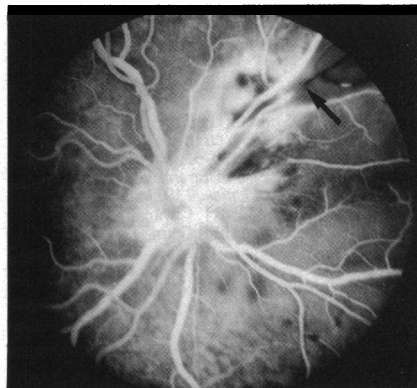


Figure 1 Fluorescein angiogram showing the active retinochoroidal inflammation and the occluded retinal arteriole (arrow).

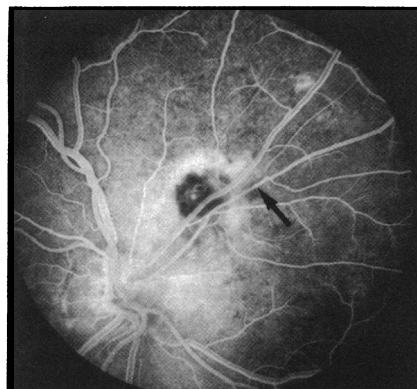


Figure 2 Fluorescein angiogram showing resolution of the inflammation and reperfusion of the retinal arteriole (arrow).

The patient was treated with clindamycin, 150 mg four times a day, and prednisolone 60 mg daily, reducing over eight weeks. At the end of this period the inflammatory focus had become inactive. Repeat fluorescein angiography demonstrated reperfusion of the artery (Fig 2). However, the field defect persisted.

This case confirms that field loss in toxoplasma retinochoroiditis can result from arterial occlusion. Arterial thrombosis is presumably caused by the intense adjacent inflammation. Corticosteroid and antimicrobial therapy<sup>6</sup> may assist resolution of the inflammatory focus and should be considered when retinal vessels are involved and therefore at risk of occlusion. If, as in this case, occlusion has already occurred, retinal function may not recover despite resolution of the inflammation and reperfusion of the blood vessel.

TOM H WILLIAMSON  
PAUL A R MEYER  
Tennent Institute of  
Ophthalmology,  
Western Infirmary  
Church Street,  
Glasgow G11 6NT  
and Addenbrookes Hospital, Cambridge

- 1 Gaynon MW, Boldey ED, Strahlman ER, Fine SL. Retinal neovascularisation and ocular toxoplasmosis. *Am J Ophthalmol* 1984; 98: 585-9.
- 2 Gass JM. *Stereoscopic atlas of macular disease: diagnosis and treatment*. 3rd ed. St Louis: Mosby, 1987; 2: 464-9.
- 3 Owens PL, Goldberg MF, Busse BJ. Prospective observation of vascular anastomoses between the retina and the choroid in recurrent toxoplasmosis. *Am J Ophthalmol* 1979; 88: 402-5.
- 4 Braunstein RA, Gass JDM. Branch artery obstruction caused by acute toxoplasmosis. *Arch Ophthalmol* 1980; 98: 512-3.
- 5 Morgan CM, Gragoudas ES. Retinal artery occlusion associated with recurrent toxoplasmosis. *Arch Ophthalmol* 1987; 105: 130-1.
- 6 Lakhpanal V, Schocket SS, Nirankari VS. Clindamycin in the treatment of toxoplasmic retinochoroiditis. *Am J Ophthalmol* 1983; 95: 605-13.

### Corneal penetration by tarantula hairs

SIR,—Tarantulas are large, hairy spiders belonging to the family Theraphosidae. Their popularity as pets parallels the increasing popularity of exotic pets in general. Although their bite is virtually harmless to humans, many species of New World tarantulas possess projectile urticating hairs on the dorsal surface of the abdomen.<sup>1</sup> When threatened, the spiders rapidly stroke their hind legs in a vibratory fashion on the dorsal hairs, catapulting a cloud of barbed hairs at the attacker. Some species may incorporate urticating hairs into their retreats or webs. These hairs, each possessing multiple barbs, are capable of penetrating deeply into skin, and causing intense and prolonged localised urticaria in humans.<sup>1,2</sup> In addition to dermatological trauma tarantula hairs are capable of embedding into the ocular tissues and producing an inflammatory reaction in the eye.<sup>3,4</sup> Due to its small calibre, offending hairs could easily be overlooked without a slit-lamp examination of the anterior eye segment.

A 13-year-old boy reported feeling severe foreign body sensation in both eyes within five minutes of stroking his pet tarantula. This was followed by intense pruritus, tearing, conjunctival injection, and eyelid swelling, thus prompting the patient to rub his eyes vigorously with his fingers. The eye rubbing further aggravated his discomfort. The patient was seen that day by his family physician, who treated him with antibiotic eyedrops. When the symptoms and signs showed only minimal resolution after three weeks of treatment, the patient was referred for ophthalmological con-



## Adverse effects of subconjunctival injections of mydriatic agents.

I Hartstein and N Deutsch

*Br J Ophthalmol* 1991 75: 253  
doi: 10.1136/bjo.75.4.253

---

Updated information and services can be found at:  
<http://bjournal.bmj.com/content/75/4/253.1.citation>

---

### Email alerting service

*These include:*

Receive free email alerts when new articles cite this article. Sign up in the box at the top right corner of the online article.

---

### Notes

---

To request permissions go to:  
<http://group.bmj.com/group/rights-licensing/permissions>

To order reprints go to:  
<http://journals.bmj.com/cgi/reprintform>

To subscribe to BMJ go to:  
<http://group.bmj.com/subscribe/>