

CASE REPORTS

Clearance of corneal crystals in nephropathic cystinosis by topical cysteamine 0.5%

Nicholas P Jones, Robert J Postlethwaite, Joan L Noble

Abstract

A 2-year-old girl with nephropathic cystinosis was successfully treated with topical cysteamine 0.5% to one eye. Clearance of crystals from the treated cornea was virtually complete after three months. The possibilities and limitations of this form of treatment are discussed.

Infantile nephropathic cystinosis is an autosomal recessive condition leading to the progressive accumulation of cystine in tissues including the eye.¹ Characteristic crystal deposition within the cornea and conjunctiva leads to intense photophobia and visual disability.² Later, crystal deposition in the iris, on the lens capsule, and within the retina³ further affects vision. The use of oral cysteamine has been shown to reduce cystine deposition systemically and to improve renal function⁴ but an effect on the cornea has not been demonstrated. Trials of topical cysteamine have shown variable response to treatment,^{5,6} with a minority of patients showing substantial clearance of crystals over treatment periods ranging from four to 37 months. We report on a child with nephropathic cystinosis who, with good compliance to intensive treatment, obtained

excellent corneal clearance of crystals within three months from an initial, severely affected state.

Case report

The patient, a 2-year-old girl, had typical ocular signs of nephropathic cystinosis, with severe crystal deposition within the cornea and conjunctiva. The corneal stroma was more deeply involved at the periphery but involved at least the anterior half at the visual axis (Fig 1). There was intense photophobia. The signs were symmetrical.

Topical 0.5% cysteamine drops were instilled into the right eye only, hourly during waking hours. Treatment was performed by the patient's mother, who was highly motivated, and compliance was considered to be excellent. After three months the eyes were re-examined by the same observer (NPJ). The crystals were completely cleared from the axis of the right cornea. Clearance was substantial, but not complete, from the peripheral cornea (Fig 2). The diminution in photophobia during anterior segment photography was obvious. The left cornea was unchanged from its appearance three months previously. Treatment to the left eye has now

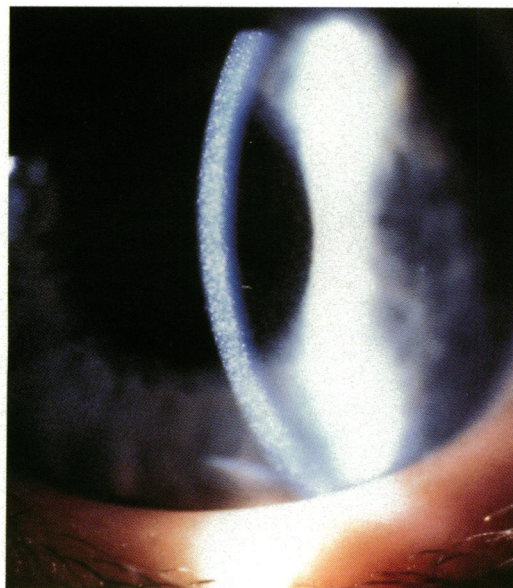


Figure 1 Right cornea before treatment, showing typical severe crystal deposition.

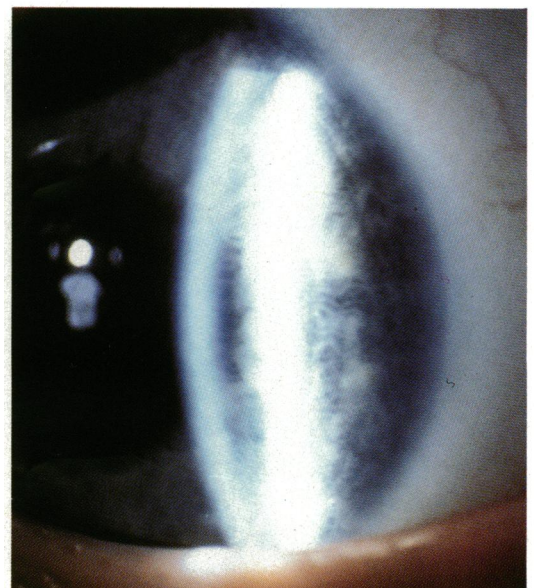


Figure 2 Right cornea after treatment for three months, showing virtually complete clearance of crystals except in the extreme periphery.

Manchester University
Department of
Ophthalmology
N P Jones

Royal Manchester
Children's Hospital
R J Postlethwaite

Manchester Royal Eye
Hospital
J L Noble

Correspondence to:
Mr N P Jones, University
Department of
Ophthalmology, Manchester
Royal Eye Hospital, Oxford
Road, Manchester M13.

Accepted for publication
13 November 1990

given a similar result, and we aim to find a maintenance dose which is both effective and acceptable to the patient.

Discussion

The symptoms of photophobia and glare disability in nephropathic cystinosis can be disabling.^{2,3,6} Increased survival time following the use of systemic cysteamine, or after renal transplantation, makes the long-term ocular effects of great significance.³ Corneal transplantation has been used for intractable symptoms,⁷ yet crystals may quickly accumulate again after such intervention.⁸ An effective long-term topical therapy is clearly desirable.

The results of topical cysteamine therapy have been generally disappointing.^{5,6} Most patients studied by Kaiser-Kupfer *et al* did not show any discernible effect of treatment, but cysteamine 0.5% appeared more effective than 0.1%.⁶ Compliance is clearly a problem with hourly administration of drops, but it is likely that such frequency will not be required for maintenance treatment once the cornea has been cleared. The time taken to clear the cornea is probably related to the initial severity of crystal deposition. Our patient demonstrates that with good compliance with hourly drops of 0.5% cysteamine an excellent result can be obtained. If problems with compliance in long-term therapy are

encountered, it may be that a sustained-release fornix-held preparation would prove useful.

No problems with ocular toxicity have been noted with 0.5% cysteamine,⁹ yet large-dose systemic administration has been shown to be cataractogenic.¹⁰ Since, to be effective, topical cysteamine therapy would be required for life in patients with cystinosis, the long-term effects of such treatment require further evaluation.

We are grateful to Mr A Prest for the production of the illustrations.

- 1 Melles RB, Schneider JA, Rao NA, Katz B. Spatial and temporal sequence of corneal crystal deposition in nephropathic cystinosis. *Am J Ophthalmol* 1987; **104**: 598-604.
- 2 Katz B, Melles RB, Schneider JA. Glare disability in nephropathic cystinosis. *Arch Ophthalmol* 1987; **105**: 1670-1.
- 3 Kaiser-Kupfer MI, Caruso RC, Minkler DS, Gahl WA. Long-term manifestations in nephropathic cystinosis. *Arch Ophthalmol* 1986; **104**: 706-11.
- 4 Gahl WA, Reed GF, Thoene JG, *et al*. Cysteamine therapy for children with nephropathic cystinosis. *N Engl J Med* 1987; **316**: 971-7.
- 5 Kaiser-Kupfer MI, Fujikawa L, Kuwabara T, Jain S, Gahl WA. Removal of corneal crystals by topical cysteamine in nephropathic cystinosis. *N Engl J Med* 1987; **316**: 775-9.
- 6 Kaiser-Kupfer MI, Gazzo MA, Datiles MB, Caruso RC, Kuehl EM, Gahl WA. A randomised placebo-controlled trial of cysteamine eye drops in nephropathic cystinosis. *Arch Ophthalmol* 1990; **108**: 689-93.
- 7 Kaiser-Kupfer MI, Datiles MB, Gahl WA. Corneal transplant in a twelve-year-old boy with nephropathic cystinosis. *Lancet* 1987; **i**: 331.
- 8 Katz B, Melles RB, Schneider JA. Recurrent crystal deposition after keratoplasty in nephropathic cystinosis. *Am J Ophthalmol* 1987; **104**: 190-1.
- 9 Jain S, Kuwabara T, Gahl WA. Range of toxicity of topical cysteamine in rabbit eyes. *J Ocul Pharmacol* 1988; **4**: 127-31.
- 10 Truong T, Sagar SM, Millard WJ, Shaw JL. Cysteamine induces cataracts in newborn rats. *Invest Ophthalmol Vis Sci* 1987; **28**: 1710-3.



Clearance of corneal crystals in nephropathic cystinosis by topical cysteamine 0.5%.

N. P. Jones, R. J. Postlethwaite and J. L. Noble

Br J Ophthalmol 1991 75: 311-312

doi: 10.1136/bjo.75.5.311

Updated information and services can be found at:
<http://bjo.bmj.com/content/75/5/311>

Email alerting service

These include:

Receive free email alerts when new articles cite this article. Sign up in the box at the top right corner of the online article.

Notes

To request permissions go to:
<http://group.bmj.com/group/rights-licensing/permissions>

To order reprints go to:
<http://journals.bmj.com/cgi/reprintform>

To subscribe to BMJ go to:
<http://group.bmj.com/subscribe/>