

# Conjunctival cysts in anophthalmic orbits

Ton J Smit, Leo Koornneef, Frans W Zonneveld

## Abstract

Five out of 149 patients (3%) who received an intraorbital implant to prevent or treat the disfiguring symptoms associated with the postenucleation socket syndrome developed intraorbital conjunctival cysts. All five patients had received a secondary implant two to 14 months previously. After excision of the cysts four patients required additional surgery for lack of conjunctiva and/or recurrent cyst formation. The clinical findings, mechanism of development, and management of this rare but serious complication of socket surgery are described.

Conjunctival cysts of the orbit following enucleation are rare. Only 17 cases of orbital conjunctival cyst formation after enucleation have been reported.<sup>1-6</sup> We have seen this complication in five patients over a period of seven years.

## Patients and methods

The patients consisted of 149 patients referred to the Orbital Center who received an intraorbital implant between January 1982 and April 1989 to prevent or treat the disfiguring symptoms associated with the postenucleation socket syndrome. Fifty-one patients had the implant placed at the time of enucleation (primary implant), 73 some time after enucleation (secondary implant), 17 after replacement of a previously inserted inadequate implant, and eight after an evisceration of the eye. The implants were 18 mm acrylic balls covered with donor sclera, the so-called baseball implants.<sup>7</sup> For patients whose eyes were eviscerated 18 mm bare acrylic balls were used. The implants were inserted in a standardised manner.<sup>6,8</sup>

## Results

Five patients in this series, all with a secondary implant, developed conjunctival cysts in the anophthalmic orbit two to 14 months after the implantation of the baseball (Table 1). In all five increasing difficulty in retaining the prosthesis was the first sign. Proptosis of the prosthesis and shallowness of the fornices (the inferior fornix in four, the superior fornix in one) was also noted. In two a palpable mass was found.

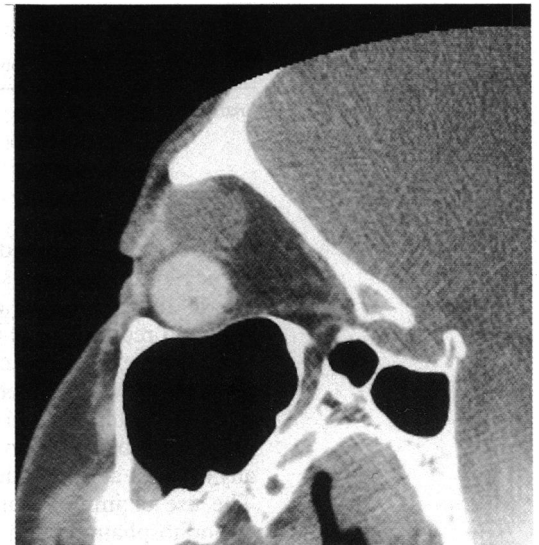


Figure 1 Sagittal CT scan of the anophthalmic orbit (patient 3). A large conjunctival cyst superior to the implant is present. The implant is displaced downwards.

Diagnosis was established with high resolution computerised tomography (CT) in two patients (Fig 1) and with fine needle aspiration of 6-7 ml of a yellow-grey fluid from the mass in one patient. In the other two patients the cysts were accidentally found during surgery for deepening the fornix. In three of the five patients multiple cysts were present. Complete excision was undertaken in all cases.

During excision three implants were replaced because they appeared to communicate with the cysts. The two patients in whom the implant was not replaced at first had a recurrence. The recurrent cysts were removed completely in a second session, together with the implant in one patient. So altogether four out of five implants had to be replaced. In three patients a donor sclera-covered ball was reinserted; in one patient a dermis fat graft was used after recurrent cyst excision because this patient also showed lack of conjunctiva (Table 2).

Histopathological examination revealed cysts lined with non-keratinising stratified squamous epithelium and surrounded by fibrous tissue.

Lack of conjunctiva, resulting in shallow fornices, was a complication found in three patients after excision of the cysts. This required additional treatment: two patients had fornix reconstruction with oral mucous membrane grafts, and in one patient a dermis fat implant was placed instead of a baseball implant - and later on a mucous membrane graft (Table 2).

Unfortunately, the final cosmetic result was poor in all five patients.

## Discussion

Orbital cyst formation following enucleation is a

Orbital Centre, A2-118,  
University of  
Amsterdam, The  
Netherlands  
T J Smit  
L Koornneef

Department of  
Radiology, University of  
Utrecht, The  
Netherlands  
F W Zonneveld

Correspondence to:  
Dr T J Smit, Orbital Centre,  
A2-118, Academisch Medisch  
Centrum, Meibergdreef 9,  
1105 AZ Amsterdam, The  
Netherlands.

Accepted for publication  
22 November 1990

Table 1 Patient data

Patient no.	Age at enucleation (years)	Age at implantation (years)	Age at cyst excision (years)	Time interval from enucleation to cyst excision (years)	Time interval from implantation to cyst excision (months)
1	18	33	33	15	2
2	0.5	53	54	53	14
3	8	31	31	23	4
4	22	39	40	18	14
5	2	30	30	28	3

Table 2 Clinical details

Patient no.	Reason for enucleation	Surgery	Multiple cysts	Additional surgery
1	Trauma	Excision cyst	-	Recurrent cyst excision, replacement implant with dermis fat graft, mucous membrane graft
2	Retinoblastoma	Excision cyst, replacement implant	-	Mucous membrane graft
3	Glioma	Excision cysts	+	Recurrent cyst excision
4	Trauma	Excision cysts, replacement implant	+	Mucous membrane graft
5	Melanoma	Excision cysts, replacement implant	+	

rare but serious complication. In our population it was found in 3% of the patients, but only in those in whom a secondary implant was inserted. Tyers and Collin<sup>6</sup> found conjunctival implantation cysts in 7% of a series of six primary and 35 secondary implantations. They did not describe whether the cysts were found in the primary or in the secondary implant group. They appeared to consider these cysts to be of minor importance, because they could be removed easily, with direct closure of conjunctiva, owing to their being so close to the conjunctival surface.

In our series, however, it appeared to be a serious complication because of the need for further surgery in four of the five patients after excision of the cyst(s). The surgical measures in all five patients, consisting in removal of the cysts and surgical treatment of the subsequent complications, led to deterioration of the cosmetic outcome.

McCarthy *et al*<sup>3</sup> postulated three possible mechanisms for the development of conjunctival cysts in an anophthalmic orbit: (1) inadvertent implantation of a free fragment of conjunctiva within Tenon's capsule during enucleation surgery; (2) incarceration of a tongue of conjunctiva that is accidentally inverted in wound closure through Tenon's capsule; (3) epithelial downgrowth by wound dehiscence. The viable

conjunctiva buried in the socket by one of these mechanisms may form the orbital conjunctival cyst.

It is therefore not surprising that in our series conjunctival cysts were found only in patients with a secondary implant. In contrast to a primary implantation, the orbital anatomy in secondary implantations has already been disturbed, and a space for the implant has to be created by sharp dissection inside the collapsed orbital tissues. Because of this the secondary implantation technique is more complicated. The risk of implantation of conjunctiva into the orbit is increased, because accurate closure of Tenon's capsule and conjunctiva is more difficult. It is therefore important to close Tenon's capsule and conjunctiva with great care in two separate layers. If conjunctival cysts still develop, it is better to remove the implant as well to forestall further recurrences.

We conclude that orbital cyst formation is rare in patients with a primary implant. If orbital conjunctival cysts occur in secondary implants, we recommend removal of the implant together with the cysts to prevent further complications. In general the final cosmetic outcome in these patients remains poor.

- Allison SC, Wergeland FL. Giant conjunctival cyst of the orbit. *Ann Ophthalmol* 1973; 5: 199-202.
- Judisch GF, Maumenee IH. Large orbital conjunctival cyst after enucleation. *Am J Ophthalmol* 1977; 83: 49-51.
- McCarthy RW, Beyer CK, Dallow RL, Burke JF, Lessell S. Conjunctival cysts of the orbit following enucleation. *Ophthalmology* 1981; 88: 30-5.
- Hornblass A, Bosniak S. Orbital cysts following enucleation: the use of absolute alcohol. *Ophthalmic Surg* 1981; 12: 123-6.
- Thach AB, Busack JA, La Piana FG. Orbital cyst with pseudooptic nerve: CT features. *J Comput Assist Tomogr* 1990; 14: 131-2.
- Tyers AG, Collin JRO. Baseball orbital implants: a review of 39 patients. *Br J Ophthalmol* 1985; 69: 438-42.
- Frueh BR, Felker GV. Baseball implant. A method of secondary insertion of an intraorbital implant. *Arch Ophthalmol* 1976; 94: 429-30.
- Collin JRO. Socket surgery. In: Collin JRO, ed. *A manual of systematic eyelid surgery*. Edinburgh: Churchill Livingstone, 1989: 121-37.



## Conjunctival cysts in anophthalmic orbits.

T J Smit, L Koornneef and F W Zonneveld

*Br J Ophthalmol* 1991 75: 342-343

doi: 10.1136/bjo.75.6.342

---

Updated information and services can be found at:

<http://bjo.bmj.com/content/75/6/342>

---

### References

*These include:*

Article cited in:

<http://bjo.bmj.com/content/75/6/342#related-urls>

### Email alerting service

Receive free email alerts when new articles cite this article. Sign up in the box at the top right corner of the online article.

---

### Notes

---

To request permissions go to:

<http://group.bmj.com/group/rights-licensing/permissions>

To order reprints go to:

<http://journals.bmj.com/cgi/reprintform>

To subscribe to BMJ go to:

<http://group.bmj.com/subscribe/>