

## LETTERS TO THE EDITOR

### Spontaneous regression of a choroidal metastasis from renal carcinoma

EDITOR, — Although spontaneous regression of lung and liver metastases from renal cell carcinoma is well known,<sup>1-3</sup> regression of a choroidal metastasis from renal cell carcinoma has not been published in literature as far as we know.

In a 56-year-old male complaining of left flank pain an 8 cm solid and cystic lesion was

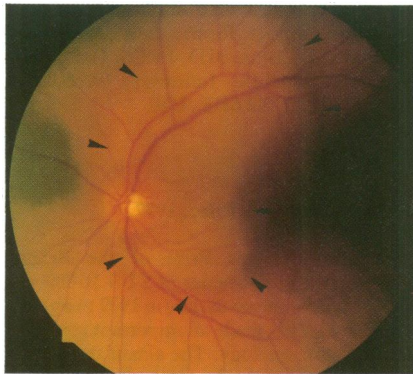


Figure 1 Fundus photograph showing a choroidal metastasis superotemporal to the optic disc. Black arrows indicate the tumour boundaries. Visual acuity 6/12.

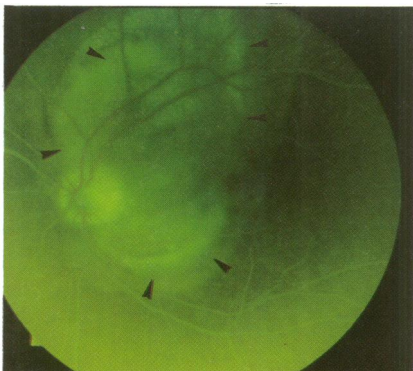


Figure 2 Fluorescein angiography. Progressive diffuse hyperfluorescence of the tumour and serous retinal detachment. Black arrows indicate the border between tumour and serous detachment.

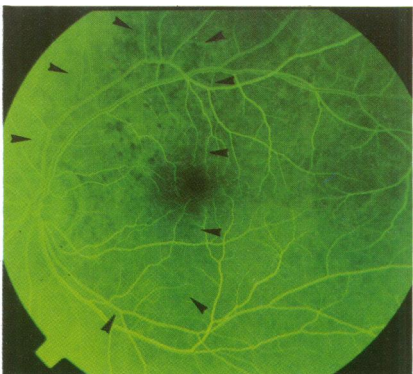


Figure 3 Fluorescein angiography 3 weeks later showing window defects and focal blockage. Diffuse hyperfluorescence had disappeared (Black arrows indicate the boundaries of the previous tumour).

diagnosed in the left kidney by ultrasonography. After radical nephrectomy histopathological examination revealed a primary renal carcinoma which had infiltrated the superior renal vein. Six months after surgery the patient noticed blurred vision in his left eye. Indirect ophthalmoscopy showed a slightly elevated yellow lesion located superotemporally to the disc involving part of the nasal macula (Fig 1). Visual acuity was 6/12. Fluorescein angiography revealed an early hypofluorescence and a late staining of the tumour and surrounding serous detachment (Fig 2).

The tumour prominence in A and B scan was 1.9 mm with a low internal reflectivity. In the B scan choroidal excavation was missing. Because of evidence of an epidemic keratoconjunctivitis, external beam irradiation was delayed for 3 weeks. One week later visual acuity had recovered to 1.0. In indirect ophthalmoscopy the tumour had disappeared leaving a depigmented area with pigment clumping at the site of the previous tumour, which resembled a scar formation after irradiation of a metastasis. Fluorescein angiography revealed pigment epithelial window defects with focal blockage due to pigment clumping (Fig 3). Tumour prominence could not be detected in the A or B scan. Six months later the patient died of widespread metastatic disease.

Recent results obtained from basic and clinical studies have indicated that the following factors could play an important role in spontaneous regression of tumours: (1) generation of antineoplastic cytotoxic cells<sup>4</sup>; (2) production of immunoregulatory cytokines by lymphocytes and monocytes<sup>5</sup>; (3) possible cross reactions between tumour, bacterial antigens,<sup>3</sup> and viral antigens.<sup>3</sup>

GERALD LANGMANN  
K MÜLLNER  
Department of Ophthalmology,  
University of Graz,  
Auenbruggerplatz 4,  
A-8036 Graz,  
Austria

- De Riese W, Goldenberg K, Allhoff E, Stief C, Schlick R, Jonas U. Metastatic renal cell carcinoma (RCC): spontaneous regression, long term survival and late recurrence. *Int Urol Nephrol* 1991; 23: 13-25.
- Ritchie AW, Layfield LJ, de Kernion JB. Spontaneous regression of liver metastasis from renal carcinoma. *J Urol* 1988; 140: 596-7.
- Sureda M, Subira ML, Martin Algarra S, Prieto-Valtuna J, Sangrao B. Spontaneous tumor regression. *Med Clin Barc* 1990; 95: 306-8.
- Zanovello P, Vallerani E, Biasi G, Landolfo S, Collavo D. Monoclonal antibody against IFN gamma inhibits Moloney sarcoma virus-specific cytotoxic T lymphocyte differentiation. *J Immunol* 1988; 140: 1341-4.
- Yamashita Y, Ariyoshi A, Hasuo K, Shirakusa T. Surgical treatment of renal cell carcinoma associated with pulmonary metastasis. *Nippon Gan Chiryō Gakkai Shi* 1989; 24: 759-64.

### Exploding bottles: eye injury due to yeast fermentation of an uncarbonated soft drink

EDITOR, — We would like to draw your attention to the following case. A 20-year-old woman was struck in her right eye by a bottle top which flew off while she was trying to open a plastic bottle containing uncarbonated orange juice. On initial examination, the visual acuity was light perception in the right eye and 6/6 in the left eye. Slit-lamp examination disclosed moderate corneal oedema and total hyphaema. By the third day the hyphaema cleared and gonioscopy showed 180 degrees of angle recession superiorly. Ophthalmoscopic examination revealed a superior vitreous haemorrhage. Within 3 weeks of the accident her visual acuity

had improved to 6/6 and retinal pigment epithelial changes were noted behind the clearing vitreous haemorrhage. Culture of the juice yielded a profuse growth of a yeast which was identified as *Zygosaccharomyces baillii*.<sup>1</sup>

In order to confirm our assumption that a fermentation process had indeed produced sufficient gas to cause the accident, a simple experiment was performed. Orange juice of the same brand (uncontaminated batch) was inoculated with the isolate of *Z baillii*. Prolific gas production was evident after a few hours at room temperature. An attempt to ascertain the pressure developed in a closed container was thwarted by the explosion of the vessel.

*Z baillii* is frequently isolated from spoiling fruit juices and other beverages.<sup>1</sup> The source of the contamination (spoilage) in this case was related to the manufacturing process.

This type of injury has not previously been recognised. However, reports of the explosion of bottles containing carbonated beverages have been published.<sup>2-5</sup> Such incidents were usually related to warm environmental temperature or agitation which released dissolved carbon dioxide and increased the pressure within the bottle.<sup>3-5</sup>

The plastic bottle, now in general use, is a safer alternative to the glass bottle. Nevertheless, the high pressures generated by such common spoilage organisms as *Z baillii* still pose a potential hazard.

AHARON GRINBAUM  
ISAAC ASHKENAZI  
GIORA TREISTER  
Goldschleger Eye Institute,  
Chaim Sheba Medical Center,  
Tel Hashomer 52621, Israel

ANNA GOLDSCHMIED-REOUVEN  
COLIN S BLOCK  
Microbiology Laboratory,  
Chaim Sheba Medical Center,  
Tel Hashomer 52621, Israel

- Barnett A, Payne RW, Yarrow D. *Yeasts: characteristics and identification*. Cambridge University Press, 1985.
- Duerksen KM, Albert DW, Saulson RM. Soda pop top ophthalmopathy. *Am J Ophthalmol* 1988; 61: 761-2.
- Mondino BJ, Brown SI, Grand G. Ocular injuries from exploding beverage bottle. *Arch Ophthalmol* 1978; 96: 2040-1.
- Alsalem M, Sheriff SMM. Ocular injury from carbonated soft drink bottle explosions. *Br J Ophthalmol* 1984; 68: 281-3.
- Bergeson PS, Sehering SA, Sousa-Lenox IJ. Pop bottle explosions: further information. *JAMA* 1978; 239: 2447-8.

## NOTICES

### Keratoconus Self Help and Support Association

For some time keratoconus patients at Moorfields Eye Hospital have met as a self help and support group. On 10 March 1994 this was formally constituted as the Keratoconus Self Help and Support Association. Mr Roger Buckley, MA, FRCS, FRCOphth, Director of Moorfields Contact Lens Department, accepted the Association's invitation to become its president. The Association aims to heighten awareness of keratoconus, its effects, and management, both within the medical and optical professions and generally. Funds are to be raised for publication of a pamphlet for this purpose. While the condition does not lead to blindness, for some the deterioration is such



## Exploding bottles: eye injury due to yeast fermentation of an uncarbonated soft drink

Aharon Grinbaum, Anna Goldschmied-Reouven, Isaac Ashkenazi, et al.

*Br J Ophthalmol* 1994 78: 883  
doi: 10.1136/bjo.78.11.883-a

---

Updated information and services can be found at:  
<http://bjo.bmj.com/content/78/11/883.2.citation>

---

### Email alerting service

*These include:*

Receive free email alerts when new articles cite this article. Sign up in the box at the top right corner of the online article.

---

### Notes

---

To request permissions go to:  
<http://group.bmj.com/group/rights-licensing/permissions>

To order reprints go to:  
<http://journals.bmj.com/cgi/reprintform>

To subscribe to BMJ go to:  
<http://group.bmj.com/subscribe/>