

LETTERS TO THE EDITOR

Peribulbar anaesthesia

EDITOR,—We read with interest the article by S J Talks *et al* on visual acuity and pupillary reactions after peribulbar anaesthesia.¹ Our own experience backs up their figures. We prospectively followed a comparable sample of 50 peribulbar anaesthetics on patients undergoing uncomplicated cataract surgery.

Our anaesthetic technique was similar except that the medial injection of 3–4 ml was only used if complete or near complete akinesia was not attained after 5 minutes. This second injection was necessary in 42% of our cases.

Amaurosis (inability to perceive an operating light shone directly at the eye) was noted in 22% of our cases. This agrees with the 25% of the reported study. Likewise we attained 100% complete analgesia with near or total akinesia.

The reported study achieved complete ptosis in all cases. We used less anaesthetic and required a Van Lindt block in 12% of cases. The Van Lindt block was used with equal frequency whether one or two peribulbar injections were required.

We found that the inferolateral peribulbar approach provides an effective local anaesthetic for uncomplicated cataract surgery. We concur with the need to warn those patients who are not patched postoperatively that their vision may be impaired for some hours, but that it will recover by the next day.

Our experience and the study show peribulbar anaesthesia affecting optic nerve function that suggests some retrobulbar spread of anaesthetic. In some of our cases amaurosis was noted very soon after the injection. It is possible that an inadvertent retrobulbar injection had been performed. This area is within reach of a 25 mm needle if a subconjunctival approach is used. In the study it is possible that some of the amaurosis achieved was due to such an injection. We will be performing further work employing a 15 mm needle to test this hypothesis.

R A H SCOTT
P A ACHARYA
C M JAKE MAN
S R PERRY
Princess Mary's Royal Air
Force Hospital,
Halton, Aylesbury,
Bucks HP22 5PS

1 Talks SJ, Chong NHV, Gibson JM, Francis IR. Visual acuity and pupillary reactions after peribulbar anaesthesia. *Br J Ophthalmol* 1994; 78: 41–3.

Reply

EDITOR,—Scott *et al* report a similar experience with peribulbar anaesthesia to ours, in that about a quarter of patients developed no perception of light following injection of local anaesthetic solution.¹ Our technique differs however, in that we routinely give two injections, 5 ml in the inferolateral quadrant and 5 ml medial to the caruncle, using a modified method to that described by Hamilton *et al*.² We deliberately give a relatively large volume of local anaesthetic solution because in our experience it works quickly with good analgesia and akinesia, without the need for

further 'top-up' injections. In addition, by angulating the last part of the inferolateral injection laterally and superficially under the conjunctiva, a good facial block is obtained without resort to an injection through the skin, which can be rather painful and associated with bruising in elderly patients.

We have also noticed that some patients report an almost immediate loss of vision following the peribulbar injections, and it is possible as Scott *et al* postulate that the injection has been given intraconally, as an unintentional retrobulbar injection. However we feel that this rapid effect is more likely to be dependent on the volume of local anaesthetic solution mixed with hyaluronidase, rather than the site of placement of the injection. As we mentioned, contrast solution injected around the eye has been shown to diffuse quickly around the optic nerve within 2 minutes of injection.³ Whether a shorter 15 mm needle would work as effectively as the 25 mm needle that is commonly used remains to be seen, but theoretically it may well be safer to use.

J M GIBSON
Birmingham Heartlands Hospital,
Bordesley Green East,
Birmingham B9 5SS

1 Talks SJ, Chong NHV, Gibson JM, Francis IR. Visual acuity and pupillary reactions after peri-

bulbar anaesthesia. *Br J Ophthalmol* 1994; 78: 41–3.

2 Hamilton RC, Gimbel HV, Strunin L. Regional anaesthesia for 12000 cataract extraction and intraocular lens implantation procedures. *Can J Anaesth* 1988; 35: 615–23.

3 Ropo A, Nikki P, Ruusuvaara P, Kivisaari L. Comparison of retrobulbar and periorbital injections of lignocaine by computerised tomography. *Br J Ophthalmol* 1991; 75: 417–20.

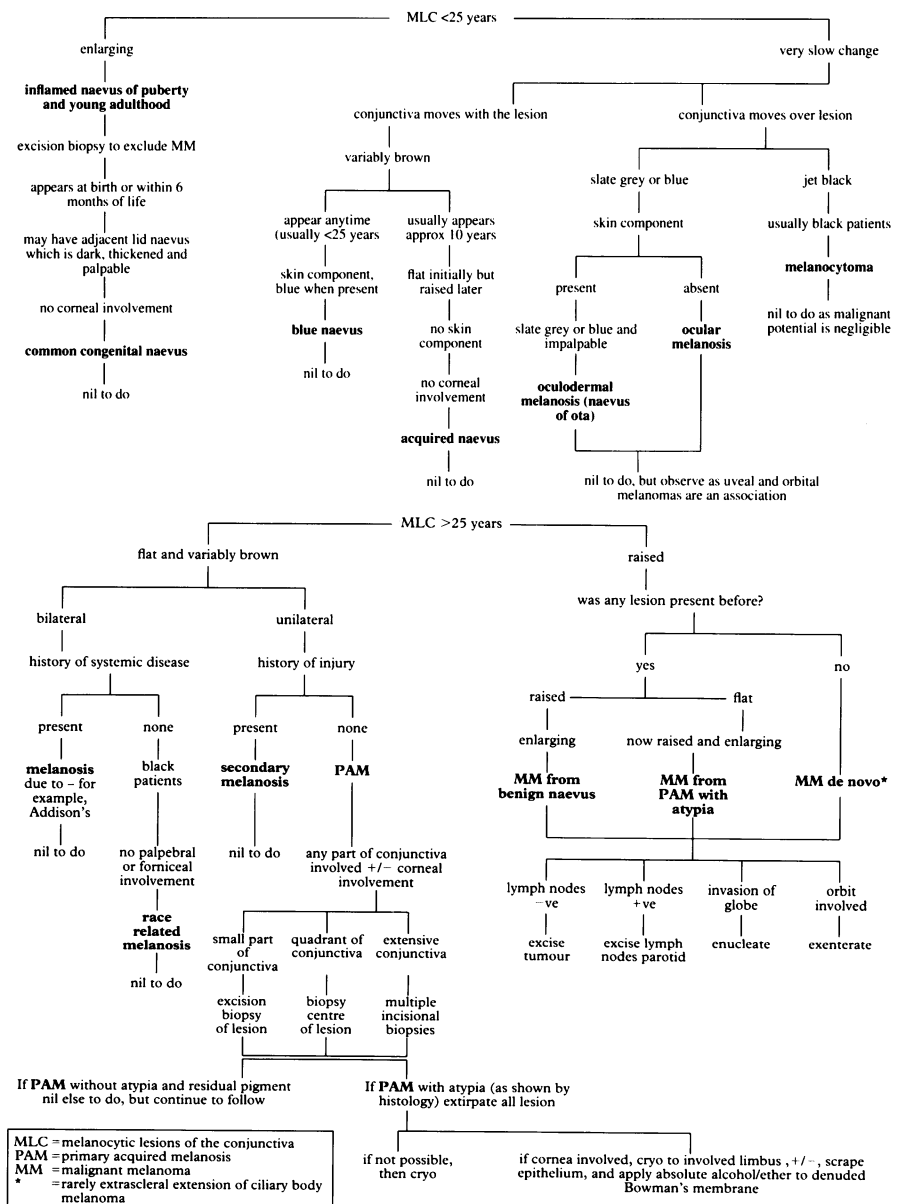
Melanotic lesions of the conjunctiva

EDITOR,—The difficulties in diagnosis and management of melanotic lesions of the conjunctiva (MLC) has led us to develop these algorithms. Non-melanotic lesions are outside their scope. MLC can be divided usefully into those occurring before or after 25 years of age.^{1,2}

I HUSSAIN
K PARTINGTON
R BONSHK
A B TULLO
Manchester Royal Eye Hospital,
Oxford Road,
Manchester M13 9WH

1 Jakobiak FA, Folberg R, Iwamoto T. Clinicopathological characteristics of premalignant and malignant melanotic lesions of the conjunctiva. *Ophthalmology* 1989; 96: 147–66.

2 De Potter P, Shields CL, Shields JA, Menduke H. Clinical predictive factors for development of recurrence and metastasis in conjunctival melanoma: a review of 68 cases. *Br J Ophthalmol* 1993; 77: 624–30.





Melanotic lesions of the conjunctiva

I Hussain, K Partington, R Bonshek, et al.

Br J Ophthalmol 1994 78: 592

doi: 10.1136/bjo.78.7.592-a

Updated information and services can be found at:

<http://bjo.bmj.com/content/78/7/592.2.citation>

References

These include:

Article cited in:

<http://bjo.bmj.com/content/78/7/592.2.citation#related-urls>

Email alerting service

Receive free email alerts when new articles cite this article. Sign up in the box at the top right corner of the online article.

Notes

To request permissions go to:

<http://group.bmj.com/group/rights-licensing/permissions>

To order reprints go to:

<http://journals.bmj.com/cgi/reprintform>

To subscribe to BMJ go to:

<http://group.bmj.com/subscribe/>