

# Effect of lodoxamide and disodium cromoglycate on tear eosinophil cationic protein in vernal keratoconjunctivitis

Andrea Leonardi, Franco Borghesan, Antonio Avarello, Mario Plebani, Antonio G Secchi

## Abstract

**Aim**—To validate the use of tear eosinophil cationic protein (ECP) as a marker for eosinophil activation, and its pharmacological modulation, in addition to evaluating the efficacy of lodoxamide and sodium cromoglycate in the treatment of vernal keratoconjunctivitis (VKC).

**Methods**—Tears were collected from 30 patients affected by active mild to moderate VKC before and after therapy with disodium cromoglycate 4% (DSCG) (n=15) or lodoxamide 0.1% (n=15) for 10 days. Tear cytology and ECP measurement were performed, and ocular signs and symptoms evaluated.

**Results**—While statistically significant changes did not occur after DSCG therapy, mean tear ECP increased from 343 (SD 363) µg/l to 571 (777) µg/l due to marked elevation in six eyes. The clinical score in DSCG eyes did not improve. After lodoxamide therapy, both clinical signs and symptoms, and tear ECP levels (560 (756) µg/l to 241 (376) µg/l) decreased significantly ( $p < 0.0001$  and  $p < 0.01$ , respectively). Compared with DSCG treatment, lodoxamide was more effective in reducing signs and symptoms ( $p < 0.005$ ). ECP levels were significantly correlated with signs, symptoms, corneal involvement, and number of eosinophils in tears ( $p < 0.0001$ ).

**Conclusions**—In patients with VKC, lodoxamide significantly reduced ECP tear levels, and thus, eosinophil activation, and was more effective than DSCG in reducing clinical signs and symptoms.

(*Br J Ophthalmol* 1997;81:23-26)

Vernal keratoconjunctivitis (VKC) is an ocular allergic disease predominantly observed in children and young adults living in warm, southern climates.<sup>1</sup> Specific allergens and non-specific stimuli cause mast cell degranulation and, probably, a lymphocyte mediated response. The high presence of eosinophils in tear fluid and in the conjunctival tissues shows that eosinophils play a major role in the development of this disease.<sup>2</sup>

Eosinophils, when activated by specific and non-specific stimuli, release granule stored, pharmacologically specific proteins, enzymes, and newly formed mediators. Eosinophil cationic protein (ECP) comprises 30% of the eosinophil granule matrix.<sup>3</sup> Its toxic effect on

human corneal epithelial cells has recently been demonstrated in vitro.<sup>4,5</sup> ECP levels in biological fluids correlate with the severity of some allergic diseases and its presence in biological fluids and tissues is now considered a marker for eosinophil activation.<sup>6</sup> We have already reported the usefulness of this marker in monitoring the treatment of VKC and found that ECP levels in tears were strongly correlated to the severity of the disease.<sup>7</sup>

In this study, tear ECP levels were measured in patients with active VKC treated with two mast cell stabilisers, sodium cromoglycate 4% (DSCG) and lodoxamide tromethamine 0.1%. Lodoxamide has been shown clinically to be more effective than DSCG in reducing corneal involvement in VKC, a common complication due to toxic proteins released by eosinophils.<sup>8</sup>

## Materials and methods

Thirty patients who had a previous clinical history of VKC and who were affected by active mild to moderate VKC (mean age 12 (SD 1.1) years; 21 males, nine females) were enrolled in the study. Only patients with a sum clinical score of not less than 3 and not more than 14 for allergic signs and symptoms were included. All patients were free from medication for at least 5 days. After clinical evaluation of ocular signs and symptoms, tear samples were collected using a capillary micropipette for tear cytology and ECP determination. A 5 µl aliquot was used for tear cytology, with the remainder stored at -20°C for subsequent determination of ECP.

Patients were divided in a double masked, randomised fashion into two groups (n=15 per group) to be treated bilaterally four times daily with either DSCG 4% (group 1) or lodoxamide 0.1% (group 2). In both groups, two patients with monolateral VKC were included. Clinical evaluation and tear collection (for tear cytology and ECP measurement) were repeated 10 days after commencement of therapy.

A clinical score (0-4: 0 = absent; 4 = severe) was determined at each visit and for each eye for the four major symptoms: itching, tearing, photophobia, and foreign body sensation, and for the six major signs: conjunctival erythema, conjunctival chemosis, discharge, papillae, (mild hyperaemic scattered papillae = 1+; moderate diffuse hyperaemic swollen papillae = 2+; as before but more severe = 3+; hyperaemic swollen giant papillae covering the superior tarsal plate = 4+), limbal infiltrates (mild

Institute of Clinical Ophthalmology, Department of Physiopathological Optics, University of Padua, Padua, Italy  
A Leonardi  
A Avarello  
A G Secchi

Department of Laboratory Medicine, University of Padua, Padua, Italy  
F Borghesan  
M Plebani

Correspondence to:  
Andrea Leonardi, MD,  
Istituto di Clinica Oculistica,  
Università di Padova, via  
Giustiniani 2, 35128 Padova,  
Italy.

Accepted for publication  
16 September 1996

limbus hyperaemia and swelling =1+; moderate limbus hyperaemia and swelling =2+; as before but more severe = 3+; 360° limbus hyperaemia and swelling=4+), and corneal epithelial disease (fine superficial epithelial defects involving less than half of the cornea = 1+; diffuse fine superficial epithelial defects involving more than half of the cornea = 2+; confluent epithelial defects or mucous plaque formation = 3+; oval corneal ulcers = 4+).

Tear cytology was evaluated using precoloured slides (Testsimplet, Boehringer, Mannheim, Germany), counting the eosinophils present in five microscopic fields of 0.15 mm<sup>2</sup> each.

ECP was measured using a commercially available radioimmunoassay technique (Kabi Pharmacia, Uppsala, Sweden). The results were expressed as micrograms per litre (µg/l).

Statistical analyses of the normally distributed clinical data were performed using the paired Student's *t* test for intratreatment comparisons, and unpaired Student's *t* test for between treatment comparisons. The Wilcoxon sign rank test was used for the laboratory ECP values and for eosinophil number in tears, both not normally distributed data. Results are listed as the mean plus or minus standard deviation of the mean (SD). Correlations were obtained using the Spearman correlation analysis. For statistical significance, the assigned *p* value was  $\geq 0.05$ .

## Results

At baseline, the mean score of individual and total symptoms and signs and the mean tear ECP levels were similar in both groups of patients.

In DSCG treated patients, the mean score of clinical signs and symptoms did not change significantly from baseline. In 12 of the 28 DSCG treated eyes (42%), the mean score of symptoms and signs was unchanged. The mean tear ECP increased from 343 (SD 363) µg/l to 571 (777) µg/l after treatment (Table 1) due to a marked elevation in six of the treated eyes. However, in 17 of the samples (65%), tear ECP levels did show a decrease after treatment. The number of eosinophils in tears was reduced from 18.7 (14.2) to 12.5 (12.7).

In patients treated with lodoxamide, the mean total clinical score of both signs and symptoms decreased significantly ( $p < 0.001$ ) compared with baseline. In only five of 28 treated eyes (15%), the mean score was unchanged. Of the individual signs and symptoms, itching, photophobia, foreign body sensation, tearing, hyperaemia, chemosis, limbal infiltrates, and discharge were all significantly improved ( $p < 0.001$ ). Lodoxamide treatment also significantly reduced tear ECP compared with baseline levels (560 (756) µg/l *v* 241 (376) µg/l;  $p < 0.01$ ) (Table 1), with 83% of samples showing decreased tear ECP after treatment. The number of eosinophils in tears was reduced, but not significantly, from 16.2 (13.7) to 9.6 (10.2).

When comparing the two treatments, lodoxamide was significantly more effective in reducing clinical signs and symptoms

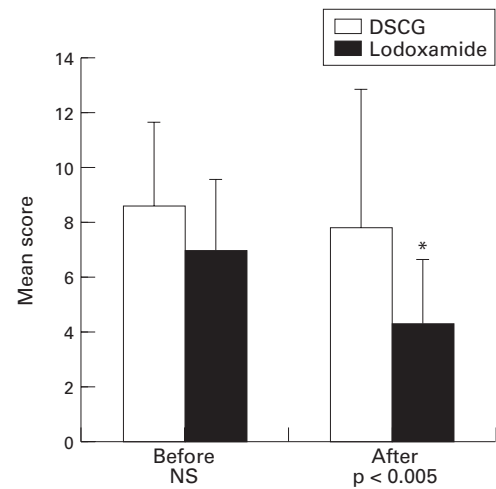


Figure 1 Mean (SD) sum score of the six major ocular clinical signs of vernal keratoconjunctivitis (VKC) (conjunctival erythema, chemosis, discharge, papillae, limbus infiltrates, and epithelial disease) before and after topical, ocular treatment of 30 patients with VKC with either sodium cromoglycate 4% (DSCG) or lodoxamide 0.1%. \*Statistically significantly lower than baseline ocular signs,  $p < 0.005$

( $p < 0.005$ ) than was DSCG (Figs 1 and 2). Lodoxamide was superior to DSCG in the reduction of itching, photophobia, foreign body sensation, tearing, hyperaemia, chemosis, discharge, and corneal epitheliopathy, but not limbal infiltrates and papillae. Tear ECP was lower in patients treated with lodoxamide (241 (376) µg/l) than in those treated with DSCG (571 (777) µg/l). However, a cross group comparison of the values of these two groups did not show a statistically significant difference ( $p < 0.06$ ).

Significant correlations ( $p = 0.0001$ ) were observed between ECP levels in all samples (independent of therapy) and signs, symptoms, corneal involvement, and number of eosinophils in tears.

## Discussion

Vernal keratoconjunctivitis is a chronic inflammatory disorder in which both IgE and cellular mediated mechanisms are recognised as pathogenic factors.<sup>9</sup> The typical histological features of VKC are the conjunctival infiltration of eosinophils and basophils, a constant, increased number of mast cells, and a connective tissue hyperplasia with an increased deposition of collagen.<sup>10 11</sup> An accumulation of Th2-like helper T cells, producing interleukins 3, 4, and 5, has also been shown to occur in VKC,

Table 1 Eosinophil cationic protein (ECP) levels (µg/l) in tears of 30 patients with vernal keratoconjunctivitis before and after topical treatment with disodium cromoglycate (DSCG) or lodoxamide (range (SD))

|                | DSCG                                 | Lodoxamide                          |
|----------------|--------------------------------------|-------------------------------------|
| Before         | 343.8 (363.3)<br>(18–1690)<br>(n=26) | 560.4 (756.7)<br>(6–2360)<br>(n=24) |
| After          | 571.3 (777.1)<br>(6–2387)<br>(n=26)  | 241.4 (376.8)<br>(6–1590)<br>(n=23) |
| <i>p</i> Value | NS                                   | 0.01*                               |

n=Number of eyes with tears available for ECP determination. \*Wilcoxon sign rank test.

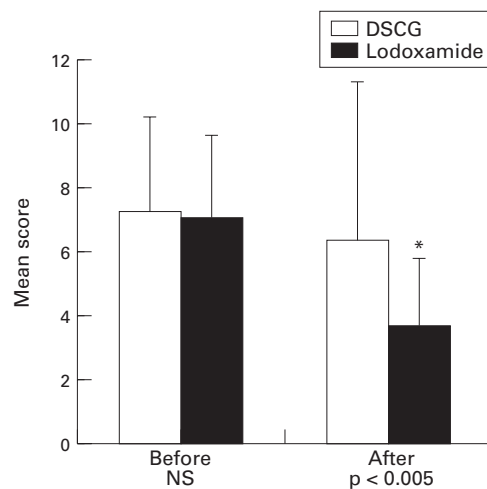


Figure 2 Mean (SD) sum score of the four major ocular clinical symptoms of vernal keratoconjunctivitis (VKC) (itching, tearing, photophobia, and foreign body sensation) before and after topical ocular treatment of 30 patients with VKC with either sodium cromoglycate 4% (DSCG) or lodoxamide 0.1%. \*Statistically significantly lower than baseline ocular symptoms,  $p < 0.005$ .

accounting for the frequent occurrence of high levels of tear immunoglobulin E, mast cell proliferation, and the abundant presence of eosinophils.<sup>12</sup> Activated eosinophils are known to release toxic factors, such as the currently studied ECP, in addition to major basic protein (MBP), eosinophil peroxidase, eosinophil derived neurotoxin/eosinophil protein X (EDN/EPX). Eosinophil MBP has already been shown to play a role in the pathogenesis of epithelial erosions observed in VKC, indicating the importance of eosinophil activation in severe forms of this disease.<sup>13</sup> Conjunctival eosinophil activation and degranulation, accompanied by high levels of tear ECP, was also previously reported in seven patients with VKC<sup>14</sup> and then confirmed by us in a larger group of patients.<sup>7</sup> Higher levels of serum ECP and EPX were also shown, indicating that VKC should be considered a 'systemic' disorder with circulating activated eosinophils.<sup>15</sup> The toxic effect of ECP on corneal epithelial cells has been shown in vitro,<sup>4,5</sup> suggesting a relation between this mediator and VKC related corneal damage and that reduction of eosinophil activation may be an important objective in the treatment of VKC.

In this study, ECP was easily detectable and measurable in tears with a high degree of sensitivity. The wide variation of ECP levels found in baseline tears of VKC patients may have reflected a varying range of activation of eosinophils. Lodoxamide significantly decreased mean tear ECP levels, which reflected reductions in 83% of individual eyes. Mean ECP was increased after DSCG because six of the treated eyes showed a remarkable increase of ECP associated with a worsening in clinical signs and symptoms. However, DSCG did reduce tear ECP in 66% of treated eyes.

Clinical signs and symptoms were significantly decreased only by lodoxamide treatment. The finding that lodoxamide significantly reduced ECP levels but not eosinophil number suggests that this drug is more

effective on eosinophil activation and less on chemotaxis. ECP levels were found to be highly correlated with both signs and symptoms, in addition to corneal involvement and, less strongly, with the number of eosinophils in tears. The correlation between ECP and corneal epitheliopathy substantiates in vitro studies on the epithelial toxicity of ECP.

DSCG has been shown to be effective in the long term management of VKC,<sup>16</sup> but often moderate to severe cases need additional therapy with steroids or the alternative, topical treatment with cyclosporin A.<sup>17</sup>

Lodoxamide is a newly available mast cell stabiliser more active than DSCG in inhibiting the passive cutaneous anaphylaxis and conjunctival allergic reactions in animal models.<sup>18,19</sup> Recently, using the conjunctival provocation test in humans, we reported the efficacy of lodoxamide in reducing histamine release and the development of induced clinical and cytological allergic reactions in animal models.<sup>18,19</sup> Recently, using the conjunctival provocation test in humans, we reported the efficacy of lodoxamide in reducing histamine release and the development of induced clinical and cytological allergic reactions in animal models.<sup>20</sup> In other studies, lodoxamide has been shown to be more effective than DSCG in alleviating signs and symptoms of VKC<sup>21</sup> and to be more effective at decreasing steroid use.<sup>22</sup> Additionally, in a long term study, lodoxamide was shown to decrease corneal epitheliopathy in VKC.<sup>8</sup>

With the present data, lodoxamide was shown to reduce eosinophil activation and the release of toxic proteins. The finding of a parallel decrease in signs and symptoms, which were shown to be correlated with ECP levels, suggests that inhibition of eosinophil activation should be an important part of VKC management. Thus, the measurement of ECP in tears is a new tool for use not only in the monitoring of ocular allergic diseases, but also in the evaluation of topical therapies, for which an objective factor is needed to complement clinical assessments.

- Allansmith MR. *The eye and immunology*. St Louis: CV Mosby, 1982.
- Trocme SD, Aldave AJ. The eye and the eosinophil. *Surv Ophthalmol* 1994;39:241-52.
- Olsson I, Venge P. Cationic proteins of human granulocytes. II. Separation of the cationic proteins of the granules of leukemic myeloid cells. *Blood* 1974;44:235-46.
- Hallberg CK, Brysk MM, Tying SK, Gleich GJ, Trocme SD. Toxic effects of eosinophil cationic protein on cultured human corneal epithelium. *Invest Ophthalmol Vis Sci* 1994;35 (Suppl):1943.
- Ward SL, Gleich GJ, Dimitrijevic SD, Kruszewski FH, Walker TL, Trocme SD. The barrier properties of in vitro human corneal epithelial model are not altered by eosinophil major basic protein or eosinophil cationic protein. *Invest Ophthalmol Vis Sci* 1995;36(Suppl):3217.
- Rak S, Lowhagen O, Venge P. The effect of immunotherapy on bronchial hyper-responsiveness and eosinophil cationic protein in pollen-allergic patients. *J Allergy Clin Immunol* 1988;82:470-80.
- Leonardi A, Borghesan F, Faggian D, Secchi AG, Plebani M. Tear eosinophil cationic protein (ECP) in tears of normal subjects and patients affected by vernal keratoconjunctivitis. *Allergy* 1995;50:610-3.
- Santos CI, Huang AJ, Abelson MB, Foster SC, Friedlander M, McCulley JP. Efficacy of lodoxamide 0.1% ophthalmic solution in resolving corneal epitheliopathy associated with vernal keratoconjunctivitis. *Am J Ophthalmol* 1994;117:488-97.
- Easty DL, Birkenshaw M, Merrett T, Merrett J, Entwistle C, Amer B. Immunological investigations in vernal eye disease. *Trans Ophthalmol Soc UK* 1980;100:98-107.
- Leonardi A, Abatangelo G, Cortivo R, Secchi AG. Collagen type I and III in vernal keratoconjunctivitis. *Br J Ophthalmol* 1995;79:482-5.
- Leonardi A, De Paoli M, Fregona IA, Violato D, Plebani M, Secchi AG. Fibroblast activity and collagen overproduction in VKC. *Invest Ophthalmol Vis Sci* 1995;36(Suppl):3866.
- Maggi E, Biswas P, Del Prete G, Parronchi P, Macchia D, Simonelli C, et al. Accumulation of Th-2-like helper T cells

- in the conjunctiva of patients with vernal conjunctivitis. *J Immunol* 1991;**146**:1169-74.
- 13 Trocme SD, Kephart GM, Burne WM, Buckley RJ, Gleich GJ. Eosinophil granule major basic protein deposition in corneal ulcers associated with vernal keratoconjunctivitis. *Am J Ophthalmol* 1993;**115**:640-3.
  - 14 Saiga T, Ueno N, Shimizu Y. Deposition of eosinophil cationic protein in conjunctival tissues and tears in vernal keratoconjunctivitis. *Invest Ophthalmol Vis Sci* 1991;**32**(Suppl):682.
  - 15 Tomassini M, Magrini L, Bonini S, Lambiase A, Bonini S. Increased serum levels of eosinophil cationic protein and eosinophil-derived neurotoxin (protein X) in vernal keratoconjunctivitis. *Ophthalmology* 1994;**101**:1808-11.
  - 16 Secchi AG, Tognon MS, Leonardi A. Topical use of cyclosporine in the treatment of vernal keratoconjunctivitis. *Am J Ophthalmol* 1990;**110**:137-42.
  - 17 Foster CS, Duncan J. Randomized clinical trial of topically administered cromolyn sodium for vernal keratoconjunctivitis. *Am J Ophthalmol* 1980;**90**:175-81.
  - 18 Nyberg M, Sugar J, Fiscella R. Effect of lodoxamide on immediate hypersensitivity in the guinea pig conjunctiva. *Invest Ophthalmol Vis Sci* 1984;**25**(Suppl):27.
  - 19 Aoki KR, Jones MM, Robertson SM, DeSantis L. Topical anti-allergic activity of lodoxamide against a passive anaphylaxis reaction in the rat conjunctiva. *Invest Ophthalmol Vis Sci* 1985;**26**(Suppl):190.
  - 20 Leonardi A, Fregona IA, Smith LM, Salmaso M, Secchi AG. Lodoxamide prevents histamine release and clinical EPR and LPR induced by conjunctival provocation. *Eur J Ophthalmol* 1996;**6**:106-12.
  - 21 Caldwell DR, Verin P, Hartwich-Young R, Meyer SM, Drake MM. Efficacy and safety of lodoxamide 0.1% vs cromolyn sodium 4% in patients with vernal keratoconjunctivitis. *Am J Ophthalmol* 1992;**113**:632-7.
  - 22 Fahy G, Easty DL, Collum L, Lumbroso P, Ober M, Verin P, et al. Double-masked efficacy and safety evaluation of lodoxamide 0.1% ophthalmic solution versus Opticrom 2%—a multicentre study. In: Ferraz de Oliveira LN, ed. *Ophthalmology today* 1988:341-2.



## Effect of Iodoxamide and disodium cromoglycate on tear eosinophil cationic protein in vernal keratoconjunctivitis

Andrea Leonardi, Franco Borghesan, Antonio Avarello, et al.

*Br J Ophthalmol* 1997 81: 23-26

doi: 10.1136/bjo.81.1.23

---

Updated information and services can be found at:

<http://bjo.bmj.com/content/81/1/23.full.html>

---

*These include:*

### References

This article cites 20 articles, 3 of which can be accessed free at:

<http://bjo.bmj.com/content/81/1/23.full.html#ref-list-1>

Article cited in:

<http://bjo.bmj.com/content/81/1/23.full.html#related-urls>

### Email alerting service

Receive free email alerts when new articles cite this article. Sign up in the box at the top right corner of the online article.

---

### Topic Collections

Articles on similar topics can be found in the following collections

[Conjunctiva](#) (170 articles)

[Cornea](#) (380 articles)

[Ocular surface](#) (452 articles)

---

### Notes

---

To request permissions go to:

<http://group.bmj.com/group/rights-licensing/permissions>

To order reprints go to:

<http://journals.bmj.com/cgi/reprintform>

To subscribe to BMJ go to:

<http://group.bmj.com/subscribe/>