

## ORIGINAL ARTICLES—Clinical science

## Presumed ocular histoplasmosis in the Netherlands—an area without histoplasmosis

Maria S A Suttorp-Schulten, Jan G Bollemeijer, Pierre J M Bos, Aniki Rothova

### Abstract

**Aims/background**—The syndrome of ocular histoplasmosis is usually prefaced by 'presumed' as the aetiology is not yet clear. The aim of this study was to evaluate the clinical features of a similar ocular syndrome in the Netherlands where the fungus *Histoplasma capsulatum* is not endemic.

**Methods**—A retrospective multicentre study in which all patients were included who were diagnosed with a syndrome similar to presumed ocular histoplasmosis and in whom both fluorescein angiogram and all complete patient data were available. Fluorescein angiograms were examined by three authors in a masked fashion. Eighty one patients were selected who fulfilled the ophthalmic criteria for presumed ocular histoplasmosis. Fifty one patients showed the classic clinical picture, while 30 patients had an incomplete form as they did not show numerous histospots.

**Results**—No major difference in clinical characteristics could be identified when comparing the group of patients with the classic syndrome with the one with the incomplete syndrome. Final visual outcome of patients with macular subretinal neovascularisation after laser treatment was better when compared with untreated patients ( $p < 0.01$ ).

**Conclusions**—Since the fungus *Histoplasma capsulatum* is absent in the Netherlands, other aetiological agents must have led to this clinical entity similar to the presumed ocular histoplasmosis syndrome seen in the USA.

(*Br J Ophthalmol* 1997;81:7-11)

The presumed ocular histoplasmosis syndrome is a clinical entity consisting of a maculopathy which may either be a disciform lesion caused by neovascularisation or atrophy, peripapillary atrophy, and multiple choroidal spots (called histospots), combined with the presence of a clear vitreous. The disease occurs predominantly in young adults.<sup>1</sup> Linear streaks are described in 5% of the cases.<sup>2-4</sup>

The first patient ever described with this syndrome suffered from systemic histoplasmosis, which suggested that the fungus *Histoplasma*

*capsulatum* plays a causative role.<sup>5</sup> *H capsulatum* is endemic in subtropical regions, such as the middle west of the USA and usually causes a benign influenza-like infection.<sup>6</sup> Epidemiological data support the causative role of *H capsulatum* in this ocular syndrome.<sup>7-13</sup> The presence of histoplasmosis in the eye has been studied from necropsy material of patients suffering from generalised histoplasmosis, but only one of these patients showed the characteristic ocular symptoms of presumed ocular histoplasmosis as described above.<sup>14-19</sup> One isolated case of endophthalmitis after cataract extraction caused by *H capsulatum* has been described.<sup>20</sup>

The causative role of the fungus in this ocular disease is also supported by animal studies in non-human primates which have shown that a chorioretinitis can be caused by injecting *H capsulatum* into the carotid artery. Nevertheless, the lesions caused in this model are not the same as those seen in the clinical setting and the fungus could not be found on histological examination.<sup>21-26</sup>

*H capsulatum* may not be the exclusive causative agent as macular disease caused by presumed ocular histoplasmosis has been associated with HLA B7 and HLA-DR-W2, which suggests a genetic predisposition.<sup>27-31</sup> In the north western part of Europe *H capsulatum* is virtually absent and the generalised infection is only seen in patients who visited endemic areas.<sup>6</sup> An ocular syndrome similar to presumed ocular histoplasmosis has been noted earlier in western Europe in previous studies with small groups of nine, five, 15 and five patients.<sup>32-35</sup>

The aim of this study was to evaluate the clinical features and outcome of a syndrome similar to presumed ocular histoplasmosis in the Netherlands where the fungus *H capsulatum* is not endemic. We performed a retrospective study of 81 patients diagnosed with a syndrome similar to presumed ocular histoplasmosis.

### Patients and methods

In this study, patients were included who had been diagnosed in the ophthalmological departments of the university hospitals of Utrecht, Leiden, and Amsterdam with presumed ocular histoplasmosis and in whom fluorescein angiograms and all complete patient data were available.

Netherlands  
Ophthalmic Research  
Institute, Amsterdam,  
the Netherlands  
M S A Suttorp-Schulten  
A Rothova

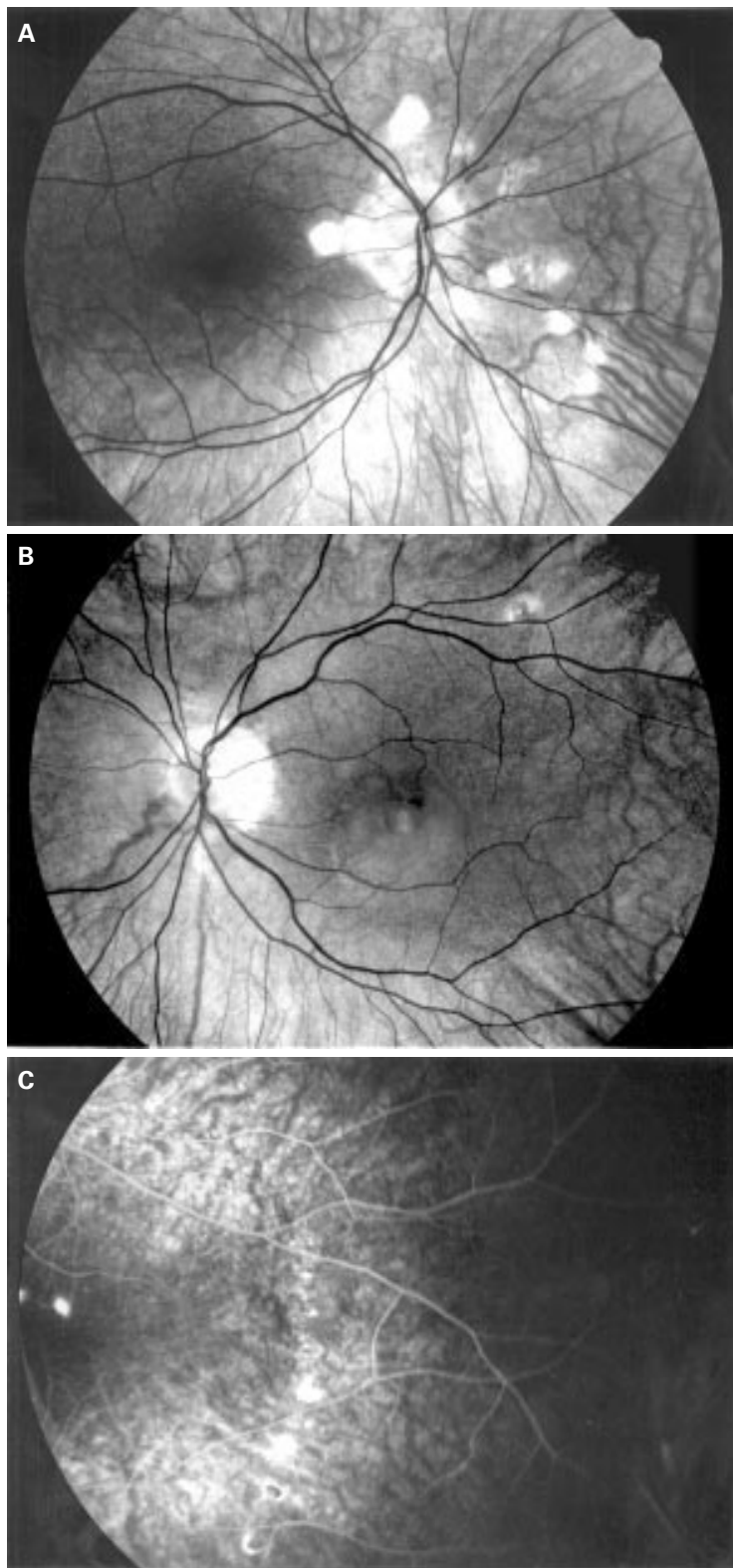
Department of  
Ophthalmology,  
Academic Hospital  
Leiden, the  
Netherlands  
J G Bollemeijer

Department of  
Ophthalmology,  
Academic Medical  
Centre Amsterdam,  
the Netherlands  
P J M Bos

F C Donders Institute  
for Ophthalmology,  
Academic Hospital  
Utrecht, the  
Netherlands  
A Rothova

Correspondence to:  
M S A Suttorp-Schulten,  
MD, Netherlands  
Ophthalmic Research  
Institute, PO Box 12141,  
1100 AC Amsterdam, the  
Netherlands.

Accepted for publication  
1 August 1996



**Figure 1** (A) Right eye, peripapillary atrophy, peripapillary histospots, mid peripheral atrophic chorioretinal scars. (B) Left eye with peripapillary atrophy and disciform macular lesion (same patient as (A)). (C) Left eye, peripheral linear streak.

All patients had to exhibit a macular disciform lesion caused by neovascularisation, peripapillary atrophy, and a clear vitreous. According to whether atrophic peripheral chorioretinal scars were present, patients were

retrospectively divided into two groups according to clinical features at presentation (Fig 1).

The group with the syndrome similar to the classic presumed ocular histoplasmosis syndrome (group I) included patients who fulfilled all three criteria of macular disciform lesions, peripapillary atrophy, and more than two atrophic peripheral chorioretinal scars (see Fig 1). The group with incomplete presumed ocular histoplasmosis syndrome (group II) included patients who did show macular disciform lesions and peripapillary atrophy, but no or fewer than two histospots.

To become acquainted with the presentation of the disease in the mid west of the USA, one of us (MSS) visited the Department of Ophthalmology of Barnes Hospital, Washington University, St Louis, Missouri and reviewed a large number of patient records and photographs of patients with presumed ocular histoplasmosis seen earlier by Dr Kaplan and his coworkers.

All fluorescein angiograms were reviewed by three authors (AR, MS, JB), who at that time were not aware of the patients' medical histories. Patients were then divided in two groups according to the classification described above if all three agreed.

If information on histoplasma skin testing was available this was recorded.

Exclusion criteria were older than 50 years, age related macular degeneration, and associated syndromes—for example, retinal pigment epithelium changes and drusen, or associated macular myopic degeneration. The diagnosis of subretinal idiopathic neovascularisation cannot be excluded in occasional patients of the incomplete syndrome. If patients developed vitreous cells, they were excluded from this study and the clinical diagnosis was changed to multifocal choroiditis (Fig 2).

Data were analysed by the Student's *t* test and Fisher's exact probability test whenever appropriate.

## Results

The group with the classic syndrome (group I) consisted of 51 patients, 40 women and 11 men, aged 17 to 47 years, with an average age of 29 years. At presentation, all patients had a macular disciform lesion, three were bilateral with an old disciform lesion in one eye and a newly formed lesion in the other eye. Histoplasmin sensitivity testing was available in six cases and all were negative. Linear streaks were noted in eight patients (16%). Peripapillary atrophy was seen in all 51 patients, 29 of them bilateral (41%). In 20 patients, the peripapillary atrophy was circumferential; in 16 cases, it was more than half of the circumference; and in 15 cases it was less than half of the circumference. Thirty seven of the 51 patients had myopia of 1 dioptre or more (73%). The best corrected visual acuity at presentation of the affected eye is shown in Table 1; 21 patients (42%) had a visual acuity of 20/200 or less, 14 patients (27%) better than 20/200 and less than 20/40; and 16 patients (31%) had a visual acuity of 20/40 or better.

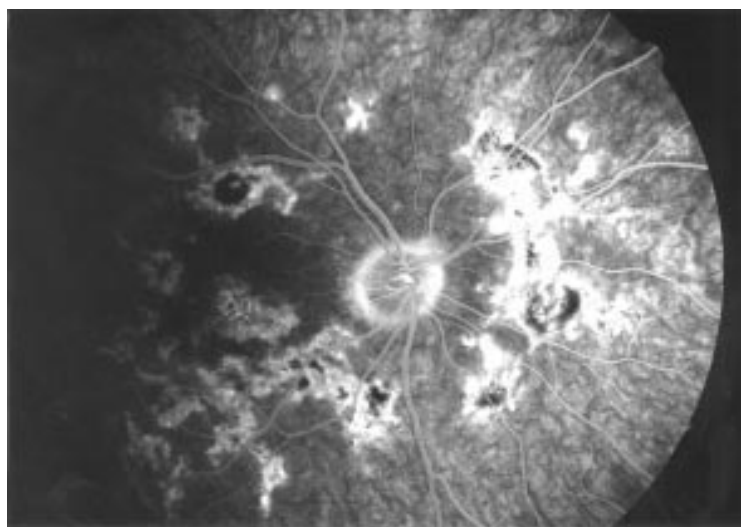


Figure 2 Right eye of a patient who developed multifocal choroiditis.

The group with incomplete syndrome (group II) consisted of 30 patients, 20 women and 10 men, aged 11 to 50 years, with an average age of 30 years. At presentation, all patients had a disciform macular lesion, one was bilateral with an old lesion in one eye and a newly formed lesion in the other eye. Histoplasmin skin testing was performed in one case and was negative. None of the patients showed more than two atrophic peripheral chorioretinal scars; 25 patients (83%) showed no histospots at all. All patients had peripapillary atrophy, which was bilateral in 18 cases (60%). In seven patients this peripapillary atrophy was circumferential; in six patients it was more than half of the circumference; and in 17 cases it was less than half of the circumference. Twenty one of these patients (70%) had myopia of 1 dioptre or more. At presentation the best corrected visual acuity in the affected eye is shown in Table 1, 14 patients (47%) had a visual acuity of 20/200 or less, six patients (20%) had a visual acuity between

20/200 and less than 20/40, and 10 patients (33%) had a visual acuity of 20/40 or better (Table 1).

In the whole series, long term follow up was available for 69 patients, as shown in Table 2.

In the group with the classic syndrome (group I) 47 patients were followed with a mean follow up of 74 months. The mean of the best corrected visual acuity of these eyes affected, measured at first presentation and at last visit, was 20/40. Twenty three patients (49%) in this group retained a visual acuity of 20/40 or better in the eye affected. Bilateral visual deterioration was encountered in nine patients. Three of these showed bilateral macular involvement at the first visit. At that time the lesions developed they were 27, 41, and 33 years old. In two patients macular involvement developed within 1 year. At the time the lesions developed they were 26 and 30 years old. In four patients the lesions developed after 4, 5, 6, and 12 years respectively, when the lesions developed the patients were 33, 30, 33, and 37 years old. Three patients (7%) out of the group of 41 patients with the classic syndrome developed the clinical picture of multifocal choroiditis 6 months, 1 year, and 2 years after the onset of the initial symptoms (see Fig 2).

In the group with the incomplete syndrome (group II), 22 patients were followed with an average of 37 months. The mean of best corrected visual acuity of the eyes affected, measured at first presentation and at the last visit, was 20/40. Twelve patients in this group (55%) could retain a visual acuity of 20/40 or more in the affected eye (Table 2). Three patients showed bilateral macular involvement, one at the time of presentation (at that time aged 32 years) and two patients 5 years after presentation (at that time aged 37 and 30 years).

There was no major difference between the two groups when comparing age of onset, sex ratio, visual acuity at presentation, and bilateral macular involvement. No difference was found

Table 1 Clinical characteristics of 81 patients at presentation

	Group I classic syndrome No (%)	Group II incomplete syndrome No (%)
Number of patients	51 (100)	30 (100)
Male/female ratio	11/40 (22/78)	10/20 (33/66)
Myopia more than 1 dioptre	37 (73)	21 (70)
Visual acuity of affected eye at presentation		
≤20/200	21 (42)	14 (47)
<20/40	14 (27)	6 (20)
≥20/40	16 (31)	10 (33)
Average age (years) (range)	29 (17–40)	30 (11–50)
Linear streaks	8 (16%)	None

Table 2 Clinical characteristics of 69 affected eyes at follow up

	Group I classic syndrome No (%)	Group II incomplete syndrome No (%)
Number of eyes	47 (100)	22 (100)
Mean follow up (months)	74 (2–264)	37 (1–228)
Bilateral macular involvement	9 patients (18%), 3 at presentation, 6 at follow up	3 patients (10%), 1 at presentation, 2 at follow up
Visual acuity		
≤20/200	11 (23)	6 (27)
≤20/40	13 (28)	4 (18)
≤20/40	23 (49)	12 (55)

Table 3 Visual acuity and duration of follow up

	24 Months or less No (%)	More than 24 months No (%)
Mean follow up (months) (range)	12 (1–24)	200 (25–264)
Number of eyes	29	40
Visual acuity		
≤20/200	7 (24)	10 (25)
<20/40	8 (28)	9 (22.5)
≥20/40	14 (48)	21 (52.5)

Table 4 Visual acuity at follow up and laser treatment

	Not treated by laser No (%)	Treated by laser No (%)
Number of eyes	36	33
Mean follow up (months) (range)	68 (2–228)	57 (1–264)
Mean visual acuity	20/80	20/30
Visual acuity		
≤20/200	13 (36)*	4 (12)*
<20/40	8 (22)	9 (27)
≥20/40	15 (42)	20 (61)

\*p= 0.02.

when comparing the final visual acuity of patients in group I and group II ( $p>0.1$ ; Table 2).

Twenty nine patients were followed for 2 years or less, the mean follow up was 12 months. The mean visual acuity in these patients was 20/40. Forty patients were followed for more than 2 years with a mean follow up of 100 months. The mean visual acuity in this group was 20/40. There was no significant difference when comparing the final visual acuity between the patients with short and long term follow up ( $p>0.5$ ; Table 3). Twelve patients (17%) out of 69 who were followed had bilateral involvement at follow up combined with a bilateral visual acuity of 20/200 or less.

Of the total group of 69 patients with available follow up 36 patients received no laser photocoagulation of the subretinal neovascularisation, as the localisation and/or the extent of the lesion made this treatment impossible. The mean visual acuity in these patients was 20/80 at last follow up with a mean follow up of 68 months. Thirty three patients received laser photocoagulation of the subretinal neovascularisation. The mean visual acuity of these treated patients was 20/30 at last follow up, with a mean follow up of 57 months (Table 4). When comparing the final visual outcome in the group treated by laser photocoagulation with the group not treated, the treated group had a much better outcome ( $p<0.01$ ); only four of 33 patients (12%) experienced serious visual deterioration ( $\leq 20/200$ ) compared with 13 patients of 36 (36%) in the non-treated group (Table 4).

### Discussion

The syndrome described here demonstrates an ophthalmic feature similar to that seen in patients suffering from presumed ocular histoplasmosis in the USA. We report 81 patients who fulfilled the clinical criteria for presumed ocular histoplasmosis, including 51 patients exhibiting the classic clinical picture which was identical to the entity as described in the USA. Thirty patients had an incomplete form, as

they did not show numerous histospots. Nevertheless, there are some differences in clinical features when comparing our patients with those described in the USA.

Our patients do not come from an area endemic for histoplasmosis, which is usually the case for diagnosis in the USA.<sup>1,36</sup> In seven patients, the results of histoplasmin skin testing were available, and it was negative in all patients. Diagnosis by histoplasmin skin testing has been abandoned since it was suggested that there was a possibility of flare up of maculopathy in 7%.<sup>37</sup> There is a predominance of females in our group, which is not encountered in the USA.<sup>3</sup> The average age of onset is 30 years, compared with 40 years in American patients, a difference that does not seem significant.<sup>3</sup> When comparing the incomplete with the classic form in our study, both groups showed a very high incidence of moderate myopia (70%), compared with the 14% in the normal population.<sup>38</sup> Patients with fundus changes due to myopic degeneration were excluded from the study. The high incidence of myopia found in our patients is not systematically mentioned in descriptions of American patient groups.<sup>1,36</sup> Linear streaks were observed in 16% of our patients with the classic syndrome, compared with 5% in American patients.<sup>2</sup>

The visual prognosis at follow up was alike in both groups. Visual acuity was alike in patients followed for 24 months compared with patients followed for a longer period, suggesting that no major changes in visual acuity occur once the first years have passed. Involvement of the second eye was not seen after the age of 41 and occurred in 20% of our patients, which is similar to the 9–22% described in the USA.<sup>39,40</sup> In our series, 17% of the patients were legally blind at follow up, compared with 5% in a recent large American study.<sup>40</sup> Of the eyes not treated, 42% had a final visual acuity of 20/40 or more, which seems to be better than 14% and 19% in the US series.<sup>41,42</sup> The prognosis for eyes that received laser treatment was similar to the results reported from the USA; in our patients 61% of these eyes obtained a visual acuity of 20/40 or better compared with 71%.<sup>43</sup>

Taking into consideration the similarity of the two patient groups, we assume that it is probably one single clinical entity that presents in two forms: a classic form with numerous histospots or in an incomplete form without numerous histospots. In our opinion this entity represents a spectrum that extends from idiopathic neovascular membrane, through a combination of this with few or numerous choroidal lesions up to the diffuse picture of multifocal choroiditis.

In conclusion, our findings show that the clinical spectrum of the disease seen in Europe is similar to that seen in the USA in terms of visual outcome, involvement of the second eye, and response to laser photocoagulation. Earlier European authors have described isolated cases of individuals with what appeared to be the presumed ocular histoplasmosis syndrome and commented that *Histoplasma capsulatum* is not present in north western Europe.<sup>32–35</sup> In this

series we suggest that this syndrome might exist on a larger scale in the non-endemic region of north western Europe than previously thought. As *H capsulatum* cannot play a role in our patients, other aetiological factors must be considered. Other infectious agents, unknown until now, might play a causative role. HLA association and genetic factors must be investigated further. Autoimmune disease is not very probable as no patients showed systemic disease, but this cannot be excluded, especially because of the predominance of females in our group. Future laboratory investigation in American and European patients will be necessary to clarify the aetiology of this syndrome.

We thank H Kaplan, MD, St Louis, for the opportunity to visit his department.

- 1 Nussenblatt RB, Palestine AG. *Uveitis: fundamentals and practice*. Chicago: Yearbook Medical Publishers, 1989: 379–87.
- 2 Fountain JA, Schlaegel Jr TF. Linear streaks of the equator in the presumed ocular histoplasmosis syndrome. *Arch Ophthalmol* 1981;**99**:246–8.
- 3 Gass JDM, Wilkinson CP. Follow-up study of presumed ocular histoplasmosis. *Trans Am Acad Ophthalmol Otolaryngol* 1972;**76**:672–94.
- 4 Maumenee AE. Clinical entities in 'uveitis': an approach to the study of intraocular inflammation. XXVI Edward Jackson Memorial Lecture. *Am J Ophthalmol* 1970;**69**:1–27.
- 5 Reid JD, Sherer JH, Herbut PA, Irving H. Systemic histoplasmosis diagnosed before death and produced experimentally in guinea pigs. *J Lab Clin Med* 1942;**27**:419–34.
- 6 Edwards PQ. Histoplasmin sensitivity patterns around the world. In: Ajello L, Chick EW, Furcolow L, eds. *Histoplasmosis. Proceedings of the Second National Conference*. Springfield, IL: CC Thomas, 1971:97–102.
- 7 Woods AC, Wahlen HC. The probable role of benign histoplasmosis in the etiology of granulomatous uveitis. *Am J Ophthalmol* 1960;**49**:205–20.
- 8 Walma Jr D, Schlaegel Jr TF. Presumed histoplasmic choroiditis. *Am J Ophthalmol* 1964;**57**:107–10.
- 9 Smith RE, Ganley JP. An epidemiological study of presumed ocular histoplasmosis. *Trans Am Acad Ophthalmol Otolaryngol* 1971;**75**:994–1005.
- 10 van Metre TE, Maumenee AE. Specific ocular uveal lesions in patients with evidence of histoplasmosis. *Arch Ophthalmol* 1964;**71**:314–24.
- 11 Ganley JP, Smith RE, Knox DL, Comstock GW. Presumed ocular histoplasmosis III. Epidemiologic characteristics of people with peripheral atrophic scars. *Arch Ophthalmol* 1973;**89**:116–9.
- 12 Ellis FD, Schlaegel TF. The geographic localization of presumed histoplasmic choroiditis. *Am J Ophthalmol* 1973;**75**:953–6.
- 13 Ganley JP. Epidemiology of presumed ocular histoplasmosis. *Arch Ophthalmol* 1984;**102**:1754–6.
- 14 Hoefnagels KLJ, Pijpers PM. Histoplasma capsulatum in a human eye. *Am J Ophthalmol* 1967;**63**:715–23.
- 15 Scholz RW, Green WR, Kutys R, Sutherland J, Richards RD. Histoplasma capsulatum in the eye. *Ophthalmology* 1984;**91**:1100–4.
- 16 Specht CS, Mitchell KT, Bauman AE, Gupta M. Ocular histoplasmosis with retinitis in a patient with acquired immune deficiency syndrome. *Ophthalmology* 1991;**98**:1356–9.
- 17 Khalil MK. Histopathology of presumed ocular histoplasmosis. *Am J Ophthalmol* 1982;**94**:369–76.
- 18 Goldstein BG, Buettner H. Histoplasmic endophthalmitis, a clinicopathologic correlation. *Arch Ophthalmol* 1983;**101**:774–7.
- 19 Feman SS, Pritchett P, Johns K, Westrich DJ, Salmon WD. Intraocular tumor from disseminated histoplasmosis. *South Med J* 1982;**84**:780–1.
- 20 Pulido JS, Folberg R, Carter KD, Coonan P. Histoplasmosis capsulatum endophthalmitis after cataract extraction. *Ophthalmology* 1990;**97**:217–20.
- 21 Day R. Experimental ocular histoplasmosis. *Am J Ophthalmol* 1949;**32**:1317–31.
- 22 Jester JV, Smith RE. Subretinal neovascularization after experimental ocular histoplasmosis in a subhuman primate. *Am J Ophthalmol* 1985;**100**:252–8.
- 23 Smith RE, Dunn S, Jester JV. Natural history of experimental histoplasmic choroiditis in the primate. I. Clinical features. *Invest Ophthalmol Vis Sci* 1984;**25**:801–9.
- 24 Smith RE, Dunn S, Jester JV. Natural history of experimental histoplasmic choroiditis in the primate. II. Histopathologic features. *Invest Ophthalmol Vis Sci* 1984;**25**:810–9.
- 25 Palvolgyi I, Anderson A, Rife L, Taylor C, Smith RE. Immunopathology of reactivation experimental ocular histoplasmosis. *Exp Eye Res* 1993;**57**:169–75.
- 26 Anderson A, Clifford W, Palvolgyi I, Rife L, Taylor C, Smith RE. Immunopathology of chronic experimental histoplasmic choroiditis in the primate. *Invest Ophthalmol Vis Sci* 1992;**33**:1637–41.
- 27 Braley RE, Meredith TA, Aaberg TH, Koethe SM, Witkowski JA. The prevalence of HLA-B7 in presumed ocular histoplasmosis. *Am J Ophthalmol* 1978;**85**:859–61.
- 28 Godfrey WA, Sabates R, Cross DE. Association of presumed ocular histoplasmosis with HLA-B7. *Am J Ophthalmol* 1978;**85**:854–8.
- 29 Meredith TA, Smith RE, Duquesnoy RJ. Association of HLA DRw2 antigens with presumed ocular histoplasmosis. *Am J Ophthalmol* 1980;**89**:70–6.
- 30 Meredith TA, Smith RE, Brakey RE, Witkowski JA, Koethe SM. The prevalence of HLA B7 in presumed ocular histoplasmosis in patients with peripheral atrophic scars. *Am J Ophthalmol* 1978;**86**:325–8.
- 31 Spaide RF, Skerry JE, Yannuzzi LA, De Rosa JT. Lack of HLA DR2 specificity in multifocal choroiditis and panuveitis. *Br J Ophthalmol* 1990;**74**:536–7.
- 32 Saraux H, Pelose B, Guigi A. Choroidite multifocale interne: pseudohistoplasmosse. Forme europeenne de l'histoplasmosse presumee americaine. *J Fr Ophtalmol* 1986;**9**:645–51.
- 33 Bottoni FG, Deutman AF, Aandekerke AL. Presumed ocular histoplasmosis syndrome and linear streak lesions. *Br J Ophthalmol* 1989;**74**:528–32.
- 34 Braunstein RA, Rosen DA, Bird AC. Ocular histoplasmosis syndrome in the United Kingdom. *Br J Ophthalmol* 1974;**58**:893–8.
- 35 Flage T, Bratberg A, Syrdalen P. Haemorrhagic maculopathy in young adults. *Acta Ophthalmol* 1977;**55**:489–96.
- 36 Weiter JJ, Roh S. Presumed ocular histoplasmosis. In: Albert DM, Jakobiec A, eds. *Principles and practice of ophthalmology: clinical practice*. Vol 6, Philadelphia: WB Saunders, 1994:488–95.
- 37 Schlaegel TF. Presumed ocular histoplasmosis. In: Tasman W, Jaeger EA, eds. *Duane's clinical ophthalmology*. Philadelphia: Lippincott, 1990: vol 3, chapter 48.
- 38 Duke Elder S, Abrams D. *System of ophthalmology*. London: Kimpton, 1970; Vol V:234–9.
- 39 Lewis ML, Schiffman JC. Long term follow up of the second eye in ocular histoplasmosis. *Int Ophthalmol Clin* 1983;**23**:125–35.
- 40 Macula Photocoagulation Study Group. Five year follow-up of fellow eyes of individuals with ocular histoplasmosis and unilateral extrafoveal or juxtafoveal choroidal neovascularization. *Arch Ophthalmol* 1996;**114**:677–88.
- 41 Kleiner RC, Ratner CM, Enger C, Fine SL. Subfoveal neovascularization in the ocular histoplasmosis syndrome. A natural history study. *Retina* 1988;**8**:225–9.
- 42 Olk JR, Burgess DB, McCormick PA. Subfoveal and juxtafoveal subretinal neovascularization in the presumed ocular histoplasmosis syndrome. *Ophthalmology* 1984;**91**:1592–602.
- 43 Cummings HL, Rehmer AJ, Wood WJ, Isernhagen RD. Long-term results of laser treatment in the ocular histoplasmosis syndrome. *Arch Ophthalmol* 1995;**113**:465–8.



## Presumed ocular histoplasmosis in the Netherlands —an area without histoplasmosis

Maria S A Suttorp-Schulten, Jan G Bollemeijer, Pierre J M Bos, et al.

*Br J Ophthalmol* 1997 81: 7-11

doi: 10.1136/bjo.81.1.7

---

Updated information and services can be found at:

<http://bjo.bmj.com/content/81/1/7.full.html>

---

### References

*These include:*

This article cites 34 articles, 12 of which can be accessed free at:

<http://bjo.bmj.com/content/81/1/7.full.html#ref-list-1>

Article cited in:

<http://bjo.bmj.com/content/81/1/7.full.html#related-urls>

### Email alerting service

Receive free email alerts when new articles cite this article. Sign up in the box at the top right corner of the online article.

---

### Notes

---

To request permissions go to:

<http://group.bmj.com/group/rights-licensing/permissions>

To order reprints go to:

<http://journals.bmj.com/cgi/reprintform>

To subscribe to BMJ go to:

<http://group.bmj.com/subscribe/>