

Adenoid squamous carcinoma of the conjunctiva—a clinicopathological study of 14 cases

Joseph A Mauriello Jr, Ahmed Abdelsalam, Ian W McLean

Abstract

Aims—In order to determine the clinicopathological features and optimum management of a series of patients with adenoid squamous cell carcinoma of the conjunctiva, all cases of squamous cell carcinoma (SCC) of the conjunctiva and cornea on file in the registry of the ophthalmic pathology at the Armed Forces Institute of Pathology were reviewed.

Methods—On histopathological examination, a predominant adenoid or pseudoglandular pattern due to islands of neoplastic squamous or epidermoid cells surrounded by acantholytic cells was necessary for inclusion in the study. Histochemical and transmission electron microscopic studies (TEM) were performed. Clinical features of all the patients were extracted from the charts.

Results—The anatomical location of the 14 tumours was corneoscleral limbus (seven patients) and bulbar conjunctiva (seven patients). Eight patients presented with inflammatory signs and irritation (red eye, tearing, foreign body sensation), while six patients developed a slowly growing, painless mass. Histochemical and TEM studies showed extracellular hyaluronic acid and no intracellular mucin. Of the two patients initially treated by enucleation, one was free of disease after 2 years while the second patient had recurrence in the socket and died of brain metastases despite wide orbital excision and radiotherapy. All five patients with recurrent tumours initially had irritated red eyes and two required enucleation. One such patient, after orbital exenteration and radiotherapy, died of unrelated disease.

Conclusion—The study demonstrates that adenoid SCC of the conjunctiva often presents with inflammatory signs. The tumour is locally aggressive and may metastasise and should, therefore, be histopathologically differentiated from the less aggressive conventional squamous cell carcinoma. Optimum treatment includes wide excision with documented histological clear margins of resection on permanent sections and frequent follow up.

(*Br J Ophthalmol* 1997;81:1001-1005)

Adenoid squamous cell carcinoma (adenoid acanthoma) is a histopathological variant of squamous cell carcinoma (SCC) that has been described in the skin of the head, the oral cavity, lung, and neck and the cervix of the uterus but not in the conjunctiva.¹⁻¹⁶ It has a characteristic pseudoglandular appearance due to acantholysis of the neoplastic squamous cells.

Adenoid SCC of the skin occurs in sun exposed areas and may arise from actinic keratosis.⁸ A large study suggested that adenoid SCC of the skin had a low rate of metastasis similar to that of the garden variety of SCC of the skin.⁸ For example, of 155 patients with 213 adenoid SCC of skin, metastasis occurred in three patients.⁸ Two of these patients had only regional lymph node metastases while one had regional lymph node and pulmonary metastases. Two other patients had direct extension of the disease to vital structures. All five of these patients died as a result of their tumours. More recently, mortalities range from 19% in 55 cases¹³ to 50% in six cases¹⁵ in other series of this tumour. The aggressiveness of the skin tumour is also stressed in review articles.¹⁶ Adenoid SCC in other anatomical locations, such as the oral cavity and mucosal surfaces of the head and neck, is aggressive.¹²⁻¹⁴

To the best of our knowledge, there have been no reports of adenoid SCC of the conjunctiva.¹⁻¹⁶ We, therefore, performed a retrospective clinicopathological study of patients with adenoid SCC of the conjunctiva on file in the registry of ophthalmic pathology of the Armed Forces Institute of Pathology (AFIP).

Methods

All cases accessioned between 1970 and 1982 that were coded as SCC of the conjunctiva were examined. Only those tumours with predominant histological features of an adenoid or pseudoglandular appearance due to neoplastic squamous surrounding lumina created by acantholysis were included in the study. Any tumour with a classic 'acantholytic' or 'adenoid' pattern was defined as an adenoid SCC even if that pattern was only identified in a small section of the tumour.

The following histochemical stains were performed in all cases: haematoxylin and eosin (H and E), periodic acid Schiff (PAS), mucicarmine, aldehyde fuchsin, and Alcian blue at pH of 2.5 and 0.4 and with and without pretreat-

Department of Ophthalmology, UMD-New Jersey Medical School, Newark, New Jersey, USA

J A Mauriello, Jr
A Abdelsalam

Department of Ophthalmic Pathology, Armed Forces Institute of Pathology, Washington, DC, USA
I W McLean

Correspondence to:
J A Mauriello, MD,
Department of Ophthalmology, UMD-New Jersey Medical School, Doctors Office Center, 90 Bergen Street, Newark, NJ 07103-2499, USA.

Accepted for publication
10 March 1997

Table 1 Clinical features and follow up data on eight patients with adenoid carcinoma of conjunctiva who had inflammatory signs

Case	Age	Sex	Presentation	Anatomic	Treatment	Outcome
1	81	M	Irritated, red eye	Limbus, superotemporal	Excision	Recurrence in 18 months
			Recurrent, irritated, red eye	Limbus, superotemporal	Wide re-excision	Recurrence in 28 months
			Mass	Limbus, superotemporal	Enucleation	Orbital recurrence in 22 months
			Mass	Socket	Exenteration Radiation therapy	Died of congestive heart failure
2	79	M	Irritated, red eye with mass Mass	Limbus, superotemporal Socket	Enucleation	Recurrence in 23 months
3	83	M	Irritated, red eye	Limbus, inferotemporal	Wide excision Radiation therapy	Died of brain metastases in 25 months
4	50	M	Irritated, red eye with mass and proptosis	Bulbar conjunctiva, temporal	Wide excision	No recurrence in 24 months
5	78	M	Irritated, red eye	Limbus, site unspecified	Enucleation	No further follow up
			Recurrent, mass	Limbus	Wide excision	No recurrence in 15 months
6	40	F	Fungating mass	Limbus onto cornea	Wide excision	Incompletely excised
			Irritated, red eye	Bulbar conjunctiva, nasal	Re-excised	No recurrence in 13 months
7	55	F	Irritated, red eye	Bulbar conjunctiva, superonasal	Wide excision	Recurrence in 9 months
			Mass	Bulbar conjunctiva, superotemporal	Wide re-excision	Recurrence in 15 months
			Mass	Bulbar conjunctiva, temporal	Wide re-excision	No recurrence in 13 months

ment with hyaluronidase. Transmission electron microscopy (TEM) was performed on one case.

Follow up information was obtained in all cases and length of follow up was recorded from the time of initial presentation. Recurrent cases were studied histopathologically whenever such materials were available.

Kaplan–Meier analysis was performed (Prodas, Conceptual Software, Houston, TX, USA) comparing the interval to recurrence for patients with and without an inflammatory presentation of their adenoid SCC. The log rank test was used to determine the significance of differences in recurrence rates.

Results

CLINICAL DATA

The study included 10 men and four women. The median age at the time of the diagnosis was 65 years (mean age of 62) and the age range 38–83 years. Twelve patients were white (nine men, three women), and two patients were black (one man, one woman).

The tumours were adjacent to the limbus in seven patients and in the bulbar conjunctiva in seven patients (Tables 1 and 2). Twelve cases involved the right eye and two cases involved the left eye. An irritated ‘red’ eye accompanied by tearing and foreign body sensation was the clinical presentation in eight cases (Fig 1). One such patient had proptosis with markedly decreased visual acuity and massive orbital invasion. The other six patients (Table 2) had a slowly growing painless mass which was pinkish yellow (two cases), greyish (two cases), leukoplakic (one case), or dark brown (one case of a black patient). The duration of signs and symptoms ranged from 6 weeks to 5 months.

HISTOPATHOLOGICAL FINDINGS

The typical tumour was a nodular epithelial proliferation that extended from the epithelium into the substantia propria of the conjunctiva or corneal stroma (Fig 2). The proliferating epithelial cells formed lobules, columns, and islands. Within the lobules there

Table 2 Clinical features and follow up data on six patients with adenoid carcinoma of conjunctiva who did not have inflammatory signs

Case	Age	Sex	Presentation	Anatomic	Treatment	Outcome
9	38	M	Mass	Limbus, superotemporal	Wide excision	No recurrence in 26 months
10	69	F	Mass	Bulbar conjunct-inferotemporal	Wide excision	No recurrence in 23 months
11	39	M	Mass	Limbus, inferonasal	Wide excision	No recurrence in 20 months
12	65	M	Fungating mass	Bulbar conjunctiva, inferonasal	Wide excision	No recurrence in 12 months
13	73	M	Mass	Limbus, temporal	Wide excision	No recurrence in 26 months
14	63	F	Mass	Bulbar conjunctiva, temporal	Wide excision	No recurrence in 23 months

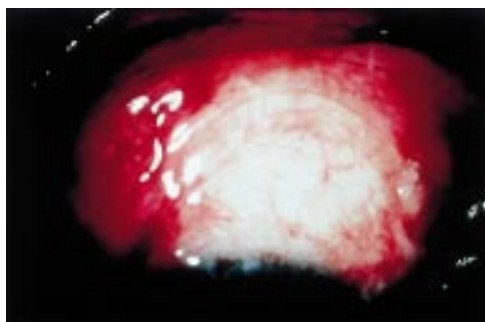


Figure 1 Clinical photograph of the eye of a 62-year-old man with irritated superior bulbar conjunctival mass (case 8).

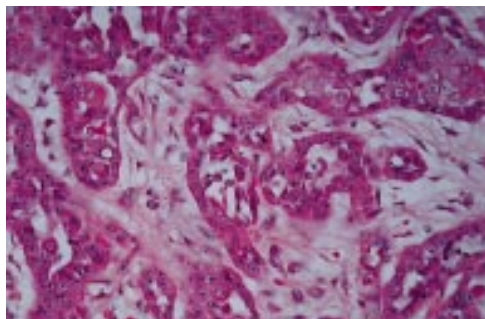


Figure 2 Note pseudoglandular pattern due to acantholysis of the neoplastic squamous cells.

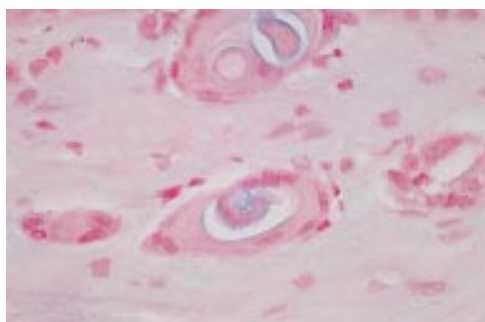


Figure 3 Island of tumour cells show extracellular Alcian blue positive substance that was digested by pretreatment with hyaluronidase (not shown) and consistent with hyaluronic acid.

was an adenoid or pseudoglandular appearance as a result of lumina that were formed by acantholysis.

Alcian blue at pH of 2.5 with or without pretreatment with testicular hyaluronidase demonstrated extracellular hyaluronic acid (Fig 3). The material stained positively with mucicarmine but did not stain with Alcian blue pH of 0.4, aldehyde fuchsin, or PAS. Electron microscopy in one case demonstrated no intracellular mucin filled vacuoles (Figs 4 and 5). Desmosomes and microvilli were present.

FOLLOW UP AND MANAGEMENT

The median follow up period was 2 years (mean 2 years and 4 months) and ranged from 1 year to 5 years and 11 months. Twelve of the 14 patients were initially managed by local excision and two patients were initially treated by enucleation (Table 1). Four of the 14 patients had a recurrence and one tumour was re-excised when it was noted that the initial

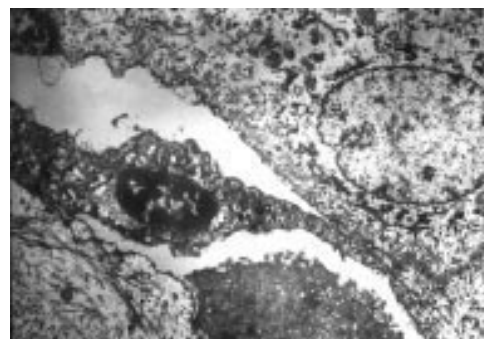


Figure 4 Electron micrograph of tumour cells from Figure 1 shows surface epithelial cells with microvillous processes.

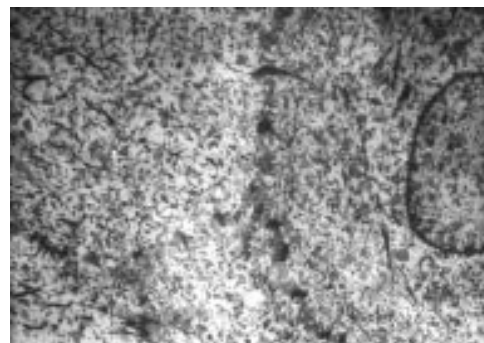


Figure 5 Electron micrograph of tumour cells from Figure 1 shows intracytoplasmic short collagen fibrils and desmosomal connections are present. There are no intracytoplasmic vacuoles.

excision was incomplete (Table 1). All five of these patients had an irritated, inflamed eye.

Three patients had more than one recurrence. One patient (case 1) had three recurrences (one in the conjunctiva and a second and third in the orbit). Each of the other two patients (cases 5 and 8) had two local, conjunctival recurrences.

One of the two patients initially treated by enucleation was a 50-year-old man (Table 1, case 4). He presented with proptosis due to massive orbital disease. He was free of disease 2 years after modified enucleation and wide tumour resection. The second patient (case 2), a 79-year-old man, had intraocular invasion with decreased vision. Twenty three months after enucleation, he had recurrence in the socket. Despite radical orbital excision and radiotherapy, he died of direct extension to the brain 2 years after initial presentation.

Two of the 12 patients initially managed with excision required enucleation for recurrent disease (Table 1). The first patient (case 1), an 81-year-old man, had excision of a leukoplakic limbal lesion in an irritated red eye. Twenty two months later, the tumour recurred and was widely excised. Twenty months after this second excision, a third recurrence required enucleation. A subsequent fourth recurrence was treated by orbital exenteration and radiation therapy. The patient died of unrelated congestive heart failure 3 months later. The second patient (case 5), a 78-year-old man, treated with enucleation after two local recurrences, was subsequently lost to follow up.

Kaplan–Meier analysis indicated that none of the patients without inflammatory signs had a recurrence in a 26 month follow up period whereas 81% of patients with inflammatory signs had a recurrence in a 30 month interval. The difference in the recurrence rates was significant ($z=2.35$, $p=0.019$).

Discussion

Adenoid squamous cell carcinoma (SCC) of the conjunctiva is a variant of SCC that has not previously been reported in the conjunctiva.^{1–16} Our review of 12 years of cases on the file at the AFIP revealed only 14 cases. The registry of the AFIP receives approximately 25 cases of SCC of the conjunctiva per year, and, therefore, the estimated prevalence of adenoid SCC is approximately 4% in a tertiary referral centre for pathology.²¹ Adenoid SCC has an adenoid or pseudoglandular pattern as a result of lumina formed by acantholysis within islands of neoplastic squamous cells. Since any tumour with a classic ‘acantholytic’ or ‘adenoid’ pattern was defined as an adenoid SCC even if that pattern was only identified in a small section of the tumour, it is possible that cases may have been neglected. None the less, the adenoid variant is worth the designation of as a separate subgroup because of its striking histopathological pattern and its apparent aggressiveness. Moreover, it has a distinct histochemical pattern in that the mucin in the acantholytic spaces contains is sensitive to hyaluronidase while the mucin in mucoepidermoid carcinoma is not sensitive to hyaluronidase. In contrast, mucoepidermoid carcinoma of the conjunctiva,^{17–20} composed of both squamous and mucus secreting tumour cells contains intracellular vacuoles and extracellular lumina of a sialomucin resistant to hyaluronidase.⁸

In addition to the lack of intracellular mucin on histochemical studies of our 14 cases, TEM of one case demonstrates that adenoid SCC of the conjunctiva is a variant of SCC of the conjunctiva that is different from mucoepidermoid carcinoma. The tumour cells demonstrate tonofilaments and microvillous processes characteristic of conjunctival squamous cells and no cells with features of conjunctival goblet cells.

Like adenoid SCC of the conjunctiva, extracellular hyaluronic acid is present in adenoid SCC of the skin.⁸ The origin of the hyaluronic acid in the conjunctival tumours is unclear. In the normal skin, hyaluronidase is present between cells of the outer root sheath of hairs and around the epidermal cells. Adenoid SCC of the skin is probably related to actinic exposure.⁸ Most of our cases arose in the sun exposed areas of the conjunctiva suggesting that these carcinomas are also actinically derived. Johnson and Helwig⁸ noted intracellular glycogen in the atypical degenerating acantholytic cells in adenoid SCC of the skin, and suggested that the origin of many of these carcinomas may be the epithelium of the pilar outer root sheath, which normally contains intracellular glycogen as well as extracellular

hyaluronic acid.⁸ A pilar origin is not possible in our 14 conjunctival tumours and intracellular glycogen was not present in any of them.

Conventional SCC rarely results in intraocular or orbital invasion and has a favourable prognosis.^{1–7} Adenoid SCC of the conjunctiva seems to be more aggressive and has a tendency to recur frequently even after wide excision. Eight of the 14 patients, all with an inflammatory presentation (Fig 1) had an ‘inflammatory’ clinical presentation. Five of our 14 patients had recurrent or incompletely resected tumours, four required enucleation, and one patient died with extension to the brain.

Adenoid SCC in other anatomical locations, including the skin and mucosal areas of the head and neck, has a worse prognosis than conventional SCC.^{12–16} Adenoid SCC of the conjunctiva, like the skin tumour, is a true variant of SCC and appears to be related to actinic exposure.

Because of the small sample size and the tertiary referral nature of the AFIP, we cannot exclude the possibility that our sample may be biased by over-representation of advanced cases. We also cannot be absolutely certain of the extent of the original resections because the material we reviewed did not allow adequate assessment of the surgical margins. None the less, we advocate ‘microscopically controlled excision’ of adenoid SCC.²² In this technique, the tumour is resected with a clinically free border of 2 mm. Neoplastic invasion of the cornea is treated by scraping off all epithelium over Bowman’s layer (with 2 mm clear margins) with a No 69 Beaver blade. The area of corneal epithelium is pretreated for 5 seconds with a cotton tipped applicator moistened in absolute alcohol to devitalise any residual abnormal cells. A lamellar keratectomy is not performed unless there is invasion through Bowman’s layer, which is usually a barrier against tumour spread into the corneal stroma.²²

Completeness of resection may best be judged only after review of the edges of the resection processed as permanent sections.²² Tumour present at the surgical margins requires re-excision while tumour at the base of the lesion signifies scleral involvement. In such instances, Buuns *et al*²² recommend cryotherapy since the sclera is too thin for resection. Cryotherapy (double cycle, freeze thaw refreeze technique with a nitrous oxide eyelid cryoprobe) may be delivered for 20 seconds each cycle. The thinness of the sclera precludes the use of a thermocouple. Close follow up is recommended to detect and manage recurrences as soon as possible.

The opinions or assertions contained herein are the private views of the authors and are not to be construed as official or as reflecting the views of the Department of the Army or the Department of Defense.

Supported in part by an unrestricted Departmental Grant from Research to Prevent Blindness, New York, New York, and the Lions Eye Research Foundation, Newark, New Jersey, USA.

1 Zimmerman LE. The cancerous, precancerous and pseudo-cancerous lesions of the cornea and conjunctiva (The Third Pocklington Memorial Lecture). In: Rycroft PV, ed. *Corneo-plastic surgery* (Proceedings of the Second Inter-

- national Corneo-Plastic Conference, London 1967). Oxford: Pergamon Press, 1969:547–55.
- 2 Irvine AR. Dyskeratotic epibulbar tumors. *Trans Am Ophthalmol Soc* 1963;61:243–73.
 - 3 Iliff WJ, Marback R, Green WR. Invasive squamous cell carcinoma of the conjunctiva. *Arch Ophthalmol* 1975;93:119–22.
 - 4 Nicholson H, Herschler J. Intraocular extension of squamous cell carcinoma of the conjunctiva. *Arch Ophthalmol* 1977;95:843–6.
 - 5 Li WW, Petit TH, Zakka KA. Intraocular invasion by papillary squamous cell carcinoma of the conjunctiva. *Am J Ophthalmol* 1980;90:697–701.
 - 6 Wexler SA, Wallow IHL. Squamous cell carcinoma of the conjunctiva presenting with intra-ocular extension. *Arch Ophthalmol* 1980;103:1175–7.
 - 7 Glasson WJ, Hirst LW, Axelson RA, Moon M. Invasive squamous cell carcinoma of the conjunctiva. *Arch Ophthalmol* 1994;112:1342–5.
 - 8 Johnson WC, Helwig EB. Adenoid squamous cell carcinoma (adenocanthoma). A clinicopathologic study of 155 patients. *Cancer* 1966;19:1639–50.
 - 9 Shimizu J, Oda M, Hayashi Y, Nonomura A, Watanabe Y. A clinicopathologic study of resected cases of adenosquamous carcinoma of the lung. *Chest* 1996;109:989–94.
 - 10 Fujiwara H, Mitchell MF, Arseneau J, Hale RJ, Wright TC. Clear cell adenosquamous carcinoma of the cervix. *Cancer* 1995;76:1591–600.
 - 11 Yoshida K, Manabe T, Tsunoda T, Kimoto M, Tadaoka Y, Shimizu M. Early gastric cancer of adenosquamous carcinoma type: report of a case and review of literature. *Jap J Clin Oncol* 1996;26:252–7.
 - 12 Napier SS, Gormely JS, Newlands C, Ramsay-Baggs P. Adenosquamous carcinoma A rare neoplasm with an aggressive course. *Oral Surg, Oral Med Oral Path, Oral Radiol, Endodontics* 1995;79:6078–611.
 - 13 Nappi O, Pettinato G, Wick MR. Adenoid (acantholytic) squamous cell carcinoma of the skin. *J Cutan Path* 1989;16:114–21.
 - 14 Batsakis JG, Huser J. Squamous carcinomas with glandlike (adenoid) features. *Ann Otol Rhinol Laryngol* 1990;99:87–88.
 - 15 Nappi O, Wick MR, Pettinato G, Ghiselli RW, Swanson PE. Pseudovascular adenoid squamous cell carcinoma of the skin. A neoplasm that may be mistaken for angiosarcoma. *Am J Surg Pathol* 1992;16:429–38.
 - 16 Bernstein SC, Lim KK, Brodland DG, Heidelberg KA. The many faces of squamous cell carcinoma. *Dermatol Surg* 1996;22:243–54.
 - 17 Rao NA, Font RL. Mucoepidermoid carcinoma of the conjunctiva; a clinicopathologic study of five cases. *Cancer* 1976;38:1699–709.
 - 18 Albert DM. Mucoepidermoid of the conjunctiva with intraocular invasion. Read before the Eastern Ophthalmic Pathology Society meeting, Philadelphia, 10 October 1980.
 - 19 Brownstein S. Mucoepidermoid carcinoma of the conjunctiva with intraocular invasion. *Ophthalmology* 1981;88:1226–9.
 - 20 Gamel JW, Eiferman RA, Guibor P. Mucoepidermoid carcinoma of the conjunctiva. *Arch Ophthalmol* 1984;102:730–1.
 - 21 McLean IW, Burnier MN, Jakobiec FA, Zimmerman LE. *Atlas of tumor pathology, tumors of the eye and ocular adnexa. Third Series.* Washington, DC: Armed Forces Institute of Pathology, 1994:51.
 - 22 Buuns DR, Tse DT, Folberg R. Microscopically controlled excision of conjunctival squamous cell carcinoma. *Am J Ophthalmol* 1994;117:97–102.



Adenoid squamous carcinoma of the conjunctiva —a clinicopathological study of 14 cases

Joseph A Mauriello, Jr, Ahmed Abdelsalam and Ian W McLean

Br J Ophthalmol 1997 81: 1001-1005

doi: 10.1136/bjo.81.11.1001

Updated information and services can be found at:

<http://bjo.bmj.com/content/81/11/1001.full.html>

These include:

References

This article cites 16 articles, 6 of which can be accessed free at:

<http://bjo.bmj.com/content/81/11/1001.full.html#ref-list-1>

Email alerting service

Receive free email alerts when new articles cite this article. Sign up in the box at the top right corner of the online article.

Topic Collections

Articles on similar topics can be found in the following collections

[Eye \(globe\)](#) (538 articles)

Notes

To request permissions go to:

<http://group.bmj.com/group/rights-licensing/permissions>

To order reprints go to:

<http://journals.bmj.com/cgi/reprintform>

To subscribe to BMJ go to:

<http://group.bmj.com/subscribe/>