

## PERSPECTIVE

## Current approach to postoperative endophthalmitis

Gordana Sunaric-Mégevand, Constantin J Pournaras

Endophthalmitis is a rare complication, potentially the most devastating, of intraocular surgery or trauma. Despite major advances in asepsis, surgical technique and antibiotic therapy, it remains a major concern for any ocular surgeon. Its prevention by meticulous clinical evaluation of preoperative risk factors, accurate surgical procedure, pre- and perioperative antibiotic prophylaxis is one of our first goals. In some cases, however, the infection will occur; only prompt diagnosis and adequate treatment can successfully restore visual acuity.

This review summarises some relevant notions about the incidence, the causative organisms, and predisposing factors, with particular emphasis on the prophylaxis and various treatment modalities.

**Incidence**

Over the past decade, there has been a decline in the incidence of postoperative endophthalmitis, owing to the improvement of modern surgery, instrumentation, sterility, and prophylactic antibiotics. Generally accepted as approximately 10% at the beginning of the century,<sup>1</sup> the incidence today ranges from 0.3% (prospective study realised in 1989 in France)<sup>2</sup> down to 0.07% (retrospective American study reporting data from 1984 to 1989).<sup>3</sup>

Incidence seems to depend on the type of surgery. After extracapsular lens extraction (ECLE) or phacoemulsification and intraocular lens (IOL),<sup>3,4</sup> it is between 0.07% and 0.12% (Table 1). After secondary IOL implantation, it is higher (0.3%), probably related to greater manipulation. Endophthalmitis immediately following trabeculectomy is rare (0.6%), with an apparent higher incidence of late onset endophthalmitis (1.8%) occurring from 3 months to 27 years postoperatively.<sup>5</sup> Of particular concern is the high incidence of rapidly progressing and devastating late onset endophthalmitis after the use of the antimetabolites 5-fluorouracil (5-8%)<sup>6,7</sup> and mitomycin C (MMC) (2.7-3%).<sup>8,9</sup>

In a large study (27 181 eyes) of sutureless cataract extraction after conventional ECLE or phacoemulsification, an incidence of only 0.015% has been reported.<sup>10</sup>

Olson has postulated that 88% of all cases of endophthalmitis occur within 6 months after surgery.<sup>11</sup> Seventy five per cent of cases in the Endophthalmitis Vitrectomy Study (EVS) were reported within 11 days after cataract surgery.<sup>12</sup>

**Organisms**

It has been postulated that the patient's own flora is the most common source of infections.<sup>13,14</sup> Indeed, 75% of cultures from samples taken on normal eyes are positive for *Staphylococcus epidermidis*, *Staph aureus*, and various streptococci<sup>15</sup> and a similar organism pattern has been found in eyes with endophthalmitis. Genetic analysis using plasmid typing, restriction endonuclease analysis of genomic DNA and Southern blot hybridisation in *Staph*

*epidermidis* endophthalmitis was performed on 17 cases with bacteriologically similar organisms isolated from external and intraocular sources.<sup>13</sup> The authors found the isolates to be genetically indistinguishable in 82% of cases. Recently 67.7% of indistinguishable eyelid and intraocular specimens were described using pulsed field gel electrophoresis in 105 isolates of 225 patients with postoperative infection.<sup>16</sup> These studies confirmed that the periocular microbiota serve as a potential causal agent for postoperative endophthalmitis. Contamination of the lens can occur by contact with the ocular surface, or with the air of the operating room.<sup>17</sup> The organism can also be introduced into the eye by contaminated irrigation solutions.<sup>18-22</sup>

The most common organisms responsible for endophthalmitis are listed in Table 2: these include mainly Gram positive bacteria, followed by Gram negative bacteria, and only rarely fungi. Coagulase negative staphylococci are the most common infecting organisms, particularly *Staph epidermidis*.<sup>23,24</sup> Streptococci are diagnosed in 20% of infections after intraocular surgery, but account for 57% in late onset endophthalmitis after trabeculectomy.<sup>5</sup> According to numerous reports, virtually any organism can cause endophthalmitis.

**Clinical aspects**

Initial symptoms are blurred vision and a red or painful eye. Pain, although thought to be a major diagnostic sign, can be absent in up to 25% of the cases.<sup>12</sup> Poor visual ac-

Table 1 Incidence of postoperative endophthalmitis

	Kattan et al <sup>3</sup>	Javitt et al <sup>4</sup>
ECLE + IOL	0.07% (16/22791)	0.12% (236/195587)
ICLE + IOL	0.09% (7/7552)	0.12% (34/28424)
Phaco+ IOL		
Sec IOL	0.3% (3/988)	
PPV	0.05% (1/1974)	
PKP	0.11% (2/1783)	
Trab		
acute	0.06% (1/1632)	
late	1.8%*	

ECLE = extracapsular lens extraction; ICLE = intracapsular lens extraction; IOL = intraocular lens; Phaco = phacoemulsification; Sec IOL = secondary IOL implantation; PPV = pars plana vitrectomy; PKP = perforating keratoplasty; Trab = trabeculectomy.

\* Mandelbaum.<sup>5</sup>

Table 2 Organisms

Gram positive bacteria 75%-85%	Gram negative bacteria 10%-15%
<i>Staphylococcus epidermidis</i> 43%	<i>Pseudomonas</i> 8%
<i>Streptococcus</i> spp 20% (57%)*	<i>Proteus</i> 5%
<i>Staphylococcus aureus</i> 15%	<i>Haemophilus influenzae</i> 0-1% (23%*)
<i>Propionibacterium acnes</i> 30 reports	<i>Klebsiella</i> 0-1%
<i>Bacillus cereus</i> 1%	<i>Coliform</i> spp 0-1%
Fungi (rare)	Single organism >mixed flora
<i>Candida parapsilosis</i>	
<i>Aspergillus</i>	
<i>Cephalosporium</i> spp dtc	

\*In late onset endophthalmitis associated with filtering blebs.

ity, hypopyon, decreased media clarity, and poor fundus visualisation are the main clinical signs.

Three forms of clinical presentation can be distinguished. The acute form, usually fulminant, occurs 2–4 days postoperatively, and is most frequently due to streptococci, *Staph aureus*, or Gram negative organisms. Some clinical elements can indicate a Gram negative infection—a corneal infiltrate, the loss of red reflex, and poor initial visual acuity. The delayed form, moderately severe, occurs 5–7 days postoperatively and is frequently due to *Staph epidermidis*, coagulase negative cocci, or more rarely, fungal species. Finally, chronic infection can occur as early as 1 month postoperatively. *Propionibacterium acnes*, *Staph epidermidis*, or fungal infections are the most common organisms found in this late onset group. These forms, however, are subject to great variations. A case of delayed endophthalmitis with indolent course caused by *Pseudomonas aeruginosa* has been reported.<sup>25</sup>

### Particular forms of postoperative endophthalmitis

#### ENDOPHTHALMITIS OCCURRING AFTER FILTERING SURGERY

The occurrence of late infection associated with filtering surgery has been well described. The presence of a thin walled, cystic bleb is the determining factor in creating a direct access to the eye for an organism either by the high permeability of the cystic wall or by the relatively frequent coexistence of a conjunctival leak.<sup>5 26–30</sup> This allows the organism to colonise the bleb and invade the anterior chamber or the vitreous even in a late postoperative period.<sup>3 25 27</sup> It is important to identify the intraocular infection before it reaches the vitreous; once the posterior chamber is infected, the visual outcome usually seems poor, particularly in culture proved endophthalmitis.<sup>5 27</sup> Unlike endophthalmitis following cataract surgery, streptococci in late bleb related infections are the most frequent organisms involved.<sup>5</sup> Recently, the term ‘blebitis’ was suggested<sup>31</sup> in order to differentiate bleb related infections, involving only the anterior segment and characterised by a good prognosis, from those with fulminant endophthalmitis involving also the vitreous.

Antimetabolites increase the incidence of cystic filtering blebs. Histological studies of eyes treated with mitomycin C present filtering blebs with attenuated epithelium, loosely arranged hypocellular, subepithelial connective tissue, and a paucity of blood vessels.<sup>31–33</sup> The resulting cystic, ischaemic, and particularly thin walled bleb has a greater potential risk of infection than filtering blebs where no antiproliferative agents have been used. Chronic or intermittent leakage has been noted in many blebs where an antimetabolite had been used.<sup>6</sup>

Very little is reported in the literature about late bleb related endophthalmitis in relation to the use of antimetabolites. Moster *et al* reported one case of endophthalmitis in a series of 115 patients using MMC at a concentration of 0.04% exposed for 1.5–4 minutes.<sup>34</sup> Three per cent of bleb related endophthalmitis has been found with 0.02% MMC, independently of the duration of the application (2 or 5 minutes).<sup>35</sup> Higginbotham *et al* report a 2.6% incidence rate (6/229) over a 3 year period after application of 0.02–0.05% MMC for 2–5 minutes, occurring in the majority of cases in trabeculectomy performed in the inferior quadrant.<sup>9</sup> Trabeculectomy with 5-fluorouracil accounts for 5.7% of late bleb related endophthalmitis with higher incidence occurring in inferior filtration blebs.<sup>6 7</sup> It appears that the use of antimetabolites increases the cumulative incidence of bleb related endophthalmitis that can lead to severe visual impairment, and it should therefore be used only on high risk patients for whom conventional filtering surgery failed.

#### FUNGAL ENDOPHTHALMITIS

Fungal postoperative endophthalmitis is rare. However, the particular clinical setting and diagnostic difficulties make this type of intraocular infection a serious concern. Over 20 species have been isolated, the most common being candida species, in particular *Candida albicans*, *Aspergillus*, *Cephalosporium*, *Fusarium*, *Voluella*, and *Neurospora*. There have been several reports of fungal endophthalmitis resulting from contaminated solutions.<sup>18–22</sup>

The clinical presentation is that of chronic endophthalmitis with indolent inflammation associated with relatively mild symptoms, fibrinopurulent anterior chamber exudate, vitreous snowballs, and opacities. Typically, signs and symptoms will not become evident for several weeks after the operation<sup>20 36</sup>; sometimes they are masked by the use of topical corticosteroids and this can lead to a dramatic increase in intraocular inflammation and ocular discomfort.<sup>18</sup>

Fungal endophthalmitis may be difficult to distinguish from infection due to *Propionibacterium acnes*.

#### ENDOPHTHALMITIS DUE TO PROPIONIBACTERIUM

Chronic, low grade, delayed, and often recurrent postoperative granulomatous uveitis is the typical presentation of *P acnes* endophthalmitis. The infection is due to an anaerobic, pleomorphic, Gram positive bacillus, a normal commensal of the conjunctival sac.<sup>35 37</sup> The organism is able to stimulate the immune system, but is resistant to the killing mechanisms of polymorphonucleocytes and monocytes, and thus persists intracellularly after phagocytosis.<sup>38</sup>

Although there seems to be an adjuvant effect of the bacteria in provoking an immune response with residual soft lens material,<sup>39 40</sup> the type of cellular reaction present in the inflammatory exudate is not consistent with an anaphylactic type of uveitis.

The organism can be sequestered in inflammatory cells and in colonies in the capsular bag clinically presented as white capsular plaques. Therefore, it is often difficult to culture *Propionibacterium*, as cultures may take up to 14 days to show an identifiable growth. Negative cultures have been reported in a case with light microscopy proved Gram positive organisms within the removed capsular remnants.<sup>41</sup> Gram stain is an even less reliable method of identifying the organism.<sup>42</sup>

*P granulorum*, described twice in the literature, has a similar clinical presentation and therapeutic response.<sup>43 44</sup>

Although typically appearing as a chronic infection, endophthalmitis due to *Propionibacterium* can also be found in an acute form.<sup>45 46</sup> This form seems to be of better prognosis because it responds well to the usual therapeutic strategies for acute endophthalmitis, and no recurrences are reported. It has been postulated that the acute form may be related to the size of the inoculum, the absence of bacterial sequestration within the lens capsule, or to some host factors.<sup>47</sup>

#### STERILE POSTOPERATIVE ENDOPHTHALMITIS

Postoperative inflammation is not always due to an infecting organism. Residual chemicals from sterilisation processes,<sup>48</sup> toxicity of the polymethylmethacrylate (PMMA) monomers,<sup>49</sup> and mechanical irritation of the iris and ciliary body by the intraocular lens<sup>47 50</sup> are possible, although they are causes less frequently incriminated now than during the early use of intraocular implants. Autoimmunity to the lens cortical remnants can cause a mild to severe inflammation with hypopyon, in the absence of infection.<sup>51–53</sup> However, retained lens fragments and endophthalmitis may occur concurrently; it is therefore mandatory to suspect an infection in any ocular inflammation following cataract surgery with retained lens material.<sup>54</sup> Some

authors have suggested that bacterial infection may contribute to the pathogenesis of lens induced uveitis.<sup>40</sup>

### Diagnosis

The clinical picture suggestive of postoperative endophthalmitis can be confirmed by the culture of the pathogenic organism. Conjunctival swabs are not indicated since most eyes are culture positive preoperatively for organisms likely to cause postoperative endophthalmitis.<sup>55</sup> Additionally, only few of these culture proved eyes will develop postoperative infections, even in cases of particularly virulent species. Anterior chamber taps, as well as a vitreous biopsy, should be performed; cultures from the vitreous tap are positive in 56%–70% of the cases, compared with only 36%–40% for the aqueous humour tap.<sup>54 55</sup> The ESV study confirmed these data.<sup>12</sup> Cases with a positive aqueous tap and a negative vitreous tap have been described, showing that a combined vitreous and aqueous tap culture is required.<sup>56 57</sup>

The anterior chamber aspirate is obtained through a paracentesis using a 25–27 gauge needle attached to a tuberculin syringe to aspirate about 0.1 ml of aqueous humour. The anterior chamber reforms in 3–5 minutes.

The vitreous specimen can be obtained by aspiration through a needle, either using a vitrectomy biopsy procedure or as part of a full therapeutic vitrectomy. The vitreous in endophthalmitis can be dense and contain inflammatory membranes, so aspiration may not provide sufficient volume for analysis. In addition, vitreous biopsy is safer by cutting the vitreous strands rather than pulling on them, as occurs with aspiration. When the technique of vitrectomy biopsy is used, infusion is usually recommended to prevent the globe from collapsing.<sup>58 59</sup> Doft and Donnelly recommend a single sclerotomy vitreous biopsy technique without infusion, which avoids additional sclerotomy openings.<sup>60</sup>

If possible, the sample should be sent immediately for Gram and fungal staining; however the injection of broad spectrum antibiotics should not be retarded, as the Gram stain is positive in only 60% of the cases.<sup>61</sup> In case of a positive fungal stain an antifungal agent should be added. The samples should be inoculated to aerobic, anaerobic, and fungal media. Anaerobic media should be watched for at least 14 days if *Propionibacterium* is suspected.

Careful procedure can reveal a positive culture and prove the presence of endophthalmitis in 56%–82% of samples.<sup>61 62</sup>

### Treatment

The aim of the treatment is to apply as soon as possible an agent with a broad spectrum antibiotic. The majority of antibiotics have a poor penetration into the vitreous cavity when administered intravenously or orally; retrobulbar injections reach higher intraocular concentrations than subconjunctival injections.<sup>63</sup> However, in established endophthalmitis, these routes are unable to provide sufficient antibiotic concentrations in the avascular vitreous cavity. Therefore intravitreal injections are the treatment of choice in endophthalmitis.

#### INTRAVITREAL INJECTION OF ANTIBIOTICS

Intravitreal injection bypasses the blood-retinal barrier and can rapidly achieve therapeutic drug levels at the sites of infection. In the past 20 years, several authors have studied the modality of intravitreal injections and the type of antibiotics to be used. The ideal drug must show a good antibacterial activity against both Gram positive and Gram negative organisms, and no toxicity for ocular structures,

particularly in the retina. Presently, no single antibiotic covers efficiently all the organisms that induce postoperative endophthalmitis; a combination of at least two drugs is thus required.

Based on experimental studies on rabbits, Peymann and coworkers recommended the use of gentamicin 0.2–0.4 mg for Gram negative organisms in association with a cephalosporin of the first or second generation (cephazolin or cefoxitin) active against Gram positive organisms.<sup>64 65</sup> Amikacin and tobramycin were mainly used for cases resistant to gentamicin.<sup>66 67</sup> However, several experimental and clinical studies have recently raised the problem of retinal toxicity related to aminoglycosides and particularly gentamicin.<sup>68 69</sup> The evidence of toxic maculopathy following either subconjunctival or intravitreal injection of this antibiotic has prevented many surgeons from using it systematically.<sup>69 70</sup> Amikacin has four times less retinal toxicity than gentamicin at 0.4 mg.<sup>67</sup> It is unclear whether the concentration of the drug was correct in the five cases in which retinal toxicity after intravitreal injection was suspected.<sup>69</sup> Amikacin covers a large number of Gram negative organisms and those resistant to other aminoglycosides.

Ceftazidime has emerged as an interesting antibiotic for Gram negative organisms and an alternative to amikacin. As a third generation cephalosporin, this drug is bactericidal against the majority of Gram negative bacteria with little resistance, as well as *Pseudomonas aeruginosa* generally resistant to cephalosporin, and is more effective than aminoglycosides in hypoxic or acid conditions. Retinal toxicity of ceftazidime has been studied in primates and the concentrations of 2.25 mg/0.1 ml is safe and recommended for intravitreal injection.<sup>71</sup>

Amikacin and ceftazidime are relatively poorly active against Gram positive organisms and must therefore be reinforced by one of the antibiotics known to be effective against Gram positive bacteria. Many surgeons still combine amikacin or ceftazidime with a first or second generation cephalosporin. However, methicillin resistant staphylococci are resistant to all available cephalosporins and there has been a recent increase in ocular staphylococcal infections resistant to ceftazidime.

Vancomycin has a bactericidal activity against almost all Gram positive bacteria including methicillin resistant *Staph aureus* or methicillin resistant *Staph epidermidis* and some cephalosporin resistant streptococci, *Bacillus cereus*, and coagulase negative staphylococci. It is active in case of chronic postoperative endophthalmitis due to *P acnes*. Its excellent activity against streptococcal strains makes it the drug of choice in the treatment of late onset bleb related endophthalmitis after filtering surgery. No retinal toxicity has been reported with intravitreal injections of up to 2 mg.<sup>72</sup> When vancomycin is associated with amikacin, these two drugs display a synergic activity. The association with ceftazidime is characterised by their physical incompatibility and the appearance of a precipitate,<sup>73</sup> but in clinical practice this has not been reported as a problem. Actually, vancomycin combined with amikacin or ceftazidime appears to be the best association in the treatment of postoperative endophthalmitis; the former for its activity on Gram positive organisms, the latter on Gram negative.

Other antibiotics are only of limited interest for intravitreal injection; synthetic penicillins, such as ampicillin, amoxicillin, and carbenicillin, are effective against a variety of Gram positive and Gram negative bacteria, but they are inactivated by penicillinase and are therefore ineffective against benzylpenicillin (penicillin G) resistant staphylococci.<sup>74</sup> Because of the low minimal inhibitory concentration for the majority of streptococcal strains, these antibiotics would in theory be the choice in the treat-

ment of bleb related late onset endophthalmitis. However, other organisms than streptococci have been cultured in cases of endophthalmitis following filtering surgery<sup>75</sup> and therefore a broad spectrum antibiotic with little resistance is needed.

Erythromycin is quite similar to penicillin in its effect against Gram positive micro-organisms; staphylococcal resistance to this drug develops as readily as it does to penicillin.<sup>74</sup> Therefore erythromycin is seldom the first choice for the treatment of endophthalmitis.

Teicoplanin, a glycopeptide antibiotic such as vancomycin, is active against Gram positive aerobic and anaerobic bacteria including methicillin resistant strains. To our knowledge, no data are available on intravitreal injections of this drug.

Imipenem, a carbapenem  $\beta$  lactam antibiotic, can be used as intravitreal infusion in a concentration of 5  $\mu$ g/ml. This drug displays good activity against staphylococcal and streptococcal species; however, methicillin resistant staphylococci and the majority of pseudomonas species are resistant to imipenem.<sup>74</sup>

Quinolones are currently being studied for intravitreal use.

A single intravitreal injection may not be sufficient since positive vitreous cultures following intravitreal injection of antibiotics have been observed.<sup>56, 76, 77</sup> It shows that some organisms, although sensitive to the antibiotic used, are more resistant or more virulent.<sup>78</sup> Other organisms, such as pseudomonads and fungi, have a slow growing rate and are therefore difficult to eradicate with single doses.<sup>79</sup>

Delayed treatment seems to decrease the chance of curing endophthalmitis; in experimental studies the antibiotic was not effective in salvaging the infected eyes when given 24 hours or later after inoculation in the vitreous cavity.<sup>66</sup> Clinical studies confirm the poor efficacy when antibiotics are injected intravitreally 48 hours after the infection is established.<sup>80</sup>

The pharmacokinetics of the drug, which involves the study of the time course of changes in the concentration of drugs and their metabolites in tissues, its bioavailability, relating the amount of drug absorbed to the amount administered,<sup>74</sup> and the presence or absence of vitreous are other important factors influencing the efficacy of the antibiotic therapy.<sup>81</sup>

In any instance where no improvement is achieved after the first injection, a repeated aqueous humour and vitreous tap is indicated. A second antibiotic injection can then be chosen, guided by results of the culture and sensitivity studies of material from the initial procedure. The need for a second intravitreal injection must be balanced against the potential toxicity of a cumulated concentration. Although far less toxic than gentamicin, repeated injections of amikacin induce more toxic retinal changes than repeated injections of vancomycin.<sup>82</sup>

#### SYSTEMIC ANTIBIOTIC TREATMENT

The use of systemic postoperative antibiotics in the treatment of endophthalmitis remains a controversial issue. The ESV study has clearly shown that systemic postoperative antibiotic therapy has no benefit in the treatment of endophthalmitis.<sup>12</sup> However, the antibiotics used (ceftazidime and amikacin), are known to have a relatively poor coverage for Gram positive organisms and intravitreal penetration of amikacin after intravenous injection is poor.<sup>83</sup> Other antibiotics, such as quinolones and imipenem, have a much better intravitreal penetration, when given systemically, and a larger antimicrobial spectrum. In experimental staphylococcal endophthalmitis, intravenous sparflaxacin, perfloxacin, and imipenem have a significantly better activity than vancomycin and amikacin.<sup>83</sup>

Whether patients with endophthalmitis treated with vitrectomy or vitreous tap would benefit from systemic antibiotics such as quinolones and imipenem can only be answered by a controlled, randomised study.

Penicillin penetration into the aqueous and vitreous humours is generally poor<sup>84, 85</sup> even in the inflamed eye.<sup>86</sup> Intraocular levels can be improved by concomitant use of probenecid, a tubule blocking drug<sup>87</sup>; that is, however, rarely used in practice. The same effect can be achieved by giving more penicillin and, furthermore, these drugs may cause allergy or renal stones. Other antibiotics with broader antimicrobial spectra and better intraocular penetration, as mentioned above, have replaced penicillin in the treatment of endophthalmitis.

Clindamycin is effective against Gram positive aerobic and anaerobic infections and is used when penicillin and cephalosporins cannot be administered and in the particular setting of post-traumatic endophthalmitis caused by *Bacillus cereus*.<sup>74</sup>

Teicoplanin is a glycopeptide antibiotic like vancomycin, and is active against Gram positive aerobic and anaerobic bacteria including methicillin resistant strains. Several reports claim the same efficacy as vancomycin with a superior tolerability and fewer adverse events.<sup>88, 89</sup> However, resistance to this drug has recently been described.<sup>90</sup> No data are available on the intraocular penetration of teicoplanin but the poor diffusion through the blood-brain barrier leads to the assumption that no or very little drug will penetrate in the vitreous after systemic administration. This issue can only be clarified by pharmacokinetic studies in ocular tissues.

#### TREATMENT OF FUNGAL ENDOPHTHALMITIS

Since the first reported successful treatment of candida endophthalmitis with parenteral amphotericin B in 1960,<sup>91</sup> this drug has become the treatment of choice of intraocular fungal infections. Based on experimental studies on rabbits, Axelrod *et al* found no toxic effect of the drug when injected in the vitreous at a concentration of 5  $\mu$ g.<sup>92</sup> Currently, intravenous amphotericin B associated with intravitreal injections of the drug following vitrectomy is used in the treatment of postoperative fungal endophthalmitis. However, the poor penetration of intravenously administered amphotericin B into the vitreous,<sup>93</sup> its serious systemic side effects,<sup>94</sup> and confirmed retinal toxicity following intravitreal injection of recommended concentrations,<sup>95</sup> render this drug less attractive. Several clinical reports and experimental results confirm the good intraocular penetration of fluconazole, a new azole derivate.<sup>96</sup> Following intravenous injection of fluconazole in New Zealand White rabbits, 64% of the serum concentration is found in the aqueous humour and 27% in the vitreous. Similar findings have been reported in humans in whom aqueous humour concentration reaches 80% of the serum concentration after a single oral dose of 200 mg.<sup>96</sup> Intravitreal accumulation and steady state of the drug have been observed in miniature pigs if the plasma concentration is maintained stable.<sup>98</sup> In this condition, the vitreous concentration reaches 56% of the plasma concentration. As some authors do not recommend the use of systemic antimycotic agents for exogenous endophthalmitis, we studied the possibility of an intraocular route for administering fluconazole. No retinal toxicity was found by means of an intraretinal electroretinogram with concentrations up to 1000  $\mu$ g.<sup>98</sup> This method of administration, particularly important and useful in exogenous fungal infections, would provide a new way of treating postoperative fungal endophthalmitis.

Other antifungal agents have low intraocular penetration (miconazole, ketoconazole, itraconazole) and are therefore

rarely used.<sup>96</sup> Flucytosine has good ocular penetration but high resistance development. Synergistic action occurs with the combined use of flucytosine and amphotericin B or flucytosin and fluconazole. Unfortunately the combination of these antifungal drugs enhances toxicity against host cells, inducing morbidity that overshadows their beneficial effect.<sup>99 100</sup>

#### TREATMENT OF ENDOPHTHALMITIS DUE TO P ACNES

The effective treatment of proved *Propionibacterium* endophthalmitis is still controversial. Zambrano *et al* suggested an algorithm for staged therapy: milder cases would initially be treated with intraocular vancomycin alone (1 mg/0.1 ml), and in more severe cases with either intraocular vancomycin or vitrectomy plus intraocular vancomycin.<sup>101</sup> A high recurrence rate after intraocular injections alone, vitrectomy, and partial capsulectomy with or without intraocular or systemic antibiotics has been reported.<sup>47</sup> It suggests the persistence of viable organisms sequestered within the capsular remnants, where they may survive to intraocular, intravenous, oral, and topical antibiotic therapies. Only complete removal of the white capsular plaques or, in severe inflammation, removal of the entire capsular bag and intraocular lens exchange, are guarantees of therapeutic success.<sup>47</sup>

#### Vitrectomy

Vitrectomy offers several theoretical advantages: removal of infecting organisms and their toxins, removal of vitreous membranes that could lead to subsequent tractional detachment of the retina, provision of adequate material for culture, and better distribution of antibiotics. However, the absence of vitreous could increase drug toxicity: firstly, the injected concentration reaches the retina immediately and prolongs its contact time and, secondly, the clearance of the antibiotic from the vitreous cavity is quicker, and multiple injections could be necessary to obtain the same elimination half life and efficacy, thereby increasing the risk of toxicity.<sup>81</sup>

Results in experimental studies are better when vitrectomy is associated with intravitreal injection of antibiotics rather than intraocular antibiotics alone.<sup>102-104</sup> Previous clinical reports showed no advantage of vitrectomy over intravitreal injection of antibiotics alone. However, there was a selection bias mainly because eyes with severe endophthalmitis and poor visual prognosis were vitrectomised. The protocol suggested by Stern *et al*<sup>105</sup> advocates no vitrectomy in cases of mild to moderate endophthalmitis with an hypopyon less than 15%. However, in case of severe endophthalmitis with a hypopyon greater than 15%, a vitrectomy is necessary.

The results of the prospective, randomised, multicentre Endophthalmitis Vitrectomy Study show no advantage of vitrectomy in eyes with a visual acuity of hand movement or better; vitrectomy gave better results in eyes with light perception vision or worse. The authors suggest that eyes with visual acuity better than light perception should be treated with intravitreal antibiotic injection alone (Fig 1).<sup>12</sup>

#### Steroids

The rationale for using steroids is the requirement of an anti-inflammatory drug in endophthalmitis. Histological studies of eyes with endophthalmitis show that the massive inflammation of the posterior segment in itself causes retinal destruction. Periphlebitis, perivascular neutrophil infiltration, exudates, oedema, haemorrhages, and intraretinal microabscesses can be seen as early signs of bacterial endophthalmitis. Retinal serous or tractional detachment can follow and seriously compromise visual rehabilitation.

Furthermore, vitreal bands and membranes can enclose the micro-organisms and inhibit the action of antibiotics in cases where no vitrectomy is used.<sup>106 107</sup>

Based on experimental studies on rabbits, an intravitreal injection of 0.2–0.4 mg of dexamethasone was recommended within the first 10 hours after inoculation, except when fungal infection is suspected.<sup>66</sup> Even subconjunctival injections of corticosteroids on inoculated rabbit eyes clear the vitreous compared with eyes without treatment. No advantage over subconjunctival injections was found with retrobulbar administration.<sup>108</sup>

The systemic administration of corticosteroids was studied in a retrospective study comparing visual outcome and media clarity between a group with intravenous methylprednisolone in the first 48 hours, another group with oral prednisone after the first 48 hours, and a third group with no corticosteroid. Significantly better results were obtained in the first two groups.<sup>107</sup>

Intravitreal injection of 1200 µg of corticosteroids after vitrectomy resulted in a clearance of the vitreous cavity in 19 of 20 patients.<sup>109</sup> No exacerbation of endophthalmitis was seen in these patients.

Whether the oral or intravenous administration is as effective as intravitreal injection remains to be elucidated.

#### Prevention

Over 70% of preoperative conjunctival swabs in normal eyes will show positive cultures for organisms most commonly found in postoperative endophthalmitis.<sup>15 17</sup> Anterior chamber inoculation by this saprophytic conjunctival flora has been studied by Egger *et al*<sup>110</sup>; anterior chamber aspirates of 200 patients undergoing uncomplicated ECLE and IOL (87%) or phacoemulsification and IOL (13%), taken both at the beginning and at the end of the surgical procedure, showed in 51 patients (25.5%) culture growth, mainly coagulase negative staphylococci; in 17 of these patients (33%) only the samples taken at the beginning of surgery were positive, and in 21 of them (41.2%) only those taken at the end of surgery were positive; in 13 patients (25%) both samples were contaminated. The authors state a possible role of intensive fluid irrigation during the procedure as an explanation for the isolated positive cultures at the beginning of surgery.

It appears evident that decreasing preoperative risk factors and infections is one of the most important steps in preventing postoperative infection. Particular care should be taken to exclude from surgery patients with blepharitis, conjunctivitis, hordeolum, canaliculitis, dacryocystitis, and even ulcers elsewhere in the body. Special attention should be given to wearers of extended wear contact lenses and patients with a contralateral prosthesis. Such eyes are often colonised by Gram negative organisms. Patients with atopic dermatitis, as well as patients suffering from keratoconjunctivitis sicca, present with a high colonisation of staphylococci.

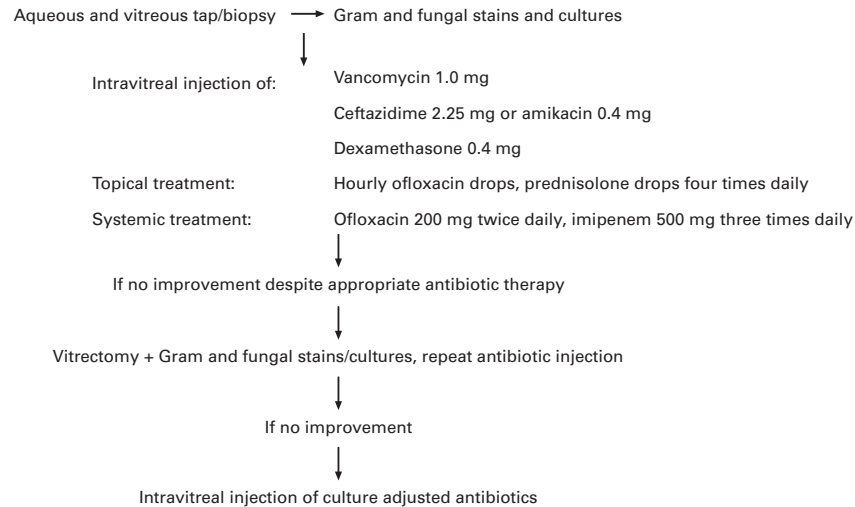
#### PREOPERATIVE SCRUB

Povidone-iodine has a broad antibacterial, as well as antifungal and antiviral, activity: it decreases conjunctival flora growth to 91% and species to 50%, and it has been clearly shown to reduce the incidence of endophthalmitis.<sup>111-114</sup> This iodine releasing polymer can destroy bacteria in 30 seconds and its efficacy is comparable with a 3 day preoperative treatment with the association of polymyxin, neomycin, and gentamicin.<sup>112 113 115</sup>

#### TOPICAL ANTIBIOTIC PROPHYLAXIS

Allen and Mangiaracine report a reduction in the incidence of postoperative infections after the use of

### Visual acuity greater than hand movements



### Visual acuity less than hand movements

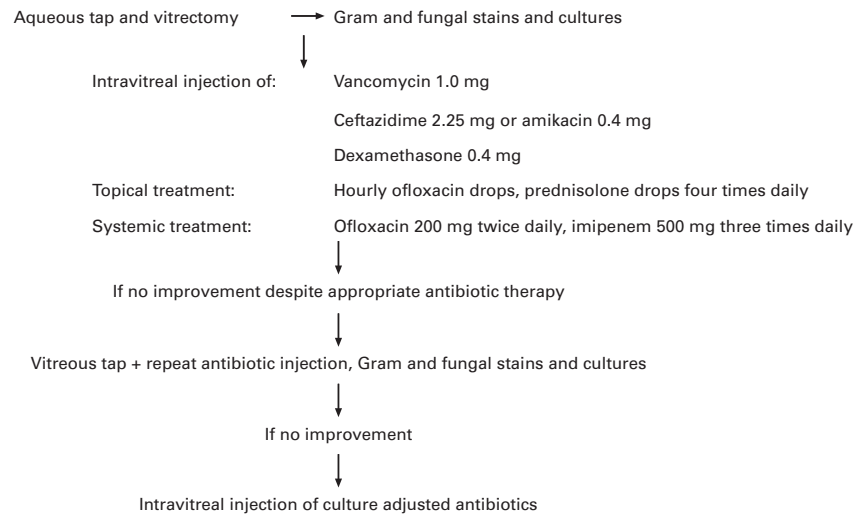


Figure 1 Treatment of postoperative endophthalmitis.

various preoperative antibiotic regimens, compared with no preoperative topical prophylaxis.<sup>116</sup> Of the topical antibiotics currently used, fluoroquinolones have a broader spectrum.<sup>117</sup> Because of the high mean inhibitory concentration (MIC 90) of this group of antibiotics against streptococci, three fluoroquinolones have been compared—ofloxacin has more activity in vitro against streptococcal species than ciprofloxacin and norfloxacin.<sup>118 119</sup> Donnenfeld *et al* compared the aqueous humour concentration of preoperatively applied topical ofloxacin, norfloxacin, and ciprofloxacin in 32 patients undergoing cataract surgery, and found ofloxacin to penetrate into the aqueous in a significantly greater amount than norfloxacin and ciprofloxacin.<sup>120</sup>

Dickey *et al* cultured anterior chamber aspirates of 30 patients who underwent uncomplicated ECLE and IOL treated with one application of gentamicin the day before surgery and found contamination in 43% of the patients, with coagulase negative staphylococci as the most commonly isolated organism.<sup>121</sup> King *et al* found a significant reduction in the incidence of positive anterior chamber cultures after cataract surgery when ofloxacin was applied 30–140 minutes every 5 minutes before surgery (5.3%).<sup>122</sup>

A similar result was recently obtained after the use of tobramycin 24 hours before phacoemulsification surgery. In this study, however, the low incidence of positive cultures is not related only to the topical antibiotic used preoperatively but could also depend on the surgical technique (phacoemulsification rather than ECLE).<sup>123</sup>

An alternative to topical antibiotics is currently being investigated and consists of antibiotic soaked collagen shields. In rabbits, this method of drug delivery has generally achieved intraocular levels comparable with or greater than those achieved by subconjunctival administration,<sup>124</sup> and this treatment modality seemed to be well tolerated in humans.<sup>125</sup> Before the widespread use of antibiotic soaked shields is advocated as routine preoperative treatment, further studies should confirm an absence of drug toxicity to the corneal epithelium or endothelium, particularly in sutureless cataract surgery.

#### SUBCONJUNCTIVAL INJECTION OF ANTIBIOTICS

Results of animal studies are in favour of prophylactic subconjunctival injections. High mean aqueous humour concentrations are found 10 hours after perilimbal injections, and treatment with ceftazidime, gentamicin, or

ciprofloxacin reduced the clinical infection in inoculated eyes after cataract extraction.<sup>126</sup>

The use of subconjunctival antibiotics at the end of the surgical procedure remains a much debated question. Kolker *et al* demonstrate that this route is better than no prophylaxis at all.<sup>127</sup> In the largest study of a periocular antibiotic regimen, conducted in an eye camp in Pakistan in the 1970s, 54 000 patients were examined; there was no significant difference between the 44 000 patients who did not receive subconjunctival prophylaxis and the 10 000 patients who received postoperative subconjunctival antibiotics.<sup>128</sup> However, some years later, the same author reported results from the same hospital indicating that the treatment with preoperative topical and postoperative subconjunctival antibiotics was better than the preoperative treatment of topical antibiotics alone.<sup>129</sup>

The controversy about the routine use of postoperative subconjunctival injections comes from several reports claiming inadvertent eye perforation while performing subconjunctival injection or the access of extraocular fluid to the anterior chamber (AC) with sutureless corneoscleral incision reaching toxic intraocular levels.<sup>130</sup> Results from experimental studies suggest that the time to achieve maximal and therapeutic levels in the AC is relatively long after a subconjunctival injection and, thus, has no effect on the contaminated corneoscleral incision and aqueous humour immediately at the end of surgery. This could further lead to a delay in the onset of the infection, and thus, increase the gravity of the endophthalmitis, leading to a poorer visual outcome.<sup>130</sup>

#### PROPHYLACTIC ANTIBIOTICS IN THE INFUSION CANNULA

Recently, particular interest has been shown in the use of antibiotics in the irrigation solution.<sup>131</sup> Rather than affecting the actual number of organisms entering the anterior chamber during surgery, the antibiotics administered continuously during surgery affected the viability of these organisms. No culture growth from anterior chamber aspirates at the end of uncomplicated phacoemulsification and IOL was reported after the use of gentamicin at 8 µg/ml.<sup>132</sup> In a large series of 11 748 cases of phacoemulsification and IOL using 8 µg/ml of gentamicin supplemented by 0.1 ml of vancomycin injected behind the IOL at the end of surgery, no endophthalmitis was reported.<sup>133</sup>

Nevertheless, toxicity persists as a major problem with the use of gentamicin. Although former studies did not show any evidence of ocular toxicity even at higher concentrations (80 µg/ml), this remains a major concern when aminoglycosides are used intraocularly.

Vancomycin appears to be not only particularly well suited for the treatment of established endophthalmitis as mentioned before, but also for routine prophylaxis during surgery. Gills describes the use of vancomycin at a concentration of 50 mg/ml in the phacoemulsification infusion fluid as an effective approach to the prevention of endophthalmitis, while Gimbel *et al* prefer to inject vancomycin behind the IOL at the end of surgery.<sup>131 133</sup> Intracameral concentrations of vancomycin administered via the infusion cannula at a concentration of 40 µg/ml reach sufficient MIC 90 levels for all Gram positive organisms, with a minimal endothelial cell loss, noted by specular microscopy.<sup>134</sup>

However, serious concerns about the prophylactic use of this drug emerged recently because of increased occurrence of vancomycin resistant organisms. Vancomycin resistant enterococcal infections increased from 0.3%–7.9% between 1989 and 1993.<sup>135</sup> Of major concern is the potential for plasmid borne resistance of vancomycin being transferred to other Gram positive organisms, including *Staph aureus* and *Staph epidermidis*.<sup>136</sup> The danger lies in the

fact that, at present, no other agent is available or clinically effective against vancomycin resistant organisms. The US Department of Health and Human Services, Centers for Disease Control and Prevention (CDC) has recently published recommendations for the use of vancomycin: their report cautions against its excessive use, in particular as a prophylactic treatment.<sup>137</sup> Their recommendations are particularly intended for surgical or high risk medical patients, but no straight guidelines are available concerning its use in ophthalmology. In light of the CDC's recommendations, it would appear that vancomycin should be avoided for empirical prophylactic postoperative treatment either topically, in the infusion cannula, or systemically. It should be reserved for the treatment of ocular infections resistant to other available antibiotics. However, our cataract patients, often operated in an ambulatory setting, do not correspond with the patients described by the CDC. Furthermore, the local use of vancomycin in the infusion cannula at low concentrations has little risk of spreading resistance. In our opinion, until the emergence of a new agent with less potential to resistance but with all the convenience of vancomycin, this latter antibiotic remains the best agent to be used in the infusion cannula. Meanwhile, ophthalmologists should be aware of this serious problem of emerging vancomycin resistance and should maintain an interest in the appropriate use of this drug.

Quinolones are currently being studied for use in the infusion cannula. No toxicity on ocular structures of the anterior segment has been found with concentrations up to 1200 µg.<sup>138</sup> Retinal toxicity after intravitreal injection of the drug is currently being evaluated. However, an increasing number of quinolone resistant organisms are being reported in the literature. Commercially available derivatives of quinolones may therefore not fulfil the requirements at present. New derivatives are under investigation.<sup>139</sup> However, before the use of quinolones in the infusion cannula can be advocated, the therapeutic concentration of the drug, with no toxicity to all ocular structures, should be determined.

Although this type of antibiotic treatment for prophylaxis of infection is approved by the majority of surgeons, some suggest that the antibiotic supplementation of intraoperative infusion is of questionable value and should be re-examined.<sup>140</sup> Indeed, endophthalmitis can occur despite the use of antibiotics in the infusion cannula.<sup>141</sup> Further experimental and clinical studies are needed to prove the usefulness of this prophylaxis, as well as to determine the best antibiotic to be used and its safety.

The surgical technique strongly affects the incidence of positive anterior chamber aspirates and the possibility of subsequent endophthalmitis. Of 103 patients undergoing uncomplicated cataract surgery using single instrument endocapsular phacoemulsification with scleral tunnel incision and IOL, anterior chamber aspirates showed positive cultures in five patients (5.15%).<sup>142</sup> Similar findings are reported by Egger *et al*; 7.6% of contaminated anterior chamber samples with the phacoemulsification method, compared with 28.2% after conventional ECLE and IOL.<sup>111</sup> The smaller surgical incision for phacoemulsification and the tunnelling design creating a self sealing valve prevent the entry of surrounding irrigation. Driebe *et al* found retrospectively inaccurate wound closure in 22% of 83 patients with endophthalmitis following cataract surgery.<sup>23</sup> Maxwell and Diamond stated that 60% of patients with endophthalmitis following sutureless cataract surgery had inadequate and non self sealing wounds.<sup>130</sup> A complicated cataract extraction with posterior capsular rupture and anterior vitrectomy has a four times higher probability of developing postoperative endophthalmitis: the organism easily penetrates the posterior segment in the

absence of the posterior capsule, which creates a barrier. The probability of endophthalmitis at 1 year reaches 0.58% in complicated surgery, compared with 0.14% in uncomplicated surgery.<sup>3</sup> Even if prophylactic subconjunctival antibiotics are used at the end of these procedures, their poor penetration into the vitreous cavity gives the organism the opportunity to react rapidly. Increased operating time and surgical manipulation further increase the risk of infection.<sup>143</sup>

Intraocular lenses represent a risk factor of infection; their electrostatic surface charge attracts the bacteria. The use of PMMA intraocular lenses may reduce the risk of endophthalmitis. The surface adhesion for bacteria of these lenses is lower than in lenses with polypropylene haptics.<sup>144</sup> However, a report states that 80% of previously sterile PMMA lenses were contaminated by contact with the bulbar conjunctiva.<sup>145</sup>

The advantage of small incision cataract surgery using foldable lenses has led to the development of new materials. Silicon lenses have in vitro a higher adhesion potential of bacteria compared with hydrogel or PMMA lenses.<sup>146</sup> To our knowledge, there is no controlled prospective study as yet comparing the incidence of endophthalmitis after the use of foldable intraocular implants with PMMA lenses.

Despite the use of prophylactic antibiotic treatment and preoperative instillation of povidone into the conjunctival fornix, the saprophytic conjunctival flora cannot be completely eradicated, and some organisms can easily be conveyed into the anterior chamber via the surgical wound during the operation, as showed by several studies mentioned earlier. Although positive AC aspirates have been found, mostly no cases will develop clinical endophthalmitis. It appears that the immune defence of the eye, including immunoglobulins circulating in the aqueous that neutralise bacteria and potentiate phagocytosis, the filtration capability of the trabecular meshwork, and the phagocytic ability of the endothelium lining the trabecular meshwork, is strong enough to combat common organisms when present at a relatively low level.<sup>147 148</sup> Although the specific threshold for some organisms in postoperative endophthalmitis is unknown, Samad *et al* postulate that the threshold for *Staph epidermidis* is greater than the 200 colony forming units per millilitre noted in their study.<sup>142</sup> Other studies confirm these data; preoperative cultures of anterior chamber aspirates show a low number of colonies which might be insufficient to overwhelm host immunity.<sup>132 149</sup> Studies in primates have shown that several thousands of colonies of *Staph epidermidis* are needed to induce endophthalmitis.<sup>149 150</sup> This threshold is dramatically reduced with the inoculation of Gram negative organisms.<sup>151 152</sup>

## Conclusion

Postoperative endophthalmitis remains a major concern after cataract surgery despite the availability of potent antibiotics with a large spectrum of activity. Several preoperative risk factors can predispose to an infection. Their early recognition may prevent a disastrous outcome. However, in some cases the infection seems impossible to foresee. Therefore, a careful patient selection and special attention to asepsis are mandatory. Further controlled prospective clinical trials are needed to evaluate the necessity of pre- or preoperative antibiotic prophylaxis, as well as the best drug to be used. Several studies are investigating new molecules with better antibacterial activity and less ocular toxicity. Until these results are available, the evaluation and therapeutic choice remain the surgeon's best judgment.

GORDANA SUNARIC-MÉGEVAND  
CONSTANTIN J POURNARAS

Clinique Universitaire d'Ophthalmologie, Rue Alcide-Jentzer 22,  
1205 Genève, Switzerland

- Adenis JP, Denis F, Colin J, Franco JL, Mounier M. *L'endophthalmie*. Paris: Edit Ellipses 1988:159.
- Salvanet-Bouccara A, Forestier F, Coscas G, Adenis JP, Denis F. Endophthalmies bactériennes. Résultats ophtalmologiques d'une enquête prospective multicentrique nationale. *J Fr Ophtalmol* 1992;15:669-78.
- Kattan HM, Flynn HW, Pflugfelder SC, Robertson C, Forster RK. Nosocomial endophthalmitis survey. *Ophthalmology* 1991;98:227-38.
- Javitt JC, Vitale S, Canner JK, Street DA, Krakauer H, McBean AM, *et al*. National outcome of cataract extraction. *Arch Ophthalmol* 1991;109:1085-9.
- Mandelbaum S, Forster RK, Gelender H, Culbertson W. Late onset endophthalmitis associated with filtering blebs. *Ophthalmology* 1985;92:964-72.
- Wolner B, Liebmann JM, Sassani JW, Ritch R, Speaker M, Marmor M. Late bleb-related endophthalmitis after trabeculectomy with adjunctive 5-fluorouracil. *Ophthalmology* 1991;98:1053-60.
- Mesham MP, Salmon JF. The use of 5-fluorouracil in trabeculectomy: dose, cystic blebs and endophthalmitis. *S Afr Arch Ophthalmol* 1992;17:24-7.
- Sunaric Mégevand G, Salmon JF. Late bleb-related endophthalmitis as a complication of trabeculectomy with mitomycin C. (Submitted for publication.)
- Higginbotham EJ, Stevens RK, Musch DC. Bleb-related endophthalmitis after trabeculectomy with mitomycin C. *Ophthalmology* 1996;103:650-6.
- Williams DL, Gills JP. Infectious endophthalmitis following sutureless cataract surgery (letter). *Arch Ophthalmol* 1992;110:913.
- Olson GC, Forster RK, Culbertson WW. Results in the treatment of postoperative endophthalmitis. *Ophthalmology* 1983;90:697-9.
- Endophthalmitis Vitrectomy Study Group. Results of the endophthalmitis vitrectomy study. A randomized trial of immediate vitrectomy and of intravenous antibiotics for the treatment of postoperative bacterial endophthalmitis. *Arch Ophthalmol* 1995;113:479-96.
- Speaker MG, Milch FA, Shah MK. The role of external bacterial flora in the pathogenesis of acute postoperative endophthalmitis. *Ophthalmology* 1991;98:639-49.
- Forster RK, Abbott RG, Gelender H. Management of infectious endophthalmitis. *Ophthalmology* 1980;87:313-9.
- Starr MB. Prophylactic antibiotics for ophthalmic surgery. *Surv Ophthalmol* 1983;27:353-73.
- Bannerman TL, Roden DL, McAllister SK, Miller JM, Wilson LA, for the Endophthalmitis Vitrectomy Study Group. The source of coagulase-negative staphylococci in the Endophthalmitis Vitrectomy Study. *Arch Ophthalmol* 1997;115:357-61.
- Vafidis GC, March RJ, Stacey AR. Bacterial contamination of intraocular lens surgery. *Br J Ophthalmol* 1984;68:520-3.
- Stern WH, Tamura E, Jacobs RA. Epidemic postsurgical candida parapsilosis endophthalmitis. Clinical findings and management of 15 consecutive cases. *Ophthalmology* 1985;92:1701-9.
- Crompton DO. Personal observations on the prevention of sepsis following lens extraction. In: Theodore FH ed. *Complications after cataract surgery*. Boston: Little, Brown, 1965:519.
- Theodore FH. Etiology and diagnosis of fungal postoperative endophthalmitis. *Ophthalmology* 1978;85:327-40.
- Pettit TH, Olson RJ, Foos RY. Fungal endophthalmitis following intraocular lens implantation, a surgical epidemic. *Arch Ophthalmol* 1980;98:1025-39.
- Egerer I, Sehorst W. Histopathologie der exogenen mycotischen Endophthalmitis. *Klin Monatsbl Augenheilkd* 1976;169:325-31.
- Driebe WT Jr, Mandelbaum S, Forster RK, Schwartz LK, Culbertson WW. Pseudophakic endophthalmitis. *Ophthalmology* 1986;93:442-8.
- Bode DD Jr, Gelender H, Forster RK. A retrospective review of endophthalmitis due to coagulase-negative staphylococci. *Br J Ophthalmol* 1985;69:915-9.
- Fong D, Pesavento RD. Pseudomonas endophthalmitis presenting as subacute inflammation (letter). *Arch Ophthalmol* 1995;113:265.
- Freedman J, Gupta M, Bunke A. Endophthalmitis after trabeculectomy. *Arch Ophthalmol* 1978;96:1017-8.
- Katz LJ, Cantor LB, Spaeth GL. Complications of surgery in glaucoma: early and late bacterial endophthalmitis following surgery. *Ophthalmology* 1985;92:959-63.
- Hattenhauer JM, Lipsich MP. Late endophthalmitis after filtering surgery. *Am J Ophthalmol* 1971;72:1097-101.
- Kanski JJ. Treatment of late endophthalmitis associated with filtering blebs. *Arch Ophthalmol* 1974;91:339-43.
- Tabbara KF. Late infections following filtering procedures. *Ann Ophthalmol* 1976;8:1228-31.
- Brown RH, Yang LH, Walker SD, Lynch MG. Treatment of bleb infection after glaucoma surgery. *Arch Ophthalmol* 1994;112:57-61.
- Bergstrom TJ, Wilkinson WS, Skuta GL. The effects of subconjunctival mitomycin C on glaucoma filtering surgery in rabbits. *Arch Ophthalmol* 1991;109:1725-30.
- Pasquale LR, Thibault D, Dorman Pease ME. Effect of topical mitomycin C on glaucoma filtration surgery in monkeys. *Ophthalmology* 1992;99:14-8.
- Moster MR, Costa VP, Wilson RP, Schmidt CM. Complications of topical intraoperative subconjunctival mitomycin C in glaucoma filtering surgery. *Invest Ophthalmol Vis Sci* 1993;34(suppl):730.
- Sunaric Mégevand G, Salmon JF, Scholtz RP, Murray ADN. The effect of reducing the exposure time of mitomycin C in glaucoma filtering surgery. *Ophthalmology* 1995;102:84-90.
- Pflugfelder SC, Flynn HW Jr, Zwickey TA, Forster RK, Tsiligianni A, Culbertson WW, *et al*. Exogenous fungal endophthalmitis. *Ophthalmology* 1988;95:19-30.
- Cummins CS, Johnson JL. Corynebacterium parvum: a synonym for Propionibacterium acnes. *J Gen Microbiol* 1974;80:433-42.
- Webster GF, Seyden JJ, Musson RA, Douglas SD. Susceptibility of Propionibacterium acnes to killing and degradation by human neutrophils and monocytes in vitro. *Infect Immun* 1985;49:116-21.
- Smith RE. Inflammation after cataract surgery. *Am J Ophthalmol* 1986;102:788-90.
- Cousins SW, Kraux-Mack E. Lens associated uveitis. In: Pepose JS, Holland GN, Wilhelmus KR, eds. *Ocular infections and immunity*. St Louis: Mosby 1995.

- 41 Winward KE, Pflugfelder SC, Flynn HW Jr. Postoperative propionibacter endophthalmitis. *Ophthalmology* 1993;100:447-51.
- 42 Fox G, Joondorph BC, Flynn HW Jr, Pflugfelder SC. Delayed onset pseudophakic endophthalmitis. *Am J Ophthalmol* 1991;111:163-73.
- 43 Walker J, Dangel ME, Makley TA, Opremac EM. Postoperative Propionibacterium granulosum endophthalmitis (letter). *Arch Ophthalmol* 1990;108:1073-4.
- 44 Meisler DM, Mandelbaum S. Propionibacterium associated endophthalmitis after extracapsular cataract extraction. Review of reported cases. *Ophthalmology* 1989;96:54-61.
- 45 Ormerod LD, Paton BG, Haaf J. Anaerobic bacterial endophthalmitis. *Ophthalmology* 1988;94:799-808.
- 46 Beatty RF, Robin JB, Trousdale MD. Anaerobic endophthalmitis caused by Propionibacterium acnes (letter). *Am J Ophthalmol* 1986;101:114-6.
- 47 Hunter JW. Early postoperative sterile hypopyons. *Br J Ophthalmol* 1978;62:470-473.
- 48 Stark WJ, Rosenblum P, Maumenee AE. Postoperative reactions to intraocular lens sterilized with ethylene oxide. *Ophthalmology* 1980;87:385-9.
- 49 Holyk PR, Eifrig DE. Effects of monomeric methylmethacrylate on ocular tissues. *Am J Ophthalmol* 1979;88:385-95.
- 50 Galin MA, Tuberville AW, Obstbaum SA. Mechanism of implant inflammation. *Trans Ophthalmol Soc UK* 1980;100:229-30.
- 51 Apple DJ, Mammalis N, Steinmetts RL. Phacoanaphylactic endophthalmitis associated with extracapsular cataract extraction and posterior chamber intraocular lens. *Arch Ophthalmol* 1984;102:1528-32.
- 52 Melther DW. Sterile hypopyon following intraocular lens surgery. *Arch Ophthalmol* 1982;98:100-4.
- 53 Irvine WD, Flynn HW Jr, Murray TG. Retained lens fragments after phacoemulsification manifesting as marked intraocular inflammation with hypopyon. *Am J Ophthalmol* 1992;114:610-4.
- 54 Kim JE, Flynn HW, Rubsam PE. Endophthalmitis in patients with retained lens fragments after phacoemulsification. *Ophthalmology* 1996;103:575-8.
- 55 Fahmy JA, Moller S, Weis Bentzon M. Bacterial flora in relation to cataract extraction. I. Material, methods and preoperative flora. *Acta Ophthalmol* 1975;53:458-75.
- 56 Driebe WT Jr, Mandelbaum S, Forster RK, Schwartz LK, Culbertson WW. Pseudophakic endophthalmitis: diagnosis and management. *Ophthalmology* 1986;93:442-8.
- 57 Donahave S, Kowalski R, Jewart B. Vitreous cultures in suspected endophthalmitis. Biopsy or vitrectomy. *Ophthalmology* 1993;100:452-9.
- 58 Heaven CJ, Mann PJ, Boase DL. Endophthalmitis following extracapsular cataract surgery: a review of 32 cases. *Br J Ophthalmol* 1992;76:419-23.
- 59 Hughes DS, Hill RJ. Infectious endophthalmitis after cataract surgery. *Br J Ophthalmol* 1994;78:227-32.
- 60 Doft B, Donnelly K. A single sclerotomy vitreous biopsy technique in endophthalmitis. *Arch Ophthalmol* 1991;109:465.
- 61 Levin MR, D'Amico DJ. Traumatic endophthalmitis. In: Shingleton BJ, Hersh PS, Kenyon KR, eds. *Eye trauma*. St Louis: Mosby, 1991:242.
- 62 Nobe JR, Gomez DS, Liggett P. Post-traumatic and postoperative endophthalmitis: a comparison of visual outcome. *Br J Ophthalmol* 1987;71:614-7.
- 63 Barza M. Factors affecting the intraocular penetration of antibiotics. *Scand J Infect Dis (Suppl)* 1978;14:151-9.
- 64 Peyman GA, Herbst R. Bacterial endophthalmitis. *Arch Ophthalmol* 1974;91:416-8.
- 65 Peyman GA, May DR, Ericson ES, Apple D. Intraocular injection of gentamicin. *Arch Ophthalmol* 1974;92:42-7.
- 66 Peyman GA. Antibiotic administration in the treatment of bacterial endophthalmitis. II Intraocular injections. *Surv Ophthalmol* 1977;21:332-46.
- 67 D'Amico DJ, Caspers-Velu L, Libert J. Comparative toxicity of intravitreal aminoglycoside antibiotics. *Am J Ophthalmol* 1985;100:264-75.
- 68 Conway BP, Tabatabay CA, Campochiaro PA. Gentamicin toxicity in the primate retina. *Arch Ophthalmol* 1989;107:107-12.
- 69 Campochiaro PA, Conway BP. Aminoglycoside toxicity—a survey of retinal specialists. *Arch Ophthalmol* 1991;109:946-50.
- 70 Campochiaro PA, Lim JJ. Aminoglycoside toxicity in the treatment of endophthalmitis. *Arch Ophthalmol* 1994;112:48-53.
- 71 Campochiaro PA, Green WT. Toxicity of intravitreal ceftazidime in primate retina. *Arch Ophthalmol* 1992;110:1625-9.
- 72 Pflugfelder JC, Hernandez E, Fliesler SJ. Intravitreal vancomycin. Retinal toxicity, clearance and interaction with gentamicin. *Arch Ophthalmol* 1987;105:831-7.
- 73 Fiscella RG. Physical incompatibility of vancomycin and ceftazidime for intravitreal injection (letter). *Arch Ophthalmol* 1993;111:730.
- 74 Mauger TF, Craig EL. Pharmacokinetics. In: Craven L, ed. *Havener's ocular pharmacology*. St Louis: Mosby, 1994:22-52.
- 75 Phillips WB, Wong TP, Gergren RL. Late onset endophthalmitis associated with filtering blebs. *Ophthalmol Surg* 1994;25:88-91.
- 76 Stern GA, Engel HM, Driebe WT Jr. Recurrent postoperative endophthalmitis. *Cornea* 1990;9:102-7.
- 77 Irvine WD, Flynn HW Jr, Amiller D, Pflugfelder SC. Endophthalmitis caused by gram-negative organisms. *Arch Ophthalmol* 1991;110:1450-4.
- 78 Shaarawy A, Grand MG, Meredith TA. Persistent endophthalmitis after intravitreal antimicrobial therapy. *Ophthalmology* 1995;102:382-7.
- 79 Fox GM, Joondorph BC, Flynn HW Jr. Delayed-onset pseudophakic endophthalmitis. *Am J Ophthalmol* 1991;111:163-73.
- 80 Davey PG, Barza M, Stuart M. Dose response of experimental pseudomonas endophthalmitis to ciprofloxacin, gentamicin and imipenem: evidence for resistance to late treatment of infections. *J Infect Dis* 1987;155:518-23.
- 81 Doft BH, Weiskopf J, Nilsson-Ehle I. Amphotericin clearance in vitrectomized versus nonvitrectomized eyes. *Ophthalmology* 1985;92:1601-5.
- 82 Stern GA. Factors affecting the efficacy of antibiotics in the treatment of experimental postoperative endophthalmitis. *Trans Am Ophthalmol Soc* 1993;91:775-844.
- 83 Marrakchi-Benjaafar S, Cochereau I, Pocardalo J-J, Carbon C. Systemic prophylaxis of experimental staphylococcal endophthalmitis: comparative efficacy of sparfloxacin, pefloxacin, imipenem, vancomycin and amikacin. *J Infect Dis* 1995;172:1312-6.
- 84 Bloome MA, Golden B, McKee AP. Antibiotic concentration in ocular tissues. *Arch Ophthalmol* 1970;83:78.
- 85 Records RE. The human intraocular penetration of sodium methicillin. *Arch Ophthalmol* 1966;76:720-2.
- 86 Records RE. Human intraocular penetration of sodium oxacillin. *Arch Ophthalmol* 1967;7:693-5.
- 87 Goldman EE, McLain JH, Smith JL. Penicillins and aqueous humor. *Am J Ophthalmol* 1968;65:717-21.
- 88 Murphy S, Pinney RJ. Teicoplanin or vancomycin in the treatment of gram-positive infections? *J Clin Pharm Ther* 1995;20:5-11.
- 89 Wood MJ. The comparative efficacy and safety of teicoplanin and vancomycin. *J Antimicrob Chemother* 1996;37:209-22.
- 90 Garcia-Leoni ME, Diaz MD, Sanchez-Carrillo C. Emergence of teicoplanin-resistant coagulase-negative staphylococci. *J Clin Microbiol* 1996;34:1765-8.
- 91 Louria DB, Dineen P. Amphotericin B in the treatment of disseminated moniliasis. *JAMA* 1960;174:273-5.
- 92 Axelrod AJ, Peyman GA, Apple DJ. Toxicity of intravitreal injection of amphotericin B. *Am J Ophthalmol* 1973;76:578-3.
- 93 Green WR, Bennett JE, Goos RD. Ocular penetration of amphotericin B. A report of laboratory studies and a case report of post-surgical cephalosporin endophthalmitis. *Arch Ophthalmol* 1965;73:769.
- 94 Gallis HA, Drew RH, Pickard WW. Amphotericin B: 30 years of clinical experience. *Rev Inf Dis* 1990;12:308-29.
- 95 Souri EN, Green R. Intravitreal amphotericin B toxicity. *Am J Ophthalmol* 1974;78:77-81.
- 96 Savani DV, Perfect JR, Cobo LM. Penetration of new azole compounds in the eye and efficacy in experimental Candida endophthalmitis. *Antimicrob Agents Chemother* 1987;31:6-10.
- 97 Abe M, Ishikawa H. Ocular penetration of fluconazole. *J Eye* 1991;8:1479-81.
- 98 Sunaric Mégevand G, Pournaras CJ. Intravitreal pharmacokinetic and retinal toxicity of fluconazole (abstract). *Invest Ophthalmol Vis Sci* 1996;37(suppl):777.
- 99 Mauger T. Antifungals. In: Mauger TF, Craig EL, eds. *Havener's ocular pharmacology*. St Louis: Mosby-Year Book, 1994; chap 6:313-24.
- 100 Park SS, D'Amico DJ, Paton B, Barker AS. Treatment of exogenous candida endophthalmitis in rabbits with oral fluconazole. *Antimicrob Agents Chemother* 1995;39:958-63.
- 101 Zambrano W, Flynn HW, Pflugfelder SC. Management options for propionibacterium acnes endophthalmitis. *Ophthalmology* 1989;96:1100-5.
- 102 Zachary IG, Forster RK. Experimental intravitreal gentamicin. *Am J Ophthalmol* 1976;82:604-11.
- 103 Peyman GA, Vastine DW, Raichand M. Postoperative endophthalmitis: experimental aspects and their clinical application. *Ophthalmology* 1978;85:374-85.
- 104 Cottingham AJ, Forster RK. Vitrectomy in endophthalmitis. *Arch Ophthalmol* 1976;94:2078-81.
- 105 Stern GA, Engel HM, Driebe NT. The treatment of postoperative endophthalmitis. *Ophthalmology* 1989;96:62-7.
- 106 Packer AJ, Weingest TA. Retinal periphlebitis as an early sign of bacterial endophthalmitis. *Am J Ophthalmol* 1983;96:66-71.
- 107 Auclin F, Ullern M. Inéret des corticoïdes dans le traitement de l'endophthalmitis postopératoire. *J Fr Ophthalmol* 1993;16:446-52.
- 108 Baum JL, Barza M, Lugar J. The effect of corticosteroids in the treatment of experimental bacterial endophthalmitis. *Am J Ophthalmol* 1975;80:513-7.
- 109 Cole HP, Stallman J, Diamon DJ. High dose intravitreal dexamethasone for infectious endophthalmitis. *Invest Ophthalmol Vis Sci* 1989;30:509-12.
- 110 Egger SF, Huber-Spitz V, Scholda C, Schneider B, Grabner G. Bacterial contamination during extracapsular cataract extraction. *Ophthalmologica* 1994;208:77-81.
- 111 Caldwell DR, Kastl PRR, Cook J, Simon J. Povidone-iodine: its efficacy as a preoperative conjunctival and perioperative preparation. *Ann Ophthalmol* 1984;16:577-80.
- 112 Apt L, Isenberg SJ, Yoshimori R, Paez JH. Chemical preparation of the eye in ophthalmic surgery. III Effect of povidone-iodine on the conjunctiva. *Arch Ophthalmol* 1984;102:728-9.
- 113 Isenberg SJ, Apt L, Yoshimori R, Khwarg S. Chemical preparation of the eye in ophthalmic surgery. IV Comparison of povidone-iodine on the conjunctiva with a prophylactic antibiotic. *Arch Ophthalmol* 1985;103:1340-2.
- 114 Speaker MG, Menikoff JA. Prophylaxis of endophthalmitis with topical povidone-iodine. *Ophthalmology* 1991;98:639-49.
- 115 Sagers BA, Stewart GT. Polyvinyl-pyrrolidone-iodine: an assessment of antibacterial activity. *J Hyg* 1964;62:509-18.
- 116 Allen HF, Mangiaracine AB. Bacterial endophthalmitis after cataract extraction. II Incidence in 36000 consecutive operations with special reference to preoperative topical antibiotics. *Arch Ophthalmol* 1974;91:3-7.
- 117 Gwon L. Topical ofloxacin compared with gentamicin in the treatment of external ocular infections. *Br J Ophthalmol* 1992;76:714-8.
- 118 Goldstein EJ, Citron DM, Bendon L. Potential of topical norfloxacin therapy. *Arch Ophthalmol* 1987;105:991-4.
- 119 Shingu DL, Tutlane VK, Weinberg E. In vitro antibacterial activity of norfloxacin and other agents against ocular pathogens. *Chemotherapy* 1985;31:112-8.
- 120 Donnenfeld ED, Schrier A, Perry HD. Penetration of topically applied ciprofloxacin, norfloxacin, and ofloxacin into the aqueous humor. *Ophthalmology* 1994;101:902-5.
- 121 Dickey JB, Thompson D, Jay WM. Anterior chamber aspirate cultures after uncomplicated cataract surgery. *Am J Ophthalmol* 1991;112:278-82.
- 122 King KM, Thompson KD, Boucharde GS. Anterior chamber aspirate culture following uncomplicated cataract surgery in patients pretreated with topical ofloxacin (abstract). *Invest Ophthalmol Vis Sci* 1993;34:884.
- 123 Amdahl LD, Osher RH, Cheetham JK. The antibacterial activity and intraocular availability of trimethoprim-polymyxin B versus tobramycin in cataract patients (abstract). *Invest Ophthalmol Vis Sci* 1993;34:884.
- 124 Alaranta S, Oksala O, Mahlberg K, Siirilä M, Mali M. Drug delivery into the rabbit eye. Collagen shields soaked with gentamicin compared with subconjunctival injections (abstract). *Invest Ophthalmol Vis Sci* 1993;34:1488.
- 125 Renard G, Bennami N, Lutaj P, Richard C, Trinquand C. Comparative study of a collagen corneal shield and subconjunctival injection at the end of cataract surgery. *J Cataract Refract Surg* 1993;19:48-51.

- 126 Behrens-Baumann W, Martell J. Ciprofloxacin concentration in the rabbit aqueous humor and vitreous following intravenous and subconjunctival administration. *Infection (Munich)* 1988;**16**:55-7.
- 127 Kolker AE, Freeman MI, Pettit TH. Prophylactic antibiotics and postoperative endophthalmitis. *Am J Ophthalmol* 1967;**63**:434-9.
- 128 Christy NE, Lall P. Postoperative endophthalmitis following cataract surgery. *Arch Ophthalmol* 1973;**90**:361-6.
- 129 Christy NE, Sommer A. Antibiotic prophylaxis of postoperative endophthalmitis. *Ann Ophthalmol* 1979;**11**:1261-5.
- 130 Maxwell DP, Diamond JG. Infectious endophthalmitis following sutureless cataract surgery (letter). *Arch Ophthalmol* 1992;**110**:915.
- 131 Gills JP. Filters and antibiotics in irrigating solution for cataract surgery. *J Cataract Refract Surg* 1991;**17**:385.
- 132 Dickey J, Thompson KD, Jay WM. Intraocular gentamicin sulfate and postcataract anterior chamber aspirate cultures. *J Cataract Refract Surg* 1994;**20**:373-7.
- 133 Gimbel HV, Sun R, De Brof BM. Prophylactic intracameral antibiotics during cataract surgery: the incidence of endophthalmitis and corneal endothelial cell loss. *Eur J Implant Refract Surg* 1994;**6**:280-5.
- 134 Bron A. Tolérance cornéenne et biodisponibilité de la vancomycine utilisée dans le liquide d'irrigation lors de la chirurgie de cataracte. Personal communication. Congrès de la Société Française d'Ophthalmologie, Paris 1996.
- 135 Hospital Infection Control Practices Advisory Committee (HICAC). Recommendations for preventing the spread of vancomycin resistance. *Infect Control Hosp Epidemiol* 1995;**162**:105-13.
- 136 Fiscella RG. Vancomycin use in ophthalmology. *Arch Ophthalmol* 1995;**113**:1353-4.
- 137 Centers for Disease Control and Prevention. Preventing the spread of vancomycin resistance. Report from the Hospital Infection Control Practices Advisory Committee, 59 Federal register 25, 757 (1994).
- 138 Von Gunten S, Rungger-Brändle E, Gilodi N, Leuenberger P. Corneal toxicity of Ofloxacin after injection or perfusion into the anterior chamber in pigmented rabbit eyes (abstract). *Invest Ophthalmol Vis Sci* 1996;**37**(suppl):874.
- 139 Ng EWM, Samiy N, Ruoff K, Paton B, Hooper DC, D'Amico DS, et al. Ocular pharmacokinetics of oral CP 99,219 in a rabbit model of Staphylococcus epidermidis endophthalmitis (abstract). *Invest Ophthalmol Vis Sci* 1996;**37**(suppl):776.
- 140 Gritz DC, Cevallos AV, Smoin G, Whithagher JP. Antibiotic supplementation of intraoperative infusions (abstract). *Invest Ophthalmol Vis Sci* 1995;**36**(suppl):154.
- 141 Townsend-Pico WA, Meyers SM, Langston RH. Coagulase-negative Staphylococcus endophthalmitis after cataract surgery with intraocular vancomycin. *Am J Ophthalmol* 1996;**121**:318-9.
- 142 Samad A, Solomon LD, Miller MA. Anterior chamber contamination after uncomplicated phacoemulsification and intraocular lens implantation. *Am J Ophthalmol* 1995;**120**:143-50.
- 143 Menikoff JA, Speaker MG, Marmor M, Raskin EM. A case control study of risk factors for postoperative endophthalmitis. *Ophthalmology* 1991;**98**:1761-8.
- 144 Raskin E, Speaker MG, McCormick SA, Wong D, Menikoff JA. Influence of haptic materials on the adherence of staphylococci to intraocular lenses. *Arch Ophthalmol* 1993;**111**:250-3.
- 145 Doyle A, Beigi B, Early A. Adherence of bacteria to intraocular lenses: a prospective study. *Br J Ophthalmol* 1995;**79**:347-9.
- 146 Cusumano A, Busin M, Spitznas M. Bacterial growth is significantly enhanced on foldable intraocular lenses. *Arch Ophthalmol* 1994;**112**:1015-6.
- 147 Chrisholm IA, Grierson I. Particulate phagocytosis by trabecular meshwork endothelium. *Can J Ophthalmol* 1973;**12**:293-9.
- 148 Grierson I, Lee WR. Erythrocyte phagocytosis in the trabecular meshwork. *Br J Ophthalmol* 1973;**57**:400-6.
- 149 Chitkara DK, Manners T, Chapman F, Stoddart MG, Hill D, Jenkins D. Lack of effect of preoperative norfloxacin on bacterial contamination of anterior chamber aspirates after cataract surgery. *Br J Ophthalmol* 1994;**78**:772-4.
- 150 Records RE, Iwen PC. Experimental bacterial endophthalmitis following extracapsular lens extraction. *Exp Eye Res* 1989;**49**:729-37.
- 151 Beyer TL, Bogler G, Sharma D, O'Donnell FE. Potent barrier effect of the posterior lens capsule in exogenous bacterial endophthalmitis: an experimental primate study. *Invest Ophthalmol Vis Sci* 1984;**25**:108-12.
- 152 Beyer TL, O'Donnell FE, Goncalves V, Siggh R. Role of posterior capsule in prevention of postoperative endophthalmitis: experimental primate studies and clinical implications. *Br J Ophthalmol* 1985;**69**:841-6.



## Current approach to postoperative endophthalmitis

GORDANA SUNARIC-MÉGEVAND and CONSTANTIN J POURNARAS

*Br J Ophthalmol* 1997 81: 1006-1015

doi: 10.1136/bjo.81.11.1006

---

Updated information and services can be found at:

<http://bjo.bmj.com/content/81/11/1006.full.html>

---

*These include:*

### References

This article cites 130 articles, 50 of which can be accessed free at:

<http://bjo.bmj.com/content/81/11/1006.full.html#ref-list-1>

### Email alerting service

Receive free email alerts when new articles cite this article. Sign up in the box at the top right corner of the online article.

---

### Topic Collections

Articles on similar topics can be found in the following collections

[Choroid](#) (434 articles)

[Eye \(globe\)](#) (538 articles)

[Ophthalmologic surgical procedures](#) (962 articles)

[Lens and zonules](#) (638 articles)

---

### Notes

---

To request permissions go to:

<http://group.bmj.com/group/rights-licensing/permissions>

To order reprints go to:

<http://journals.bmj.com/cgi/reprintform>

To subscribe to BMJ go to:

<http://group.bmj.com/subscribe/>