

Surgical management of macular holes: results using gas tamponade alone, or in combination with autologous platelet concentrate, or transforming growth factor β 2

M Minihan, M Goggin, P E Cleary

Abstract

Background—Vitreotomy and gas tamponade has become a recognised technique for the treatment of macular holes. In an attempt to improve the anatomic and visual success of the procedure, various adjunctive therapies—cytokines, serum, and platelets—have been employed. A consecutive series of 85 eyes which underwent macular hole surgery using gas tamponade alone, or gas tamponade with either the cytokine transforming growth factor β 2 (TGF- β 2) or autologous platelet concentrate is reported.

Methods—Twenty eyes had vitrectomy and 20% SF₆ gas tamponade; 15 had vitrectomy, 20% SF₆ gas, and TGF- β 2; 50 had vitrectomy, 16% C₃F₈ gas tamponade, and 0.1 ml of autologous platelet concentrate prepared during the procedure.

Results—Anatomic success occurred in 86% of eyes, with 96% of the platelet treated group achieving closure of the macular hole. Visual acuity improved by two lines or more in 65% of the SF₆ only group, 33% of those treated with TGF- β 2, and in 74% of the platelet treated group. In the platelet treated group 40% achieved 6/12 or better and 62% achieved 6/18 or better. The best visual results were obtained in stage 2 holes.

Conclusion—Vitreotomy for macular holes is often of benefit and patients may recover good visual acuity, especially early in the disease process. The procedure has a number of serious complications, and the postoperative posturing requirement is difficult. Patients need to be informed of such concerns before surgery.

(*Br J Ophthalmol* 1997;81:1073-1079)

Department of
Ophthalmology, Cork
University Hospital
and University College
Cork, Wilton, Cork,
Ireland
M Minihan
M Goggin
P E Cleary

Correspondence to:
Ms Miriam Minihan,
Department of
Ophthalmology, Cork
University Hospital, Wilton,
Cork, Ireland.

Accepted for publication
13 August 1997

vitreous cortex, and by epiretinal membranes, especially in a tangential manner.

Before the use of vitrectomy for the treatment of macular holes, it was believed that a technique which would promote flattening of the small rim of retinal detachment surrounding the macular hole, would inevitably lead to an improvement in visual acuity. Spontaneous flattening has been reported in rare circumstances.³ Laser photocoagulation was employed in an attempt to flatten this detached area,⁴ but its destructive properties have precluded its use in this vision sensitive area.

Macular hole surgery has become defined as an accepted technique since Kelly and Wendel⁵ first reported the benefit of pars plana vitrectomy and gas tamponade in inducing closure of macular holes, flattening of the neurosensory rim, and improvement in visual acuity. Since then, a variety of techniques have been reported in an attempt to improve the anatomic and visual results. These include the use of wound healing substances, cytokines, to promote closure of the macular hole. Glaser *et al*⁶ reported a 90-100% success rate in the closure of macular holes using the cytokine transforming growth factor β 2 (TGF- β 2).

Other growth promoting substances, such as serum⁷ and platelets,⁸ have been used in an attempt to improve the anatomic and visual success of macular hole surgery. However, the clinical decision of when and if to operate is still not clearly defined.⁹ Some recommend surgery for unocular cases only.¹⁰ Nevertheless, impressive visual results have been reported in some series, although it is not yet possible to identify preoperatively those patients capable of worthwhile visual improvement.

We report a consecutive series of 85 eyes, and document results and complications in an attempt to better define indications for surgery. We describe three groups—those treated with vitrectomy and gas tamponade only; those treated with vitrectomy, gas tamponade, and TGF- β 2; and a prospective trial of vitrectomy, gas tamponade, and autologous platelet concentrate.

Subjects and methods

We report on 85 procedures in 75 patients. Two patients had both eyes operated, and eight procedures were reoperations. Patients were included in the study if they had a visual acuity

Idiopathic macular holes may cause significant reduction in visual acuity. They are relatively common, particularly in women,¹ in the seventh and eighth decades of life. Visual reduction may be due to dehiscence at the umbo, loss of retinal tissue in the hole, and detachment of the neurosensory retina surrounding the hole.

Gass² has suggested that macular holes are the result of a dehiscence of the retina at the macula, and that this dehiscence is due to tractional forces on the macula by the prefoveal

of 6/18 or worse, no other significant ocular disease, and had symptoms for less than 1 year. Preoperatively, a complete ocular examination was performed, including best corrected Snellen visual acuity, intraocular pressure measurement, assessment of lens clarity, slit lamp biomicroscopy, contact lens examination of the fundus, and fundus fluorescein angiography. All patients had preoperative confrontational visual field examination and patients in the platelet treated group had suprathreshold Humphrey visual field testing.

Fifty nine (79%) patients were female and 16 (21%) male. They ranged in age from 23 to 85, mean 65 years. The macular holes were staged according to the criteria outlined by Gass.^{2 11} There were 20 (23.5%) stage 2, 45 (53%) stage 3, and 20 (23.5%) stage 4 holes. This staging was confirmed at the time of surgery. There was no statistical difference in the proportions of different stages in the different treatment groups. One case was a traumatic macular hole, all others were idiopathic. Preoperative visual acuity ranged from 6/18 to 1/60. All patients received an information leaflet preoperatively, and the importance of postoperative posturing was reiterated during their inpatient stay.

Three port trans pars plana vitrectomy was performed in all eyes. In stage 2 and 3 holes, the posterior hyaloid was detached and vitreous removed as far out to the periphery as possible. In stage 4 holes, posterior vitreous detachment was confirmed using aspiration with a silicone tipped needle. Before air/fluid exchange, all patients underwent careful examination of the peripheral fundus to discover any induced retinal tears. Following air/fluid exchange, 10 minutes were allowed for peripheral fluid to drain posteriorly. This fluid was then aspirated and an air-gas exchange was performed. The intraocular gas used was either 20% SF₆ or 16% C₃F₈ depending on which group the patient fell into.

Twenty eyes were treated with 20% SF₆ gas tamponade alone. Patients then postured prone for 7–10 days. Fifteen eyes received 1000 ng of porcine TGF-β2 in 0.1 ml of balanced salt solution under air at the macula, followed by air/gas exchange using 20% SF₆ gas. These patients postured supine for 6 hours then prone for at least 10 days. Fifty eyes had 0.1 ml of autologous platelet concentrate placed on the macula followed by air/16% C₃F₈ gas tamponade. These patients postured supine for 6 hours, then prone for 2–4 weeks.

In the SF₆ and SF₆ + TGF-β groups, fluid was drained through the hole and a search was made for epiretinal membranes around the hole with a membrane pick, sometimes producing nerve fibre layer haemorrhages. In the C₃F₈ + platelets group, which formed a prospective trial, we followed a standard procedure as proposed by Glaser in which fluid was not drained and no membranes were peeled.

Platelets were prepared in the manner described by Gaudric *et al.*⁸ Immediately before the procedure, 40 ml of venous blood was taken from the patient. This was mixed gently with 6 ml of acid citrate dextrose

(ACD). The mixture was then centrifuged at 280 g for 15 minutes and the platelet rich plasma decanted. The plasma was mixed with 1/8 volume ACD and further centrifuged at 1000 g for 10 minutes. The packed platelets were then mixed with 0.6 ml of sodium chloride to achieve a platelet suspension. The preparation of platelets was performed entirely in the operating theatre.

Patients were advised to continue to posture at home for up to 4 weeks postoperatively, and were contacted by telephone to encourage posturing.

All patients have a minimum follow up of 6 months. Postoperative assessment was carried out at 1, 3, 6, and 12 months postoperatively, and included best corrected Snellen visual acuity, intraocular pressure measurement, assessment of lens clarity, slit lamp biomicroscopy, contact lens examination of the fundus, and suprathreshold Humphrey visual field examination.

Results were analysed statistically using Student's *t* testing and χ^2 analysis. Visual acuity measurements were converted to logMAR to compare means.

Results

Postoperatively, there was zero to mild anterior chamber activity. In the platelet treated group, in the immediate postoperative period, a white 'coagulum' was visible over the posterior pole and covering the macular hole, and this material slowly disappeared over the subsequent 1–2 weeks.

Cases were deemed an anatomic success if the subretinal fluid surrounding the hole resolved and the retina flattened. The macular hole was closed in 15 (75%) eyes treated with SF₆ gas alone; in 10 (66%) eyes treated with SF₆ gas and TGF-β2; and in 48 (96%) eyes treated with C₃F₈ gas and platelet concentrate (Table 1). The rate of anatomic success in the C₃F₈ + platelet concentrate group was significantly better than either the SF₆ + TGF-β group (Fisher's exact: *p*=0.017, confidence interval (CI) 0.01–0.89), or the SF₆ only group (Fisher's exact: *p*=0.005, CI:0.01–0.63). Eighteen (90%) stage 2, 39 (86%) stage 3, and 16 (80%) stage 4 holes were an anatomic success. There was no statistical difference in the anatomic success rates of the different stages.

Table 1 Anatomic results

	Closed, no edge	Flat, with edge	Open	Total
SF ₆	10	5	5	20
SF ₆ +TGF-β	6	4	5	15
C ₃ F ₈ + platelets	46	2	2	50
Total	62	11	12	85

C₃F₈ + platelets *v* SF₆ +/-TGF-β2: better surgical results *p*=0.01.

Table 2 Visual outcome of different staged holes

	6/12 or better	6/18 or better	VA increase, 2 lines or more	VA increase, 4 lines or more
Stage 2	12	11	14	4
Stage 3	14	24	29	12
Stage 4	3	5	10	5

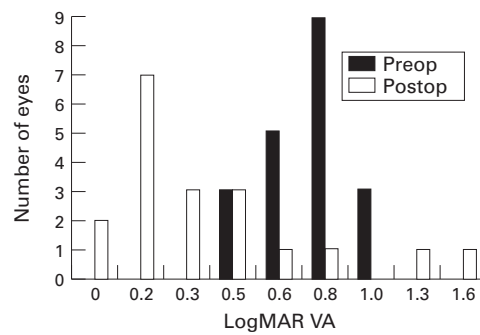


Figure 1 Pre and postoperative logMAR visual acuity of stage 2 holes.

Postoperative visual acuity ranged from 6/6 to counting fingers. Best visual results were in those eyes with stage 2 holes, 60% of these eyes achieved final visual acuity of 6/12 or better. Visual acuity improved by two lines or more in 14 (70%) stage 2, 29 (64%) stage 3, and 10 (55%) stage 4 holes (Table 2). Mean logMAR visual acuity postoperatively was better (Student's *t* test) in stage 2 holes than either stage 3 ($p=0.02$) or stage 4 ($p=0.004$) holes. Of successful cases, stage 2 holes are more likely than either stage 3 (Fisher's exact: $p=0.012$) or stage 4 (Fisher's exact: $p=0.004$) to achieve a final visual acuity of 6/9 or better (Fig 1). Overall, 36% of eyes had visual acuity of 6/12 or better postoperatively, and 54% had 6/18 or better. Visual acuity improved by two lines or more in 13 (65%) of eyes which had SF₆ gas tamponade alone, in five (33%) eyes with SF₆ gas and TGF- β 2; and in 37 (74%) of the platelet treated group (Table 3). Rate of two line improvement in the platelet treated group was significantly better than in the SF₆ + TGF- β 2 group (χ^2 : $p=0.0004$, CI: 0.03-0.44), but no significant difference existed between the C₃F₈ + platelet group and the SF₆ only group (χ^2 : $p=0.6$, CI: 0.19-2.39). At all levels visual results were worse in the TGF- β 2 treated group.

Eight procedures were reoperations for previously failed surgery. Although the anatomic success rate of these procedures was 75% (six of eight), only two (25%) improved by two lines or more in visual acuity. Best visual acuity after a second procedure was 6/24, and this group of eyes had significantly worse visual results than those with one operation only ($p<0.001$). Five eyes (6%) developed retinal tears intraoperatively, three (3%) developed rhegmatogenous retinal detachments postoperatively. Three eyes had splinter haemorrhages in the nerve fibre layer at the optic disc intraoperatively. In two eyes (2%), a previously closed macular hole reopened. One eye had optic atrophy postoperatively.

Twenty two patients have been found to have temporal or inferotemporal visual field loss

postoperatively. All three eyes with optic disc haemorrhage during surgery had postoperative visual field loss. Of those with visual field loss, six had SF₆ gas tamponade and 16 had C₃F₈ gas tamponade, 17 required posterior hyaloid stripping (stage 2 or stage 3), and five already had posterior vitreous detachment (stage 4). Lens opacities have progressed to cause significant cataracts in 33 patients to date. Abnormalities were present at the macula in a number of eyes with an anatomically successful outcome. Twelve (14%) had radial striae emanating from the closed hole, which tended to disappear after about 6 weeks. There was no significant difference in visual outcome in eyes with or without radial striae. Focal retinal pigmentary changes, most commonly a pigment spot was present in 20 (24%) eyes. This pigmentary change was more likely to occur in the platelet treated group than in either of the other groups ($p=0.048$ and $p=0.025$). Mean visual outcome was not significantly different between eyes with or without this pigment hypertrophy. Ten (12%) eyes had fine epiretinal membranes, not causing distortion or affecting vision, postoperatively.

In 11 eyes the edge of the macular hole was still visible postoperatively, despite closure of the hole. This edge was less likely to be present in the platelet treated group than in either of the other two groups (Fisher's exact: $p=0.01$, CI: 0.001-0.62). Eyes without an edge were more likely to achieve at least four lines of improvement in visual acuity than eyes with an edge (Fisher's exact: $p=0.01$, CI: 0.005-1.64).

Discussion

The goal of surgical therapy for macular hole is closure of the hole, and flattening of the cuff of subretinal fluid surrounding the hole with accompanying visual improvement. Recent years have seen the search for techniques to improve hole closure, without damage to surrounding retinal tissue, thus increasing the chance of substantial visual recovery.

Kelly and Wendel⁵ first described vitreous surgery for macular holes. Our initial technique was similar to theirs in that we performed vitrectomy, SF₆ gas tamponade, and postoperative posturing. Others have proposed techniques such as aggressive peeling of very fine epiretinal membranes, and even peeling of the internal limiting membrane (ILM) and drainage of subretinal fluid through the macular hole. As our experience with the procedure increased, we undertook a prospective study using a standard technique in which we avoided any contact with the macular hole or the retina surrounding the hole. Epiretinal membranes were peeled only if easily visible or causing retinal traction. We have noted fine epiretinal membranes at the macula, usually contracted postoperatively, but they have not interfered with vision or caused traction. It is, perhaps, these membranes that others are peeling during surgery. It seems possible therefore to achieve a high anatomic success rate despite avoiding aggressive peeling of fine ERMs or of the ILM which may cause nerve fibre layer haemorrhages. Glaser's patients also achieved a

Table 3 Visual results

	6/12 or better	6/18 or better	VA increase, 2 lines or more	VA increase, 4 lines or more
SF ₆	9 (45%)	12 (60%)	13 (55%)	4 (20%)
SF ₆ + TGF- β	2 (13%)	3 (60%)	5 (33%)	2 (13%)
C ₃ F ₈ + platelets	21 (43%)	31 (63%)	36 (73%)	20 (42%)

high anatomic success rate without foveal manipulation.¹² In our study, the three different treatment groups were treated consecutively, which may introduce a learning curve bias, although we believe that this was not significant as the surgical procedure is relatively straight forward.

There is evidence that the duration of the intraocular gas bubble tamponade may have an effect on the outcome of macular hole surgery.¹³ We initially used SF₆ gas but, for our prospective trial, changed to the longer acting C₃F₈ gas. We also encouraged our patients to posture by informing them of the requirement in a patient information leaflet, by reiterating this information verbally postoperatively, and telephoning them at home. Posturing remains a troublesome and unpleasant requirement for patients.

Adjunctive therapy was introduced to the surgical management of macular holes by Glaser, in an attempt to improve the anatomic and visual outcomes. The rationale for the use of cytokines is to promote chorioretinal adhesion at the margins of the hole, and it has been suggested⁶ that cytokines may also have a growth promoting effect, stimulating photoreceptor regeneration. Other sources known to be rich in cytokines including serum and platelets, and thrombin have now also been used as adjuncts. Platelets are a rich source of cytokines, and this resource has been exploited to promote wound healing.¹⁴ Gaudric and colleagues⁸ suggested in a preliminary report that an autologous platelet preparation is beneficial in treating macular holes and others have reported the successful use of platelets in a small number of cases.¹⁵ Smiddy *et al* have shown closure of induced retinal tears, in rabbit eyes, using the cytokine TGF-β2,¹⁶ and autologous serum has been shown to promote closure of experimental retinal tears in the rabbit retina.¹⁷

Several studies in which a variety of techniques were used have now reported an anatomic success rate of 80–90% in macular hole surgery. Kelly and Wendel used vitrectomy, and SF₆ gas tamponade alone to achieve 58% anatomic success.⁵ This had improved to 90% anatomic success in a larger series of patients.¹⁸ Glaser and colleagues achieved 100% macular hole closure in patients treated with 1330 ng dose of TGF-β2.⁶ Liggett and coworkers⁷ found 100% anatomic success in 11 eyes treated with human autologous serum adjunct to vitrectomy and gas tamponade. In 1995 Gaudric *et al*⁸ reported 95% anatomic success in 20 eyes, and in 1996 Korobelnik *et al*¹⁵ reported 87.5% closure in 11 eyes using autologous platelet concentrate. In this study, using C₃F₈ gas tamponade and autologous platelet concentrate we had an anatomic success rate of 96%. This was significantly better than our success rate using SF₆ gas alone (p=0.005), or SF₆ gas and TGF-β (p=0.017). Although our best results were obtained in the platelet concentrate group, we also used a longer acting gas tamponade in these eyes so a combination of these two factors may be responsible for the improved results. It is clear,

however, that using a variety of techniques and adjuncts, it is now possible to obtain a very high anatomic success rate in the surgical treatment of macular holes. The precise role of adjunctive therapy and the various surgical techniques employed such as foveal manipulation can probably be addressed only within a controlled clinical trial.

In 11 eyes, despite resolution of the subretinal fluid, the edge or part of the edge of the macular hole was visible postoperatively. It is of interest that only two (5%) of these were in the platelet treated group, compared to five (33%) in the SF₆ only group, and four (40%) in the SF₆ and TGF-β2 group. This difference between the platelet treated group and the others was statistically significant (p=0.01). We saw this complication only rarely in eyes treated with platelets and C₃F₈. This may indicate a more enhanced chorioretinal adhesive response in this group, compared with the other two groups. Whether this is due to the action of platelets, or due to the longer lasting tamponade, we cannot say; however, we intend to conduct a study to examine the effects of platelet concentrate using a shorter duration of tamponade. Although the cuff of subretinal fluid had resolved in these eyes, the presence of an edge may reduce the functional result. Eyes without an edge were more likely to achieve at least four lines of improvement than those with an edge (p=0.01).

Closure of the hole is usually associated with an improvement in visual acuity. Patients benefit from surgery by an increase in visual acuity, and a resolution of metamorphopsia. Visual acuity of 6/12 or better will enable patients to drive. Improved visual acuity with resolution of metamorphopsia will affect reading ability. Polk *et al*²⁰ showed that there is an improvement in bilateral visual function following macular hole surgery, particularly if there is subnormal vision in the fellow eye. Most authors use a two line improvement in Snellen visual acuity as an indication of success; however, actual final visual acuity is, perhaps, more important.

Overall visual results in this study were similar to those in other reports,^{5 6 12 18} with two line improvement achieved in 74% of eyes treated with C₃F₈ + platelets. Glaser and colleagues⁶ also suggested that TGF-β2, as well as having the properties of a 'biologic chorioretinal glue',¹⁶ may also have additional effects on visual function at a cellular level, on photoreceptor function and/or regeneration. There is a possibility that the release of cytokines from platelets may have an effect on local cellular function. We, however, found, no significant difference in visual acuity improvement between those groups receiving platelets and those receiving no adjunctive therapy.

We inject 0.1 ml of a platelet solution containing 10⁶ platelets per ml into the eye. For the following 1–2 weeks, a white 'coagulum' is visible over the posterior fundus and almost always covering the macular hole. This may be merely clumping of the platelets, or the material may contain some clotting factors—for example, fibrin. At present we are analysing

the exact constituents of this material. Others working with platelets have also noted this appearance (Gaudric, personal communication). This white material may have a beneficial effect by enhancing closure of the macular hole by mechanical means, perhaps providing a scaffold for cell proliferation, but it is also possible that it has a deleterious effect on retinal tissue. A number of eyes treated with platelet concentrate, despite having successfully closed holes, had one of a variety of macular abnormalities. Twenty had retinal pigment abnormalities at the fovea. At about 6 weeks postoperatively, a hyperpigmentation of the retinal pigment epithelium occurred at the site of the macular hole in these 20 eyes. Surrounding this RPE spot the hole was closed with no edge visible. Seventeen of this group were treated with platelet concentrate and C_3F_8 gas, two had SF_6 gas tamponade, and one had SF_6 gas and TGF- β 2. The platelet treated group was more likely than either of the other two groups to develop a pigment spot ($p=0.048$ and $p=0.025$ respectively). Even with this pigment epithelium disturbance, the mean visual outcome, in these patients was not significantly different from those without the pigment spot ($p=0.27$), and indeed one patient with postoperative visual acuity of 6/6 had a pigment spot.

We noted radial striae emanating from the closed macular hole in 12 eyes postoperatively. They present postoperatively and then gradually disappear over about 6 weeks. Radial striae in the retina are present in some macular holes preoperatively and their presence has been correlated with a better visual outcome.²¹ We were unable to define any significant difference in visual outcome in our patients with radial folds but the numbers are quite few. The retina remains thickened at the fovea for several weeks postoperatively in some eyes in which the macular hole has closed and these striae may represent the effects of centripetal contraction on hole closure.

Our experience with TGF- β 2 was disappointing with a significantly worse visual outcome in this group than in either of the other two groups. Our numbers, however, are limited and a high proportion (40%) of these eyes were reoperations with a substantial delay between first and second operation making visual improvement less likely. TGF- β 2 is extracted from porcine or bovine platelets. It is possible that microheterogeneities in the structure of the compound may affect its action and could explain our disappointing results. Although initially a 100% success rate was reported using 330 ng or 1330 ng of bovine TGF- β 2, in a more recently conducted controlled clinical trial comparing recombinant TGF- β 2 and placebo, no significant difference was found between the TGF- β 2 treated group and control group.²²

Twenty eyes had stage 2 macular holes; 15 (75%) of these had a final visual acuity of 6/18 or better, and 12 (60%) had a final acuity of 6/12 or better. In this study, the mean postoperative visual acuity for stage 2 macular holes is logMAR 0.5 (6/18); it is 0.6 (6/24) for stage 3;

and 0.8 (6/36) for stage 4. Stage 2 holes, when successful, are more likely than either stage 3 ($p=0.012$) or stage 4 ($p=0.004$) to achieve a final visual acuity of 6/9 or better. A previous study has also indicated a favourable outcome of stage 2 holes, and that patients with recent onset holes have a better visual prognosis than older holes.^{23, 24} We have attempted to make sure that macular holes were present for a no longer than 1 year, but depending on patient symptoms, an exact measure of duration is sometimes difficult to ascertain.

It has been suggested that reoperation should be considered in cases in which the macular hole has failed to close at initial surgery.^{25, 26} In our series of eight reoperations, although six (75%) were an anatomic success, only 25% achieved visual improvement of two lines or more. This may be due to a delay in the reoperation time, in our patients, ranging from 1.5 to 11 months (mean 7 months).

The recognised complications of macular hole surgery include cataract, retinal tears, retinal detachment, visual field loss, reopening of the hole, and optic atrophy.^{27, 28} We have experienced all of these complications. We had five (6%) retinal tears, which were treated with cryotherapy intraoperatively. Three (3.5%) eyes developed retinal detachments, two successfully repaired. One failure developed proliferative vitreoretinopathy. In two (2.5%) patients a previously closed macular hole reopened, requiring repeat vitrectomy, one at about 4 weeks postoperatively and the other at 3 months. We also experienced one case of postoperative optic atrophy (1.4%). The reason for this is unclear, there was no postoperative intraocular pressure rise and this patient was a healthy young man with no apparent systemic disease. This patient resembles the three patients described by Stirpe with optic atrophy following macular hole surgery²⁹ and which he attributed to damage to the optic nerve fibre layer during stripping of the posterior hyaloid.

Endophthalmitis is a concern when injecting any material into the vitreous cavity, and has occurred following injection of serum as an adjunct in macular hole surgery³⁰ (P E Liggett, personal communication). We believe that preparation of the platelet concentrate within the operating theatre avoiding transport of the blood or blood product may reduce the risk of bacterial or viral contamination.

Visual field loss has been described in association with vitrectomy³¹ and more recently following macular hole surgery.^{32, 33} We found visual field defects in 22 eyes, 16 in the C_3F_8 gas and platelet concentrate group, all of whom had preoperative and postoperative perimetry. The visual field loss was quite dense, peripheral, usually inferotemporal, and in many patients, symptomatic despite improvement in central vision. In a few eyes, the cause of the visual field defect was apparent—one had optic atrophy, one had anterior ischaemic optic neuropathy, and one had a retinal detachment. In the majority, the cause of the visual field loss is uncertain, but it appears to be due to retinal nerve fibre loss rather than outer retinal damage.³² It has been attributed

to a variety of causes but especially to trauma to the optic nerve fibres during posterior hyaloid stripping, when optic nerve haemorrhages may occur.³³ In this study, however, five patients with visual field loss did not have posterior hyaloid removal during surgery, three had stage 4 macular holes, and the other patient developed a visual field defect following a second procedure for previously failed surgery. It has also been suggested that surgical damage to the optic nerve head may occur during air/fluid exchange,³¹ although this is, perhaps, unusual with silicone tipped needles. Other factors that could possibly account for visual field loss include nocturnal hypotension causing relative ischaemia of the optic nerve, raised intraocular pressure, ocular compression during prone posturing, and the effects of the intraocular gas bubble.³³ The flotation force exerted by the intraocular gas bubble on the retina is very low and probably of little clinical significance; nevertheless, it may exacerbate retinal ischaemia in susceptible patients and may, perhaps, account for the predominant pattern of inferior rather than superior visual field loss. In this study, eyes treated with C₃F₈ gas tamponade were more likely to develop field defects than eyes treated with shorter acting SF₆ gas although this difference failed to reach statistical significance. Raised intraocular pressure is not unusual immediately after macular hole surgery and it may exacerbate retinal ischaemia, and be implicated in the aetiology of visual field loss. To prevent it we routinely treated all patients with oral acetazolamide postoperatively, and the highest recorded postoperative intraocular pressure was 34 mm Hg. Of the 22 cases of field loss encountered in this study, at least six were symptomatic, so that we now inform patients of this risk before surgery.

In this study, we achieved a high rate of anatomic and visual success in the group of eyes treated with vitrectomy, gas tamponade, and autologous platelet concentrate. The methods used in this group differed from the other two groups not only in terms of adjunctive therapy but also by the avoidance of foveal manipulation and drainage of fluid through the hole, and by the use of a longer gas tamponade with a longer posturing requirement. One, or all, of these may have contributed to the improved success rate. Our best results were obtained in stage 2 macular holes. Our findings confirm previous pilot studies suggesting a beneficial outcome using a platelet concentrate as an adjunct in the surgical therapy of macular holes.⁸ Although many patients had a significant improvement in visual acuity, the incidence of postoperative visual field loss may be as high as 30%. It is now possible to achieve an anatomic success rate of greater than 90% in the surgical treatment of macular holes using a variety of techniques including adjuvants such as platelet concentrate, serum, or cytokines or by carefully dissecting fine epiretinal membranes or the internal limiting membrane around the hole. All these techniques employ C₃F₈ gas tamponade and prolonged postoperative posturing which is difficult and unsatisfac-

tory for elderly patients. Efforts must now be directed to identify techniques which reduce the posturing requirement while maintaining the high anatomic and visual success rate in macular hole surgery.

The authors thank Dr K P Cotter and Mr N Martin, Haematology Department, Cork University Hospital for their help in preparation and analysis of the autologous platelet concentrate.

- 1 The Eye Disease Case-Control Study Group. Risk factors for idiopathic macular holes. *Am J Ophthalmol* 1994; **118**:754-61.
- 2 Gass JDM. Idiopathic macular hole; its early stages and pathogenesis. *Arch Ophthalmol* 1988; **106**:629-39.
- 3 Lewis H, Cowan GM, Straatsma BR. Apparent disappearance of a macular hole with development of an epiretinal membrane. *Am J Ophthalmol* 1986; **102**:172-5.
- 4 Schocket SS, Lakhanpal V, Miao XP. Laser treatment of macular holes. *Ophthalmology* 1988; **95**:574-82.
- 5 Kelly NE, Wendel RT. Vitreous surgery for idiopathic macular holes: results of a pilot study. *Arch Ophthalmol* 1991; **109**:654-9.
- 6 Glaser BM, Michels RG, Kuppermann BD, Sjaarda RN, Pena RA. Transforming growth factor-beta 2 for the treatment of full-thickness macular holes; a prospective randomised study. *Ophthalmology* 1992; **99**:1162-72.
- 7 Liggett PE, Skolik DSA, Horio B, Saito Y, Alfaro V, Mieler W. Human autologous serum for the treatment of full-thickness macular holes. A preliminary study. *Ophthalmology* 1995; **102**:1071-6.
- 8 Gaudric A, Massin P, Paques M, Santiago PY, Guez JE, Le Gargasson JF, et al. Autologous platelet concentrate for the treatment of full-thickness macular holes. *Graefes Arch Clin Exp Ophthalmol* 1995; **233**:549-54.
- 9 Barrie T. Macular holes. (Editorial) *Br J Ophthalmol* 1995; **79**:511-2.
- 10 Fine SL. Vitreous surgery for macular hole in perspective: is there an indication? *Arch Ophthalmol* 1991; **109**:635-6.
- 11 Gass JDM. Reappraisal of biomicroscopic classification of stages of development of a macular hole. *Am J Ophthalmol* 1995; **119**:752-9.
- 12 Lansing MB, Glaser BM, Liss H, Hanham A, Thompson JT, Sjaarda RN, et al. The effect of pars plana vitrectomy without epiretinal membrane peeling on full-thickness macular holes. *Ophthalmology* 1993; **100**:868-72.
- 13 Thompson JT, Glaser BM, Sjaarda RN, Murphy RP, Hanham A. Effects of intraocular bubble duration in the treatment of macular holes by vitrectomy and transforming growth factor beta 2. *Ophthalmology* 1994; **101**:1195-200.
- 14 Steed DL, Gosler JB, Holloway GA, Malone JM, Bunt TJ, Webster MW. Randomised double-blind trial in treating chronic diabetic foot ulcers CT102 activated platelet supernatant, topical versus placebo. *Diabetes Care* 1992; **15**:1598-604.
- 15 Korobelnik JF, Hannouche D, Belayachi N, Branger M, Guez JE, Hoang-Xuan T. Autologous platelet concentrate as an adjunct in macular hole healing. A pilot study. *Ophthalmology* 1996; **103**:590-4.
- 16 Smiddy WE, Glaser BM, Green WR, Concor TB, Roberts AB, Lucas R, et al. Transforming growth factor beta. A biologic chorioretinal glue. *Arch Ophthalmol* 1989; **107**:577-80.
- 17 Christmas NJ, Skolik SA, Howard MA, Saito Y, Barnstable CJ, Liggett PE. Treatment of retinal breaks with autologous serum in an experimental model. *Ophthalmology* 1995; **102**:263-71.
- 18 Wendel RT, Patel AC, Kelly NE, Salzano TC, Wells JW, Novack GD. Vitreous surgery for macular holes. *Ophthalmology* 1993; **100**:1671-6.
- 19 Smiddy WE, Glaser BM, Thompson JT, Sjaarda RN, Flynn HW, Hanham A, et al. Transforming growth factor beta 2 significantly enhances the ability to flatten the rim of subretinal fluid surrounding macular holes. Preliminary results of a multicenter prospective randomised study. *Retina* 1993; **13**:296-301.
- 20 Polk TD, Smiddy WE, Flynn HW. Bilateral visual function after macular hole surgery. *Ophthalmology* 1996; **103**:422-6.
- 21 Yoshida A, Ishiko S, Akiba J. Radiating retinal folds detected by the scanning laser ophthalmoscope in idiopathic macular holes. Report at Club Jules Gonnin Meeting; September 1996.
- 22 Thompson JT, Smiddy WE, Williams GA. Comparison of recombinant TGF-β2 and placebo as an adjunctive agent for macular hole surgery. *Ophthalmology* 1995; **102**(suppl):91.
- 23 Ruby AJ, Williams DF, Grand MG, Thomas MA, Meredith TA, Boniuk I, et al. Pars plana vitrectomy for treatment of stage 2 macular holes. *Arch Ophthalmol* 1994; **112**:359-64.
- 24 Ryan EH, Gilbert HD. Results of surgical treatment of recent-onset full thickness macular holes. *Arch Ophthalmol* 1994; **112**:1545-53.
- 25 Ie D, Glaser BM, Thompson JT, Sjaarda RN, Gordon LW. Retreatment of full-thickness macular holes persisting after prior vitrectomy. A pilot study. *Ophthalmology* 1993; **100**:1787-93.
- 26 Smiddy WE, Sjaarda RN, Glaser BM, Flynn HW, Thompson JT, Hanham A, et al. Reoperation after failed macular hole surgery. *Retina* 1996; **16**:13-18.

- 27 Thompson JT, Glaser BM, Sjaarda RN, Murphy RP. Progression of nuclear sclerosis and long-term visual results of vitrectomy with transforming growth factor beta-2 for macular holes. *Am J Ophthalmol* 1995; **119**:48-54.
- 28 Park SS, Marcus DM, Duker JS, Pesavento RD, Topping TM, Frederick AR, *et al.* Posterior segment complications after vitrectomy for macular hole. *Ophthalmology* 1995; **102**: 775-81.
- 29 Stirpe M. Complications of removal of the posterior vitreous face during vitreous surgery. Presented at Club Jules Gonin Meeting, September 1996.
- 30 Bacon AS, Davison CR, Patel BC, Frazer DG, Ficker LA, Dart JKG. Infective endophthalmitis following vitreoretinal surgery. *Eye* 1993; **7**:529-34.
- 31 Melberg NS, Thomas MA. Visual field loss after pars plana vitrectomy with air/fluid exchange. *Am J Ophthalmol* 1995; **120**:386-8.
- 32 Ezra E, Arden GB, Riordan-Eva P, Aylward GW, Gregor ZJ. Visual field loss following vitrectomy for stage 2 and 3 macular holes. *Br J Ophthalmol* 1996; **80**:519-25.
- 33 Prendergast SD, McCuen BW. Visual field loss after macular hole surgery *Ophthalmology* 1996; **103**:1069-77.



Surgical management of macular holes: results using gas tamponade alone, or in combination with autologous platelet concentrate, or transforming growth factor β 2

M Minihan, M Goggin and P E Cleary

Br J Ophthalmol 1997 81: 1073-1079
doi: 10.1136/bjo.81.12.1073

Updated information and services can be found at:
<http://bjo.bmj.com/content/81/12/1073.full.html>

-
- References** *These include:*
This article cites 30 articles, 8 of which can be accessed free at:
<http://bjo.bmj.com/content/81/12/1073.full.html#ref-list-1>
- Email alerting service** Article cited in:
<http://bjo.bmj.com/content/81/12/1073.full.html#related-urls>
Receive free email alerts when new articles cite this article. Sign up in the box at the top right corner of the online article.

-
- Topic Collections** Articles on similar topics can be found in the following collections
[Retina](#) (1217 articles)
[Ophthalmologic surgical procedures](#) (971 articles)

Notes

To request permissions go to:
<http://group.bmj.com/group/rights-licensing/permissions>

To order reprints go to:
<http://journals.bmj.com/cgi/reprintform>

To subscribe to BMJ go to:
<http://group.bmj.com/subscribe/>