

Endonasal laser dacryocystorhinostomy—medium term results

S A Sadiq, S Ohrlich, N S Jones, R N Downes

Abstract

Background/claims—Endonasal laser dacryocystorhinostomy (ELDCR) has many potential advantages over conventional external DCR. Although the short term results of this technique have been reported, little is yet known of the long term results, and the occurrence of late rhinostomy failure. The aim of this study was to examine the results at 3 and 12 months following ELDCR.

Method—The notes of all consecutive ELDCRs performed between November 1993 and May 1995 were retrieved. Demographic information, details of surgery, and the postoperative results were noted.

Results—ELDCR procedures which did not undergo lacrimal stenting showed a short term success rate of 67% at 3 months, and a further failure rate of 9% at 12 months. ELDCRs which did undergo lacrimal stenting showed a short term success rate of 82% at 3 months, and a further failure rate of 21% at 12 months. Lacrimal intubation increased the long term success rate by 8%. The success rate was lower in the presence of local risk factors for nasal mucosal scarring.

Conclusions—ELDCR requires some adjunctive treatment to improve maintenance of the nasal mucosal ostia if it is to compete successfully with external DCR on grounds other than cosmesis and patient convenience.

(*Br J Ophthalmol* 1997;81:1089-1092)

Despite the fact that external dacryocystorhinostomy (DCR) was introduced just over 90 years ago,¹ it is not a common procedure for most general ophthalmologists to perform. Indeed, the best results are obtained by those that operate regularly on the nasolacrimal system.^{2,3} As in many other fields of medicine, there is often a resurgence of older ideas, and in the field of lacrimal surgery, we have recently seen a rekindling of the interest in a transnasal approach to DCR,⁴ which was described over a century ago.⁵ This, combined with improvements in technology allowing impressive intranasal visualisation and manipulation with the use of the nasal endoscope, has led the way forward in the use of lasers to create the rhinostomy.⁶⁻⁹ Initially the argon laser was employed,^{7,8} followed by the carbon dioxide and potassium titanyl phosphate lasers.⁹ These lasers have been surpassed by the arrival of the holmium:YAG laser,^{6,10} with its enhanced bone

ablation and haemostatic properties. At present, the erbium laser also seems to have properties which may make it ideal for use in this type of surgery.

We have previously described our early experience in fashioning a rhinostomy with the aid of the holmium:YAG laser.¹⁰ We illustrated the technique we used in 50 consecutive cases of endonasal laser dacryocystorhinostomy (ELDCR), and also reported our results after a mean follow up of 4 months. We believe that because of the many benefits afforded by ELDCR over conventional DCR (for example, surgery under local anaesthesia, a day case procedure, a much shorter operating time), ELDCR merits greater attention. In order to compare a new technique with one that has been established for many years, it is important to know the longer term results of surgery. Therefore, we now present our results of ELDCR in consecutive patients who have undergone a 1 year follow up.

Method

Consecutive patients who underwent a ELDCR to relieve nasolacrimal obstruction between November 1993 and May 1995 were identified from the theatre records. The patients' age, sex, lateralisation, and the indication(s) for surgery were noted. The vast majority of surgery was performed under local anaesthesia unless the patient expressed a preference for general anaesthesia, with the method of surgery unchanged from our previous report,¹⁰ except for the addition of an extra injection of lignocaine (with adrenaline) into the nasal mucosa overlying the proposed rhinostomy site. This was performed under direct view using the nasal endoscope and we have found it useful in reducing any sensation and blood splatter during the ablation procedure. Also, as our first report had found an improved success rate (although not statistically significant) if the nasolacrimal system was intubated preoperatively, we have increased our rate of silicone stenting. Any pre- or perioperative risk factors for scarring were also noted.

Postoperatively, patients were treated with 1 month's course of topical steroids and antibiotics (betnesol-N), along with instructions for nasal douching. Silicone stents were routinely removed 3 months postoperatively under direct view with a nasal endoscope, following which a further month's course of topical steroids was administered, along with further nasal douching. If there was surgical failure, a repeat ELDCR was offered. All revision ELDCRs received lacrimal stenting. At each visit postop-

Department of
Ophthalmology,
Queen's Medical
Centre, Nottingham
NG7 2UH
S A Sadiq
S Ohrlich
R N Downes

Department of
Otorhinolaryngology,
Queen's Medical
Centre, Nottingham
NG7 2UH
N S Jones

Correspondence to:
Mr R N Downes.

Accepted for publication
10 June 1997

eratively, the patient's symptoms were assessed and recorded. The procedure was deemed successful if there was a total relief of preoperative symptoms, or enough of an improvement so that the patient was not troubled by any symptoms. The state of the nasal mucosa and nasal ostium was assessed with a nasal endoscope, and nasolacrimal syringing was performed. Follow up was defined as the time from surgery where lacrimal intubation was not performed, or as the time after stent removal where lacrimal intubation was performed. The results of surgical outcome are analysed as the number of procedures performed—that is, bilateral ELDCR in a single patient is analysed as two procedures.

Results

Eighty five patients underwent 97 ELDCR procedures (12 bilateral, 10 of which were performed simultaneously). Of the unilateral procedures, 36 patients underwent a right sided ELDCR, and 37 underwent a left sided ELDCR. There were 57 females and 28 males, and their mean age was 63.5 years (range 19–91, SD 19.2). Sixty nine procedures were for epiphora alone, one for a mucocele alone, six for epiphora and dacryocystitis, 12 for epiphora and a mucocele, and nine for a combination of all three. Six patients (7%), with a mean age of 33.7 years (SD 14.0), opted for general anaesthesia. None of these had simultaneous bilateral surgery. The other 61 (93%), had surgery under local anaesthesia. Only one patient (1%), an 81-year-old woman required an overnight hospital stay for social reasons.

ELDCR WITHOUT INTUBATION

Twenty two ELDCR procedures were performed without lacrimal intubation. Of these, 21 (95%) were able to be analysed at 3 months postoperatively. We were unable to contact one patient who lived some distance away from the unit, despite telephoning and writing. (See Table 1, row 1 for analysis of results.) Of the successful ELDCRs at 3 months (14), we were able to analyse 11 (79%) at 12 months. Two patients had died in the interim, and one had moved without any forwarding details.

ELDCR WITH INTUBATION

Seventy five ELDCR procedures were performed with lacrimal intubation. Of these, 65 (87%) were able to be analysed at 3 months postoperatively. We were unable to complete analysis of 10 procedures (three were from outside the region, and one had moved from Nottinghamshire at 2 months postoperatively,

before he was due to have his stents removed!). Seven procedures were withdrawn from analysis by us, six of whom had had stent removal before 3 months (displaced or fallen out), and one who had inadvertently retained his stents for 11 months! This latter patient was asymptomatic at his last follow up, and of the remaining six exclusions, three were successful at the last follow up, and three procedures had failed. (See Table 1, row 2 for analysis of results.) Of the successful ELDCRs at 3 months (53), we were able to analyse 52 (98%) at 12 months; one patient had died in the interim.

PRE- AND PEROPERATIVE RISK FACTORS

Preoperative risk factors were identified in 42 cases. These consisted of intranasal pathology (for example, previous nasal surgery, nasal scarring, polyps), previous external approach DCR, some element of mucosal blockage, Wegener's granulomatosis, and sarcoidosis. (See Table 2 for analysis of how these affected the results.) Peroperative risk factors were identified in six cases, and consisted of technical difficulties in five (for example, deviated nasal septum, anteropositioned anterior ethmoidal air cells) and peroperative bleeding in one.

FIRST REVISION ELDCR

Twelve cases of failed ELDCR underwent a revisionary ELDCR with lacrimal intubation. At 3 months post stent removal, six (50%) have been successful, and six (50%) had failed again.

Discussion

The aim of a DCR is to leave the patient with a patent unscarred rhinostomy in order to create a low pressure lacrimal bypass system, and hence relieve their epiphora, dacryocystitis, or mucocele (see Fig 1). For many years this has been produced via an external approach DCR. A recent review of 169 external approach DCRs has shown a long term success rate of 92%.² Postoperative complications of haemorrhage occurred in 3.9%, and unacceptable scarring in 2.6%. The mean operative time was 64 minutes. Poorer success rates of 71%¹¹ and 81%¹⁰ for external DCR have also been reported.

We do admit that the follow up intervals from the time of surgery in the non-intubated group, and from the time of extubation in the stented group, are not strictly comparable. Unfortunately, there is no good method whereby this could be avoided because if the time from surgery is used for both groups, then by definition this means that 100% of the patients with stents in situ at 3 months will

Table 1 Outcomes of surgery

	3 months postoperative			12 months postoperative		
	No	Successful	Early failure	No*	Successful	Late failure
Without intubation	21	14 (67%)	7 (33%)	11	10 (91%)	1 (9%)
With intubation	65	53 (82%)	12 (18%)	52	41 (70%)	11 (21%)
All cases	86	67 (78%)	19 (22%)	63	51 (81%)	12 (19%)

Values are the number (%) of procedures performed.

*Those successful at 3 months postoperatively.

Table 2 Influence of preoperative risk factors on surgical outcome at 12 months postoperatively

Risk factor	Successful	Failed	Total
Intranasal pathology	5	4	9
Previous external DCR	6	5	11
Mucosal blockage	14	5	19
Wegener's	0	1	1
Sarcoidosis	0	2	2

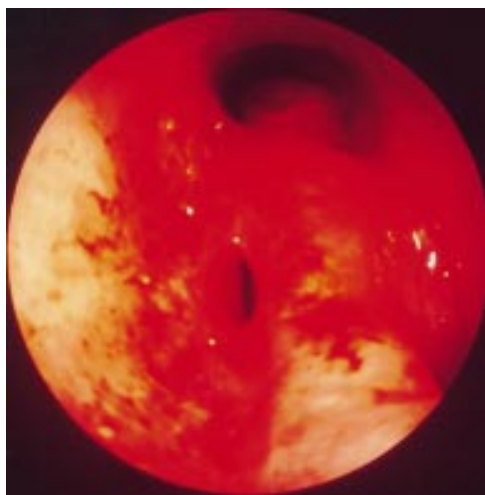


Figure 1 Endonasal view of a patent rhinostomy following ELDCR.

have anatomically patent lacrimal bypasses which would be a meaningless result, especially when we are endeavouring to assess how many procedures suffer early postoperative failure. If anything, analysis such as we have performed would actually reduce our success rate as the stented group would have a longer time to heal or scar. As well as this, analysis of symptoms at 3 months after surgery would also not be possible as the silicone tubes in the canaliculi cause some degree of watering themselves.

Our division of adjacent follow up intervals at 3 months and 12 months is certainly a wide separation, but is the result of factors inherent in our clinical practice. A significant proportion of our patients are extracontractual or tertiary referrals from other health regions, and hence we are unable to ask these patients to attend for more frequent follow ups because of the economic and distance factors involved.

Despite these considerations, our present study shows that at 3 months postoperatively, ELDCR has an overall success rate of 78%, with a further failure rate of 19% at 12 months (Table 1). These results may be further subdivided according to lacrimal intubation. In patients who did not undergo stenting, the

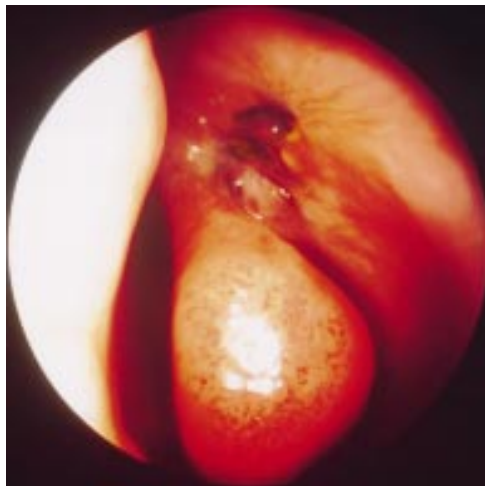


Figure 2 Endonasal view of a failed ELDCR showing fibrosis at the nasal mucosal level.

short term success rate (3 months) is lower at 67%, but there is a late failure rate (at 12 months) of only 9%. In those patients who did undergo stenting, the short term success rate is higher at 82% (this approaches conventional DCR success rates), but the late failure rate is higher at 21%. The short term success rates do show a slight improvement on our previous findings (59% without and 69% with stenting),¹⁰ and we hope this is due to our greater experience in performing ELDCR. The late failure rate without stenting of 9% is perhaps acceptable at 1 year, but the late failure rate of 21%, despite stenting for 3 months, is not desirable. This higher late failure rate indicates that there is an initial beneficial effect of intubation, but this effect is reduced over a year. Overall, intubation increases long term success rate from 56% to 64%. Again this latter figure is a lower success rate for ELDCR compared with conventional external DCR than we would hope for after primary surgery, although in our series there was a high percentage of cases without pure outflow obstruction. Revisionary surgery is very easy as it usually requires ablation of submucosal scar tissue only, and thus takes even less time to perform than a primary DCR. The 50% success rate of relatively simple revisionary surgery increases the success rate to 73% achievable within two procedures.

These rates are not very different from those obtained by other surgeons employing ELDCR to create a rhinostomy. Boush and colleagues reported success rates of 70% with the argon laser, but surgery was performed either under general anaesthesia, or under local anaesthesia with intravenous sedation.⁸ Woog and colleagues achieved success rates of 72%, but again surgery was performed under general anaesthesia or local anaesthesia supplemented by intravenous sedation, and a drill was required for bone removal in 38%.⁶ Hence their surgical time was more prolonged at 116 minutes, compared with the 21 minutes required to complete our method of ELDCR where even the osteotomy was performed with the holmium:YAG laser, and 93% of cases were performed under local anaesthesia without intravenous sedation.¹⁰ Patients as young as 20 years of age were able to undergo ELDCR under local anaesthesia. Simultaneous bilateral surgery requires little extra time, and in fact all 10 of these cases were performed under local anaesthesia.

Utilising the excellent vision of the intranasal cavity afforded by the nasal endoscope, our experience shows us that the usual cause of ELDCR (and conventional external DCR) failure is scarring at the nasal mucosal and submucosal level (see Fig 2). There have been no studies performed to indicate the ideal rhinostomy size required for a functioning DCR, but studies have shown that patency is still achieved even after scarring has reduced a rhinostomy size to 1.8 mm.¹² Revisionary surgery with the laser requires ablation of fibrotic nasal membranes or scars, and although this is easily performed with minimal laser energy output, it would be more desirable to prevent its

occurrence in the first place. As there does not seem to be any evidence of bony regrowth or bony encroachment upon the rhinostomy size, we therefore feel that the key to increasing our success rate of ELDCR may lie in trying to reduce nasal mucosal scarring response. Nasal mucosal fibrosis is a problem not just for lacrimal surgeons but also for rhinologists.

Our present study confirms our initial findings that canalicular intubation may help increase rhinostomy patency, although this was not statistically significant.¹⁰ We are of course concerned that silicone stents may cause canalicular trauma. A randomised prospective study investigating their use in external DCR is still not forthcoming to guide us as to their use for ELDCR, although retrospective analyses have shown no advantage¹³ or a worse success rate¹⁴ in primary open lacrimal surgery. We also routinely remove lacrimal stents under direct visualisation with the nasal endoscope which we have in the adnexal clinic. By this method we reduce nasal mucosal trauma that may be acquired during blind retrieval of these tubes, and also eliminate the possibility of tubes becoming lost after being cut at the medial canthus.

We were able to highlight a great number of potential risk factors before surgery (see Table 2), and inform our patients of the increased risk of surgical failure. These included nasal scarring (due to previous nasal surgery or external approach DCR) and mucosal blockage. We achieved success rates of over 50% and over 70% respectively despite these local risk factors. Indeed, dacryocystography preoperatively showing scarring to be present indicates a far worse prognosis,¹⁵ although we no longer perform routine preoperative radiology. In the cases of multisystem disease (Wegener's granulomatosis and sarcoidosis), ELDCR failed within 3 months of surgery.

Following on from the successful use of anti-proliferative agents to reduce fibroblast proliferation and lessen scarring during glaucoma filtration surgery, the use of these same agents at the nasal mucosal site for DCRs seems promising. We ourselves are involved in *in vitro* and *in vivo* studies investigating this, and are also aware of case reports documenting the use of mitomycin C for revisionary external approach DCRs.¹⁶ These agents seem to act by modulating the proliferation of fibroblasts, rather than by causing cell death, and may well be most useful for surgery in patients with multisystem disease such as those described previously.

Blood loss, the long operative time, and surgery under general anaesthesia can mean that the more elderly and those who are medically unfit may be unable to avail themselves of the benefits of lacrimal surgery. ELDCR has the potential to be of most value to this particular category of patients because it can be very easily performed under local anaesthesia, it has a short operative time (21 minutes), and the holmium:YAG laser allows haemostasis.¹⁰ Nowadays, many patients would prefer their surgery to be performed as a day case; 99% of our ELDCRs were performed as day cases, with no one requiring readmission after discharge. Previous attempts at outpatient general anaesthesia external DCRs have resulted in a 13% readmission rate with epistaxis.¹¹ Despite these advantages of ELDCR, the procedure does seem to require some adjunctive treatment to improve maintenance of the nasal mucosal ostium if it is to compete successfully with external DCR on grounds other than cosmesis and patient convenience.

- 1 Toti A. Nuovo metodo conservatore dicura radicale delle soppurazioni croniche del sacco lacrimale (dacriocistorinostomia). *Clin Moderna (Firenze)* 1904;10:385-7.
- 2 Tarbet KJ, Custer PL. External dacryocystorhinostomy. Surgical success, patient satisfaction and economic cost. *Ophthalmology* 1995;102:1065-70.
- 3 Zolli CL, Shannon GM. Dacryocystorhinostomy: a review of 106 operations. *Ophthalmic Surg* 1982;13:905-10.
- 4 Whittet HB, Shun-Shin GA, Awdry P. Functional endoscopic transnasal dacryocystorhinostomy. *Eye* 1993;7:545-9.
- 5 Caldwell GW. Two new operations for obstruction of the nasal duct with preservation of the canaliculi, and an incidental description of a new lacrymal probe. *NY Med J* 1893;57:581.
- 6 Woog JJ, Metson R, Puliafito CA. Holmium:YAG endonasal laser dacryocystorhinostomy. *Am J Ophthalmol* 1993;116:1-10.
- 7 Massaro BM, Gonnering RS, Harris GJ. Endolaser laser dacryocystorhinostomy: a new approach to nasolacrimal duct obstruction. *Arch Ophthalmol* 1990;108:1172-6.
- 8 Boush GA, Lemke BN, Dortzbach RK. Results of endonasal laser-assisted dacryocystorhinostomy. *Ophthalmology* 1994;101:955-9.
- 9 Gonnering RS, Lyon DB, Fisher JC. Endoscopic laser-assisted lacrimal surgery. *Am J Ophthalmol* 1991;111:152-7.
- 10 Sadiq SA, Hugkulstone CE, Jones NS, Downes RN. Endoscopic holmium:YAG laser dacryocystorhinostomy. *Eye* 1996;10:43-6.
- 11 Dresner KK, Meyer DR, Lindberg JV. Outpatient dacryocystorhinostomy. *Ophthalmic Surg* 1991;22:222-4.
- 12 Lindberg JV, Anderson RL, Bumstead RM, Barreras R. Study of intranasal ostium external dacryocystorhinostomy. *Arch Ophthalmol* 1992;100:1758-62.
- 13 Allen K, Berlin AJ. Dacryocystorhinostomy failure: association with nasolacrimal silicone intubation. *Ophthalmic Surg* 1989;20:486-9.
- 14 Walland MJ, Rose GE. The effect of silicone intubation on failure and infection rates after dacryocystorhinostomy. *Ophthalmic Surg* 1994;25:597-600.
- 15 Mannor GE, Millman AL. The prognostic value of preoperative dacryocystography in endoscopic intranasal dacryocystorhinostomy. *Am J Ophthalmol* 1992;113:134-7.
- 16 Bajaj MS, Betharia SM, Kumar H. Role of mitomycin-C in cases of failed DCR. Presented at the Indian Congress of Ophthalmology, 1995.



Endonasal laser dacryocystorhinostomy— medium term results

S A Sadiq, S Ohrlich, N S Jones, et al.

Br J Ophthalmol 1997 81: 1089-1092

doi: 10.1136/bjo.81.12.1089

Updated information and services can be found at:

<http://bjo.bmj.com/content/81/12/1089.full.html>

References

These include:

This article cites 12 articles, 1 of which can be accessed free at:

<http://bjo.bmj.com/content/81/12/1089.full.html#ref-list-1>

Article cited in:

<http://bjo.bmj.com/content/81/12/1089.full.html#related-urls>

Email alerting service

Receive free email alerts when new articles cite this article. Sign up in the box at the top right corner of the online article.

Topic Collections

Articles on similar topics can be found in the following collections

[Ophthalmologic surgical procedures](#) (962 articles)

Notes

To request permissions go to:

<http://group.bmj.com/group/rights-licensing/permissions>

To order reprints go to:

<http://journals.bmj.com/cgi/reprintform>

To subscribe to BMJ go to:

<http://group.bmj.com/subscribe/>