

## LETTERS TO THE EDITOR

**Bilateral acute angle closure glaucoma after administration of paroxetine**

EDITOR.—Paroxetine, a selective serotonin re-uptake inhibitor is said to have a reduced incidence of cholinergic side effects compared with older agents. We describe a case of a patient presenting with bilateral angle closure after commencement of therapy with paroxetine.

## CASE REPORT

A 91-year-old woman was examined in the accident and emergency department. She had woken that morning with painful eyes, blurred vision, and a dry mouth. During the day, the eye pain had worsened, and she was experiencing nausea. She was noted by the casualty officer to have red eyes and fixed pupils, and she was referred to the ophthalmology department. Symptoms were as described above, and she had commenced treatment for depression the previous day with paroxetine. She had not had any symptoms related to previous episodes of angle closure. Apart from mild cardiac failure and osteoarthritis, she was otherwise well. Other medications were co-amiflofruse (2.5 mg/20 mg) one tablet daily and co-proxamol tablets as required.

Examination revealed visual acuities of counting fingers in both eyes. Both eyes were congested, corneas were oedematous, and anterior chambers shallow. Both pupils were oval and mid dilated. Intraocular tensions measured by Goldmann tonometry were over 70 mm Hg in each eye. Nuclear sclerosis 3+ was present in each eye. There was no clear fundal view. Immediate medical treatment was instigated with acetazolamide 500 mg intravenously, pilocarpine 4% every 15 minutes, and timolol 0.5% twice daily. Response to treatment was rapid and, after 5 hours, intraocular tensions had reduced, vision had improved, and pupils were meiosis. On review the following day, symptoms had resolved. Visual acuities were 6/18 right eye and 6/9 left. Intraocular tensions were 12 mm Hg right eye, 11 mm Hg left eye. Subsequently, bilateral YAG laser peripheral iridotomies were performed. Visual acuities stabilised to 6/9 right eye and 6/6 left. Intraocular tensions were 14 mm Hg in both eyes.

## COMMENT

Acute angle closure glaucoma is an important cause of visual morbidity in the elderly. Tricyclic antidepressant agents such as imipramine have been reported in several cases of acute angle closure glaucoma, and inhaled ipratropium bromide has been similarly implicated.<sup>1,2</sup>

Selective serotonin re-uptake inhibitors such as paroxetine (Seraxat), or fluoxetine (Prozac) are thought to act as antidepressants through their ability to inhibit presynaptic serotonin reuptake in the brain. These agents are effective in the treatment of depression and have a lower incidence of cholinergic side effects than tricyclic antidepressants.<sup>3</sup> Nevertheless, some anticholinergic effects still remain, and fluoxetine has been previously implicated in acute angle closure glaucoma.<sup>4</sup> Paroxetine has been reported to have a lower incidence of anticholinergic side effects than fluoxetine.<sup>5</sup> To our knowledge this is the first case where paroxetine has been implicated in

the cause of acute angle closure glaucoma. We suggest that the same caution about tricyclic antidepressants is applied to newer agents such as paroxetine, particularly in older patients.

JAMES F KIRWAN  
IAN SUBAK-SHARPE  
M TEIMORY

Department of Ophthalmology, St George's Hospital,  
Blackshaw Road, London SW17 0QT

Correspondence to: J F Kirwan.

Accepted for publication 14 November 1996

- 1 Reuser T, Flanagan DW, Borland C, Bannerjee DK. Acute angle closure glaucoma occurring after nebulized bronchodilator treatment with ipratropium bromide and salbutamol. *J Roy Soc Med* 1992;85:499-500.
- 2 Ritch R, Krupin T, Henry C, Kurata F. Oral imipramine and acute angle closure glaucoma. *Arch Ophthalmol* 1994;112:67-8.
- 3 Haider A, Miller DR, Staton RD. Use of serotonergic drugs for treating depression in older patients. *Geriatrics* 1993;48:48-51.
- 4 Ahmad S. Fluoxetine and glaucoma. *Ann Pharmacother* 1991;25:436.
- 5 De Wilde J, Spiers R, Mertens C, Bartholome F, Schotte G, Leyman S. A double-blind, comparative, multicentre study comparing paroxetine with fluoxetine in depressed patients. *Acta Psychiatr Scand* 1993;87:141-5.

**Perfluorodecalin and silicone oil used to achieve retinal tamponade left in an eye for 6 months**

EDITOR.—Perfluorocarbon liquids (PFCLs) used in combination with silicone oil have been suggested as a method of achieving superior and inferior retinal tamponade in phakic eyes.<sup>1,2</sup> Because of toxic effects of PFCLs in animal studies, they are not recommended for long term tamponade.<sup>3</sup> We report on a case in which, owing to unforeseen circumstances, both silicone and perfluorodecalin were left in an eye for 6 months.

## CASE REPORT

A 71-year-old man presented with a right subtotal retinal detachment and a left partial detachment. Preoperative visual acuity was hand movements in the right eye and 6/9 in the left. The right retina had marked proliferative vitreoretinopathy and multiple holes in the inferior and superotemporal regions. Retinal reattachment was achieved using an air-fluid exchange but it was impossible to obtain adequate support of the inferior breaks by the use of an explant or silicone oil alone; therefore, a mixture of 1000 cSt silicone oil and perfluorodecalin was used to act as a temporary tamponade with a view to early removal, and an explant was placed in the superotemporal quadrant. It was possible to treat the left retina with an explant alone.

Because of a cardiac arrest postoperatively, further surgical intervention was delayed by 6 months. By this time, although the retina remained attached, a dense cataract had developed and an inverse hypopyon had formed. Right phacoemulsification with intraocular lens implant and removal of silicone oil and heavy liquid was carried out. A third fluid component, more dense than either silicone oil or perfluorodecalin, was noted intraoperatively.

One week later, the right retina redetached via a superonasal entry site tear. This required

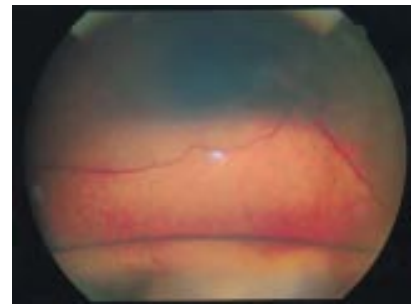


Figure 1 Perfluorodecalin in combination with silicone oil.

reinsertion of silicone oil with encirclement. At 6 months' follow up both retinas were flat with a visual acuity of counting fingers in the right eye and 6/5 in the left. Intraocular pressures have remained normal and the right cornea has remained clear.

## COMMENT

Perfluorocarbon liquids used in combination with silicone have been suggested as a method of achieving retinal tamponade in retinal detachments with inferior and superior pathology.<sup>1,2</sup> Because of differing densities, PFCLs can support the inferior retina and silicone oil the superior aspect. As both substances are immiscible, a meniscus is seen between them on fundal examination (Fig 1). With the exception of perfluorophenanthrene (Vitreon), PFCLs have been shown in animal studies to be toxic to the retina and corneal endothelium when left in situ for any period of time. Other complications of chronic hypotony or chronic raised intraocular pressure seen clinically may be related to preoperative or intraoperative factors rather than the use of PFCLs.<sup>3</sup> Perfluorodecalin has been effective in the treatment of giant retinal tears when removed 5 days postoperatively<sup>4</sup> and the use of perfluorophenanthrene as a short term vitreoretinal tamponade was limited to 4 weeks in an initial study.<sup>5</sup> There have been no reports of perfluorodecalin used in combination with silicone being left in an eye for 6 months.

Although our patient did develop a cataract and emulsified silicone in the anterior chamber, intraocular pressures have been normal and the cornea has remained clear. The third mixture found intraoperatively probably represented emulsified perfluorodecalin within silicone oil. We were unable to reproduce this mixture in vitro by combining perfluorodecalin and silicone, suggesting the presence of an emulsifying agent in vivo. The strongest emulsifiers of silicone demonstrated by in vitro experiments are fibrinogen, fibrin, and serum.<sup>6</sup> Finally, a visual outcome of counting fingers with preservation of the visual field suggests worthwhile retinal function and that, long term, intraocular perfluorodecalin may be tolerated by the retina.

V S Y GEH  
T R DABBS  
E ANSARI

Department of Ophthalmology,  
St James's University Hospital,  
Beckett Street, Leeds LS9 7TF

Correspondence to: Mr T R Dabbs.

Accepted for publication 4 November 1996

- 1 Peyman GA, Conway MD, Soike KF, Clarke LC. Long term vitreous replacements in primates with intravitreal Vitreon or Vitreon plus silicone. *Ophthalmic Surg* 1991;22:657-64.
- 2 Sparrow JR, Jayakumar A, Berrocal M, Ozmert E, Chang S. Experimental studies of the combined use of vitreous substitutes of high and low specific gravity. *Retina* 1992;12:134-40.
- 3 Peyman GA, Schulman JA, Sullivan B. Perfluorocarbon liquids in ophthalmology. *Surv Ophthalmol* 1995;39:375-95.
- 4 Bottoni F, Balio G, Arpa P, Prussiani A, Monticelli M, Molfetta V. Management of giant retinal tears using perfluorodecalin as a post-operative short-term vitreoretinal tamponade: a long-term follow-up study. *Ophthalmic Surg* 1994;25:365-73.
- 5 Binder KJ, Peyman GA, Desai UR, Nelson NC, Alturki W, Paris CL. Vitreon, a short term vitreoretinal tamponade. *Br J Ophthalmol* 1992;76:525-8.
- 6 Heidenkummer H-P, Kampik A, Thierfelder S. Emulsification of silicone oils with specific physicochemical characteristics. *Graefes Arch Clin Exp Ophthalmol* 1991;29:88-94.

### Carbon dioxide laser treatment for lipid proteinosis (Urbach-Wiethe syndrome) involving the eyelids

EDITOR.—Urbach-Wiethe syndrome is a rare autosomal recessive disorder associated with hyaline-like deposits in the skin and pharyngolaryngeal mucous membranes causing dysphonia and hoarseness.<sup>1,2</sup> Ocular manifestations include deposits along the free edges of the eyelids (moniliform blepharosis), conjunctiva, cornea, trabeculum, and Bruch's membrane.<sup>3,4</sup> We used carbon dioxide laser as a new surgical method to alleviate the papular lesion from the eyelids.

#### CASE REPORT

A 21-year-old Bedouin woman was referred to our centre for ophthalmic examination. Although a negative family history of Urbach-Wiethe syndrome was known, the patient and her brother suffered from this disorder.

The patient complained of yellowish papular lesions that occupied the entire lid margin of the upper two lids. She suffered from hoarseness caused by papules situated on the vocal cord and hyperkeratotic nodules on the skin.

Ophthalmic examination revealed numerous yellowish lesions along the lid margin of the upper and the lower lids. Her best corrected visual acuity was 6/6 in both eyes. Slit-lamp examination did not reveal any lesions in the conjunctiva and cornea. Intraocular pressure was normal. Fundus examination did not disclose any posterior segment abnormalities. Haematological investigation did not yield any high levels of serum proteins and lipids.

Light microscopy examination of the eyelid biopsy show pathological alterations diagnostic of lipid proteinosis. The lesion is papillomatous with epidermal hyperkeratosis and atrophic changes. The dermis is considerably thickened and consists in its upper portion of diffused homogeneous hyaline material which stains a pale pink with haematoxylin and eosin (Fig 1). The hyaline material is periodic acid Schiff positive and diastase resistant indicating the presence of neutral mucopolysaccharides. Lipid stain oil red O and amyloid stain Congo red give negative results.

The LX-20SP carbon dioxide laser (Luxar) was used to perform the laser procedure. Under local anaesthesia, all eyelid deposits at the lid margin and the eyelashes were shaved using a 0.2 mm spot size with 1-2 W of power in the continuous mode. To ensure safety dur-

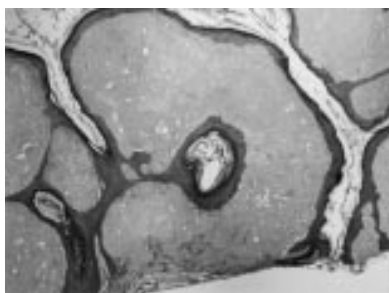


Figure 1 Histological appearance of the eyelid biopsy. Well developed lesion, with hyperkeratotic papillomatous epidermis. The dermis consists of homogeneous hyaline-like material. (Haematoxylin and eosin,  $\times 25$ .)

ing the procedure, impenetrable corneal shields were used to protect the eyes. The eyelashes and the papules were evaporated and no bleeding occurred. At the first week postoperatively, mild bruising, swelling, and regeneration of eyelashes were noticed. The patient reported no tenderness, aching, or any other discomfort. Two months later, the eyelashes had regenerated completely and the lid margins were smooth without any papules.

#### COMMENT

Urbach-Wiethe syndrome is a rare autosomal recessive disorder. The aetiology is still unknown. Some authors think that this disease is caused by a systemic disorder of increased serum levels of lipids and proteins, or an anomaly of the carbohydrate metabolism. In contrast, others assume that it is a primary connective tissue disorder.

The ophthalmic manifestations are characteristic in this disease. The involvement of the eyelids is pathognomonic and frequent. Hyaline-like deposits are located along the free margins of the palpebrals, the Zeis, Moll, and Meibomian glands causing dystriachiasis. Some deposits were noticed in the conjunctiva and cornea (Descemet's membrane). In the trabeculum they cause secondary glaucoma. Also, hyaline-like infiltrates can be found in the retina (Bruch's membrane).

Carbon dioxide laser has a wavelength of 10 600 nm. Clinically, this is advantageous because this energy is non-ionising and thus should not predispose treated skin to carcinomas or other problems associated with ionising radiation. It is highly absorbed by water, the major component of soft tissue.<sup>5</sup> Therefore, its absorption length in the skin is about 0.02 mm, making it a useful wavelength for cutaneous surgery.<sup>6</sup> The safety and efficacy of carbon dioxide laser is well documented in blepharoplasty<sup>7,8</sup> and benign dermal tumours.<sup>9,10</sup> We suggest the use of carbon dioxide laser in lipid proteinosis as a new surgical treatment to alleviate the patient's suffering from cosmetic defects of the eyelids.

G ROSENTHAL  
T LIFSHTITZ  
T MONOS

Department of Ophthalmology, Soroka Medical Center,  
Ben-Gurion University, Beer Sheva, Israel

L KACHCO  
S ARGOV

Department of Pathology, Soroka Medical Center,  
Ben-Gurion University, Beer Sheva, Israel

Correspondence to: G Rosenthal, MD, Department of Ophthalmology, Soroka Medical Center, PO Box 151, Beer-Sheva 84101, Israel.

Accepted for publication 20 November 1996

- 1 Disdier P, Harle JR, Andrac L, Swiader L, Weiller PJ. Specific xerostomia during Urbach-Wiethe disease. *Dermatology* 1994;188:50-1.
- 2 Fabrizi G, Porfiri B, Borgioli M, Serri F. Urbach-Wiethe disease. Light and electron microscopy study. *J Cut Pathol* 1980;7:8-20.
- 3 Blodi FC, Whinery RD, Hendricks CA. Lipid-proteinosis (Urbach-Wiethe) involving the lids. *Trans Am Ophthalmol Soc* 1960;58:155-66.
- 4 Francois J, Bacsulin J, Follmann P. Manifestations oculaires du syndrome d'Urbach-Wiethe. *Ophthalmologica* 1968;155:433-48.
- 5 Biesman BS. Cutaneous facial resurfacing with the carbon dioxide laser. *Ophthalmic Surg Lasers* 1996;27:685-98.
- 6 Trost D, Smith MFW, Zacherl A. Surgical lasers and their tissue interaction. In: Smith MFW, ed. *Neurological surgery of the ear*. St Louis: Mosby Yearbook, 1992.
- 7 Laurence MD. The laser approach to blepharoplasty. *J Dermatol Surg Oncol* 1988;14:741-6.
- 8 Morrow DM, Morrow LB. CO<sub>2</sub> laser blepharoplasty. A comparison with cold-steel surgery. *J Dermatol Surg Oncol* 1992;18:307-13.
- 9 Wheeland RG, Bailin PL, Reynolds OD, Ratz JL. Carbon dioxide laser vaporization of multiple facial syringomas. *J Dermatol Surg Oncol* 1986;12:225-8.
- 10 Wheeland RG, Bailin PL, Ratz JL, Roenigk RK. Carbon dioxide laser vaporization and curettage in the treatment of large or multiple superficial basal cell carcinomas. *J Dermatol Surg Oncol* 1987;13:119-25.

### Descemetocele following a simple avulsion procedure for pterygium

EDITOR.—Simple excision of a pterygium with or without a conjunctival autograft is a routine surgical procedure with generally minimal complications unless adjunctive antimetabolic agents are used. We report an unusual and severe intraoperative complication of severe descemetocele formation in a patient who underwent a routine avulsion procedure<sup>1,2</sup> for a primary pterygium.

#### CASE REPORT

A 47-year-old Malay woman with end stage renal failure on haemodialysis was found to have bilateral severe nasal primary pterygium, grade 4 in the right eye covering the pupillary axis and grade 3 in the left eye (Fig 1). In the right eye, areas of the cornea not directly affected by the pterygium invasion were also noted to be abnormal with diffuse peripheral stromal opacities and perilimbal superficial vascularisation. There was no history of previous ocular disease or trauma.

A pterygium excision with a conjunctival graft was performed in the right eye via a simple avulsion technique. Surgery was performed by a senior corneal surgeon who has performed over 300 conjunctival autograft procedures for primary and recurrent pterygium. The avulsion procedure involves grasping the inferior horizontal edge of the pterygium with conjunctival forceps and exerting traction to avulse the head and inferior aspect of the pterygium from the cornea, at the level of the Bowman's membrane (Fig 2). Concomitant scraping with a No 64

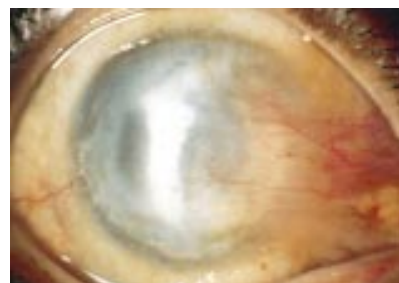

Figure 1 Right eye showing a nasal pterygium covering the pupillary axis.

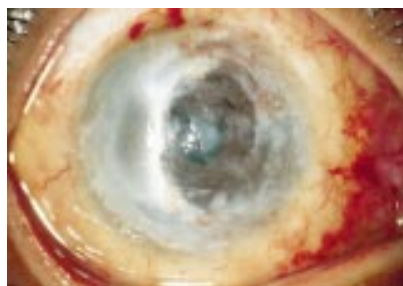


Figure 2 Right eye showing a bulging descemetocoele following an avulsion procedure for a nasal pterygium.

Beaver blade was additionally performed to facilitate clean division from Bowman's membrane. This procedure has a theoretical advantage over sharp dissection or superficial keratectomy in that the natural cleavage plane<sup>3</sup> between the pterygium and Bowman's membrane is respected, whereas sharp dissection may inadvertently result in a deeper stromal plane with excessive loss of corneal stromal tissue.

In this patient, modest traction to disinsert the pterygium resulted in avulsion of the pterygium together with significant adjacent corneal stromal tissue, resulting in a cleavage plane deep within the posterior stroma. This plane, which occurred over approximately two thirds of the surface area of the cornea (over the original pterygium site), resulted in a residual corneal thickness of less than one quarter of the original stroma, and a bulging central descemetocoele (Fig 2). The corneal stroma was noted to be opaque and abnormally friable in consistency. After removal of the pterygium, a conjunctival autograft was performed to cover the scleral bed. The large corneal defect was left bare, as corneal donor tissue was unavailable.

Postoperatively, the degree of corneal stromal loss associated with bulging of the descemetocoele was confirmed by slit-lamp microscopy, and the patient subsequently underwent successful tectonic lamellar keratoplasty 2 days after the initial pterygium

excision, when a corneal donor was obtained (Fig 3). Six months postoperatively, the lamellar graft remains clear, and visual acuity is correctable to 6/30 with corrective glasses. The conjunctival autograft remains in place and no recurrence of the pterygium has occurred. Histology of the pterygium tissue combined with deep corneal stromal tissue revealed a total lack of stromal lamellae, with fibrovascular tissue containing numerous dilated capillaries and a perivascular lymphocytic infiltrate.

#### COMMENT

Excision of a pterygium is generally not associated with significant corneal loss unless superficial keratectomy is performed without undue attention to the depth of keratectomy. The avulsion procedure performed in this patient is similar to that described by Coroneo.<sup>4</sup> A combination of pterygium tissue traction, blunt dissection, and scraping of Bowman's membrane enables clean division between pterygium tissue and Bowman's membrane. This, therefore, theoretically reduces the risk of inadvertent loss of corneal tissue. The opaque and friable nature of the underlying corneal stroma suggests significant degenerative changes of the underlying corneal stroma, which is consistent with the histology. Although underlying stromal scarring is common beneath pterygia, stromal density and consistency are usually unaf-

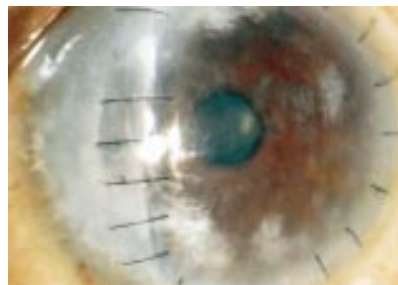


Figure 3 Right eye showing tectonic lamellar graft for a bulging descemetocoele.

ected, and careful dissection at the plane of Bowman's membrane is usually possible.

Retrospectively, the presence of pre-existing deep stromal opacification and vascularisation in adjacent corneal tissue unaffected by pterygium invasion may have suggested a pre-existing abnormal corneal state. The possibility of systemic disease affecting corneal status in this patient is raised. It is not inconceivable that the systemic or metabolic abnormalities present in end stage renal failure or haemodialysis may have played a role in the development of corneal stromal degeneration.

Pterygium excision is generally regarded as a routine surgical procedure which may be performed by residents in training. In Cameron's words 'Many surgeons consider the humble pterygium to be unworthy of their talents and sometimes for this reason, or under pressure of work, delegate the excision to junior staff who in turn treat the condition in cavalier fashion, with in some cases poor results'.<sup>5</sup>

This case illustrates that pterygium surgery may not be routine and free from complications. We propose caution during surgery when severe pterygium is associated with significant stromal disease.

MEENAKSHI SIVAKUMAR  
DONALD TAN

Singapore National Eye Centre,  
11 Third Hospital Avenue, Singapore 168751

Correspondence to: M Sivakumar.

Accepted for publication 14 October 1996

- 1 Zolli CL. Experience with the avulsion technique in pterygium surgery. *Ann Ophthalmol* 1979;11:1569-76.
- 2 Bhatti SM. Pterygium removal: knife versus modified evulsion technique. *Ophthalmic Surg* 1994;25:383-5.
- 3 Rich AM, Kietzman B, Payne T. A simplified way to remove pterygia. *Ann Ophthalmol* 1974;6:739-42.
- 4 Coroneo MT. Beheading the pterygium. *Ophthalmic Surg* 1992;23:691-2.
- 5 Cameron ME. Preventable complications of pterygium excision with beta radiation. *Br J Ophthalmol* 1972;56:52-6.

## NOTICES

### XVI Congress of the Asia Pacific Academy of Ophthalmology

The XVI Congress of the Asia Pacific Academy of Ophthalmology will be held in Kathmandu, Nepal from 2–6 March 1997. Further details: The Secretariat, XVI Congress of APAO, Nepal Eye Hospital Building, Tripureswor, PO Box 335, Kathmandu, Nepal. (fax: +977 1 227505/518.)

### Conferences on Angiography in Créteil

A review of the literature on retinal and choroidal vascular pathology will take place on 10 March 1997 at the University of Créteil. Further details: Professor Gisèle Soubrane, Clinique Ophtalmologique Universitaire de Créteil, 40 Avenue de Verdun, 94010 Créteil Cédex, France. (Tel: 45 17 52 22.)

### Glaucoma Meeting Basel '97

A teaching meeting on NO and endothelin in the pathogenesis of glaucoma will be held on 21–22 March 1997 at the Zentrum für Lehre und Forschung (ZLF), Kantonsspital Basel, Hebelstrasse 20, Basel, Switzerland. Further details: Daniela Stumpf, University Eye Clinic Basel, Mittlere Strasse 91, PO Box, CH-4012 Basel, Switzerland. (Tel: ++41-61-321 59 62 or ++44-61-321 77 77; fax: ++41-61-322 40 01.)

### International Symposium on Ocular Tumors

The International Symposium on Ocular Tumors will be held on 6–10 April 1997 in Jerusalem, Israel. Further details: Professor J Pe'er, Tumors, PO Box 50006, Tel Aviv 61500, Israel. (Tel: 972 3 5140000; fax: 972 3 5175674 or 514007.)

### 2nd International and 4th European Congress on Ambulatory Surgery

The 2nd International and 4th European Congress on Ambulatory Surgery will be held at the Queen Elizabeth II Conference Centre, Westminster, London on 15–18 April 1997. Further details: Congress Secretariat, Kite Communications, The Silk Mill House, 196 Huddersfield Road, Meltham, West Yorkshire HD7 3AP. (Tel: +44 1484 854575; fax: +44 1484 854576.)

### Second European Forum on Quality Improvement in Health Care

The Second European Forum on Quality Improvement in Health Care will take place

on 24–26 April 1997 in Paris, France. The forum will consist of one day teaching courses, invited presentations, posters and presentations selected from submissions, and a scientific session. Further details: BMA, Conference Unit, PO Box 295, London WC1H 9TE. (Tel: +44 (0) 171 383 6478; fax: +44 (0) 171 383 6869.)

### Association for Research in Vision and Ophthalmology (ARVO)

The Association for Research in Vision and Ophthalmology (ARVO) is holding its annual meeting on 11–16 May 1997 at the Fort Lauderdale Convention Center, Fort Lauderdale, Florida, USA. Further details: ARVO, 9650 Rockville Pike, Bethesda, MD 20814-3998. (Tel: (301) 571-1844; fax: (301) 571-8311.)

### 30th Panhellenic Ophthalmological Congress

The 30th Panhellenic Ophthalmological Congress organised by the Hellenic Ophthalmological Society will be held at the Astir Palace Hotel, Vouliagmeni on 28 May to 1 June 1997. Further details: T Kouris, CT Congress, Creta Travel, 19 Amerikis 106 72 Athens, Greece. (Tel: (01) 3607 120, 3635 104; fax: 3603392.)

### Conferences on Angiography in Créteil

A conference on clinical cases in ICG will be held on 9 June 1997 at the University of Créteil. Further details: Professor Gisèle Soubrane, Clinique Ophtalmologique Universitaire de Créteil, 40 Avenue de Verdun, 94010 Créteil Cédex, France. (Tel: 45 17 52 22.)

### British Council International Seminar

A British Council international seminar (number 97031) entitled 'Corneal and external eye disease: new surgical techniques' with Professor D L Easty as director will be held on 29 June to 5 July 1997 in Bristol, UK. The seminar will be of particular interest to all young eye surgeons from the developing and developed world. Further details: Promotions Manager, International Seminars, The British Council, 1 Beaumont Place, Oxford OX1 2PJ, UK (Tel: +44 (0) 1865 316636; fax: +44 (0) 1865 557368/516590; E-mail: International.Seminars@britcoun.org).

### European Association for the Study of Diabetic Eye Complications (EASDEC)

The 7th meeting of EASDEC will be held on 18–19 July 1997 at the Okura Hotel, Amsterdam, the Netherlands, as a pre-congress sym-

posium of the 16th International Diabetic Federation (IDF) congress. Further details: Professor BCP Polak, Rotterdam Eye Hospital, PO Box 70030, 3000 LM Rotterdam, the Netherlands. (Fax: (31) 10 4017655.)

### Continuing Medical Education

The 17th annual current concepts in ophthalmology will be held on 25–27 July 1997 at the San Diego Marriott Mission Valley, San Diego, California, USA. Further details: Marie Krygier, Medical Education Coordinator, San Diego Eye Bank, 9444 Balboa Avenue, Suite 100, San Diego, CA 92123, USA. (Fax: (619) 565-7368.)

### 5th International Symposium on Ocular Circulation and Neovascularisation

The 5th International Symposium on Ocular Circulation and Neovascularisation will be held on 15–19 September 1997 in Kyoto, Japan. Further details: Professor Dr Masanobu Uyama, Secretary General of the Organising Committee, Department of Ophthalmology, Kansai Medical University, Moriguchi, Osaka 570, Japan. (fax: 81-6-997-3475.)

### 2nd International Symposium on ARMD

The 2nd International Symposium on ARMD will be held at Glasgow University, Scotland under the auspices of the Royal College of Ophthalmologists on 16–18 September 1997. Further details: Dr G E Marshall, Eye Department, Western Infirmary, 38 Church Street, Glasgow G11 6NT, UK. (Tel: 0141 211 2094; fax: 0141 339 7485; email: gem1b@clinmed.gla.ac.uk)

### XXVIIIth International Congress of Ophthalmology

The XXVIIIth International Congress of Ophthalmology will be held in Amsterdam on 21–26 June 1998. Further details: Eurocongres Conference Management, Jan van Goyenkade 11, 1075 HP Amsterdam, the Netherlands. (Tel: +31-20-6793411; fax: +31-20-6737306; internet <http://www.solution.nl/ico98/>)

### 2nd International Conference on Ocular Infections

The 2nd International Conference on Ocular Infections will be held on 22–26 August 1998 in Munich, Germany. Further details: Professor J Frucht-Pery, Ocular Infections, PO Box 50006, Tel Aviv, 61500, Israel. (Tel: 972 3 5140000; fax: 972 3 5175674 or 5140077.)



## Bilateral acute angle closure glaucoma after administration of paroxetine

JAMES F KIRWAN, IAN SUBAK-SHARPE and M TEIMORY

*Br J Ophthalmol* 1997 81: 252  
doi: 10.1136/bjo.81.3.252

---

Updated information and services can be found at:  
<http://bjo.bmj.com/content/81/3/252.1.full.html>

---

### References

*These include:*

This article cites 5 articles, 1 of which can be accessed free at:  
<http://bjo.bmj.com/content/81/3/252.1.full.html#ref-list-1>

Article cited in:  
<http://bjo.bmj.com/content/81/3/252.1.full.html#related-urls>

### Email alerting service

Receive free email alerts when new articles cite this article. Sign up in the box at the top right corner of the online article.

---

### Notes

---

To request permissions go to:  
<http://group.bmj.com/group/rights-licensing/permissions>

To order reprints go to:  
<http://journals.bmj.com/cgi/reprintform>

To subscribe to BMJ go to:  
<http://group.bmj.com/subscribe/>