

## Altered retrobulbar vascular reactivity in early diabetic retinopathy

David W Evans, Alon Harris, Ronald P Danis, Oliver Arend, Bruce J Martin

### Abstract

**Aim/background**—In diabetic eye disease the factors leading to compromised circulation and the resulting loss of visual function are poorly understood. Although retinal circulation has been widely investigated, it accounts for only a fraction of total eye blood flow. Blood flow was investigated in the larger vessels feeding the eye in patients with early diabetic retinopathy. **Methods**—Eleven patients with early diabetes with minimal or no retinopathy and 11 healthy controls were evaluated for retrobulbar blood flow velocity using colour Doppler imaging for the ophthalmic and central retinal arteries. Patients and subjects were tested while breathing room air and again under conditions of isocapnic hyperoxia.

**Results**—Hyperoxia induced a significant change in the central retinal artery end diastolic velocity (EDV) ( $p = 0.008$ ) and resistance index (RI) ( $p = 0.032$ ) in normal subjects, but not in diabetic patients. Consequently, during hyperoxia, the diabetic patients were significantly higher for EDV ( $p = 0.006$ ) and significantly lower for RI ( $p = 0.002$ ) compared with normal controls. Hyperoxia caused no significant change in either group in the ophthalmic artery; nevertheless, under isocapnic hyperoxia conditions the diabetic patients had lower peak systolic velocity ( $p = 0.05$ ) and lower RI ( $p = 0.05$ ) than normal subjects.

**Conclusions**—Imposition of isocapnic hyperoxia produces significant differences in the ophthalmic and central retinal artery blood flow velocities in diabetic patients with early disease when compared with normal subjects. These results demonstrate that diabetic patients with minimal or no retinopathy suffer from irregular ocular vascular function in the major vessels feeding the eye.

(*Br J Ophthalmol* 1997;81:279-282)

Altered retinal circulation is well documented in diabetic eye disease.<sup>1,2</sup> Presumably, poor oxygen delivery to retinal tissue causes tissue hypoxia, thus provoking angiogenesis. The factors leading to the compromised circulation and the resulting loss of visual function are poorly understood. A better understanding of ocular haemodynamics in diabetes may provide insight into the causes and prospective treatments for this blinding disease.

In the normal eye, tissue hyperoxia is accompanied by vasoconstriction of retinal vessels<sup>3,4</sup> and reduced blood flow.<sup>5</sup> This autoregulatory response controls tissue partial pressure of oxygen ( $P_{O_2}$ ). Several studies have demonstrated that retinal vessels in patients with diabetes mellitus do not demonstrate this same autoregulatory response. Retinal vessels in insulin dependent diabetic patients without background retinopathy, with background retinopathy and with proliferative retinopathy experience less vasoconstriction and less of a reduction in blood flow compared with age-matched control subjects under conditions of hyperoxia.<sup>6,7</sup> Harris *et al*<sup>8</sup> recently confirmed these results. During 100% oxygen breathing, diabetic patients demonstrated no change in arteriovenous dye passage time (AVP), while AVP for normal subjects was significantly prolonged. Interestingly, the diabetic patients also demonstrated an acute improvement in central static contrast sensitivity during hyperoxia, demonstrating for the first time a direct link between tissue hypoxia and visual and vascular changes in diabetes.

While studies of retinal circulation have vastly increased our knowledge of vascular changes in diabetes, retinal vessels supply only a fraction of total blood flow to the eye.<sup>9</sup> An analysis of retrobulbar haemodynamics, such as of the central retinal and ophthalmic arteries, may provide more knowledge about ocular circulation in diabetes mellitus. The purpose of this study was to examine retrobulbar blood flow velocity as measured by colour Doppler imaging in diabetic patients compared with normal control subjects during room air and hyperoxia conditions.

### Methods

Eleven insulin dependent diabetic patients and 11 healthy subjects were tested. All subjects and patients participated after signing informed consent to procedures approved by a committee for the protection of human subjects. The research conformed to the tenets of the Declaration of Helsinki.

### DIABETIC SUBJECTS

Patients were recruited from the clinical practice of the Retina Service at the Indiana University Medical Center. All subjects presented for routine screening for diabetic retinopathy. Subjects had had insulin dependent diabetes for at least 5 years and no concurrent systemic illness. An ophthalmic examination consisting of history, refraction, visual acuity measurement, slit-lamp, and detailed fundus

Department of  
Ophthalmology,  
Indiana University,  
Indianapolis, USA  
D W Evans  
A Harris  
R P Danis

School of Optometry,  
Department of Visual  
Sciences, Indiana  
University,  
Bloomington, USA  
D W Evans

Department of  
Physiology and  
Biophysics, Indiana  
University  
Indianapolis, USA  
A Harris

Augenlinik RWTH,  
Aachen, Germany  
O Arend

Department of  
Medical Sciences,  
Indiana University,  
Bloomington, USA  
B J Martin

Correspondence to:  
Alon Harris, PhD, Indiana  
University, Department of  
Ophthalmology, 702 Rotary  
Circle, Indianapolis, IN  
46202, USA.

Accepted for publication  
15 November 1996

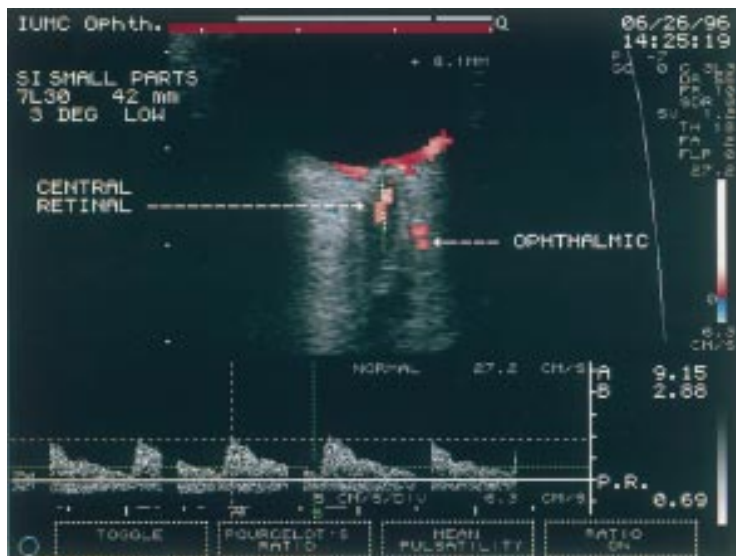


Figure 1 Example of image from colour Doppler imaging of retrobulbar vessels. Shown are coloured pixels from the ophthalmic and central retinal arteries. The Doppler frequency spectrum for the central retinal artery is shown as the wave form at the bottom of the picture. The corresponding peak systolic velocity, end diastolic velocity, and resistance index as determined from the wave form are shown on the bottom right.

examination was performed on each subject. Best corrected visual acuity was 20/25 or better for each subject as measured by ETDRS acuity. Fundus examination was performed with a 90 dioptre lens at the slit-lamp and indirect ophthalmoscopy was carried out with a 20 dioptre lens. The level of retinopathy was estimated in each eye. Only eyes with no detectable retinopathy or with haemorrhages and/or microaneurysms grade Ia or less (by the DRS modified Arlie House classification<sup>10</sup>) and no other signs of retinopathy were included.

#### NORMAL SUBJECTS

Normal volunteers were recruited from the subject pool at the Indiana University Medical Center. They were selected so that mean age, age range, and sex distribution matched that of the diabetic cohort. All normal subjects had 20/20 or better best corrected visual acuity, no history of ocular or cardiovascular disease, and were taking no systemic or topical vasoactive agents.

#### COLOUR DOPPLER IMAGING

Retrobulbar blood flow velocity was assessed using colour Doppler imaging (CDI), an ultrasound technique that combines B-scan grey scale imaging of tissue structure, coloured representation of blood flow based on Doppler shifted frequencies, and pulsed Doppler measurement of blood flow velocities. A Siemens Quantum 2000 (Issaquah, WA, USA) with a 7.5 MHz linear phase transducer was used. For this device, energy density is approximately 15 mW/cm<sup>2</sup> in the colour imaging mode, and approximately 77 mW/cm<sup>2</sup> during the spectral analysis mode. Measurements of peak systolic velocity (PSV) and end diastolic velocity (EDV) were taken of the ophthalmic (OA) and central retinal (CRA) arteries. To examine the ophthalmic artery, the sample volume (segment along the transmitted beam chosen for analysis, approximately 1.2 × 1.2

mm) was oriented nasally and superior to the optic nerve, just lateral to and abutting the visible hyporeflexive stripe representing the nerve. The central retinal artery was found at the anterior of the optic nerve and the sample volume was placed with its centre about 2 mm behind the surface of the disc. Figure 1 presents a sample CDI image showing the ophthalmic and central retinal arteries. After measurement of the flow velocities, the resistance index (RI) was subsequently calculated ((PSV - EDV)/PSV) by computer for each vessel measured. Recent studies<sup>11 12</sup> have demonstrated good reproducibility for CDI measurement of the vessels evaluated in this study.

Retrobulbar flow velocity measurements were taken while subjects and patients breathed room air and again under conditions of isocapnic hyperoxia created by breathing 100% oxygen. Examination order of room air and hyperoxia were counterbalanced. Two measurements of each vessel were taken during each condition. End tidal oxygen and carbon dioxide were monitored by rapid response gas analysers which sampled the initial portion of the expired air stream. If end tidal carbon dioxide values diminished during pure oxygen inhalation, carbon dioxide was added to the inspired end of the apparatus to maintain patient isocapnia.<sup>13</sup> For the hyperoxia condition, CDI measurements were initiated after the end tidal oxygen expiration levels reached or exceeded 80%.

#### STATISTICAL ANALYSIS

Paired Student's *t* tests were used to assess changes in CDI measures induced by hyperoxia within each group. Unpaired Student's *t* tests were used to compare baseline and hyperoxia measurements in normal and diabetic patients. Bonferroni's correction was applied when multiple *t* tests were performed using a single data set. A *p* value of < 0.05 was considered statistically significant.

#### Results

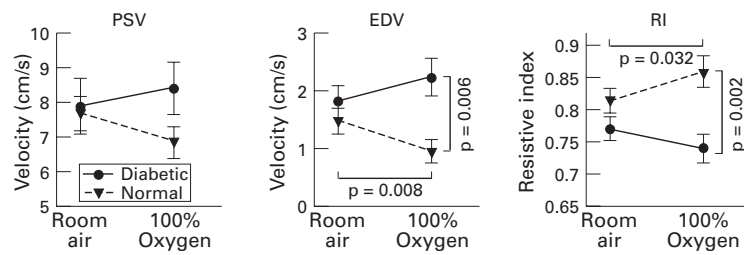
The mean ages for the diabetic patients and the normal control subjects were 29.5 (SD 8.6) and 29.4 (6.3) years, respectively (*p* = NS). There were six females and five males in each group. Data of all CDI measurements were normally distributed according to the Kolmogorov-Smirnov test.

#### ROOM AIR

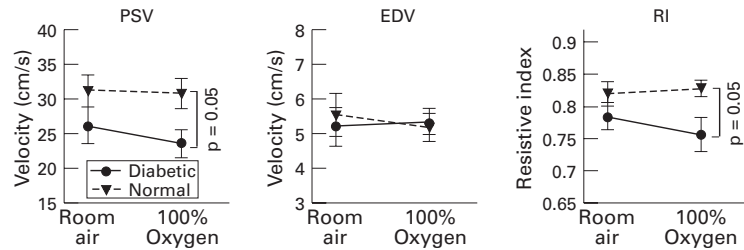
No significant differences were found between groups during room air conditions (Figs 2 and 3).

#### HYPEROXIA

During isocapnic hyperoxia, diabetic patients showed no alteration in PSV, EDV, or RI in the central retinal artery (Fig 2). In contrast, normal subjects demonstrated a significant reduction in central retinal artery EDV (*p* = 0.008) and a significant increase in central retinal artery RI (*p* = 0.032) when breathing 100% oxygen. These changes were accompanied by a significant difference between the two



**Figure 2** Peak systolic velocity (PSV), end diastolic velocity (EDV), and resistance index (RI) from the central retinal artery for both diabetic patients and normal subjects during conditions of room air and hyperoxia. Error bars represent standard error of the mean. The normal controls demonstrate a significant reduction in EDV and a significant increase in RI under conditions of hyperoxia compared with room air. Diabetic patients show no such change. Also during hyperoxia, the groups are significantly different for EDV and RI.



**Figure 3** Peak systolic velocity (PSV), end diastolic velocity (EDV), and resistance index (RI) from the ophthalmic artery for both diabetic patients and normal subjects during conditions of room air and hyperoxia. Error bars represent standard error of the mean. During hyperoxic conditions, diabetic patients have lower PSV and lower RI than the normal controls.

groups for central retinal artery EDV ( $p = 0.006$ ) and for central retinal artery RI ( $p = 0.002$ ) during hyperoxic conditions. Also during hyperoxia, differences were found between the groups for ophthalmic artery PSV ( $p = 0.05$ ) and RI ( $p = 0.05$ ) (Fig 3).

## Discussion

These results confirm that insulin dependent diabetic patients with minimal or no retinopathy display altered ocular haemodynamics. Under conditions of hyperoxia, the diabetic patients and normal subjects were significantly different for central retinal artery EDV and RI. These differences were due in large part to the significant reduction in central retinal artery EDV and significant increase in central retinal artery RI induced by hyperoxia in the normal subjects. Hyperoxia induced no significant change in the ophthalmic artery measures in either group; however, during hyperoxia diabetic patients displayed significantly lower ophthalmic PSV and significantly lower ophthalmic artery RI.

Recent evidence points to good reproducibility of the velocity measurements in the ophthalmic and central retinal artery using colour Doppler imaging.<sup>12</sup> It is important to note, however, that the velocity measurements do not provide a direct measure of flow, as both vessel diameter and velocity are required for this determination. Currently, no technique is available to measure, accurately and non-invasively, retrobulbar vessel diameter. Despite this limitation, good correlation has been found between blood velocity and blood flow both in vivo, using haemodynamic models,<sup>14</sup> and, in vitro, in cerebral vessels.<sup>15 16</sup> Consequently, our results suggest that normal

subjects experience reduced blood flow in the retrobulbar vessels during hyperoxia, while diabetic patients show no change.

To our knowledge, no previous research has compared oxygen reactivity in the retrobulbar vessels for diabetic patients versus normal subjects. Hyperoxia induced changes in the retinal vasculature have been widely studied using a variety of testing modalities—blue field entoptic phenomenon,<sup>7</sup> laser Doppler velocimetry,<sup>5 6</sup> and scanning laser ophthalmoscopy.<sup>8</sup> These studies showed that diabetes blunts or abolishes hyperoxia induced vasoconstriction in affected tissues—that is, retinal blood flow diminishes less than normal or not at all. Our central retinal artery results are predictable from these previous studies. Considerable in vitro and in vivo evidence points to a close correlation of a high resistance index and low end diastolic velocity with increased distal resistance.<sup>14 17 18</sup> Vasoconstriction and reduced flow in the retinal vessels increases vascular resistance distal to the central retinal artery. Our results which showed reduced central retinal artery EDV and increased RI in normal subjects most probably occurred as a result of this increased distal resistance. The lack of central retinal artery response by our diabetic patients suggests that no, or only minimal, change in vascular resistance occurs in these patients, confirming their limited vascular reactivity to hyperoxia.

Previous results have shown significant differences in ophthalmic artery resistance index and in central retinal artery flow velocities in diabetic patients compared with normal age-matched control subjects.<sup>19 20</sup> We also found significant differences between groups in these vessels, but only during the hyperoxia condition not in room air. In previous studies the patient populations were older and had more advanced disease than in our current report. Hyperoxia apparently exacerbates the vascular differences between diabetic patients and normal subjects, presumably by accentuating the diminished autoregulatory capacity in diabetic vessels. Studies have demonstrated that the level of autoregulatory vascular reactivity to 100% oxygen breathing is related to stage of diabetic disease progression.<sup>6 7</sup> These results suggest that the imposition of hyperoxia and the measurement of retrobulbar vascular response may aid in more accurately quantifying the stage of vascular dysfunction in diabetic patients. Such a non-invasive test may be particularly enlightening when used to evaluate patients who exhibit normal retrobulbar flow velocities during room air conditions.

Visual function as measured by contrast sensitivity, colour perception, and electroretinogram is known to be depressed in diabetic patients with early disease and good visual acuity.<sup>8 21-23</sup> Tissue hypoxia has been implicated as the cause for this early vision loss associated with diabetes. Our finding that retrobulbar blood velocity differences between normal subjects and diabetic patients are seen more clearly under conditions of hyperoxia lends support to this theory. Further study which

determined the extent of association, if any, between retrobulbar vascular reactivity to hyperoxia and visual function may provide insight into the mechanism of vision loss associated with the disease.

In summary, institution of isocapnic hyperoxia provides for significant differences in the ophthalmic and central retinal artery blood flow velocities in diabetic patients with early disease compared with normal subjects. These results demonstrate that diabetic patients with minimal or no retinopathy suffer from irregular ocular vascular function in the major vessels feeding the eye. The relation of this irregularity to disease progression and concomitant vision loss is a topic requiring further investigation.

Supported by NIH grant EY 10801. Dr A Harris is a recipient of the William and Mary Greve Award from Research to Prevent Blindness.

- 1 Cogan D, Toussaint D, Kuwabara T. Retinal vascular patterns. IV Diabetic retinopathy. *Arch Ophthalmol* 1961;66:366-78.
- 2 Kohner EM, Oakeley NW. Diabetic retinopathy. *Metabolism* 1975;24:1085-102.
- 3 Sieker HO, Hickman JB. Normal and impaired retinal vascular reactivity. *Circulation* 1953;7:79-3.
- 4 Hickman JB, Sieker HO, Frayser R. Studies of retinal circulation and A-V oxygen difference in man. *Trans Am Clin Climatol Assoc* 1959;71:31-4.
- 5 Riva CE, Grunwald JE, Sinclair SH. Laser Doppler velocimeter study of the effect of pure oxygen breathing on retinal blood flow. *Invest Ophthalmol Vis Sci* 1983;24:47-51.
- 6 Grunwald JE, Riva CE, Brucker AJ, Sinclair SH, Petrig B. Altered retinal vascular response to 100% oxygen breathing in diabetes mellitus. *Ophthalmology* 1984;91:1447.
- 7 Fallon TJ, Maxwell DL, Kohner EM. Autoregulation of retinal blood flow in diabetic retinopathy measured by the blue light entoptic technique. *Ophthalmology* 1987;4:1410.
- 8 Harris A, Arend O, Danis R, Evans D, Wolf S, Martin B. Hyperoxia improves contrast sensitivity in early diabetic retinopathy. *Br J Ophthalmol* 1996;80:209-13.
- 9 Alm A, Bill A. Ocular circulation. In: Moses R, Hart W, eds. *Adler's physiology of the eye: clinical applications*. St Louis: CV Mosby, 1987:183-203.
- 10 Diabetic Retinopathy Study Report 7. A modification of the Arlie House classification of diabetic retinopathy. *Invest Ophthalmol Vis Sci* 1981;21:210.
- 11 Lieb WE, Cohen SM, Merton DA, Shields JA, Mitchell DG, Goldberg BB. Color Doppler imaging of the eye and orbit. Technique and normal vascular anatomy. *Arch Ophthalmol* 1991;109:527-31.
- 12 Harris A, Williamson T, Martin B, Shoemaker J, Sergott R, Spaeth G, et al. Test/retest reproducibility of color Doppler imaging assessment of blood flow velocity in orbital vessels. *J Glaucoma* 1995;4:281.
- 13 Harris A, Arend O, Kopecky K, Caldemeyer K, Wolf S, Sponsel E, Martin B. Physiological perturbation of ocular and cerebral blood flow as measured by scanning laser ophthalmoscopy and color Doppler imaging. *Surv Ophthalmol* 1994;38:S81-6.
- 14 Spencer J, Giussani D, Moore P, Hanson M. In vitro validation of Doppler indices using blood and water. *J Ultrasound Med* 1991;10:305-8.
- 15 Hansen N, Stonestreet B, Rosenkrantz T, Oh W. Validity of Doppler measurements of anterior cerebral artery blood flow velocity: correlation with brain blood flow in piglets. *Pediatrics* 1983; 72:526-31.
- 16 Rosenberg A, Narayanan V, Jones M. Comparison of anterior cerebral artery blood flow velocity and cerebral blood flow during hypoxia. *Pediatric Res* 1985;19:67-70.
- 17 Adamson S, Langille B. Factors determining aortic and umbilical blood flow pulsatility in fetal sheep. *Ultrasound Med Biol* 1992;18:255.
- 18 Downing G, Yarlagadda A, Maulik D. Comparison of the pulsatility index and input impedance parameters in a model of altered hemodynamics. *J Ultrasound Med* 1991;10:317.
- 19 Tamaki Y, Nagahara M, Yamashita H, Kikuchi M. Analysis of blood flow velocity in the ophthalmic artery by color Doppler imaging. 2 Studies on diabetic eyes. *Acta Soc Ophthalmol Jap* 1993; 97:961-6.
- 20 Goebel W, Lieb W, Ho A, Sergott R, Farhoumand R, Grehn F. Color Doppler imaging: a new technique to assess orbital blood flow in patients with diabetic retinopathy. *Invest Ophthalmol Vis Sci* 1995;36:864-70.
- 21 Dileo M, Caputo S, Palsini B, Porciatti V, Mimella A, Graco A, et al. Nonselective loss of contrast sensitivity in visual system testing in early type I diabetes. *Diabetes Care* 1992; 15:620-5.
- 22 Carr R. Hue discrimination and S cone pathway sensitivity in early diabetic neuropathy. *Invest Ophthalmol Vis Sci* 1990;15:1008-15.
- 23 Boschi D, Frosini M, Mencucci R, Sodi A. The influence of early diabetes on the pattern electroretinogram. *Doc Ophthalmol* 1989;71:369-73.



## Altered retrobulbar vascular reactivity in early diabetic retinopathy

David W Evans, Alon Harris, Ronald P Danis, et al.

*Br J Ophthalmol* 1997 81: 279-282

doi: 10.1136/bjo.81.4.279

---

Updated information and services can be found at:

<http://bjo.bmj.com/content/81/4/279.full.html>

---

### References

*These include:*

This article cites 19 articles, 9 of which can be accessed free at:

<http://bjo.bmj.com/content/81/4/279.full.html#ref-list-1>

Article cited in:

<http://bjo.bmj.com/content/81/4/279.full.html#related-urls>

### Email alerting service

Receive free email alerts when new articles cite this article. Sign up in the box at the top right corner of the online article.

---

### Topic Collections

Articles on similar topics can be found in the following collections

[Retina](#) (1217 articles)

---

### Notes

---

To request permissions go to:

<http://group.bmj.com/group/rights-licensing/permissions>

To order reprints go to:

<http://journals.bmj.com/cgi/reprintform>

To subscribe to BMJ go to:

<http://group.bmj.com/subscribe/>