

## LETTERS TO THE EDITOR

**Recurrent uveitis in a patient with adult onset cyclic neutropenia associated with increased large granular lymphocytes**

EDITOR.—A 35-year-old white man was referred with a 1 month history of recurrent bilateral uveitis.

The patient had a history of cyclic neutropenia beginning at age 19. Severe neutropenia (total neutrophil count as low as 68 cells  $\times 10^6/l$ ), lasting about 3 days, was documented to occur at the time of clinical symptoms. Prednisone produced a marked diminution in episodes of symptomatic neutropenia.

At age 35, the patient developed iritis in his left eye during a 'crisis'. This was treated with 0.1% dexamethasone phosphate solution. The anterior chamber inflammatory reaction subsided, but 1+ cells persisted in the vitreous despite an injection of methylprednisolone 40 mg into the sub-Tenon's capsule. The fundus was normal. An extensive immunological examination and HLA-B27 determination were negative or normal. The uveitis resolved as the crisis subsided. Recurrent episodes of uveitis in the left eye occurred episodically, but always at the time of neutropenic crisis and despite topical and systemic anti-inflammatory therapy.

Development of cataract reduced the visual acuity to counting fingers at 1 foot. Cataract extraction with posterior chamber lens implantation resulted in stable visual acuity of 20/30 (5 year follow up) despite continued episodes of iritis.

## COMMENT

Cyclic neutropenia is a rare disorder characterised by regular oscillations in blood neutrophil counts, as well as other blood cells.<sup>1</sup> Cycling occurs regularly every 21 days and lasts 3-6 days in most of the cases.<sup>2-4</sup> The patient described here presented with cyclic episodes of neutropenia occurring every 18-25 days and lasting for 3-5 days. The patient's neutrophil counts were repeatedly below 800 cells  $\times 10^9/l$  at the lowest and no changes in other leucocyte or platelet counts were observed.

During neutropenic episodes, patients may experience a wide variety of symptoms, from malaise and low grade fever to severe life threatening gastrointestinal infections and, although there is moderate morbidity associated with the disease, its course is usually benign.<sup>5</sup> Conjunctivitis has been described.<sup>1</sup> Iridocyclitis associated with neutropenic cycling and refractory to therapy has not been described previously. Extensive and repeated laboratory investigations for an underlying cause of the uveitis in our patient were negative except for large granular lymphocytes and an IgG antineutrophil antibody, both characteristic of cyclic neutropenia.

Many therapeutic strategies have been used in the management of patients with cyclic neutropenia. Splenectomy, testosterone, etiocholanolone, and endotoxin have been employed, all to some therapeutic effect.<sup>6</sup> The response to alternate day low dose prednisone therapy has been particularly successful for patients with the adult onset of the disease.<sup>6</sup> Our patient was managed with 5-25 mg of prednisone every other day, with significantly reduced symptomatology and neutrophil cycling. More recently, correction has been reported with granulocyte macrophage-

colony stimulating factor (GM-CSF)<sup>7</sup> and granulocyte-colony stimulating factor (G-CSF).<sup>8</sup> Although a direct cause-effect association between the recurrent uveitis present in this patient and adult onset cyclic neutropenia cannot be definitively established, the existence of different immune system abnormalities (for example, proliferation of large granular lymphocyte cells, inversion of the CD4:CD8 ratio, presence of different autoantibodies) in patients with cyclic neutropenia and large granular lymphocytosis may contribute to the recurrence of uveitis and its refractoriness to conventional therapy.

ALEJANDRO RODRIGUEZ

*Immunology and Uveitis Service, Department of Ophthalmology, Massachusetts Eye and Ear Infirmary, Harvard Medical School, Boston, MA, USA*

ROBERT A YOOD

*Division of Rheumatology, Fallon Clinic, Worcester, MA, USA*

THOMAS J CONDON

*Division of Ophthalmology, Fallon Clinic, Worcester, MA, USA*

C STEPHEN FOSTER

*Immunology and Uveitis Service, Department of Ophthalmology, Massachusetts Eye and Ear Infirmary, Harvard Medical School, Boston, MA, USA*

Correspondence to: C Stephen Foster, MD, Massachusetts Eye and Ear Infirmary, 243 Charles Street, Boston, MA 02114, USA.

Accepted for publication 11 December 1996

- 1 Wright DG, Dale DC, Fauci AS, Wolff SM. Human cyclic neutropenia: clinical review and long-term follow-up of patients. *Medicine* 1981;60:1-13.
- 2 Dale DC, Hammond WP. Cyclic neutropenia: a clinical review. *Blood Rev* 1988;2:178-85.
- 3 Kawaguchi Y, Kobayashi M, Tanabe A, Hara M, Nishi Y, Usui T, et al. Granulopoiesis in patients with congenital neutropenia. *Am J Hematol* 1985;20:223-34.
- 4 Loughran TP Jr, Clark EA, Price TH, Hammond WP. Adult-onset cyclic neutropenia is associated with increased large granular lymphocytes. *Blood* 1986;68:1082-7.
- 5 Wallis WJ, Loughran TP, Kadin ME, Clark EA, Starkebaum GA. Polyarthritides and neutropenia associated with circulating large granular lymphocytes. *Ann Intern Med* 1985;103:357-62.
- 6 Wright DG, Fauci AS, Dale DC, Wolff, SM. Correction of human cyclic neutropenia with prednisolone. *N Engl J Med* 1978;298:295-300.
- 7 Kurzrock R, Talpaz M, Gutterman JU. Treatment of cyclic neutropenia with very low doses of GM-CSF. *Am J Med* 1991;91:317-8.
- 8 Migliaccio AR, Migliaccio G, Dale DC, Hammond WP. Hematopoietic progenitors in cyclic neutropenia: effect of granulocyte colony-stimulating factor in vivo. *Blood* 1990;75:1951-9.

**Delayed acute retinal necrosis after herpetic encephalitis**

EDITOR.—The herpes virus family, especially herpes simplex virus (HSV) and varicella zoster virus (VZV), has been associated with acute retinal necrosis (ARN)<sup>1,2</sup> and these viruses also represent an important cause of encephalitis.<sup>3</sup> Cases of retinitis in patients with a history of previous herpetic encephalitis, although rare, have been reported<sup>4,5</sup>; a delay between the diagnosis of encephalitis and the onset of ocular symptoms has been reported to be as long as from 1 to 5 months,<sup>6,7</sup> but an interval of up to 5 years has been recorded.<sup>8</sup> We report here two patients who developed the clinical picture of ARN 7 and 17 years after having had herpetic encephalitis.

## CASE REPORTS

*Case 1*

CH, a 27-year-old white woman presented with a 10 day history of deterioration of vision in her left eye. Seven years previously she had been diagnosed as having HSV encephalitis, confirmed by electron microscopy and viral culture of a brain biopsy specimen. The sequelae of HSV encephalitis included right homonymous hemianopia. Visual acuities were 6/5 right eye and light perception left eye. The right eye was normal. Examination of the left eye revealed intense vitritis, and retinal thickening with extensive peripheral retinal necrosis and patches of central retinal necrosis. The optic disc was swollen and there was an inferior retinal detachment, extending to the macula. There was extensive retinal vasculitis and haemorrhage. ARN was diagnosed on clinical grounds and she was treated with intravenous acyclovir, 10 mg/kg three times daily for 8 days, and then oral acyclovir 800 mg five times daily for 12 weeks. After this period the dose was reduced to 400 mg five times daily, which she is still taking.

Vitreous biopsy and lumbar puncture were performed. No virus was found in the CSF; however, using techniques based on polymerase chain reaction (PCR) the vitreous specimen revealed the presence of HSV-1 and VZV DNA. The right eye has remained uninvolved, and the patient has retained the left hemifield of vision in the right eye with visual acuity of 6/5.

*Case 2*

GP, a 17-year-old white man presented with a 1 week history of blurring of vision in his left eye. Vision in the right eye had been poor since childhood as a result of optic atrophy. HSV encephalitis had occurred at 1 week of age, which was diagnosed clinically and confirmed on aspiration of fluid from a skin vesicle.

Visual acuities, on presentation, were of counting fingers in both eyes. The right eye revealed sector iris atrophy temporally and optic atrophy. The left eye had significant vitritis, peripheral retinal necrosis, and disc swelling. No iris atrophy was present in this eye and there were no records of optic nerve or peripheral retinal involvement before the current presentation.

A clinical diagnosis of ARN was made and the patient was treated with intravenous acyclovir 10 mg/kg three times daily and oral prednisolone (initially 80 mg/day). Unfortunately a vitreous sample was not available for PCR analysis.

After 1 week on intravenous acyclovir he was given a course of oral acyclovir for 12 weeks (800 mg five times a day) which was then reduced to a maintenance dose of 400 mg five times a day. At his last examination he had visual acuities of hand movements in his left eye, and there was no inflammatory activity in either eye.

## COMMENT

Delay between the onset of viral encephalitis and ARN has been mentioned previously in the literature. Intervals of 1<sup>7</sup> and 5 months<sup>6</sup> have been reported with the mention in one case of a 5 year interval,<sup>8</sup> but without any other information regarding the clinical and diagnostic aspects of both the encephalitis and ARN. In our patients the delays were 7 years

and 17 years respectively, and the occurrence of ARN in these patients was particularly devastating as both had pre-existing visual impairment related to previous encephalitis. The explanation for such prolonged intervals include the possibility of persistent latent virus in the CNS with spread to the eye via the optic nerve, or the presence of latent virus in the ocular tissue since the time of primary infection. Cases with asymptomatic peripheral chorioretinal lesions have been reported, and these lesions were felt to be an indication of persistence of the virus in the retina.<sup>9</sup> Treatment in the acute phase is by systemic acyclovir, which has a potent antiviral action against varicella zoster and herpes simplex. Acyclovir is only effective against actively replicating virus,<sup>10</sup> and cannot eradicate latent virus, such that any protective effect is questionable.<sup>11</sup> The risk of further reactivation of the virus in our patients is unclear. For this reason, and especially taking into consideration the severe visual sequelae from their herpetic encephalitis and the further loss of vision after the episode of ARN, both patients have been maintained indefinitely on low dose acyclovir (400 mg five times a day).

Considering that significant visual loss usually results from retinal and optic nerve involvement as a late sequela of congenital HSV infection and, also, potentially from HSV encephalitis, the need for prophylactic use of systemic antiviral drugs has to be considered. The presence of retinal lesions in the retinal periphery in cases of congenital HSV infection, as described by others,<sup>9</sup> may indicate a higher risk for later ocular involvement, and may be used as a marker for use of prophylactic therapy. The need of prophylaxis after encephalitis may be more difficult to establish, but should be considered in cases of visual loss due to cortical involvement.

C E PAVÉSIO  
D K CONRAD  
P J MCCLUSKEY  
S M MITCHELL  
H M A TOWLER  
S LIGHTMAN

Department of Clinical Ophthalmology,  
Moorfields Eye Hospital, Institute of Ophthalmology,  
City Road, London EC1V 2PD

Correspondence to: Professor S Lightman, Department of Clinical Ophthalmology, Moorfields Eye Hospital, City Road, London EC1V 2PD.

Accepted for publication 11 December 1996

- Culbertson WW, Blumenkrantz MS, Pepose JS, Stewart JA, Curtin VT. Varicella zoster virus is a cause of the acute retinal necrosis syndrome. *Ophthalmology* 1986;**93**:559-69.
- Lewis ML, Culbertson WW, Post JP, Miller D, Kokame GT, Dix RD. Herpes simplex virus type 1. A cause of the acute retinal necrosis syndrome. *Ophthalmology* 1989;**96**:875.
- Griffith JF, Ch'ien LT. Herpes simplex virus encephalitis. Diagnostic and treatment considerations. *Med Clin North Am* 1983;**67**:991-1008.
- Johnson BL, Wisotzkey HM. Neuroretinitis associated with herpes simplex encephalitis in an adult. *Am J Ophthalmol* 1977;**83**:381-9.
- Bloom JN, Katz JL, Kaufman HE. Herpes simplex retinitis and encephalitis in an adult. *Arch Ophthalmol* 1977;**95**:1798-9.
- Ahmadieh H, Sajjadi H, Azarmina M, Kalani H. Association of herpetic encephalitis with acute retinal necrosis syndrome. *Ann Ophthalmol* 1991;**23**:215-9.
- Gartry DS, Spalton DJ, Tilzey A, Hykin PG. Acute retinal necrosis syndrome. *Br J Ophthalmol* 1991;**75**:292-7.
- Boer JH, Luyvendijk L, Rothova A, Baarsma GS, de Jong PTVM, Bollemeijer J-G, et al. Detection of intraocular antibody production to herpesviruses in acute retinal necrosis syndrome. *Am J Ophthalmol* 1994;**117**:201-10.
- el Azazi M, Malm G, Forsgren M. Late ophthalmologic manifestations of neonatal herpes simplex virus infection. *Am J Ophthalmol* 1990;**109**:1-7.

10 Laskin OL. Acyclovir: pharmacology and clinical experience. *Arch Intern Med* 1984;**144**:1241.

11 Palay DA, Sternberg Jr P, Davis J, Lewis H, Holland GN, Mieler WF, et al. Decrease in the risk of bilateral acute retinal necrosis by acyclovir therapy. *Am J Ophthalmol* 1991;**112**:250-5.

### Late treatment of methanol blindness

EDITOR.—Methanol intoxication is a severe and often blinding disease. Irreversible visual loss may occur within hours to days after ingestion. Treatment regimens are aimed at controlling acid-base balance, removing the toxic agent by haemodialysis, or using ethanol solution as a competitive drug. If treatment is delayed beyond the first hours after ingestion, permanent damage to the optic pathways may occur. We report on successful treatment of methanol (methyl alcohol) induced blindness with late steroids and vitamin B-1.

### CASE REPORT

A 40-year-old man was admitted to our eye department with sudden bilateral visual loss. He was generally healthy except that he was a heavy smoker and consumed alcohol regularly. During a period of 4-10 days before admission, the patient consumed pure methanol used for cleaning metal electrical wires. One day before admission, the patient complained of vomiting, nausea, and abdominal pain; however, a complete medical examination in the emergency room was inconclusive and his vision was not affected. On admission, physical and neurological examination were normal. Ophthalmic examination revealed visual acuity of hand movements in the right eye and 50 cm counting fingers in the left eye. Ocular examination was normal except for mild dilatation of the pupils which reacted sluggishly to light. No fundoscopic abnormalities were observed. One day after admission, visual acuity deteriorated to no light perception in the right eye and remained as counting fingers in the left eye, with a large central scotoma. Relative afferent papillary defect was detected in the right eye. Visual evoked response (VER) was undetectable in the right eye and prolonged latency was detected in the left eye (Fig 1A). Computed tomography of the brain and an electroencephalogram were normal. Blood laboratory tests were normal with no evidence of metabolic acidemia. Nine to 15 days after methanol ingestion, no significant recovery was evident. The conventional treatment with bicarbonate was longer not appropriate because the patient's acid-base balance was normal. Furthermore, the treatments with ethanol or haemodialysis were too late to be effective. Medical therapy was initiated including prednisone 60 mg/day by mouth and an intramuscular injection of vitamin B-1 100 mg/day. Three days after initiating the treatment, visual acuity, visual field analysis, and VER showed evidence of significant improvement in both eyes (Fig 1B). The patient was treated with vitamin B-1 injections for 20 days and with oral prednisone for 1 month with gradual tapering off. Seven weeks later the visual acuity had fully recovered in both eyes to the 20/20 level. Visual fields of both eyes showed only slight concentric constriction with no scotoma; VER demonstrated normal patterns on both eyes (Fig 1C).

### COMMENT

Methanol intoxication may be associated with severe damage to the visual pathways, potentially leading to permanent blindness. In an outbreak of methanol intoxication involving 320 people, Benton *et al* stated that in cases of

visual impairment or blindness, if vision did not return to normal within 6 days, recovery was not complete and the vision deteriorated.<sup>1</sup> Other reported cases of methanol intoxication also demonstrated the guarded prognosis of visual loss.<sup>2</sup> Thus, prolonged visual malfunction is considered an unfavourable prognostic sign, and vision almost never fully recovers. Delayed recovery is rare, and usually not complete. Scrimgeour *et al*<sup>3</sup> reported a patient who, after 12 days of blindness, regained vision and after 12 weeks his vision was hand movements in one eye and 10/20 in the other eye. One case, reported by Buzna *et al*, finally recovered to 10/20 in one eye and 2/20 in the other after treatment with ethanol and various vitamins including vitamin B-1.<sup>4</sup> The present case is an extreme exception since the patient experienced almost absolute blindness (NLP and CF) for at least 4 days, as late as 15 days after methanol was first ingested, and yet recovered to almost perfect vision of 20/20 in both eyes. An interval between methanol consumption and deterioration of vision is typical. Therefore, severe visual loss in a young and apparently healthy individual should raise a suspicion of methanol intoxication, even if it was consumed several days before presentation of symptoms. During hospitalisation our patient was under close supervision, he was practically blind and totally dependent, there-

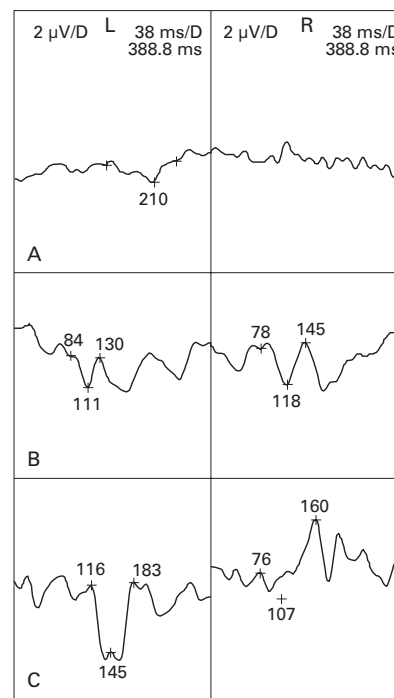


Figure 1 Visual evoked response (VER) with pattern reversal recorded during the acute phase, initial therapy, and after recovery. (A) Day 1, visual acuity, right eye no light perception, left eye counting fingers 50 cm. No structured pattern was recorded from the right eye and prolonged latency was recorded over the left eye with a very low amplitude. These recordings indicate a non-functioning right optic pathway and severe damage to the left optic nerve. (B) Day 7, after 3 days of treatment, visual acuity was right eye hand movement and left eye 20/100. A definitive pattern is evident from both sides, however, latency is still prolonged corresponding to the recovery process of the optic pathways. (C) Seven weeks after methanol blindness visual acuity recovered in both eyes to 20/20. VER over the right eye demonstrates a residual prolonged latency whereas the VER pattern of the left eye returned to normal.

fore we assume that he did not consume alcohol during this period—that is, ethylism did not play a role in his clinical symptoms.

The rationale for using steroids in methanol toxic neuropathy was based on the clinical experience with this drug being effective in other forms of optic neuropathies. The potential therapeutic effect of steroids on methanol optic neuropathy might be a reduction in the oedema of the nerve sheaths caused by the histotoxic anoxia as suggested by Sharpe *et al.*<sup>5</sup> Steroids are usually not used to treat ill effects of ethylism. Vitamin B-1 is given for treatment of Wernicke-Korsakoff syndrome, following prolonged ethanol consumption. We assumed that since vitamin B-1 is highly effective in ethanol intoxication, it might well be effective in methanol intoxication. Other ocular associated pathologies in which thiamine may be effective are nutritional amblyopia, and Leigh's disease (infantile necrotising encephalomyopathy), both irrelevant in this case.

In conclusion, the combination of steroids and vitamin B-1 was highly effective in treating severe methanol optic neuropathy. We do not know whether using only one of the drugs might be sufficient but, since the risk of permanent blindness is high, we recommend using this combination in the event of methanol intoxication.

YGAL ROTENSTREICH  
EHUD I ASSIA

Department of Ophthalmology, Meir Hospital, Israel

ANAT KESLER

Department of Neurology, Meir Hospital, Israel

Correspondence to: Ehud I Assia, Department of Ophthalmology, Meir Hospital, Sapir Medical Center, Kfar Saba, 44281, Israel.

Accepted for publication 12 February 1997

- 1 Benton CD, Calhoun FP. The ocular effect of methyl alcohol poisoning: report of catastrophe involving three hundred and twenty persons. *Trans Pa Acad Ophthalmol Otolaryngol* 1952;56:1677-85.
- 2 Scrimgeour EM. Outbreak of methanol and isopropanol poisoning in New Britain, Papua New Guinea. *Med J Aust* 1980;2:36-8.
- 3 Scrimgeour EM, Dethlefs RF, Kevau I. Delayed recovery of vision after blindness caused by methanol poisoning. *Med J Aust* 1982;2:481-3.
- 4 Buzna E, Cernea D. [The therapeutic approach in optic neuropathy due to methyl alcohol.] *Oftalmologia (Romania)* 1991;35:39-42.
- 5 Sharpe JA, Hostovsky M, Bilbao JM, Rewcastle NB. Methanol optic neuropathy: a histological study. *Neurology* 1982;32:1093-100.

### Intracranial plasmacytoma presenting with optic nerve compression

EDITOR,—Neurological complications are not uncommon in patients with multiple myeloma; however, an isolated intracranial plasmacytoma is rare. We describe a patient with multiple myelomatosis and a single intracranial lesion presenting with optic nerve compression.

#### CASE REPORT

A 73-year-old woman had had symptoms of intermittent blurring of vision in the right eye for several months and had consulted her optometrist, who had reassured her. She subsequently presented to her general practitioner with a 3 month history of left upper arm and right lower chest 'rib' pain, anorexia, weight loss, malaise, and fatigue. Skeletal survey revealed multiple extrapleural lesions bilaterally, with associated lytic bone destruction at each site. There was also evidence of lysis of the transverse process of T1 and facet complex of C7 on the right. She was referred urgently for further investigation.




Figure 1 Grey scale representation of the generalised constriction of the patient's right eye central visual field as assessed by a Humphrey visual field analyser 24-2 full threshold program.

On admission examination revealed no focal neurological deficit and investigation revealed hypercalcaemia (corrected calcium 2.80 mmol/l), raised serum protein (89 g/l), raised plasma viscosity (2.08 mPa), a venous IgG type  $\kappa$  paraprotein of 40 g/l, and a urine Bence-Jones monoclonal band of  $\kappa$  light chains of 0.34 g/l.

Abdominal ultrasound revealed two mass lesions in the anterior abdominal wall anterior to the liver. Bone scan showed multiple hot spots, especially in the posterior ribs and increased uptake in the sternum and left sacroiliac joint.

A diagnosis of multiple myeloma was made, the patient was rehydrated intravenously, and treated with intravenous steroids, melphalan, and radiotherapy. She was referred for ophthalmic assessment because of the history of blurred vision.

Best corrected visual acuity was found to be 6/60 N 14 right eye, 6/9 N 8 left (noted to be 6/9 in the right eye in 1986). A right relative afferent pupillary defect (RAPD) was detected and generalised constriction of the central 24-2 (Humphrey full threshold, Fig 1) with inferior altitudinal scotoma was noted on the right. There were minimal cortical lens opacities and funduscopy did not indicate any optic disc hyperaemia, swelling, or pallor. An urgent cranial magnetic resonance image was requested and this revealed a smoothly outlined mass in the right middle cranial fossa at the apex of the orbit compressing the optic nerve and enhancing with gadolinium (Fig 2); this mass appeared to arise from the dura mater and was the only intracranial mass detected. A diagnosis of intracranial plasmacytoma secondary to multiple myeloma was made and she was referred for radiotherapy to the lesion. Six weeks later visual acuity was 6/9 N5 right and left eyes, the right RAPD was barely detectable, and optic disc appearances remained normal.

#### COMMENT

Multiple myeloma accounts for 1% of all malignancies and 10% of haematological malignancies. Systemic signs and symptoms are due to pathological plasma cell proliferation, secondary metabolic alteration, and associated immunological dysfunction. Plasmacytomas are tumours comprising a proliferation of abnormal plasma cells; they demonstrate monoclonal intracellular immunoglobulins using immunological staining techniques, distinguishing them from plasma cell granulomas which show a polyclonal pattern of several different heavy and light chains.

Neurological complications in multiple myeloma were first classified by Clark<sup>1</sup> into: (a)

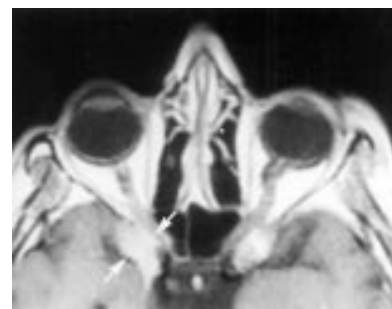


Figure 2 T1 weighted, gadolinium enhanced, axial magnetic resonance image illustrating the enhancing lesion on the right compressing the intracranial optic nerve. (The bright image on the left was non-enhancing and reported as a probable old venous thrombosis.)

cranial nerve palsies; (b) intracranial tumour syndromes; and (c) intraorbital syndromes.

Intracranial tumour syndromes tend to present with multiple neurological symptoms and signs, occasionally with those of a space occupying lesion and raised intracranial pressure.

Intraorbital involvement commonly presents with optic neuropathy and this is usually secondary to direct infiltration, a retrobulbar tumour, or a hyperviscosity state.<sup>2</sup> Optic neuropathy is rare secondary to an intracranial lesion and is usually associated with other neurological signs in these latter cases.<sup>2</sup> Isolated optic nerve compression from an intracranial plasmacytoma with no other focal neurological signs has only rarely been reported in the literature as individual case reports.<sup>3,4</sup> Two cases found in the literature were both initially treated as retrobulbar neuritis (RBN)—both with transient alleviation of symptoms with systemic steroid therapy; diagnosis was eventually made after a period of months by pneumoencephalography and craniotomy (in the absence of more sophisticated imaging techniques). A further case of intracranial plasmacytoma presenting with a long history of fluctuating vision and headache was treated as (biopsy unconfirmed) cranial arteritis with systemic steroids for 4½ years before diagnosis.<sup>2</sup>

Our case demonstrates a single intracranial deposit, and its magnetic resonance imaging appearance, resulting in an isolated optic neuropathy.

Magnetic resonance imaging is now the investigation of choice in patients with atypical optic neuropathies and no obvious orbital lesion.

Intracranial lesions may arise from the dura mater, brain parenchyma, or adjacent lytic skull lesion in which case the dura has been postulated to prevent invasion.<sup>1,5</sup>

Systemic agents—for example, melphalan, have little proved activity against intracranial lesions and extracranial radiotherapy remains the treatment of choice combined with chemotherapy for any systemic disease, as in this case.

R MAINI  
C J MACEWEN  
Department of Ophthalmology,  
Ninewells Hospital and Medical School,  
Dundee DD1 9SY

Correspondence to: R Maini.

Accepted for publication 28 January 1997

- 1 Clarke E. Cranial and intracranial myelomas. *Brain* 1954;77:61-81.
- 2 Coppeto JR, Monteiro MLR, Collias J, Uphoff D, Bear L. Foster-Kennedy syndrome caused by solitary intracranial plasmacytoma. *Surg Neurol* 1983;19:267-72.
- 3 Kamin DF, Hepler RS. Solitary intracranial plasmacytoma mistaken for retrobulbar neuritis. *Am J Ophthalmol* 1972;73:584-6.

- 4 Kennerdell JS, Jannetta PJ, Johnson BL. A steroid sensitive solitary intracranial plasmacytoma. *Arch Ophthalmol* 1974;92:393-8.
- 5 Jordan DR, Drouin J, Berry G, Watson AG. Intracranial plasmacytoma associated with multiple myeloma. *Can J Ophthalmol* 1984;19:275-8.

### Conjunctival and lacrimal sac pigmentation by kohl (eyeliner)

EDITOR.—Abnormal pigmentation of the conjunctiva has been associated with various pathological conditions including melanosis, melanocytic tumours, foreign bodies, systemic disease, topical and systemic use of medications, and industrial exposure to various chemicals.<sup>1 2</sup>

#### CASE REPORTS

In this report, abnormal pigmentation of the conjunctiva and lacrimal sac was noted in 10 patients using kohl (eyeliner, surma) that was made in India.<sup>3-5</sup> This eyeliner is used by millions in the Middle East, Asia, and Africa. The median age of nine women and one man was 52 years (range 40-64 years). All patients had used kohl for many years. The two patients with conjunctival pigmentation had bilateral, diffuse pigmentation of the fornicial and tarsal conjunctiva of the upper and lower eyelids in the form of discrete, punctate black deposits (Fig 1). The other eight patients presented with epiphora and had chronic dacryocystitis associated with obstruction of the lacrimal passages, including the lacrimal canaliculi and common lacrimal canaliculus. Three of these patients also had dacryocutaneous fistulas. During dacryocystorhinostomy, focal to diffuse black pigmentation of the lacrimal sac was observed in seven individuals, in scar tissue obstructing the common canaliculus in one, in the subcutaneous tissues around the fistula in one, and in the periosteum of the lacrimal sac fossa in another. The black pigmentation of the lacrimal sac resembled to some extent malignant melanoma, except for the absence of a mass. Preoperatively, a dark bluish pigmentation was observed around the cutaneous fistula site in one patient. Histologically, the fine to coarse extracellular pigment was often surrounded by a chronic inflammatory infiltrate, mainly lymphocytes with a few plasma cells and neutrophils.

Energy dispersive analysis of x rays of all biopsy specimens revealed a high lead content in the patient's tissues (Fig 2). Other less frequent elements included silicon, carbon, sulphur, silver, magnesium, iron, and aluminium. The kohl used by the patients was

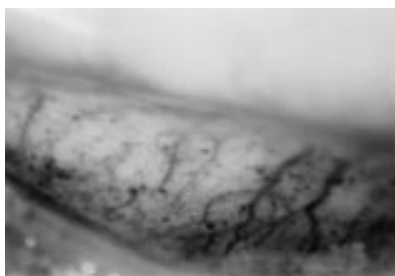


Figure 1 Case 1. The tarsal conjunctiva of the left lower lid shows black pigmentary deposit in kohl user.

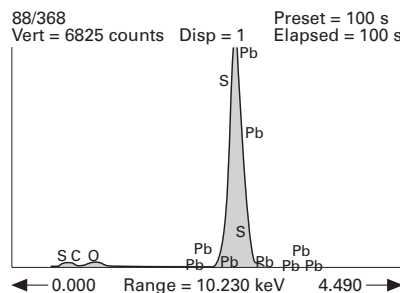


Figure 2 Case 8. Kohl in the wall of lacrimal sac shows high contents of lead (Pb) and sulphur (S). Energy dispersive analysis of x rays.

also tested and showed the same elements as detected in their biopsy specimens.

Radiographic studies of the biopsy specimen from a pigmented lacrimal sac showed a diffuse and dense radiopacity, corresponding to the high metallic content, mainly lead in the tissue.

#### COMMENT

In this study, the findings of a similar composition in the patient's tissues and the kohl used in the area of origin strongly support the clinical diagnosis of kohl pigmentation in the conjunctiva and lacrimal drainage system. The various elements in kohl that caused tissue pigmentation include lead, silver, iron, carbon, and magnesium. Intraoperatively, black pigmentation of the lacrimal sac by kohl may be confused with malignant melanoma if the surgeon is not aware of this entity. A more serious medical problem than pigmentation in our patients is the finding of lead in their tissues. In the past three decades, several well documented cases of lead poisoning (plumbism) have occurred in England<sup>6-9</sup> among Indian and Pakistani children as a

result of applying lead-containing kohl to their eyes. In our study, five patients who were tested for lead toxicity were normal. The reason for this discrepancy is probably related to the dose and site of kohl application. All of our adult patients applied the eyeliner to the eyelid margin for cosmetic reasons while in children a larger amount of kohl is usually instilled into the conjunctival sac for therapeutic reasons.<sup>6-9</sup>

It is interesting to note that a biopsy specimen from the pigmented lacrimal sac that contained lead showed diffuse radiopacity when tested radiologically. This finding may be confusing to the radiologists and/or ophthalmologists if they are not aware of this problem. Dacryostenosis in those patients with lacrimal sac pigmentation is most probably the result of trachoma, which is very common in the Middle East.

Presented at the Association for Research in Vision and Ophthalmology Annual Meeting, Sarasota, Florida 3 May 1990.

The opinions or assertions contained herein are the private views of the authors and should not be construed as being official or as representing the views of the Department of the Army or the Department of Defense.

AHMED A HIDAYAT

Armed Forces Institute of Pathology,  
Washington DC, USA

ROBERT G WEATHERHEAD

ALI AL-RAJHI  
King Khaled Eye Specialist Hospital, Riyadh,  
Saudi Arabia

FRANK B JOHNSON

Armed Forces Institute of Pathology,  
Washington DC, USA

Correspondence to: Ahmed A Hidayat, MD, Department of Ophthalmic Pathology, Armed Forces Institute of Pathology, Washington DC 20306-6000, USA. Accepted for publication 13 January 1997

- 1 Duke-Elder S, ed. *Systems of ophthalmology. Vol 14, part 2. Injuries: non-mechanical injuries.* St Louis: CV Mosby, 1972:1089-128.
- 2 Brothers DM, Hidayat AH. Conjunctival pigmentation associated with tetracycline medication. *Ophthalmology* 1981;88:1212-5.
- 3 Al-Hawi SA. Kohl. In: Wafai MZ, Kalaagi MR, eds. *Nur Al-Ugun, Wa Jame Al-Funun. Light of the eyes and the collector of arts.* Riyadh, Saudi Arabia: King Faisal Center for Research and Islamic Studies, 1986:142-8.
- 4 Tabbara KF, Burd EM. Microbial content of kohl. *Ann Saudi Med* 1986;7:177-9.
- 5 Al-Kaff A, Al-Rajhi A, Tabbara KF, El Yazigi A. Kohl—the traditional eyeliner: use and analysis. *Ann Saudi Med* 1993;13:26-30.
- 6 Warley MA, Blackledge P, Gorman PO. Lead poisoning from eye cosmetics. *BMJ* 1968;1:117.
- 7 Snodgrass GJAI, Ziderman DA, Gulati V, Richards J. Cosmetic plumbism. *BMJ* 1973;4:230.
- 8 Betts PR, Astley R, Raine DN. Lead intoxication in children in Birmingham. *BMJ* 1973;1:402-6.
- 9 Ali AR, Smales ORC, Aslam M. Surma and lead-poisoning. *BMJ* 1978;2:215-6.

Table 1 Clinical data for nine patients with kohl pigmentation

Patient No, age (years), sex	Site of pigmentation	Clinical diagnosis
1, 60, F	Conjunctiva, both eyes	Conjunctival pigmentation; cataract
2, 64, F	Conjunctiva, both eyes	Conjunctival pigmentation; corneal scar; cataract
3, 44, F	Common lacrimal	Chronic dacryocystitis, both eyes; common canaliculus occlusion by pigmented scar, right eye; upper and lower canaliculus occlusion, left eye
4, 52, M	Lacrimal sac, right eye	Chronic dacryocystitis with non-expressible mucocele, right eye
5, 50, F	Lacrimal sac, right eye	Chronic dacryocystitis with mucocele and dacryocutaneous fistula, right eye; blockage of lower canaliculus right eye; common canaliculus right eye and common canaliculus left eye
6, 50, F	Lacrimal sac, left eye	Chronic dacryocystitis, both eyes; partial common canaliculus occlusion, both eyes
7, 40, F	Lacrimal sac, left eye; subcutaneous scar tissue around the fistula	Chronic dacryocystitis with fistula, left eye; pigmentation of subcutaneous tissue around the fistula left eye
8, 55, F	Lacrimal sac, left eye; periosteum of lacrimal sac fossa, left eye	Blockage of upper and lower canaliculi, right eye, blockage of common canaliculus; congenital fistula from skin to common canaliculus
9, 56, F	Lacrimal sac, left eye	Common canaliculus obstruction, both eyes
10, 55, F	Lacrimal sac, right eye	Chronic dacryocystitis, right eye

### An unusual case of map-dot epithelial dystrophy

EDITOR.—Map-dot epithelial dystrophy, also called Cogan's microcystic dystrophy,<sup>1</sup> is a well known and relatively frequent clinical entity. The microscopic basis for the biomicroscopic appearance of the typical superficial corneal opacities and epithelial erosions are intraepithelial cysts and a multilaminated or bilaminated aberrant epithelial basement membrane.<sup>1-5</sup> Therefore, the term epithelial basement membrane dystrophy has been introduced by some authors.<sup>5</sup>

We report a patient with Cogan's corneal dystrophy with histologically proved erythrocyte inclusions in the intraepithelial cysts and a conspicuous clinical appearance not before described.

#### CASE REPORT

In March 1995 a 48-year-old white man reported to our clinic with typical symptoms of recurrent epithelial microerosions mainly on his right eye. He complained of early morning pain and reduced vision for a few weeks but could not recall an earlier ocular trauma. He did not wear contact lenses. Biomicroscopically, bright red intraepithelial inclusions in the corneal epithelium were found in the right eye (Fig 1A); there was no fluorescein staining. The left eye showed a few whitish, map-dot-like epithelial opacities.

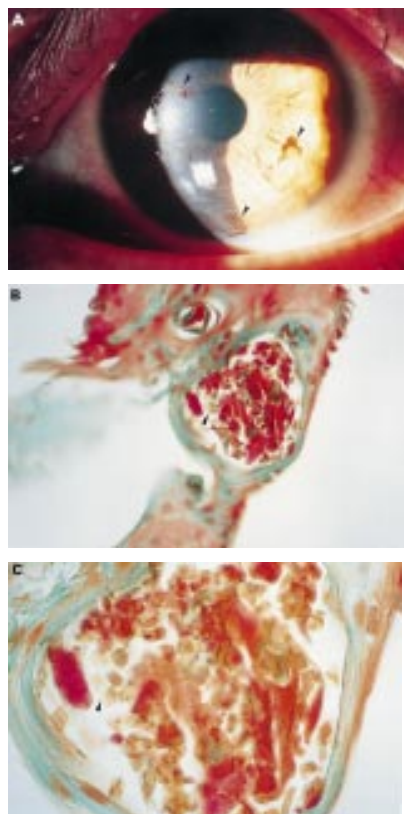


Figure 1 (A) Slit-lamp photograph of right eye. Note red blood-like colour of the inclusions in the map, dot, and fingerprint-like epithelial alterations of the cornea of the right eye (arrowheads). There was no fluorescein staining suggesting that the erythrocytes had already been entrapped intraepithelially. (B) Lower and (C) higher magnification photomicrographs of the corneal abrasion material demonstrating intraepithelial cyst with cell debris, keratin, and numerous erythrocytes (arrowhead) (trichrome stain).

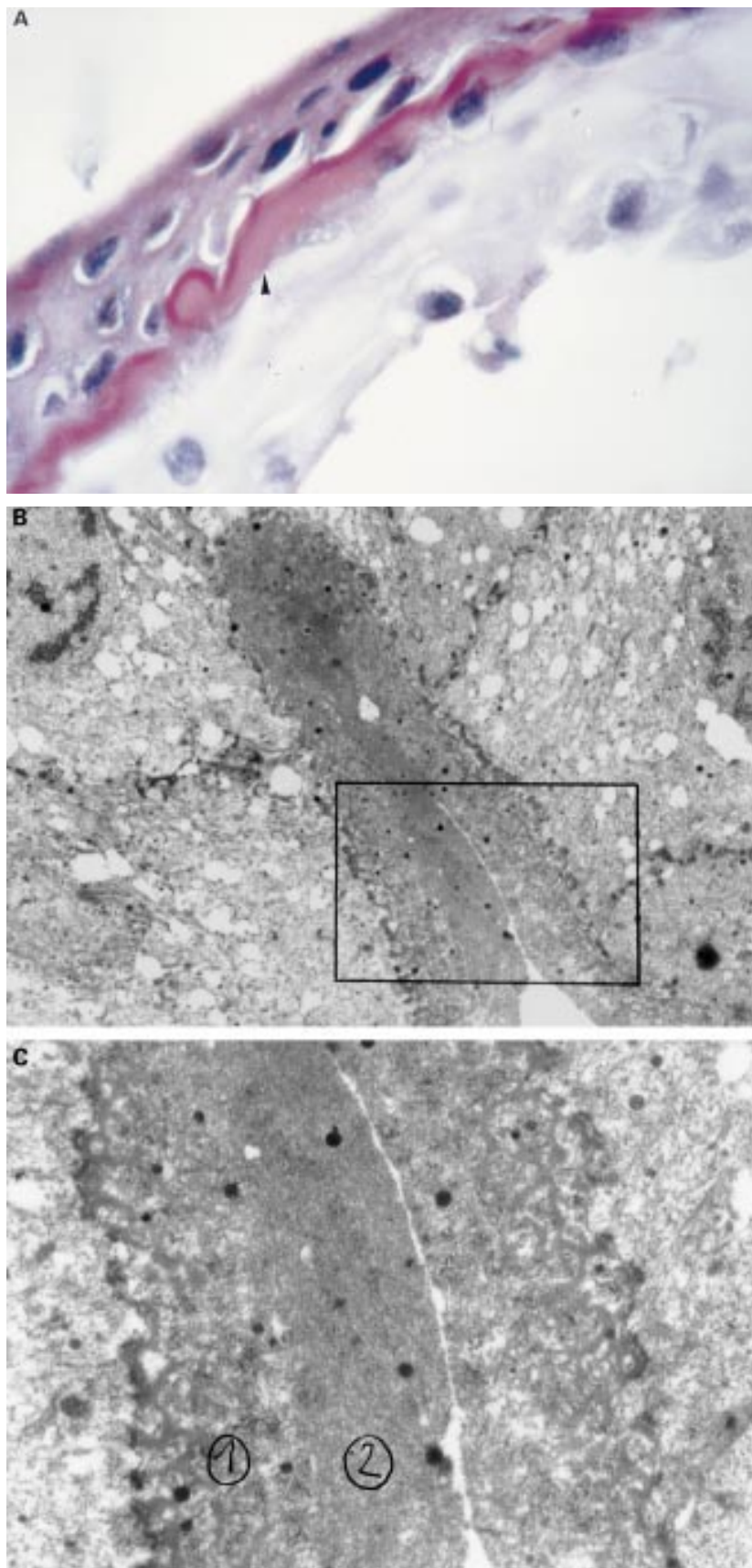


Figure 2 (A) Photomicrograph of the corneal epithelium with bilaminated, intraepithelial basement membrane with folds (arrowhead). Note pale swelling of underlying oedematous basal epithelial cells. (periodic acid Schiff,  $\times 500$ ). (B) Electron micrograph ( $\times 3240$ ) illustrating basement membrane fold with bilaminated, redundant basement membrane. (C) Shows the more loosely arranged superficial layer (1) and the more densely packed second layer (2) beneath it, both containing randomly oriented fibrils in a finely granular matrix (contrasted with uranylacetate and lead citrate,  $\times 9360$ ).

There was no corneal or limbal neovascularisation and only a slight ciliary flush. The corneal stroma, the endothelium, and the anterior chamber were without peculiarities. The eyelid margins showed signs of mild chronic blepharitis, and the tear film was unstable. The visual acuities were 6/6 left eye and 6/7 right eye.

As the clinical appearance on the right eye was unknown to us and to exclude, for example, a bacterial infection, bacterial cultures, conjunctival scrapings, and focal superficial stripping of the corneal epithelium in some of the areas of the red alterations were performed by means of a hockey knife. The bacterial cultures were negative. Therefore, we only prescribed artificial tears.

After a few weeks treatment was stopped because the patient no longer had any symptoms. Biomicroscopically, the red inclusions had completely disappeared without leaving scars. However, there were still typical map-dot epithelial opacities in both eyes. The visual acuity of the right eye had normalised to 6/6.

#### PATHOLOGICAL FINDINGS

The light microscopic examination of the stripped corneal epithelium revealed intraepithelial microcysts containing entrapped cellular debris, keratin, and numerous red blood cells (Fig 1B and C). In addition, a thickened bilaminar aberrant basement membrane with folds was found intraepithelially, visible with

periodic acid Schiff staining (Fig 2A). Electron microscopy again displayed a redundant, bilaminar basement membrane of the epithelial cells with folds (Fig 2B). On microscopy there was no hint of a bacterial infection.

#### COMMENT

We are not aware of any case of map-dot epithelial dystrophy or other corneal disease published previously with intraepithelial blood inclusions. It is useful to know of this corneal alteration because of the differential diagnosis of bacterial infection. It is also interesting because this case shows that blood cells can be included intraepithelially in the cornea under special circumstances despite regular blinking and washing of the ocular surface by the tear film.

The microscopic findings are compatible with previous histological reports on map-dot epithelial dystrophy.<sup>1-5</sup> The aberrant intraepithelial basement membrane may obstruct the normal migration of maturing epithelial cells leading to the disintegration of these cells and the formation of microcysts which may rupture eventually and form corneal erosions.<sup>1-4</sup>

In our case, initially there must have been temporary microerosions, presumably due to ruptured epithelial microcysts to which erythrocytes were attached, which were then incorporated into the epithelial microcysts when the corneal epithelium closed again. The site of origin of the erythrocytes within the

intraepithelial cysts is unknown, although haemorrhage from the eyelid is a possibility. After a few weeks the red inclusions were no longer visible, probably because the entrapped erythrocytes had been phagocytised by macrophages.

GREGOR WOLLENSAK

Department of Ophthalmology,  
University of Freiburg i Br, Killianstrasse 5,  
D-79106 Freiburg i Br, Germany

JOSEF WOLLENSAK

Department of Ophthalmology, Virchow-Hospital,  
Humboldt University of Berlin, Augustenburger Platz 1,  
D-13344 Berlin, Germany

Correspondence to: Dr G Wollensak.

Accepted for publication 4 November 1996

- 1 Cogan DG, Kuwabara T, Donaldson DD, Collins E. Microcystic dystrophy of the cornea. *Arch Ophthalmol* 1974;**92**:470-4.
- 2 Dark AJ. Cogan's microcystic dystrophy of the cornea: ultrastructure and photomicroscopy. *Br J Ophthalmol* 1978;**62**:821-30.
- 3 Rodrigues MM, Fine BS, Laibson PR, Zimmerman LE. Disorders of the corneal epithelium: a clinicopathologic study of dot, geographic, and fingerprint patterns. *Arch Ophthalmol* 1974;**92**:475-82.
- 4 Ehlers N, Møller HU. Pathology and pathomechanisms of epithelial microcystic and basement membrane abnormalities of the cornea. *Acta Ophthalmol* 1988;**66**:318-26.
- 5 Ehlers N, Møller HU. Dot-map-fingerprint dystrophy—Cogan's microcystic dystrophy—normal reactions of the corneal epithelium? *Acta Ophthalmol* 1987;**65**(suppl 182):62-6.

## CORRESPONDENCE

### Intraocular pressure changes after peribulbar injections with and without ocular compression

EDITOR,—Ten years on from Davis and Mandel's<sup>1</sup> description of the technique, and despite the popularity of the method, the exact role of, and rationale for, ocular compression in peribulbar anaesthesia remains somewhat obscure. Whatever the facts of the matter this would appear particularly undesirable since a body of evidence from clinical,<sup>2</sup> cadaveric,<sup>3</sup> and animal<sup>4</sup> work would suggest certain potential risks associated with its employment. In their recent paper, published in this journal in May 1996,<sup>5</sup> Bowman *et al* correctly admit that comparison of their results with those obtained by other workers is difficult since so many published studies attempt to draw conclusions from surgeons with widely differing practice. Final clarification of the controversy remains elusive.

While conducting a study of a separate but related aspect of peribulbar anaesthesia, we were interested to establish the details of current consultant practice and surveyed 60 consultant members of the Scottish Ophthalmic Club with 42 (70%) questionnaires returned. Of consultants surveyed 55% were using peribulbar, 23% retrobulbar, 17% sub-Tenon's, and 5% topical anaesthesia. Of those using peribulbar techniques, 62% considered compression with the balloon essential. In this group the *minimum acceptable* time for compression was quoted at between 5 and 20 minutes (average 9 minutes).

Despite the theoretical risks from ocular compression, especially in eyes with actual or potentially impaired optic nerve head blood flow, thankfully there is a relative paucity of reports of serious adverse effects in clinical practice.

JOHN ELLIS

Ninewells Hospital, Dundee DD1 9SY

PATRICK KEARNS

Queen Margaret Hospital, Dunfermline KY12 0SU

1 Davis DB, Mandel MR. Posterior peribulbar anaesthesia: an alternative to retrobulbar anaesthesia. *J Cataract Refract Surg* 1986;12:182-4.

2 Morgan JE, Chandna A. Intraocular pressure after peribulbar anaesthesia: is the Honan balloon necessary? *Br J Ophthalmol* 1995;79:46-9.

3 McDonnell PJ, Quigley HA, Maumenee AE, Stark WJ, Hutchins GM. The Honan intraocular pressure reducer. *Arch Ophthalmol* 1985;103:422-5.

4 Jay WM, Aziz MZ, Green K. Effect of Honan intraocular pressure reducer on ocular and optic nerve blood flow in phakic rabbit eyes. *Acta Ophthalmol Copenh* 1986;64:52-7.

5 Bowman R, Liu C, Sarkies N. Intraocular pressure changes after peribulbar injections with and without ocular compression. *Br J Ophthalmol* 1996;80:394-7.

### Reply

EDITOR,—Bowman and coauthors<sup>1</sup> demonstrated in their well performed study that there is a marked rise in intraocular pressure (IOP) after peribulbar anaesthesia. They injected a total of 10 ml of the anaesthetic, divided, into two different locations. The pressure could be lowered again with the help of ocular pressure.

I have been using peribulbar anaesthesia for intraocular procedures for some years now, injecting 1.5 ml of a mixture of 2% lignocaine and 0.5% bupivacaine in the upper fornix, then 1.5 ml in the lower fornix. The anaesthetic effect is very good and sufficient even for long and complicated operations. By using these relatively small quantities of local anaesthetics, the IOP rises only slightly, thus preventing complications and making ocular compression unnecessary. I would recommend this technique for most intraocular procedures.

ISSAK SCHIPPER

Eye Clinic, Cantonal Hospital,  
6000 Lucerne 16, Switzerland

1 Bowman R, Liu C, Sarkies N. Intraocular pressure changes after peribulbar injections with and without ocular compression. *Br J Ophthalmol* 1996;80:394-7.

### Author's reply

EDITOR,—We knew that the use of ocular compression after peribulbar anaesthesia is not universal and we were interested to learn from Ellis and Kearns's survey of the Scottish Ophthalmic Club that only 62% of the users of peribulbar anaesthesia considered ocular compression essential. We wonder whether those users of peribulbar anaesthesia who do not employ ocular compression afterwards were aware of our findings of the immediate mean pressure rise of 11.44 mm Hg with an injectate volume of 10 ml. We disagree with Ellis and Kearns that the rationale of the technique remains obscure: we have shown that ocular compression for 20 minutes with the Honan's balloon after peribulbar anaesthesia produces a mean fall in intraocular pressure of 11.05 mm Hg.

As Schipper points out, lower volumes of anaesthetic do not produce such a significant pressure rise. Ocular compression may not be necessary with smaller volumes of anaesthetic or topical anaesthesia. However, we continue to recommend the use of ocular compression to reduce the ocular pressure if the technique of peribulbar anaesthesia reported by Davis and Mandel<sup>1</sup> is employed.

NICHOLAS SARKIES

Wistow, The Green,  
Hilton, Huntingdon,  
Cambs PE18 9NB

1 Davis DB, Mandel MR. Posterior peribulbar anaesthesia: an alternative to retrobulbar anaesthesia. *J Cataract Refract Surg* 1986;12:182-4.

### Preschool vision screening

EDITOR,—Congratulations to Newman and colleagues<sup>1</sup> for bringing the subject of amblyopia to general attention once again.

After years of neglect in the morass of developmental trends and the shift of responsibility to parents, as advised by the Hall report and so much beloved by the cost cutting administrators, this is a breath of fresh air.

My experience over 30 years of paediatric ophthalmology evolved along similar lines. It was satisfying initially to pick up amblyopes from whatever cause at 3 and 5 years of age and to carry out the treatments with all the expense that involved.

However, in due time, I found by organising screening clinics during the sensitive period of visual development, with orthoptists at post-

natal and infant welfare clinics, it was possible to pick up younger children with early visual defect before gross amblyopia had developed. This meant that there was early referral, with only slight visual suppression, which entailed only a short period of occlusion and treatment, which was cost effective for hospital attendances, and for the families indeed, in my region of South West Thames: full blown amblyopia was virtually eliminated at that time.

Perhaps the pendulum may once again turn towards really early assessment and referral, and hence lead to prevention rather than cure.

I would urge the authors and all concerned with paediatric management to direct their energies towards this goal and fulfil the aspirations of the giants of yesteryear such as Mary Sheridan and Ronnie MacKeith.

G V CATFORD

St George's Hospital, London

1 Newman DK, Hitchcock A, McCarthy H, Keast-Butler J, Moore AT. Outcome of children referred to the hospital eye service. *Br J Ophthalmol* 1996;80:1077-82.

### First day follow up for routine phacoemulsification?

EDITOR,—We would certainly concur with Whitefield *et al*<sup>1</sup> that an important reason why patients decline day case surgery is the need for an examination the next day. We would also question this necessity following uncomplicated sutureless phacoemulsification with lens implant. However, we feel it may be unsafe practice if patients are not examined at all in the early postoperative period.

Firstly, intraocular pressure can be raised following cataract surgery,<sup>2</sup> as indeed it was in three cases in this study. The maximum pressure rise tends to occur 5-7 hours postoperatively<sup>3</sup> and so if patients were examined then many more may well be found to have raised pressure. For most patients this transient ocular hypertension is not associated with significant morbidity, but central retinal artery and venous occlusions and non-arteritic anterior ischaemic optic neuropathy<sup>4</sup> have been reported following cataract surgery and this pressure spike may be a significant factor.

It may be better, therefore, to examine the patient on the same day as surgery before discharge. The use of a prophylactic ocular anti-hypertensive agent would also be recommended. An early examination would also allow a significant wound leak to be detected.<sup>5</sup> In the study by Tufail *et al*<sup>5</sup> it was concluded that no complications were missed by examining the patients on the same day as surgery that would have been detected the next day.

Iris prolapse and endophthalmitis are both very rare (0.3%)<sup>6</sup> and so would not be expected to be detected by a study of this size (100 patients). Often these conditions do not present on the first postoperative day, with endophthalmitis typically presenting 48-72 hours postoperatively.<sup>7</sup> A fibrinous uveitis, which may be a warning of impending endophthalmitis, again is often worse a few days after surgery rather than at day 1. It is possible some of these cases could be screened for with a visit 3 days after surgery. It is our practice, however, to ask the patient to return as an emergency if symptoms change, especially increasing pain, rather than seeing all patients at day 3.

Our policy is to examine on the same day as surgery, before discharge, and again at 2 weeks

and if all is well the patient is discharged for refraction by their optician, as no further intervention is required. If one suture has been used this is removed at this 2 week visit.

S J TALKS  
P ROSEN

The Eye Hospital, The Radcliffe Infirmary,  
Woodstock Road, Oxford OX2 6HE

- Whitefield L, Crowston J, Little BC. First day follow up for routine phacoemulsification? *Br J Ophthalmol* 1996;**80**:148–50.
- Fiest RM, Palmer DJ, Fiscella R, Ernest JT, Tripathi R, Torczynski E, et al. Effectiveness of aprolonidine and acetazolamide in preventing postoperative intraocular pressure spikes after extracapsular cataract extraction. *J Cataract Refract Surg* 1995;**21**:191–5.
- Bomer TG, Lagreze WD, Funk J. Increased intraocular pressure after cataract extraction—effect of surgical technique, surgical procedure and preventive drug administration. A prospective, randomised double-blind study. *Klin Monatsbl Augenheilkd* 1995;**206**:13–9.
- Hayreh SS. Anterior ischaemic optic neuropathy. IV Occurrence after cataract extraction. *Arch Ophthalmol* 1980;**98**:1410–6.
- Tufail A, Foss AJE, Hamilton AMP. Is the first day postoperative review necessary after cataract extraction? *Br J Ophthalmol* 1995;**79**:646–8.
- Desai P. The national cataract surgery survey II. Clinical outcomes. *Eye* 1993;**7**:489–94.
- D'Amico DJ, Noorily SW. Postoperative endophthalmitis. In: Albert DM, Jakobiec FA, eds. *Principles and practice of ophthalmology. Clinical practice*. Philadelphia: WB Saunders, 1994;Vol 2:1159–69.

### A case of Leber's hereditary optic neuropathy with elevated blood levels of lactate and pyruvate

EDITOR.—Leber's hereditary optic neuropathy (LHON) is a maternally inherited disease characterised by acute bilateral loss of central vision.<sup>1</sup> We report a patient with LHON who had elevated lactate and pyruvate levels in blood and cerebrospinal fluid (CSF).

#### CASE REPORT

A 22-year-old man noticed blurred vision in both his eyes. Corrected visual acuity was 0.04 in his right eye and 0.05 in his left. Slit-lamp examination and intraocular pressures were normal. Pupillary light reflex was full in both eyes.

Fundus examination revealed slightly hyperaemic optic discs. There was marked disc pallor over the next 2 months. Fluorescein angiography showed diffuse hyperfluorescence in the paramacular area. Goldmann perimetry showed a large central scotoma in each eye. No detectable responses of pattern visually evoked potentials were observed. His neurological examination, magnetic resonance imaging (MRI) of the brain, electromyography, and electroencephalography were normal. The resting blood level of lactate was elevated to 15.7 mg/dl (normal 3.3–14.9 mg/dl) and that of pyruvate was elevated to 1.51 mg/dl (normal 0.30–0.94). The level of lactate in the CSF was 13.8 mg/dl (normal 8.7–13.5), and level of the pyruvate was 1.27 mg/dl (normal 0.37–0.75). The blood level of lactate was elevated to 38.0 mg/dl, and the pyruvate level was elevated to 2.26 mg/dl after exercise loading. Biopsy of the biceps brachii muscle showed no ragged red fibres with Gomori trichrome staining. A point mutation of mtDNA at nt11778 was determined in the leucocyte. Neither the mtDNA point mutation at nt3243 (MELAS), nt8344 (MERRF), nor large deletion (KSS, CPEO) was detected.

Previous reports suggested that LHON is a multisystem disorder with various clinical

manifestation and abnormal laboratory findings.<sup>2,3</sup> Although an abnormal rise of venous lactate is observed in patients with Kearns-Sayre syndrome and other mitochondrial cytopathy, a few reports have demonstrated abnormal elevation of lactate and pyruvate in blood and CSF in LHON.<sup>4</sup> Since 11778 mtDNA encodes subunit 4 of complex I,<sup>5</sup> one would expect that the 11778 mtDNA mutation causes an amino acid change in mitochondrial respiratory chain and leads to impaired catabolism of lactate and pyruvate. The resting lactate and pyruvate levels in blood and CSF and those after aerobic exercise would give additional information on the biochemical abnormalities of LHON.

TSUTOMU NINOMIYA  
HIROKO YAMAZAKI

Department of Ophthalmology, Kohnodai Hospital,  
National Center of Neurology and Psychiatry,  
Japan

SHIN MUNAKATA

Department of Ophthalmology, School of Medicine,  
Chiba University,  
Japan

HIIDE YOSHINO

TAKESHI SATO

Department of Neurology, Kohnodai Hospital, National  
Center of Neurology and Psychiatry,  
Japan

- Leber T. Ueber hereditäre und congenital-angelegte Sehnervenleiden. *Graefes Arch Ophthalmol* 1871;**17**:249–91.
- Nikoskelainen EK, Savontaus MJ, Wanne OP, Katila MJ, Nummelin KU. Leber's hereditary optic neuropathy. A maternally inherited disease. *Arch Ophthalmol* 1987;**105**:665–71.
- Newman N. Leber's hereditary optic neuropathy. *Arch Neurol* 1993;**50**:540–8.
- Uemura A, Osame M, Nakagawa M, Makahara K, Sameshima M, Ohba N. Leber's hereditary optic neuropathy: mitochondrial and biochemical studies on muscle biopsies. *Br J Ophthalmol* 1987;**71**:531–6.
- Wallace DC, Singh G, Lott MT, Hodge JA, Schurr Tg, Lezza AMS. Mitochondrial DNA mutation associated with Leber's hereditary optic neuropathy. *Science* 1988;**242**:1427–30.

### Accelerated ocular hypertensive response to topical steroids in children

EDITOR.—Topical steroids are well recognised to elevate intraocular pressure (IOP) in adults who are sensitive to their effects.<sup>1,2</sup> However, less is known of the steroid response in children.<sup>3,4</sup> We report an accelerated ocular hypertensive response to topical steroids in two siblings.

#### CASE REPORT

A 6-year-old boy underwent bilateral lateral rectus recession for left divergent squint. The operation was uneventful and no subconjunctival steroid injection was given at the end of the operation. He was discharged with Maxitrol (0.1% dexamethasone and neomycin) eyedrops, six times per day bilaterally. When reviewed on the fourth postoperative day, he complained of photophobia and recurrent vomiting for the previous 2 days. Examination revealed mild ciliary injection with IOP of 44 and 46 mm Hg (measured by the applanation tonometry) in the right and left eyes, respectively. Gonioscopy showed open angles with-

out any developmental anomalies, normal iris structure, and contour. The optic nerves were normal. Topical steroid was immediately withdrawn and ocular hypotensives administered. The IOP fell to 15 mm Hg bilaterally the next day and remained within normal limits after all medications were tailed off over the ensuing days. Both the visual acuity and visual field remained normal at the latest follow up, 1 year after the steroid treatment.

#### COMMENT

There was no family history of glaucoma and both parents were normotensive with normal optic nerves. Steroid provocation tests were initiated but subsequently discontinued at the parents' demand when they grew alarmed by the positive steroid response in their other child (see below). The parents' IOP remained normal 3 days into the provocation test when it was aborted.

This test was, however, successfully completed in their 3-year-old daughter. It helps to exclude ocular hypertension secondary to squint surgery itself and tests for a familial predisposition to steroid responsiveness. Additionally, we asked if fluorometholone would produce less ocular hypertension in the second child. One eye was randomised to receive Maxitrol while the other received fluorometholone, both six times a day. Investigators were masked as to the treatments given. IOP was measured with a Tono-pen (Mentor), at 5 to 6 pm. The mean of three was recorded. Steroids were planned for withdrawal when the IOP doubled that of the baseline IOP. Just as in her brother, IOP rose rapidly to double the pretreatment value within 48 hours in the Maxitrol treated eye (Table 1). She exhibited a 66% and 33% IOP rise after a single day of instillation of Maxitrol and fluorometholone, respectively. On ceasing steroid treatment, the IOP returned to normal within 5 days. This abbreviated course of IOP elevation and recovery in this otherwise normal child strongly supports steroids as a cause of ocular hypertension in both children.

The cause of this exaggerated steroid response in children remains unknown. The relatively immature chamber angle in young children, which has been suggested to be completely developed only at 8 years, may predispose them to the effects of topical steroids.<sup>3</sup> Support for this argument comes from a rabbit model, in which only the younger animals suffered steroid induced glaucoma, while older rabbits were resistant to its effects.<sup>6</sup> As the response in young children can be both severe and extremely rapid in onset, we suggest close monitoring of IOP in the first week of topical steroid treatment under the age of 8. Moreover, with the possibility of strong familial tendency, siblings should also be tested and cautioned accordingly.

DENNIS S C LAM  
ALVIN K H KWOK

Department of Ophthalmology and Visual Sciences,  
The Chinese University of Hong Kong,  
Prince of Wales Hospital, Shatin, Hong Kong

SEKJIN CHEW  
Singapore Eye Research Institute, Singapore

Table 1 Ocular hypertensive response to topical steroids in the patient's 3-year-old sister

	Day 1*	Day 2	Day 3	Day 4	Day 8
Fluorometholone	12	16	18	13	11
Maxitrol	12	20	24†	16	12

\*Baseline IOP was taken on day 1. †All drugs were withdrawn when the IOP doubled the baseline reading.

- 1 Armaly MF. Statistical attributes of the steroid hypertensive response in the clinically normal eye. I. The demonstration of three levels of response. *Invest Ophthalmol* 1965;4:187-97.
- 2 Becker B, Hahn KA. Topical corticosteroids and heredity in primary open-angle glaucoma. *Am J Ophthalmol* 1964;57:543-51.
- 3 Biedner B-Z, David R, Grudsky A, Sachsa U. Intraocular pressure response to corticosteroids in children. *Br J Ophthalmol* 1980;64:430-1.
- 4 Ohji M, Kinoshita S, Ohmi E, Kuwayama Y. Marked intraocular pressure response to instillation of corticosteroids in children. *Am J Ophthalmol* 1991;112:450-4.
- 5 Reme C, d'Epiphany SL. Periods of development of the normal human chamber angle. *Doc Ophthalmol* 1981;51:241.
- 6 Knepper PA, Breen M, Weinstein HG, Black LJ. Intraocular pressure and glycosaminoglycan distribution in the rabbit eye: effect of age and dexamethasone. *Exp Eye Res* 1978 27:567-75.

### Feasibility of automated visual field examination in children

EDITOR,—We have read with great interest the recent paper written by Safran *et al*<sup>1</sup> on the feasibility of automated visual field examinations in children between 5 and 8 years of age.

It is very important to know that all the children at this age did remarkably well regarding both the duration of the automated visual field examination and the reliability of the answers, using an Octopus 2000R perimeter with a two level strategy. However, a preliminary familiarisation with a specially designed adaptation program was found to be mandatory with children aged 7 years or under.

I would like to point out our good experience with the Humphrey 120 full field screening test in children with previous retinopathy of prematurity at the age of 10 years. There was no need for a preliminary adaptation phase, and this test was found to be reliable and reproducible in all these children. The data are presented in our paper, published in the *BjO* in 1995.<sup>2</sup>

ISRAEL KREMER  
YUVAL YASSUR

Department of Ophthalmology,  
Rabin Medical Center, Beilinson Campus,  
Petah Tikva, 49100, Israel

- 1 Safran AB, Laffi GL, Bullinger A, Viviani P, de Weisse C, Tschopp C, *et al*. Feasibility of automated visual field examination in children between 5 and 8 years of age. *Br J Ophthalmol* 1996;80:515-8.
- 2 Kremer I, Nissenkorn I, Lusky M, Yassur Y. Late visual field changes following cryotherapy for ROP stage 3. *Br J Ophthalmol* 1995;79:267-9.

### Reply

EDITOR,—I very much appreciate the interest shown by Kremer and Yassur in our article on the feasibility of automated perimetry in children between 5 and 8 years of age.<sup>1</sup> I am pleased that their own observations with 10-year-old children<sup>2</sup> were in accordance with some of our findings. Moreover, I believe that their excellent paper illustrated well the clinical value of computerised perimetry in children. There is an obvious need for assessing the limits of such procedures in very young patients, and defining reference values.

AVINOAM B SAFRAN  
Geneva, Switzerland

- 1 Safran AB, Laffi GL, Bullinger A, Viviani P, de Weisse C, Desangles D, *et al*. Feasibility of automated visual field examination in children between 5 and 8 years of age. *Br J Ophthalmol* 1996;80:515-8.
- 2 Kremer I, Nissenkorn I, Lusky M, Yassur Y. Late visual field changes following cryotherapy for ROP stage 3. *Br J Ophthalmol* 1995;79:267-9.

## NOTICES

### Glaucoma Society (UK & Eire)

#### DAVID COLE TRAVEL FELLOWSHIP

The David Cole Travel Fellowship, instituted by Merck Sharp and Dohme in memory of Professor David Cole, will assist a visit to a hospital or research centre during the academic year starting 1 October 1997. The award will be equivalent to £2000. The purpose of the award is to enable the successful applicant to gain experience and knowledge in pursuit of a specific project related to glaucoma.

#### THE GLAUCOMA SOCIETY (UK & EIRE) RESEARCH GRANT

The Glaucoma Society (UK & Eire) research grant, sponsored by the International Glaucoma Association will be available for a research project clinically orientated to glaucoma for 1997. The award will be equivalent to £2500.

The grant may be used towards salary or project expenses or for buying equipment.

These awards are available to both medical graduates and non-medical scientists resident in the United Kingdom or Ireland. They may be held concurrently with other awards.

For further details and application forms please contact: Dr S Nagasubramanian, Secretary, The Glaucoma Society (UK & Eire), Glaucoma Unit, Moorfields Eye Hospital, City Road, London EC1V 2PD.

The closing date for applications is the 31 May 1997. The successful candidate will be informed by August 1997.

### Association for Research in Vision and Ophthalmology (ARVO)

The Association for Research in Vision and Ophthalmology (ARVO) is holding its annual meeting on 11-16 May 1997 at the Fort Lauderdale Convention Center, Fort Lauderdale, Florida, USA. Further details: ARVO, 9650 Rockville Pike, Bethesda, MD 20814-3998. (Tel: (301) 571-1844; fax: (301) 571-8311.)

### 30th Panhellenic Ophthalmological Congress

The 30th Panhellenic Ophthalmological Congress organised by the Hellenic Ophthalmological Society will be held at the Astir Palace Hotel, Vouliagmeni on 28 May to 1 June 1997. Further details: T Kouris, CT Congress, Creta Travel, 19 Amerikis 106 72 Athens, Greece. (Tel: (01) 3607 120, 3635 104; fax: 3603392.)

### American Institute of Ultrasound in Medicine

The second annual bilingual America's conference on ultrasound will be held on 1-3 June 1997 in Miami Beach, Florida, USA. Further details: Stephanie Reisberg or Kimberly

Mullaney. (Tel: (301) 498-4100; email: [pubs\\_govt@aium.org](mailto:pubs_govt@aium.org))

### Conferences on Angiography in Créteil

A conference on clinical cases in ICG will be held on 9 June 1997 at the University of Créteil. Further details: Professor Gisèle Soubrane, Clinique Ophthalmologique Universitaire de Créteil, 40 Avenue de Verdun, 94010 Créteil Cédex, France. (Tel: 45 17 52 22.)

### British Council International Seminar

A British Council international seminar (number 97031) entitled 'Corneal and external eye disease: new surgical techniques' with Professor D L Easty as director will be held on 29 June to 5 July 1997 in Bristol, UK. The seminar will be of particular interest to all young eye surgeons from the developing and developed world. Further details: Promotions Manager, International Seminars, The British Council, 1 Beaumont Place, Oxford OX1 2PJ, UK (Tel: +44 (0) 1865 316636; fax: +44 (0) 1865 557368/516590; email: [International.Seminars@britcoun.org](mailto:International.Seminars@britcoun.org))

### European Association for the Study of Diabetic Eye Complications (EASDEC)

The 7th meeting of EASDEC will be held on 18-19 July 1997 at the Okura Hotel, Amsterdam, the Netherlands, as a pre-congress symposium of the 16th International Diabetic Federation (IDF) congress. Further details: Professor BCP Polak, Rotterdam Eye Hospital, PO Box 70030, 3000 LM Rotterdam, the Netherlands. (Fax: (31) 10 4017655.)

### Continuing Medical Education

The 17th annual current concepts in ophthalmology will be held on 25-27 July 1997 at the San Diego Marriott Mission Valley, San Diego, California, USA. Further details: Marie Krygier, Medical Education Coordinator, San Diego Eye Bank, 9444 Balboa Avenue, Suite 100, San Diego, CA 92123, USA. (Fax: (619) 565-7368.)

### Tübingen Practical Angiography Course

The Tübingen Practical Angiography Course (International Faculty) will take place on 6 September 1997 at the Auditorium, University Dental Clinic, Osianderstrasse 2-8, Tübingen, Germany. Further details: F Gelissen, MD, Congress Secretariat Dept III, University Eye Clinic, Schleichstrasse 12, 72076 Tübingen, Germany. (Tel: +49 (0) 7071 2987448; fax: +49 (0) 7071 293746; email: [ingrid.kreissig@uni-tuebingen.de](mailto:ingrid.kreissig@uni-tuebingen.de))

### 5th International Symposium on Ocular Circulation and Neovascularisation

The 5th International Symposium on Ocular Circulation and Neovascularisation will be held on 15-19 September 1997 in Kyoto, Japan. Further details: Professor Dr Masanobu Uyama, Secretary General of the Organising Committee, Department of Ophthalmology, Kansai Medical University, Moriguchi, Osaka 570, Japan. (fax: 81-6-997-3475.)

## INSTRUCTIONS FOR AUTHORS

Adherence to the following guidelines is essential if efficient and expeditious processing of your manuscript is to be achieved. Manuscripts will be returned to authors for revision before peer review if they are submitted in incorrect format. Please indicate in a covering letter which category of paper your article represents.

The *British Journal of Ophthalmology* is an international journal covering all aspects of clinical ophthalmology and the visual/ophthalmic sciences. Contributors should consider the widely varying readership and write clear, simple articles with the minimum of technical detail. Space in the journal is limited and articles should therefore be as concise as possible. One page of text is approximately 1000 words.

Manuscripts should be sent to the editor who selects them on the basis of their suitability for the journal and of reports from independent referees. Manuscripts are acknowledged on receipt and the majority (>80%) are sent for review. Those that are not reviewed are returned to the author as rapidly as possible so that they may be submitted elsewhere.

Manuscripts may be processed by section editors who deal with specific areas of ophthalmology including surgical retina, medical retina, neuro-ophthalmology, glaucoma, paediatric ophthalmology, ocular motility, orbital disease, anterior segment disease, oncology, lens, optics and visual sciences, laboratory sciences, pathology, and immunology. A minimum of two referees, chosen for their specific expertise, review each article.

Papers are accepted on the understanding that they have not been and will not be published elsewhere, and that there are no ethical problems with the work described. If requested, authors shall produce the data upon which the manuscript is based for examination by the editor.

### Categories of papers

#### ORIGINAL ARTICLES

##### (a) Clinical science

Articles on clinical topics are research reports of a general or specialised nature comprising approximately 3000 words and 4-6 display items (Figures and Tables).

##### (b) Laboratory science

Articles on ophthalmic or visual sciences are research reports of experimental work generally of the same size as clinical research reports. Laboratory science papers will be included in a designated section of the journal.

Both types of original article should include the following: title; key words (up to four); address and which author address for correspondence; structured abstract (approx 200 words, headings 'Aims/background', 'Methods', 'Results', and 'Conclusion'); introduction; materials and methods; results and discussion sections; references and acknowledgements; legends for display items (Figures and Tables).

#### REVIEW ARTICLES

Substantive review articles will be included under the section 'Perspective' and will address any aspect of clinical or laboratory

ophthalmology. Review articles will be approximately 3000-5000 words in length including references and may contain display items (Figures and Tables). Most review articles are commissioned but uninvited reviews are welcomed. Prior discussion with the Editor is recommended. All reviews are subject to independent refereeing.

#### LETTERS TO THE EDITOR

Case reports will be published as 'Letters to the editor'. These are normally 500-600 words written in the form of a letter with a maximum of two display items (Figures and Tables). The letter should include an introductory section (without heading), the case report (heading: Case report) and a comment (heading: Comment), plus a maximum of 10 references.

#### CORRESPONDENCE

Letters are normally constructed in the form of scientific correspondence and are usually 200-300 words.

#### Preparation of manuscripts

Manuscripts will be received on the understanding that they have not been and will not be published elsewhere while under editorial review. Manuscripts may be subject to editorial revision with the author's agreement. All communications should be sent to the Editor, *British Journal of Ophthalmology*, Department of Ophthalmology, University of Aberdeen Medical School, Foresterhill, Aberdeen AB9 2ZD, Scotland, UK. (Tel: 01224 663812; Fax: 01224 663832.)

Manuscripts must be submitted in triplicate, and typed double spaced on one side of the paper only, with one inch margins. Each author must sign the covering letter as evidence of consent to publication. Revised manuscripts should be submitted as hard copy and on disk. Detailed instructions will be sent to authors on invitation to revise.

#### ILLUSTRATIONS

Illustrations must be submitted in triplicate. Transparencies must be accompanied by prints. Only salient detail should be included. All must be labelled with the author's name, numbered in the same order as they are cited in the text irrespective of whether they are in colour or black and white, and have the top indicated. Radiographs must be submitted as prints. Line drawings should be clearly labelled and will be redrawn to house style. The width of illustrations for the original articles should be 68 mm, 104 mm, 140 mm or, in exceptional circumstances, 176 mm, to fit the column layout of the journal. Illustrations for 'Letters to the editor' should be 56 mm or 116 mm. Stain used and a scale bar (or magnification) should be given. Legends must be typed on a separate sheet.

#### TABLES

Each table should be on a separate sheet, have a heading, and contain no vertical rules.

#### REFERENCES

In accordance with the Vancouver agreement references are cited by the numerical system. They must be *typed double spaced*.

References in the text must be cited in numerical order of first appearance. References in the list must be given in the numerical order in which they first appear in the text, not in alphabetical order of authors' names. References with one to six authors must include all authors' names; for references with more than six authors the first six should be given and then *et al*. Titles of journals should be abbreviated in accordance with the *Index Medicus* or given in full.<sup>1</sup> References to books must include names of editor(s) if there is one, town where published, name of publisher, year, volume, page numbers.<sup>2</sup>

- 1 Kaye SB, Shimeld C, Grinfield E, Maitland NJ, Hill TJ, Easty DL. Non-traumatic acquisition of herpes simplex virus infection through the eye. *Br J Ophthalmol* 1992; **76**: 412-8.
- 2 Jakobiec FA, Font RL. Orbit. In: Spencer WB, ed. *Ophthalmic pathology: an atlas and textbook*. 3rd ed. Philadelphia: Saunders, 1986: 2461-76.

References will not be checked in the editorial office. Responsibility for their accuracy and completeness lies with the author.

#### SI UNITS

The work should be reported in the units used. If these were not SI units, the equivalent in SI units should be given in parentheses.

#### STATISTICS

Particular attention should be paid to the description of any sample selection process; in particular, the representativeness of the sample should be argued and the handling of any missing data justified. Authors are asked to check tables etc to ensure that missing data are accounted for, that percentages add up to 100 and that numbers in tables are not at variance with those quoted in the text. The policy of the *British Journal of Ophthalmology* is based on the statistical guidelines published in the *British Medical Journal* in 1983 and these are a useful source of information for authors (Altman DG, Gore SM, Gardner MJ, Pocock SJ. Statistical guidelines for contributors to medical journals, *BMJ* 1983; **286**: 1489-93). Blanket statements on the use of statistical techniques should be avoided; it must be made quite clear in context which procedure is being used. Authors should bear in mind that relatively simple analyses are often quite adequate to support the arguments presented.

Advice may be available to authors before submission of papers.

#### Proofs

Contributors will receive ONE proof, and should read it carefully for printers' errors. Alterations to the original text should be kept to a minimum and may be charged to the author. Responsibility for validation of the proof lies with the author.

#### Reprints

These may be ordered from the Offprint Office when proofs are returned.



## Recurrent uveitis in a patient with adult onset cyclic neutropenia associated with increased large granular lymphocytes

ALEJANDRO RODRIGUEZ, ROBERT A YOOD, THOMAS J CONDON, et al.

*Br J Ophthalmol* 1997 81: 415  
doi: 10.1136/bjo.81.5.415

---

Updated information and services can be found at:  
<http://bjournal.bmj.com/content/81/5/415.1.full.html>

---

### References

*These include:*

This article cites 7 articles, 2 of which can be accessed free at:  
<http://bjournal.bmj.com/content/81/5/415.1.full.html#ref-list-1>

Article cited in:  
<http://bjournal.bmj.com/content/81/5/415.1.full.html#related-urls>

### Email alerting service

Receive free email alerts when new articles cite this article. Sign up in the box at the top right corner of the online article.

---

### Notes

---

To request permissions go to:  
<http://group.bmj.com/group/rights-licensing/permissions>

To order reprints go to:  
<http://journals.bmj.com/cgi/reprintform>

To subscribe to BMJ go to:  
<http://group.bmj.com/subscribe/>