

# Imaging of optic nerve head drusen with the scanning laser ophthalmoscope

R J Haynes, A Manivannan, S Walker, P F Sharp, J V Forrester

## Abstract

**Background**—Optic nerve head drusen may present diagnostic difficulties in cases of disc swelling. Imaging of the nerve in a search for drusen is often inconclusive, especially in children, where drusen may be buried below the surface of the nerve head.

**Methods**—A small study was carried out using a scanning laser ophthalmoscope (SLO) with an infrared confocal facility to scan deep within optic discs in an attempt to image drusen.

**Results**—The SLO was able to demonstrate superficial and buried drusen (using the infrared confocal facility). The superiority of the SLO over ultrasound in the presence of lens opacity was revealed, as the SLO simultaneously demonstrated both drusen and the associated anomalous disc features which are not detected by ultrasound.

**Conclusion**—The SLO can help in the diagnosis of optic disc drusen especially in difficult cases where lens opacity or buried drusen hinders their definitive diagnosis.

(*Br J Ophthalmol* 1997;81:654-657)

Imaging of optic nerve head drusen has been attempted by several different techniques, with varying degrees of success. Recent work has shown that fluorescein angiography may show autofluorescence and late staining of disc drusen in some cases; that computed tomography (CT) and magnetic resonance imaging (MRI) inconsistently show superficial calcification or lucency respectively; and that only B-mode ultrasonography consistently demonstrates calcified optic disc drusen.<sup>1</sup> However, few of the associated diagnostic features of discs with drusen are demonstrated by ultrasound and in the presence of opacity of the media, doubt over the possibility of dual pathology will persist. In this brief report, we demonstrate the value of the scanning laser ophthalmoscope (SLO) in demonstrating optic disc drusen and the associated disc abnormalities, even in the presence of lens opacity.

## Materials and methods

SLO imaging of 12 eyes with optic nerve head swelling was carried out using a custom built device. The construction and performance characteristics of this instrument are detailed elsewhere.<sup>2,3</sup> Briefly, the SLO uses a highly col-

limited narrow beam of laser light to sweep over the retina, delivering all its energy to a very small spot for a very short time. Light returning from that spot is detected and synchronously decoded to form an image on a monitor. The SLO has 'confocal optics', meaning that detection of returning light takes place at a focal point which is conjugate to the focus of the illumination spot on the retina. This is achieved by the use of a confocal aperture which allows only light which is brought to a focal point at the aperture to pass through the aperture and thus to the detector. Any light brought to focus in front of, or behind the aperture (that is, light arising from a focal plane deep to, or superficial to the confocal point) will not pass through the aperture and will not be detected.

Therefore, the SLO allows analysis of light from a particular depth of the illuminated fundus. The slice thickness analysed is dependent on the size of the confocal aperture; a smaller aperture results in a thinner slice, but also a weaker signal as less light returns to the detector. In this study a 200 µm confocal aperture was used.

An infrared diode laser (780 nm) and a visible dye laser (540 nm) were used for illumination, at an incident power at the cornea of 200 µW/cm<sup>2</sup>. Confocal and indirect images were captured. Indirect mode permits only the passage of scattered light back to the detector and, therefore, removes any directly reflected light. Suitable images were grabbed and stored on a PC compatible computer (Elonex PC-450). The SLO images were of a 25° field and at a resolution of 512 × 512 pixels. Binocular indirect ophthalmoscopy, B-mode ultrasound scan, and automated visual field analysis were performed on all patients. Fundus photographs were taken for comparison. All investigations were carried out with the informed consent of the patients.

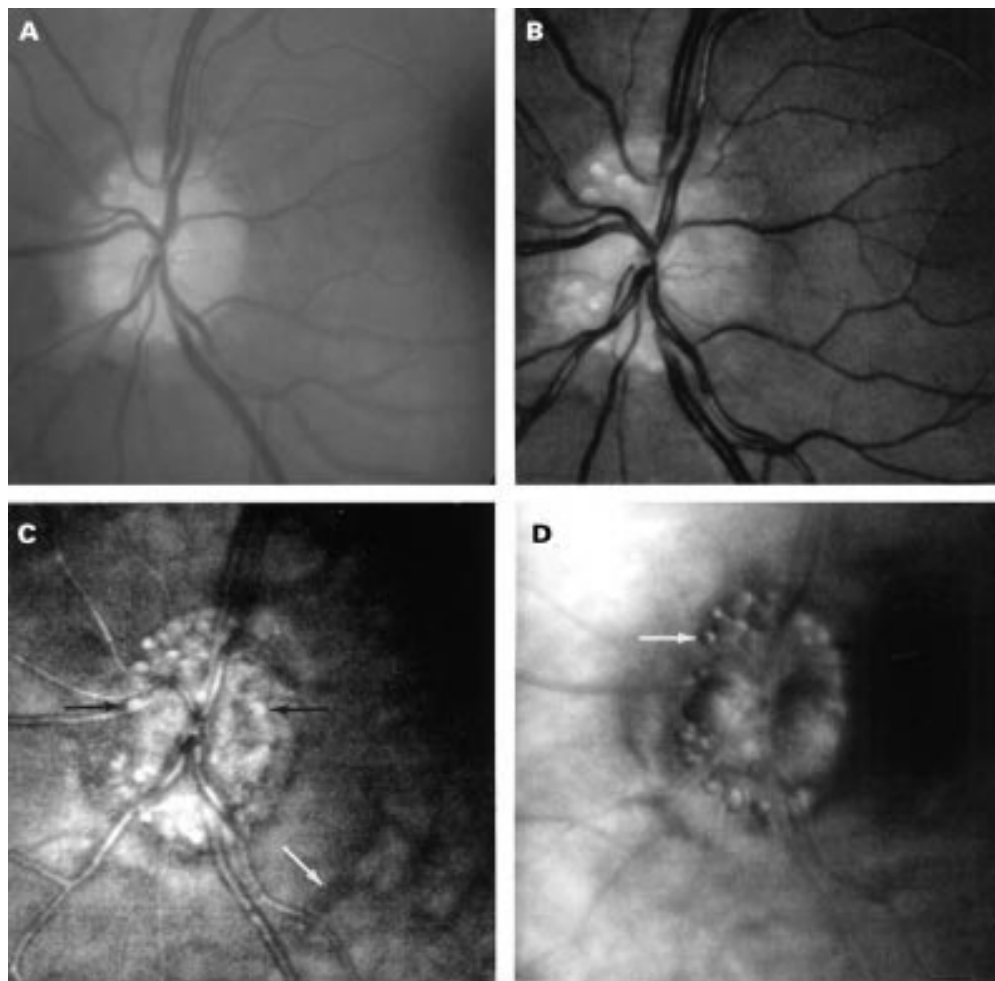
## Results

Binocular indirect ophthalmoscopy and fundus photography allowed imaging of superficial drusen in the presence of clear ocular media (Fig 1(A)). The SLO short wavelength (540 nm, green) light produced high resolution images of superficial disc drusen and other superficial structures such as the retinal vessels and the nerve fibre layer (Fig 1(B)). Long wavelength (780 nm, infrared) light using the confocal mode allowed identification of buried drusen (black arrows) and other deep struc-

Department of  
Ophthalmology,  
University of Aberdeen  
Medical School,  
Aberdeen  
R J Haynes  
A Manivannan  
S Walker  
P F Sharp  
J V Forrester

Correspondence to:  
Mr R J Haynes, 23  
Hollinwell Avenue, Wollaton,  
Nottingham NG8 1JY.

Accepted for publication  
11 March 1997



**Figure 1** Fundus images of a patient with optic disc drusen. (A) Fundus photograph showing superficial disc drusen. (B) Short wavelength (540 nm, green) SLO images showing superficial structures including disc drusen, retinal vessels, and the nerve fibre layer. (C) Long wavelength (780 nm, infrared) confocal mode SLO images showing more drusen including buried ones (black arrows) which are not visible in (A) or (B). Note the retinal vessels appear out of focus as they lie superficial to the plane of focus, whereas deep choroidal vessels are now visible (white arrow). (D) Indirect mode (780 nm, infrared) SLO images of disc drusen showing the distinctive 'bubble' appearance.

tures such as choroidal vessels (white arrow) (Fig 1(C)). Note the retinal vessels appear out of focus as they lie superficial to the plane of focus.

Indirect mode (780 nm, infrared) images of disc drusen produced a distinctive 'bubble' appearance (Fig 1(D)), which correlates well with the appearance of macular drusen imaged with the indirect mode SLO.<sup>4,5</sup> Drusen are detected by the indirect mode SLO because they scatter a large amount of light; indirect mode imaging utilises mainly scattered light.

The distinctive indirect mode 'bubble' appearance of drusen is due to the fact that the convex surface of the drusen facing the eccentrically placed confocal aperture will preferentially scatter light towards the aperture when illuminated; this surface of the drusen will thus appear light. When the scanning beam moves to the opposite side of the drusen surface (which faces away from the confocal aperture) less light will be scattered towards the aperture, and this side of the drusen will thus appear darker. The appearance of brightness on one side and darkness on the other side of the drusen results in the optical impression of a convex bubble.

Optic disc drusen were demonstrated in 10 of the 12 eyes examined with the SLO and B-mode ultrasound; image details are listed in Table 1. One of the patients had significant lens opacities, and disc drusen could not be visualised by either binocular indirect ophthalmoscopy or fundus photography (Fig 2 (A)). However, the SLO was able to generate good contrast images of disc drusen in this patient and secured the diagnosis (Fig 2 (B)). The clinical impression in the sixth patient of crowded discs without drusen, was confirmed by their absence on the confocal SLO and B-mode ultrasound.

Automated perimetry confirmed the presence of field defects in all of our cases of disc drusen. Concordance between the site of the disc drusen (and therefore loss of axons) and the spatial location of the field defects was found in some but not all patients (Table 1). This may be due to a global impairment of optic nerve function in some eyes with disc drusen, or poor performance in the automated perimetry tests.

Other features of disc swelling due to drusen demonstrated by the SLO included anomalous branching of retinal vessels; absent optic cup;

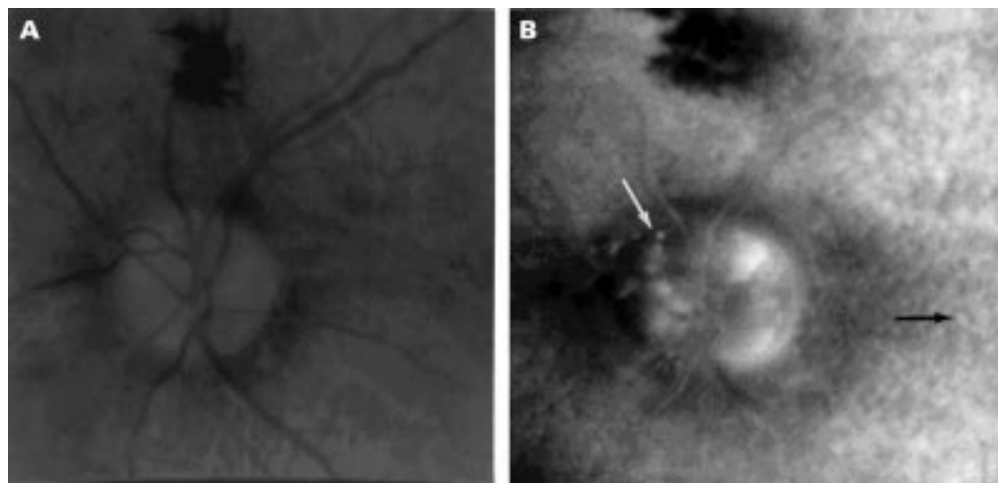


Figure 2 (A) Fundus photograph showing the poor view of disc drusen in a patient with significant lens opacity. (B) Indirect mode SLO image of the same patient demonstrating disc drusen (white arrow) and retinal drusen (black arrow) in the presence of lens opacity.

Table 1 Summary of results

Age	Sex	Symptoms	Eye	Signs	SLO	Fields	Ultrasound
36	F	Blurring of vision during pregnancy*	R	Drusen	Drusen temporally	Nasal defects	+
83	F	Decreased vision	L	Drusen + L RAPD	Drusen+++	Diffuse defects	+
			R	No drusen visible due to cataract	Diffuse drusen	Diffuse defects	+
42	M	None	L	No drusen visible due to cataract	Superior drusen	Inferior nasal step	+
			R	Drusen	Superior drusen	Constricted	+
18	F	None*	L	Drusen	Nasal drusen	Inferior arcuate	+
			R	Drusen	Diffuse drusen	Constricted	+
18	F	Poor vision on R*	L	Drusen	Diffuse drusen	Constricted	+
			R	Drusen	Macular bundle drusen+	Marked constriction	+
17	F	Headache	L	Drusen	Diffuse drusen	Constricted	+
			R	Swollen disc?	No drusen	Normal	-
			L	Swollen disc?	No drusen	Normal	-

\*Normal CT/MRI scan.

spontaneous venous pulsation; irregular disc edge with retinal pigment epithelial disturbance; and the absence of capillary telangiectasia, cotton wool spots, peripapillary retinal folds, and haemorrhages that would be suggestive of other causes of disc swelling.

### Discussion

Histopathologically, optic nerve drusen are calcified, intracellular mitochondria of optic nerve axons.<sup>6</sup> They are present clinically in 0.3% of individuals and histopathologically in 2% of individuals, being present almost exclusively in white patients and found bilaterally in 75%.<sup>7</sup> Inheritance may be autosomal dominant with variable penetrance and there is an association with retinitis pigmentosa and angioid streaks.<sup>8</sup> Visual field defects affect up to 87% of patients,<sup>9</sup> all of our confirmed cases of disc drusen having field loss. Subretinal neovascular membranes and haemorrhages may also occur.

In this study the SLO has shown itself to be an excellent method for the diagnosis of optic disc drusen and its associated nerve head abnormalities even in the presence of significant lens opacity. B-mode ultrasonography has also been shown to be effective for demonstration of calcified disc drusen; however, the asso-

ciated optic nerve features are not demonstrated simultaneously by ultrasound and in the presence of media opacity, dual pathology would be difficult to exclude conclusively. Recent experience of confocal mode SLO imaging of macular drusen with visible wavelengths in our department has shown considerably superior image contrast compared with fundus photographs.<sup>5</sup> Confocal SLO disc drusen images may therefore be suitable for quantitative image analysis, as the area of the disc affected by drusen theoretically may correlate with the visual field deficit. Longitudinal studies may also point to parallel changes in drusen and fields over time. These are a potential areas of future investigation.

We acknowledge Scotia Pharmaceuticals and the Wellcome Trust for supporting this research. Also we thank Miss D Campbell for photographic assistance.

- 1 Kheterpal S, Good P, Beale D, Kritzing E. Imaging of optic disc drusen: a comparative study. *Eye* 1995;9:67-9.
- 2 Manivannan A, Sharp PF, Phillips RP, Forrester JV. Digital fundus imaging using a scanning laser ophthalmoscope. *Physiol Meas* 1993;14:43-56.
- 3 Manivannan A, Sharp PF, Forrester JV. Performance measurements of an infrared digital scanning laser ophthalmoscope. *Physiol Meas* 1994;15:317-24.
- 4 Manivannan A, Kirkpatrick JNP, Sharp PF, Forrester JV. Clinical investigation of an infrared digital scanning laser ophthalmoscope. *Br J Ophthalmol* 1994;78:84-90.

- 5 Kirkpatrick JNP, Spencer T, Manivannan A, Sharp PF, Forrester JV. Quantitative image analysis of macular drusen from fundus photographs and scanning laser ophthalmoscope images. *Eye* 1995;**9**:48-55.
- 6 Folberg R, Campbell RJ, Luckenbach M, Margo CE, Proia AD, Schachat A. *Ophthalmic pathology and intraocular tumours*. San Francisco: American Academy of Ophthalmology Basic and Clinical Science Course 1994-1995, Section 4:176.
- 7 Rosenberg MA, Savino PJ, Glaser JS. A clinical analysis of pseudopapilledema. I Population, laterality, acuity, refractive error, ophthalmoscopic characteristics, and coincident disease. *Arch Ophthalmol* 1979;**97**:71-5.
- 8 Boye SW, Platia EV, Green WR. Drusen of the optic nerve head. *Ann Ophthalmol* 1978;**10**:695-704.
- 9 Cohen D. Drusen of the optic disc and the development of field defects. *Arch Ophthalmol* 1971;**85**:224.



## Imaging of optic nerve head drusen with the scanning laser ophthalmoscope

R J Haynes, A Manivannan, S Walker, et al.

*Br J Ophthalmol* 1997 81: 654-657

doi: 10.1136/bjo.81.8.654

---

Updated information and services can be found at:

<http://bjo.bmj.com/content/81/8/654.full.html>

---

### References

*These include:*

This article cites 6 articles, 3 of which can be accessed free at:

<http://bjo.bmj.com/content/81/8/654.full.html#ref-list-1>

Article cited in:

<http://bjo.bmj.com/content/81/8/654.full.html#related-urls>

### Email alerting service

Receive free email alerts when new articles cite this article. Sign up in the box at the top right corner of the online article.

---

### Topic Collections

Articles on similar topics can be found in the following collections

[Lens and zonules](#) (642 articles)

---

### Notes

---

To request permissions go to:

<http://group.bmj.com/group/rights-licensing/permissions>

To order reprints go to:

<http://journals.bmj.com/cgi/reprintform>

To subscribe to BMJ go to:

<http://group.bmj.com/subscribe/>