

Late reopening of successfully treated macular holes

Michel Paques, Pascale Massin, Pierre-Yves Santiago, Alain C Spielmann, Jean-François Le Gargasson, Alain Gaudric

Abstract

Background—Most idiopathic macular holes can be closed by a surgical procedure combining vitrectomy, posterior hyaloid ablation, and fluid-gas exchange followed by postoperative positioning. Reopening of closed macular holes has been reported, but its frequency is not known. Here the incidence of reopening after successful macular hole surgery is reported.

Methods—77 consecutive cases of idiopathic macular holes operated with autologous platelet injection between July 1993 and October 1995 were reviewed. The procedure consisted of three port vitrectomy, posterior hyaloid removal, non-expansile fluid-gas exchange, and autologous platelet injection followed by face down positioning. The incidence of reopening was analysed in the cohort of the 72 anatomical successes.

Results—Mean follow up was 12.3 months. The macular hole reopened in five eyes of five patients (five out of 72 patients, 6.9%), in four cases after cataract extraction. In four cases too, an epiretinal membrane was noted, either clinically or during reoperation, and fluorescein leakage in the macular area was present in two cases. Three of the five cases of reopening were reoperated and all three were anatomical successes.

Conclusion—Late macular hole reopening occurred in five out of 72 patient, and in four cases after cataract surgery. The presence of an epiretinal membrane around the hole in four of them suggested that tractional forces were responsible for the reopening. Reoperation, performed in three cases, again closed the macular holes.

(*Br J Ophthalmol* 1997;81:658-662)

enlargement of the macular hole, changes in the macular retinal pigment epithelium, and endophthalmitis.⁴⁻⁷ Recently, Duker *et al*⁸ reported eight cases of reopening of successfully operated macular holes. They postulated that in addition to the tangential traction that seems to initiate a macular hole, the exertion of tractional force on the edges of a sealed hole by an epiretinal membrane can be responsible for reopening. Interestingly, three of Duker *et al*'s patients had had cataract surgery before reopening, but the authors did not establish a relation between these two events. In this study, we examined the results for a cohort of 77 consecutive operated macular holes to determine the incidence of reopening.

Patients and methods

Seventy seven consecutive eyes of 72 patients with macular holes were operated on with autologous platelet injection in our department between July 1993 and October 1995. Sixty eight of these 77 holes were idiopathic, one was a reopening after initial success, and eight were reoperations after failure of initial surgery in another centre. Post-traumatic holes and holes associated with high myopia were excluded. The mean age of the patients was 65 years. They comprised 51 women and 26 men. Each macular hole was graded according to the classification proposed by Gass.^{9,10} There were seven stage 2 holes, 51 in stage 3, 11 in stage 4, and eight reoperations. Mean duration of symptoms was 9.5 months (range 1-24 months; one patient had a duration of 8 years). Some of the patients included here have already been reported.¹¹

Preoperative and postoperative examinations included visual acuity measurement with the best possible optical correction, fundus examination with a contact lens, fundus photographs and fluorescein angiography.

Examination with a scanning laser ophthalmoscope (SLO) was also performed during the preoperative and postoperative periods, and included assessment of the locus of fixation, screening for an absolute scotoma, and the line test—an improved version of the Watzke test.¹²

Surgery was performed by two operators (AG and PM) according to a procedure described elsewhere.¹¹ Briefly, standard central three port pars plana vitrectomy was performed. Then, for stage 3 macular holes, traction was exerted on the vitreous fibres around the disc, using an aspiration forceps to detach the Weiss ring and posterior hyaloid.¹³ The hyaloid detachment was then extended out-

Department of Ophthalmology, Hôpital Lariboisière, Université Paris VII, Paris, France

M Paques
P Massin
P-Y Santiago
A C Spielmann
A Gaudric

Department of Biophysics, Hôpital Lariboisière, Université Paris VII, Paris, France
J-F Le Gargasson

Correspondence to: Alain Gaudric, MD, Department of Ophthalmology, Hôpital Lariboisière, 2 rue Ambroise Paré, 75010 Paris, France.

Accepted for publication 1 May 1997

In recent years, rapid progress has been made in the surgery of macular holes. Since the first publication by Kelly and Wendel in 1991,¹ the anatomical success rate has risen from 52% to more than 90%, depending on the initial visual acuity, duration of the hole, and whether or not a healing adjuvant is used.^{2,3} As experience of this surgery increases, its complications are becoming better known. To date, the reported complications of macular hole surgery include cataract formation, retinal breaks, rhegmatogenous retinal detachment, visual field loss,

Table 1 Clinical characteristics of five patients with macular hole reopening

	Case No				
	1	2	3	4	5
Age (years)	65	71	62	66	62
Stage/aetiology	3	3	4	reoperation	4
Duration (months)	4	2	13	4	18
Initial VA	20/60	20/400	20/100	20/125	20/125
Preop ERM	no	yes	no	yes	yes
Postop VA	20/50	20/100	20/50	20/40	20/50
Months from hole surgery to cataract surgery	12	10	9	16	—
Months from hole surgery to reopening	19	12	11	20	18
Months from cataract surgery to reopening	7	2	2	4	—
ERM at reopening	yes	yes	yes	no	yes

VA=visual acuity; ERM = epiretinal membrane.

Table 2 Preoperative and postoperative visual acuity (VA) in the five cases of macular hole reopening

	Case No				
	1	2	3	4	5
Initial VA	20/60	20/400	20/100	20/125	20/125
Best postop VA	20/30	20/100	20/50	20/40	20/50
VA after reopening	20/125	20/200	20/100	20/100	20/100
VA after hole reoperation	20/50	20/100	20/60	—	—

wards to the equator and the vitrectomy was completed, the vitreous being removed as far out towards the periphery as possible. For stage 4 macular holes, vitrectomy confirmed that the posterior hyaloid containing the Weiss ring had indeed been detached from the retina. When the preoperative or peroperative examination disclosed the presence of an epiretinal membrane (ERM) the edge of the membrane was lifted with a silicone tipped cannula by passive aspiration, and peeling was completed with an aspirating forceps. The ERM surrounding the hole was usually soft and friable. In most cases, the ERM adhered to the edges of the hole so only its periphery was detached, and most of it was left in place to avoid additional traction on the hole. No specific attempt was made to peel off the internal limiting membrane. Fluid-air exchange was performed, after which 0.1 ml of an autologous platelet concentrate solution was injected over the posterior pole. A gas mixture (17% C₂F₆ and 83% air) was substituted for the air in the vitreous cavity. Patients remained face down as much as possible for 12 days.

Anatomical success was defined as the reattachment of the edge of the hole to the retinal pigment epithelium. A complete postoperative examination was performed between 10 and 12 weeks after surgery, and before and after cataract surgery using the same procedure as preoperatively. Seventy two of 77 eyes operated were anatomical successes (93.5%). Postoperatively, best corrected visual acuity was 20/50 or more in 72% of patients, compared with 5% preoperatively.

Results

For the 72 successfully operated patients, the mean postoperative follow up period was 12.3 months (range 3–58). Twenty two patients were followed for more than 18 months. Twenty five of the 71 successfully operated

phakic patients (35.2%) subsequently underwent cataract surgery after a mean period of 12 months (range 4–40). Ten of these 25 (40%) were operated during the year after vitrectomy. Mean follow up after cataract surgery was 9.8 months (range 2–20).

Macular hole reopening occurred in five eyes of five patients (6.9%). All five were documented as having had initially successful anatomical closure of the hole and functional improvement. At the time of initial surgery, three of these eyes underwent ERM peeling around the hole. The mean period between vitrectomy and reopening was 14.8 months (range 11–19). Before the reopening, four of the five patients with reopening had had cataract surgery, within a mean period of 11.2 months after vitrectomy (range 9–14). All four had uneventful manual extracapsular extraction and posterior chamber lens implantation. The mean period between cataract surgery and reopening was 3.8 months (range 2–7).

Four of the five patients with reopening presented with an ERM around the reopened macular hole. In one case, no such membrane was detectable by clinical or photographic examination, and the patient was not reoperated. Two patients who had had cataract extraction before reopening exhibited angiographic evidence of fluorescein leakage in the macular area, without cystoid spaces. The clinical characteristics of these five patients are given in Table 1. Three of them were reoperated by fluid-gas exchange and autologous platelet injection. In all three cases the macular hole closed, and visual acuity improved. Preoperative and postoperative visual acuity for the five cases of reopening are shown in Table 2.

CASE REPORT

A 65-year-old woman presented in our department with a 4 month old stage 3 idiopathic macular hole in her right eye and visual acuity of 20/60 (Fig 1, top). The fellow eye was unremarkable. She underwent a surgical procedure consisting of vitrectomy, posterior hyaloid ablation, fluid-gas exchange, and autologous platelet concentrate injection. Three months later, visual acuity was 20/50 and the macular hole had closed (Fig 1, bottom). SLO examination showed the absence of residual scotoma. Cataract extraction and posterior intraocular lens implantation were performed 12 months later. Four months after cataract surgery visual acuity was 20/30. An ERM developed progressively and reopening of the macular hole was noted 19 months after initial surgery, reducing vision to 20/125. Fluorescein angiography showed faint hyperfluorescence of the edges of the hole (Fig 2, top). Further surgery consisting of ERM peeling, fluid-gas exchange, and autologous platelet concentrate injection was performed. Three months after reoperation, the macular hole had again closed and visual acuity was 20/50 (Fig 2, bottom).

Discussion

With the lengthening of follow up for patients operated for macular holes, the long term

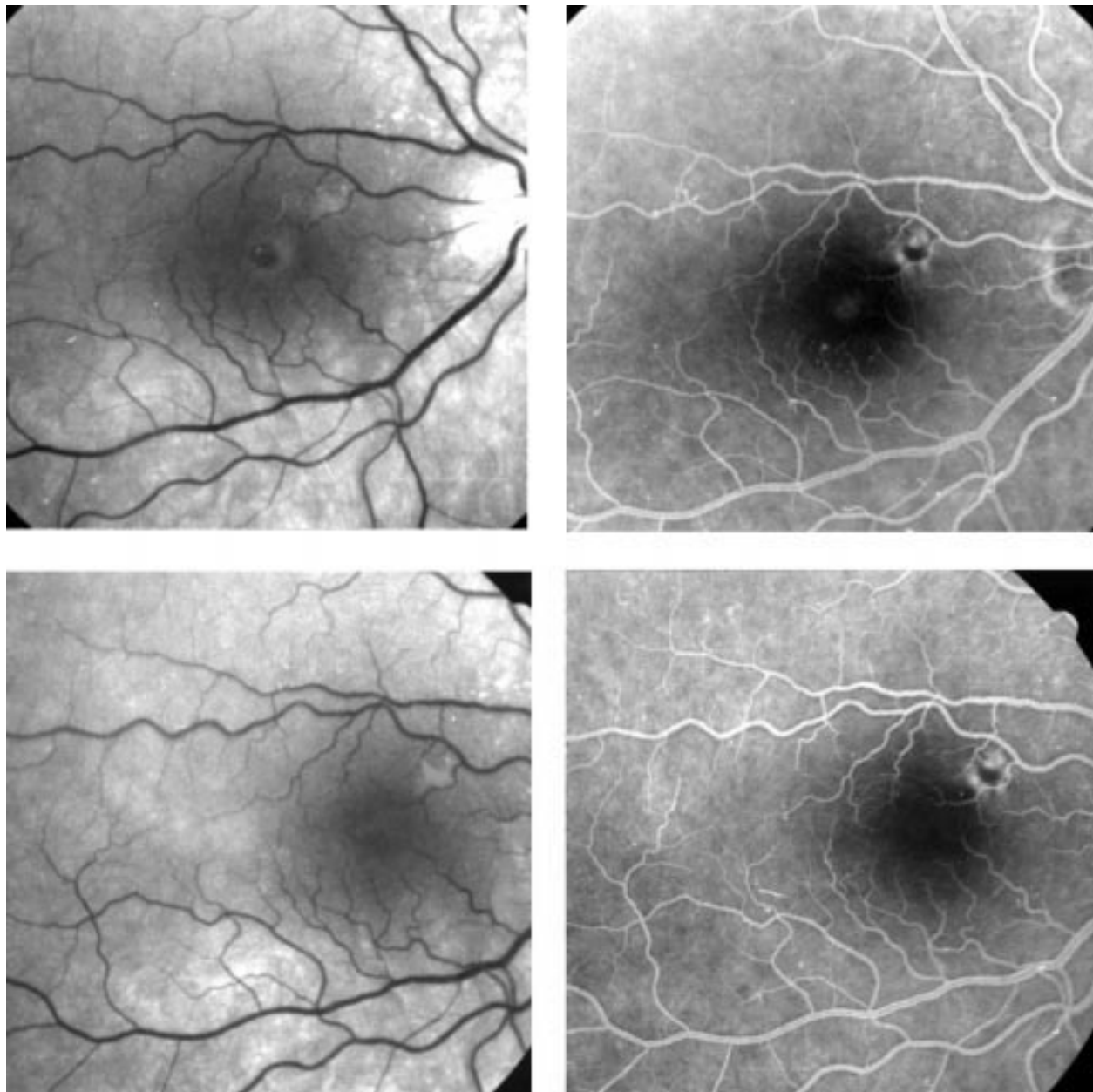


Figure 1 Case 1, a full thickness stage 3 macular hole before and after operation. Top left, red-free photograph. At presentation, macular hole with elevation of edges. Visual acuity (VA) was 20/60. Top right, fluorescein angiography. Faint central hyperfluorescence of the hole (note also the pre-existent extramacular subretinal pigmentation). Bottom left, red-free photograph. Closure of the macular hole 1 month after surgery. VA=20/30. Bottom right, fluorescein angiography. The central hyperfluorescence has disappeared.

complications of this surgery are better known. As already mentioned, previously reported complications of macular hole surgery include cataract formation, retinal breaks, rhegmatogenous retinal detachment, enlargement of the hole, changes in the macular retinal pigment epithelium, visual field loss, endophthalmitis, and macular hole reopening.⁴⁻⁸ For the eight cases of patients with hole reopening reported by Duker *et al*,⁸ the mean period between vitrectomy and reopening was 12 months. We found a period close to this of 14.8 months. Three of the eight eyes in Duker *et al*'s series underwent cataract surgery between vitrectomy and reopening, which occurred after a mean period of 8 months (range 3-12) after the cataract operation. However, Duker *et al*

did not estimate the proportion of patients with reopening of the macular hole after cataract surgery.

Three of the eight eyes in the Duker series were observed to have a clinically significant ERM at the time of reopening. Four of our five cases of reopening also had an ERM. All five patients had initial vitrectomy, and in two of them, the Weiss ring was detached according to the technique previously described by one of us.¹³ As two others had stage 4 macular holes, we can reasonably consider that the ablation of the posterior hyaloid was complete in at least four of the five cases. The remaining case was a reoperation, during which no residual vitreous was found at the vitreoretinal interface. We believe that this rules out residual vitreous

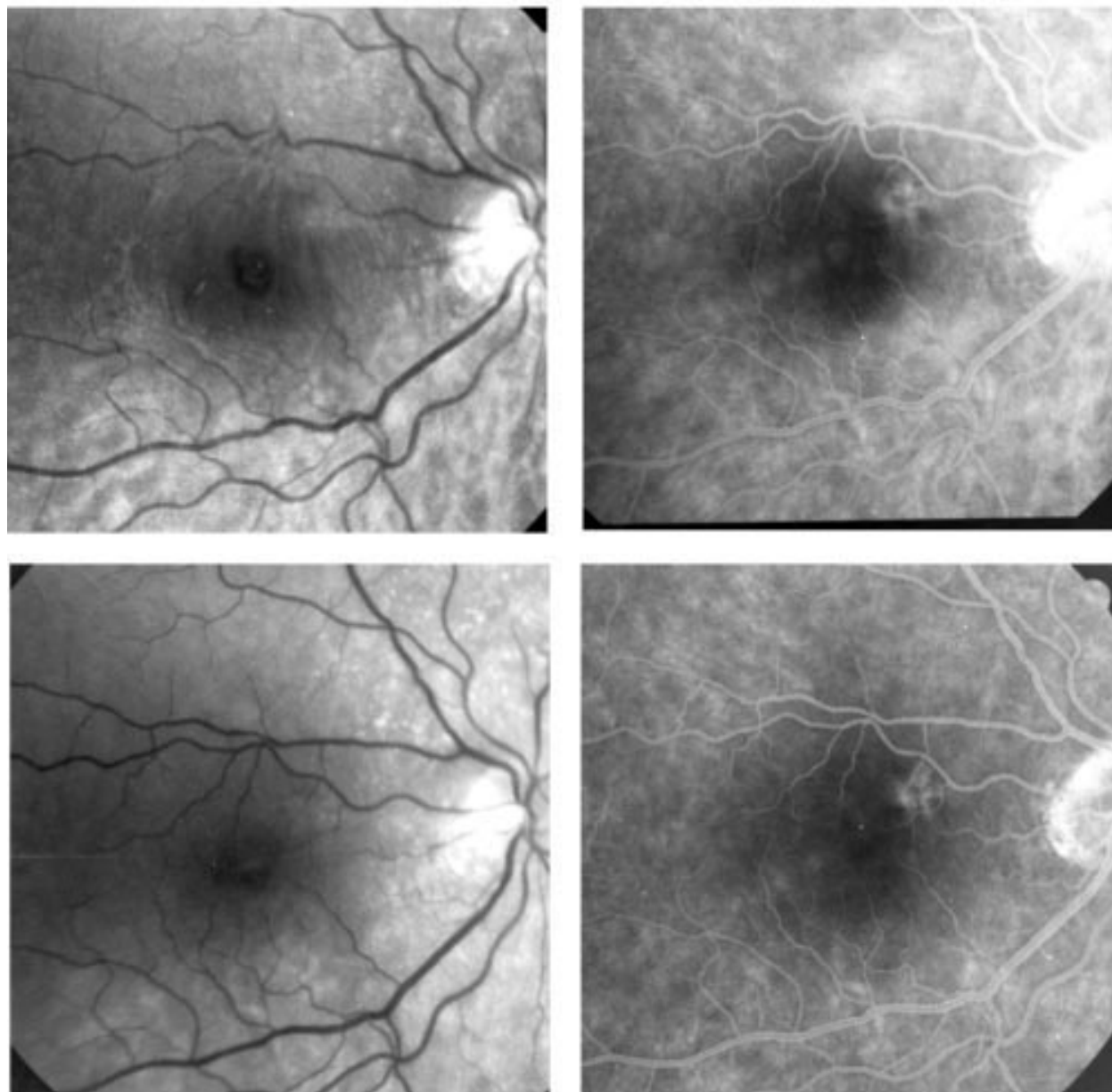


Figure 2 Case 1. Macular hole reopening after cataract extraction, and closure after reoperation. Top left, blue filter photograph: reopening of the macular hole with epiretinal membrane formation 7 months after cataract surgery and 19 months after macular hole surgery. VA=20/125. Top right, fluorescein angiography. Round central hyperfluorescence of the hole and moderate intraretinal dye leakage, with no cystoid spaces in the macula. Bottom left, red-free photograph. Closure of the hole after reoperation and complete removal of the epiretinal membrane. VA= 20/50. Bottom right, fluorescein angiography showing faint residual hyperfluorescence around the macula.

traction as a cause of the reopening. On the other hand, Gordon *et al*¹⁴ reported five cases of macular hole which occurred despite complete posterior vitreous detachment. They postulated that traction from the internal limiting membrane itself, or from vitreous remnants, might be the cause for the macular hole, rather than an ERM. However, three of their five patients had an ERM on fundusoscopic examination. We therefore believe that reopening was probably due to an ERM. Patient 1 is of particular interest, as a contractile ERM was detected in this subject 3 months before

reopening. Funata *et al*¹⁵ and Madreperla *et al*¹⁶ described histopathological aspects of postoperative sealed macular holes and showed that in some cases localised glial cell proliferation occurs between the edges of the hole. We suggest that slight tangential traction from an ERM may be sufficient to reopen the macular hole if this cicatricial tissue is weak. On the basis of a histopathological study of an ERM associated with a recurrent macular hole, Fekrat *et al*¹⁷ postulate that the cells which contribute to the closure of the hole can also form an ERM that reopens it.

The pathogenesis of ERM formation after cataract surgery is unclear. It may be that the rupture of the blood-retina barrier and the inflammation caused by cataract extraction are followed by the diffusion of factors which are chemotactic for glial cells from the plasma, and might reach the vitreous cavity and the surface of the retina, thus initiating the formation of an ERM over the operated macular hole. In our cases, cataract surgery consisted of uneventful manual extracapsular extraction. There is evidence that small incision surgery leads to less inflammation and haemato-ocular barrier rupture than manual surgery, as measured by the laser cell flare meter.¹⁸ However, the clinical relevance of this has not been demonstrated, for instance, on the rate of postoperative macular oedema. At the time of the present study, manual extracapsular extraction was the standard technique in our department for cataract extraction in vitrectomised eyes. Theoretically, a phototraumatic lesion could participate in ERM formation, although in our patients, who all had a postoperative angiography, no pigment epithelium changes suggestive of phototraumatic lesions were observed.

Autologous platelets may initially contribute to macular hole closure by creating localised glial cell proliferation, which may also form an epiretinal membrane. Interestingly, spontaneous macular hole closure by an epiretinal membrane has already been shown to occur in certain cases.^{8, 19} However, experimental studies in the rabbit failed to show the presence of an epiretinal membrane after autologous platelet injection in the vitreous (Paques *et al*, submitted).

In two of our cases of reopening, there was evidence of macular staining on post-cataract angiography, possibly due to macular oedema. However, we did not observe the typical features of Irvine-Gass syndrome—for example, cystoid spaces, disc staining, and perivascular leakage. Also, this staining may have been due to vascular distortion originating from an ERM, although such distortion was not clear on fundus examination.

As the mean period between vitrectomy and reopening in our patients was similar to that reported for the cases described by Duker *et al*, we cannot conclude with certainty that there is a causal link between cataract surgery and reopening, and it may be that the two events are coincidental.

In summary, macular hole reopening was observed in five out of 72 cases (6.9%) and in four cases was associated with the presence of

an epiretinal membrane. In four cases too, reopening was preceded by cataract surgery. Reoperation of in three of these five patients resulted in anatomical closure and functional improvement in all three. Consequently, both the patients previously operated for macular hole and the surgeons must be aware that cataract extraction can be followed by macular hole reopening, but that reoperation can again close the hole in a high percentage of cases. As the period of follow up lengthens, the number of cases of reopening in the present series may increase.

- 1 Kelly NE, Wendel RT. Vitreous surgery for idiopathic macular holes: results of a pilot study. *Arch Ophthalmol* 1991;109:654-9.
- 2 Wendel RT, Patel AC, Kelly NE, Salzano TC, Wells JW, Novack GD. Vitreous surgery for macular holes. *Ophthalmology* 1993;100:1671-6.
- 3 Glaser BM, Michels RG, Kuppermann BD, Sjaarda RN, Pena RA. Transforming growth factor-beta 2 for the treatment of full-thickness macular holes. *Ophthalmology* 1992;99:1162-73.
- 4 Parks S, Marcus D, Duker J, Pesavento R, Topping T, Fredericks A, *et al*. Posterior segment complications after vitrectomy for macular holes. *Ophthalmology* 1995;102:775-81.
- 5 Poliner LS, Tornambe PE. Retinal pigment epitheliopathy after macular hole surgery. *Ophthalmology* 1992;99:1671-7.
- 6 Melberg NS, Thomas MA. Visual field loss after pars plana vitrectomy with air/fluid exchange. *Am J Ophthalmol* 1995;120:386-8.
- 7 Ezra E, Arden GB, Riordan-Eva P, Aylward GW, Gregor ZJ. Visual field loss following vitrectomy for stage 2 and 3 macular holes. *Br J Ophthalmol* 1996;80:519-25.
- 8 Duker J, Wendel R, Patel A, Puliafito C. Late reopening of macular holes after initially successful treatment with vitreous surgery. *Ophthalmology* 1994;101:1373-8.
- 9 Gass JDM. Idiopathic senile macular hole. Its early stages and pathogenesis. *Arch Ophthalmol* 1988;106:629-39.
- 10 Gass JDM. Reappraisal of biomicroscopic classification of stages of development of a macular hole. *Am J Ophthalmol* 1995;119:752-9.
- 11 Gaudric A, Massin P, Paques M, Santiago PY, Guez JE, Le Gargasson JF, *et al*. Autologous platelet concentrate for the treatment of full-thickness macular holes. *Graefes Arch Ophthalmol* 1995;233:549-54.
- 12 Le Gargasson JF, Rigaudiere F, Guez JE, Gaudric A, Grall Y. Contribution of scanning laser ophthalmoscope (SLO) to the functional investigation of subjects with a macular hole. *Doc Ophthalmol* 1994;86:227-38.
- 13 Gaudric A, Massin P, Qinyuan C. An aspirating forceps to remove the posterior hyaloid in the surgery of full-thickness macular holes. *Retina* 1996;16:261-3.
- 14 Gordon LW, Glaser BM, Darmakusuma I, Thompson JT, Sjaarda RN. Full-thickness macular hole formation in eyes with a preexisting complete posterior vitreous detachment. *Ophthalmology* 1995;102:1702-5.
- 15 Funata M, Wendel RT, De la Cruz Z, Green WR. Clinicopathologic study of bilateral macular holes treated with pars plana vitrectomy and gas tamponade. *Retina* 1992;12:289-98.
- 16 Madreperla SA, Geiger GL, Funata M, de la Cruz Z, Green R. Clinicopathologic correlation of a macular hole treated by cortical vitreous peeling and gas tamponade. *Ophthalmology* 1994;101:682-6.
- 17 Fekrat S, Wendel RT, De la Cruz Z, Green WR. Clinicopathologic correlation of an epiretinal membrane associated with a recurrent macular hole. *Retina* 1995;15:53-7.
- 18 Oshika T, Yoshimura K, Miyata N. Postsurgical inflammation after phakoemulsification and extracapsular extraction with soft or conventional intraocular lens implantation. *J Cataract Refract Surg* 1992;18:356-61.
- 19 Lewis H, Cowan GM, Straatsma BR. Apparent disappearance of a macular hole associated with development of an epiretinal membrane. *Am J Ophthalmol* 1986;102:172-5.



Late reopening of successfully treated macular holes

Michel Paques, Pascale Massin, Pierre-Yves Santiago, et al.

Br J Ophthalmol 1997 81: 658-662

doi: 10.1136/bjo.81.8.658

Updated information and services can be found at:

<http://bjo.bmj.com/content/81/8/658.full.html>

References

These include:

This article cites 19 articles, 3 of which can be accessed free at:

<http://bjo.bmj.com/content/81/8/658.full.html#ref-list-1>

Article cited in:

<http://bjo.bmj.com/content/81/8/658.full.html#related-urls>

Email alerting service

Receive free email alerts when new articles cite this article. Sign up in the box at the top right corner of the online article.

Topic Collections

Articles on similar topics can be found in the following collections

[Retina](#) (1207 articles)

[Lens and zonules](#) (638 articles)

[Ophthalmologic surgical procedures](#) (962 articles)

Notes

To request permissions go to:

<http://group.bmj.com/group/rights-licensing/permissions>

To order reprints go to:

<http://journals.bmj.com/cgi/reprintform>

To subscribe to BMJ go to:

<http://group.bmj.com/subscribe/>