

Fluorescein angiographic correlation of focal narrowing of retinal arterioles in glaucoma

Konstantinos I Papastathopoulos, Jost B Jonas

Abstract

Background—Recent studies have shown that focal narrowing of retinal arterioles in the parapapillary region occurs in eyes with optic neuropathies such as glaucoma. This study evaluated whether these vessel constrictions detected ophthalmoscopically have an equivalent in angiographic imaging of the fundus.

Methods—Fluorescein angiograms and colour wide angle fundus photographs of 33 patients with open angle glaucoma and 76 subjects with normal optic nerves were examined for focal narrowing of retinal arterioles. The angiograms had primarily been taken for other reasons such as age related macula degeneration.

Results—All focal narrowings of retinal arterioles detected on fundus photographs showed a localised constriction of vessel filling in the fluorescein angiograms. Degree of vessel narrowing on the fundus photographs and degree of constriction of the fluorescein vessel filling were significantly ($p < 0.001$) correlated with each other.

Conclusions—Focal narrowing of retinal arterioles in the parapapillary region of eyes with optic neuropathies represents a real stenosis of the vessel lumen and is not due to an ophthalmoscopic artefact.

(*Br J Ophthalmol* 1998;82:48-50)

Generalised reduction of the diameter of retinal arterioles is a common finding in eyes with optic nerve damage independent of the reason for the optic nerve fibre loss.^{1,2} Additionally, focal narrowing of retinal arterioles has recently been described to occur in the parapapillary region of eyes with glaucomatous and non-glaucomatous optic nerve atrophy.³⁻⁵ It was found more often and it was more pronounced in eyes with marked optic nerve damage than in eyes with slight to moderate optic nerve atrophy.

The purpose of the present study was to address the question whether this focal narrowing of retinal arterioles as seen clinically on colour fundus photographs is due to an ophthalmoscopic artefact or whether it really represents a stenosis of the vessel lumen.

Patients and methods

The study included 33 patients (16 women, 17 men) with open angle glaucoma and a mean age of 67.6 (SD 13.1) years and 76 subjects (35 women, 41 men) with normal optic nerves (mean age 60.9 (17.6) years). Criteria for the diagnosis of open angle glaucoma were an

open anterior chamber angle; elevated intraocular pressure to readings of more than 21 mm Hg or history of it; glaucomatous changes of the optic nerve head such as unusual small neuroretinal rim area in relation to the optic disc size, an abnormal shape of the neuroretinal rim, and cup to disc ratios being vertically higher than horizontally; and localised or diffuse retinal nerve fibre layer defects. Visual field loss was not taken into account, since perimetric defects were also caused by other fundus abnormalities which were the reason to perform the fluorescein angiography. This included age related macula degeneration in 17 patients, melanocytic lesions of the choroid in 15 patients, and central serous chorioretinopathy in one patient.

The non-glaucomatous group consisted of 76 patients in whom fluorescein angiography had been performed due to age related macula degeneration ($n=42$), melanocytic choroidal lesions ($n=24$), and central serous chorioretinopathy ($n=10$). Patients with diabetes mellitus, retinal vessel occlusion, and epiretinal membranes were excluded because these diseases might have influenced the ophthalmoscopic appearance of the retinal vessels. Frequency of arterial hypertension did not vary significantly

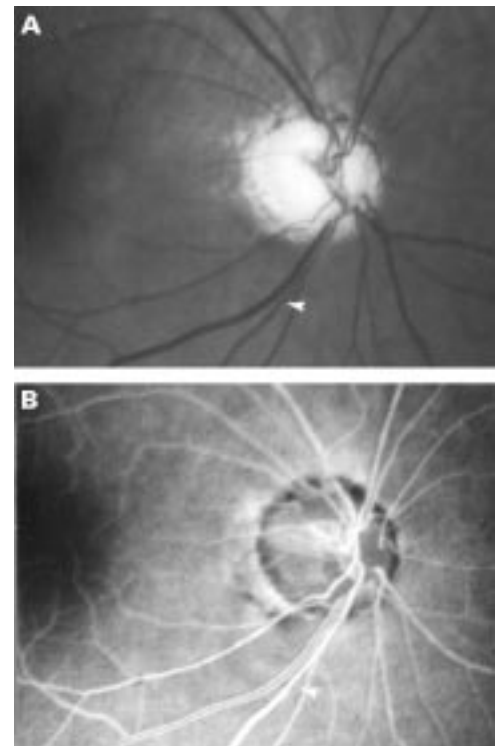


Figure 1 Clinical fundus photograph (A) and fluorescein angiogram (B) of a glaucomatous eye. Arrowheads: focal narrowing of retinal arteriole.

Department of
Ophthalmology and
Eye Hospital,
University
Erlangen-Nürnberg,
Germany
K I Papastathopoulos
J B Jonas

Correspondence to:
Dr J Jonas,
Universitäts-Augenklinik,
Schwabachanlage 6, 91054
Erlangen, Germany.

Accepted for publication
27 August 1997

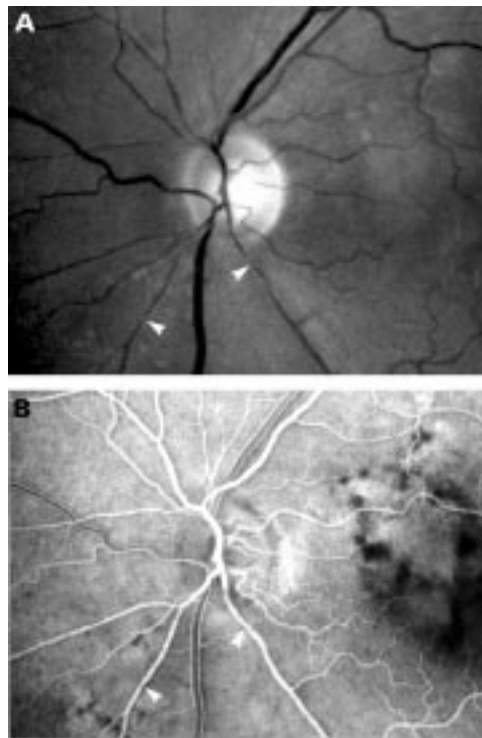


Figure 2 Clinical fundus photograph (A) and fluorescein angiogram (B) of a second glaucomatous eye. Arrowheads: focal narrowing of retinal arteriole.

($p=0.39$) between the non-glaucomatous group and the glaucomatous group. In the non-glaucomatous group, the appearance of the optic disc was normal. Reasons for optic nerve damage were not detected. The non-glaucomatous group and the glaucomatous group were matched for age.

For all eyes, 60° colour photographs of the fundus and 60° fluorescein angiographic transparencies were taken. They were examined in two steps. In a first step, the angiographic transparencies and the fundus photographs

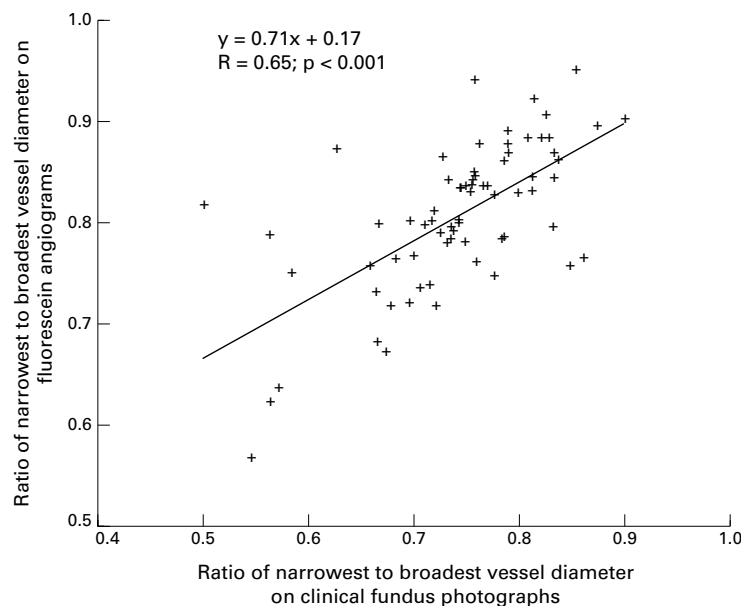


Figure 3 Scattergram showing the correlation between the ratio of the narrowest to broadest vessel diameter on the fluorescein angiograms compared with the same ratio on clinical fundus photographs.

were evaluated separately. After maximal defocusing of the projector, the diapositives were projected, the optic disc region was covered, and the projector was refocused again. Focal narrowing was graded on a scale ranging from "0" for vessels with a constant width to "6" for vessels with more than two filament-like parts (Figs 1 and 2). The narrow sections of the vessels were circumscribed with an abrupt transition to the broader part of the vessel. To determine the degree of vessel narrowing, only the ratio of vessel width in the narrowest part of the vessel to vessel width in the broadest part of the vessel at a distance of about 0.1 mm to 0.2 mm was considered. Because of an irregular course of the vessels, the area of the peripapillary scleral ring and the intrapapillary region were not taken into account. Vessel narrowing was evaluated only in the parapapillary region up to a distance of 10° from the centre of the optic disc.

In the second step of the examination, the angiographic transparencies and the fundus photographs were evaluated together. At the same retinal locations on the fundus photographs and on the angiographic transparencies, the width of the narrowest part of a vessel and the width of the broadest part of a vessel in the vicinity of the vessel constriction were measured directly with a millimetre scale. The ratio of the narrowest part of a vessel to the widest part of a vessel was calculated.

Results

Using the relative scale ranging from "0" to "6", the degree of focal narrowing of retinal arterioles on the colour fundus photographs was significantly correlated (Spearman's correlation coefficient $R = 0.74; p < 0.001$) with the degree of focal narrowing of the fluorescein filling of the retinal arterioles.

Comparing the direct measurements on the fundus photographs with the measurements on the fundus angiograms, the ratios of the diameter of the narrowest part of the arteriole to the diameter of the broadest part of the vessel were significantly and positively correlated with each other (Fig 3). All focal narrowings of the retinal arterioles as detected upon ophthalmoscopy on the fundus photographs showed a localised constriction of the vessel filling in the fluorescein angiograms.

Focal narrowing of the retinal arterioles on the fundus photographs (glaucoma group: 3.09 (SD 0.98) relative units versus non-glaucomatous group: 2.18 (1.16) relative units; $p < 0.001$; Mann-Whitney test) and on the fluorescein angiograms (glaucoma group: 2.72 (0.98) relative units versus non-glaucomatous group: 2.14 (1.0) relative units; $p < 0.05$; Mann-Whitney test) was significantly more marked in the glaucoma group than in the non-glaucomatous group. With no patients with stage III or IV hypertensive retinopathy included in the study, patients with and without arterial hypertension did not differ significantly ($p > 0.30$) in degree and frequency of focal narrowing of retinal arterioles, considered in the whole study population and taken separately within each of the two study groups. In

both study groups, the diameters of the arterioles were significantly larger ($p < 0.0001$ Wilcoxon test) on the fluorescein angiograms than on the fundus photographs.

Discussion

Generalised narrowing of the retinal vessels has been described for glaucomatous and non-glaucomatous optic neuropathies.^{1,2} In glaucoma, the vessel diameter reduces with decreasing area of the neuroretinal rim, diminishing visibility of the retinal nerve fibre layer, and increasing visual field defects.² Since the reduction of the vessel calibre is also found in eyes with non-glaucomatous optic nerve damage such as descending optic nerve atrophy¹ and non-arteritic anterior ischaemic optic neuropathy,⁶ it is inferred that a generalised reduction of the vessel diameter is typical for optic nerve damage but not characteristic for glaucoma. From a pathogenetic point of view, it suggested that vessel reduction was not causative for glaucomatous optic nerve fibre loss but secondary to a reduced demand in the superficial layers of the retina.

Rader *et al* have recently drawn attention to focal narrowing of the retinal arterioles in the peripapillary region of eyes with glaucoma or non-arteritic anterior ischaemic optic neuropathy.³ Similar observations were made by Rankin and Drance⁵ and others.⁴ These studies showed, as has already been demonstrated for a diffuse decrease in the diameter of the retinal arterioles, that focal narrowing of retinal arterioles was typical for eyes with optic nerve damage. Focal vessel narrowing was, however, not pathognomonic for glaucoma as a whole group nor specific for special types of the glaucomas such as normal pressure glaucoma.

In the present study, a significant correlation was found between focal narrowing of retinal arterioles on fundus photographs and narrowing of the same retinal arterioles on fluorescein angiograms. It suggests that focal vessel narrowing represents a real stenosis of the reti-

nal arterioles, and that it is not a purely ophthalmoscopic artefact. Since flow through a vessel is proportional to the square of the vessel radius, a reduction of the arteriole diameter by 50% or more, which has been described for eyes with optic neuropathies,³⁻⁵ may lead to a marked change in blood flow. It suggests that focal narrowing of the retinal arterioles may be associated with some of the haemodynamic changes which have already been found in the optic nerve and retina of eyes with glaucoma.⁷⁻¹³

Presented at the Annual Meeting of the American Academy of Ophthalmology, Chicago, 27-31 October 1996.

Supported by Deutsche Forschungsgemeinschaft (Klinische Forschergruppe "Glaukome", grant No Na 55/6-2).

- 1 Frisén L, Claesson M. Narrowing of the retinal arterioles in descending optic atrophy. A quantitative clinical study. *Ophthalmology* 1984;**91**:1342-6.
- 2 Jonas JB, Naumann GOH. Parapapillary retinal vessel diameter in normal and glaucoma eyes. II Correlations. *Invest Ophthalmol Vis Sci* 1989;**30**:1604-11.
- 3 Rader J, Feuer J, Anderson DR. Peripapillary vasoconstriction in the glaucomas and the anterior ischemic optic neuropathy. *Am J Ophthalmol* 1994;**117**:72-80.
- 4 Papastathopoulos KI, Jonas JB. Focal narrowing of retinal arterioles in optic nerve atrophy. *Ophthalmology* 1995;**102**:1706-11.
- 5 Rankin SJA, Drance SM. Peripapillary focal retinal arteriolar narrowing in open angle glaucoma. *J Glaucoma* 1996;**5**:22-8.
- 6 Jonas JB, Xu L. Optic disc morphology in eyes after nonarteritic anterior ischemic optic neuropathy. *Invest Ophthalmol Vis Sci* 1993;**34**:2260-5.
- 7 Spaeth GL. Fluorescein angiography: its contributions towards understanding the mechanisms of visual loss in glaucoma. *Trans Am Ophthalmol Soc* 1975;**73**:491-553.
- 8 Schwartz B, Kern J. Age, increased ocular and blood pressures, and retinal and disc fluorescein angiogram. *Arch Ophthalmol* 1980;**98**:1980-6.
- 9 Tuulonen A, Nagin P, Schwartz B, Wu DC. Increase of pallor and fluorescein filling defects of the optic disc in the follow up of ocular hypertensives measured by computerized image analysis. *Ophthalmology* 1987;**94**:558-63.
- 10 Nanba K, Schwartz B. Nerve fiber layer and optic disc fluorescein filling defects in glaucoma and ocular hypertension. *Ophthalmology* 1988;**95**:1227-33.
- 11 Robert Y, Steiner D, Hendrickson P. Papillary circulation dynamics in glaucoma. *Graefes Arch Clin Exp Ophthalmol* 1989;**27**:436-9.
- 12 Wolf S, Arend O, Sponsel WE, *et al*. Retinal hemodynamics using scanning laser ophthalmoscopy and hemorrheology in chronic open-angle glaucoma. *Ophthalmology* 1993;**100**:1561-6.
- 13 Michelson G, Langhans MJ, Groh MJM. Perfusion of the juxtrapapillary retina and the neuroretinal rim area in primary open-angle glaucoma. *J Glaucoma* 1996;**5**:91-8.



Fluorescein angiographic correlation of focal narrowing of retinal arterioles in glaucoma

Konstantinos I Papastathopoulos and Jost B Jonas

Br J Ophthalmol 1998 82: 48-50

doi: 10.1136/bjo.82.1.48

Updated information and services can be found at:

<http://bjo.bmj.com/content/82/1/48.full.html>

References

These include:

This article cites 13 articles, 3 of which can be accessed free at:

<http://bjo.bmj.com/content/82/1/48.full.html#ref-list-1>

Article cited in:

<http://bjo.bmj.com/content/82/1/48.full.html#related-urls>

Email alerting service

Receive free email alerts when new articles cite this article. Sign up in the box at the top right corner of the online article.

Topic Collections

Articles on similar topics can be found in the following collections

[Neurology](#) (1042 articles)
[Optic nerve](#) (558 articles)
[Angle](#) (791 articles)
[Glaucoma](#) (779 articles)
[Intraocular pressure](#) (789 articles)

Notes

To request permissions go to:

<http://group.bmj.com/group/rights-licensing/permissions>

To order reprints go to:

<http://journals.bmj.com/cgi/reprintform>

To subscribe to BMJ go to:

<http://group.bmj.com/subscribe/>