

Neuroretinal rim width ratios in morphological glaucoma diagnosis

Jost B Jonas, Wido M Budde, Peter Lang

Abstract

Aims—To evaluate the inferior to temporal neuroretinal rim width ratio and superior to temporal rim width ratio as measures of rim shape for diagnosis of glaucoma.

Methods—Colour stereo optic disc photographs of 527 normal subjects, 100 ocular hypertensive individuals with normal visual fields, and 202 open angle glaucoma patients with a mean perimetric defect of less than 10 dB were morphometrically evaluated. Eyes with an optic cup area of < 0.2 mm² were excluded.

Results—In the normal subjects, inferior to temporal rim width ratio (1.67 (SD 0.53)) was significantly ($p < 0.0001$) higher than superior to temporal rim width ratio (1.56 (0.49)). Both ratios were significantly ($p < 0.0001$) higher the more vertically the optic disc was configured. In the normal eyes, both ratios were statistically independent of disc size, rim area, refractive error, age, and sex. With the differences being more marked for the inferior to temporal ratio than for the superior to temporal ratio, both rim width ratios were significantly ($p < 0.005$) lower in the ocular hypertensive group than in the normal group. Despite the high significance of the differences, diagnostic power of the inferior ratio and the superior ratio was 59% and 58%, respectively, indicating a marked overlap between the groups.

Conclusions—Abnormally low inferior to temporal and superior to temporal rim width ratios can indicate glaucomatous optic nerve damage in some ocular hypertensive eyes. Being independent of optic disc size and ocular magnification, the rim width ratios may be taken as one among other variables for the ophthalmoscopic optic disc evaluation, taking into account, however, a pronounced overlap between normal eyes and ocular hypertensive eyes.

(Br J Ophthalmol 1998;82:1366-1371)

The neuroretinal rim is the intrapapillary equivalent of the optic nerve fibres. It is one of the main targets in the diagnosis of glaucomatous optic neuropathy.^{1,2} The neuroretinal rim can be described by its area,^{1,2} its volume above a reference level,^{3,4} pallor,⁵ and shape.⁶ These variables can be determined by planimetric evaluation of stereo optic disc photographs,^{1,2,6} by confocal scanning laser tomography of the optic nerve head,^{3,4} or by measurement of pallor.⁵

Previous studies using planimetry of optic disc photographs have shown that, besides the visibility of the retinal nerve fibre layer, the shape of the neuroretinal rim belongs to the most important optic disc variables for the early detection of glaucomatous optic nerve damage in ocular hypertensive eyes with normal white on white visual field examinations.⁷ The shape of the neuroretinal rim can furthermore be estimated ophthalmoscopically without taking optic disc photographs or without applying sophisticated techniques such as confocal scanning laser tomography of the optic nerve head^{3,4} or laser polarimetry of the retinal nerve fibre layer.⁸

The purpose of the present study was, therefore, to quantify the shape of the neuroretinal rim. We used the ratios of inferior to temporal rim width and superior to temporal rim width, and determined the value of these rim width ratios for the detection of glaucomatous optic nerve damage in ocular hypertensive eyes with normal achromatic visual fields.

Patients and methods

The study consisted of 100 ocular hypertensive subjects with increased intraocular pressure and normal visual fields, 202 patients with primary or secondary open angle glaucoma with a mean visual field defect ranging between 2 dB and 10 dB, and 527 normal subjects (Table 1). Prerequisite to be included in the study was the availability of good stereoscopic optic disc photographs.

The ocular hypertensive group included eyes with intraocular pressure readings of more than 21 mm Hg or history of it, and normal visual fields (Octopus program G1). About 55% of the individuals in the ocular hypertensive group were taking antiglaucomatous treatment either because the intraocular pressure measurements had repeatedly been higher than about 25 mm Hg, because the contralateral eye not included in the study showed glaucomatous visual field defects, or because the synopsis of glaucoma risk factors such as positive family history and a rather high intraocular pressure suggested antiglaucomatous treatment.

Department of Ophthalmology and Eye Hospital, Friedrich-Alexander-University Erlangen-Nürnberg, Erlangen, Germany
J B Jonas
W M Budde
P Lang

Correspondence to:
Dr J Jonas,
Universitäts-Augenklinik,
Schwabachanlage 6, 91054
Erlangen, Germany.

Accepted for publication
3 June 1998

Table 1 Composition of the study groups (mean (SD))

	Normal group	Ocular hypertensive group	Glaucoma group
Number	527	100	202
Age (years)	46.9 (16.2)	52.3 (14.9)	57.4 (14.0)
Range	4-83	12-79	23-87
Women/men	270/257	44/56	106/96
Refractive error (D)	-0.09 (2.08)	-0.65 (2.20)	-0.44 (2.27)
Range	-7.88 to +8.50	-7.50 to +4.0	-7.0 to +5.0

Criteria for the diagnosis of open angle glaucoma were an open anterior chamber angle, maximal intraocular pressure values higher than 21 mm Hg, and glaucomatous visual field defects. Glaucomatous visual field defects were defined as a Octopus G1 field with (a) at least three adjacent test points having a deviation of equal to or greater than 5 dB and with one test point with a deviation greater than 10 dB, (b) at least two adjacent test points with a deviation equal to or greater than 10 dB, (c) at least three adjacent test points with a deviation equal to or greater than 5 dB abutting the nasal horizontal meridian, and (d) elevated global visual field indices. In the primary open angle glaucoma group, the reason for an elevation of intraocular pressure was unknown. In the group with secondary open angle glaucoma, the increase of intraocular pressure to values above 21 mm Hg was due to pseudoexfoliative glaucoma or pigmentary glaucoma. For the ocular hypertensive group and for the glaucoma group, the appearance of the optic disc was not taken into account.

The normal subjects were recruited from the administrative university staff who were asked to serve as control subjects, or they were patients who attended the hospital for diseases in the contralateral eye that was not included in the study. These diseases such as rhegmatogenous retinal detachment did not primarily affect the optic nerve.

Eyes with a myopic refractive error exceeding -8.0 dioptres were excluded because of their different optic disc morphology.⁹ To be able to measure the width of the neuroretinal rim, we excluded all eyes with an optic cup area equal to or less than 0.2 mm^2 . Although the three study groups varied in mean age (Table 1), matching for this variable was not performed, since size and shape of the neuroretinal rim are statistically independent of age.⁶ Only one randomly selected eye per patient and subject was taken for statistical analysis. It means for the subjects in the ocular hypertensive group that the contralateral eye, which was not included in the study, could have glaucomatous visual field loss, or that intraocular pressure was elevated and visual field was normal, or that intraocular pressure measurements had always been normal.

For all eyes, 15° colour stereo optic disc transparencies had been taken using a Zeiss telecentric fundus camera. The disc slides were projected in a scale of 1 to 15. The outlines of the optic disc and optic cup were plotted on paper and morphometrically analysed. To obtain values in absolute size units—that is, mm or mm^2 , the ocular and photographic magnification was corrected using Littmann's method.¹⁰ The optic cup was defined on the basis of contour and not of pallor. The border of the optic disc was identical to the inner side of the peripapillary scleral ring. The method has already been described in detail.⁶ The width of the neuroretinal rim was determined in the temporal disc region, in the inferior disc region at the 6 o'clock position, and in the superior disc region at 12 o'clock position (Figs 1 and 2). As a measure for the shape of

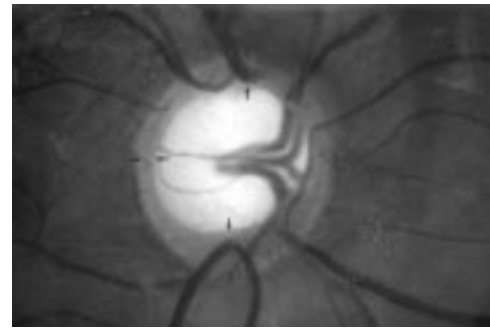


Figure 1 Photograph of an abnormally large, otherwise normal optic disc. Optic disc data: area, 5.7 mm^2 ; neuroretinal rim width (arrows) inferior, 0.57 mm ; superior, 0.35 mm ; temporal, 0.18 mm ; ratio of inferior to temporal rim width, 3.17 ; ratio of superior to temporal rim width, 1.94 . Note physiological shape of the neuroretinal rim.

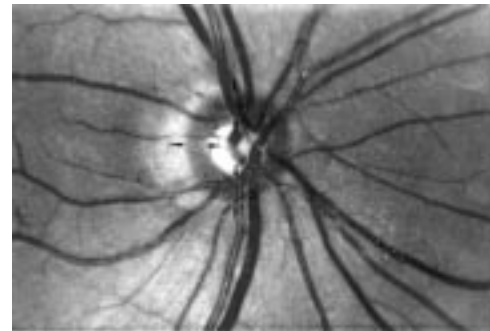


Figure 2 Optic disc photograph of an ocular hypertensive eye without visual field defects. Optic disc data: area, 1.80 mm^2 ; neuroretinal rim width (arrows) inferior, 0.37 mm ; superior, 0.39 mm ; temporal, 0.34 mm ; ratio of inferior to temporal rim width, 1.09 ; ratio of superior to temporal rim width, 1.15 . Note abnormal shape of the neuroretinal rim.

the neuroretinal rim, the ratio of the inferior to temporal rim width and the ratio of the superior to temporal rim width were calculated. The photographs were evaluated in a masked fashion without knowledge of the clinical diagnosis and the visual field data.

To assess the statistical significance of differences between the study groups, the Student's *t* test was used.

Results

In the normal subjects, the ratio of inferior to temporal rim width was significantly ($p < 0.0001$) higher than the ratio of superior to temporal rim width (Table 2). Correspondingly, the neuroretinal rim was significantly ($p < 0.0001$) broader at the inferior disc border than at the superior disc border (Table 2). Both neuroretinal rim ratios were significantly ($p < 0.0001$) and positively correlated with the quotient of vertical to horizontal disc diameter: the higher were both ratios the more vertically the optic disc was configured (for inferior to temporal rim width ratio: Pearson's correlation coefficient $R = 0.23$; equation of the regression line: rim width ratio = 1.43 (ratio of vertical to horizontal disc diameter) + 0.13 ; $p < 0.0001$). In the normal eyes, both rim width ratios were statistically independent of optic disc size, neuroretinal rim area, refractive error, age, sex, and right or left eye ($p > 0.10$, Pearson's correlation coefficient $R^2 < 0.02$).

Table 2 Morphometric optic disc data (mean (SD))

	Normal group	Ocular hypertensive group	p Value*	Glaucoma group	p Value*
Number	527	100		202	
Ratio inferior to temporal rim width	1.67 (0.53)	1.48 (0.53)	0.0002	1.38 (0.57)	<0.0001
Ratio superior to temporal rim width	1.56 (0.49)	1.41 (0.43)	0.004	1.38 (0.51)	<0.0001
Neuroretinal rim width (mm)					
Inferior	0.47 (0.12)	0.35 (0.10)	<0.0001	0.32 (0.12)	<0.0001
Superior	0.44 (0.12)	0.34 (0.10)	<0.0001	0.31 (0.11)	<0.0001
Temporal	0.30 (0.10)	0.25 (0.08)	<0.0001	0.24 (0.09)	<0.0001
Optic disc area (mm ²)	2.76 (0.63)	2.70 (0.56)	0.49 (NS)	2.68 (0.59)	0.17 (NS)
Horizontal cup to disc ratio	0.61 (0.13)	0.67 (0.11)	<0.0001	0.69 (0.10)	<0.0001
Vertical cup to disc ratio	0.54 (0.13)	0.65 (0.10)	<0.0001	0.67 (0.11)	<0.0001
Ratio vertical to horizontal disc diameter	1.08 (0.09)	1.08 (0.09)	0.63 (NS)	1.08 (0.09)	0.41 (NS)

*p Value=significance of difference between the preceding group and the normal group; NS=statistically not significant.

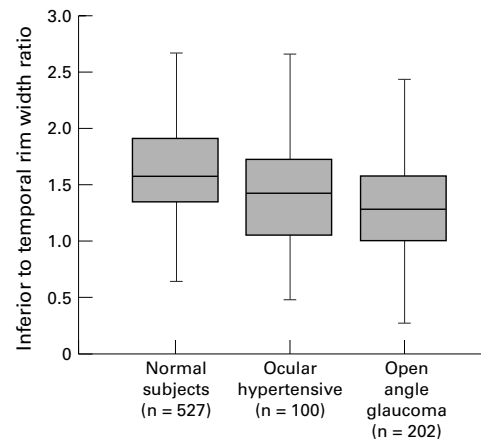


Figure 3 Box plot showing the distribution of the inferior to temporal rim width ratio in the three study groups.

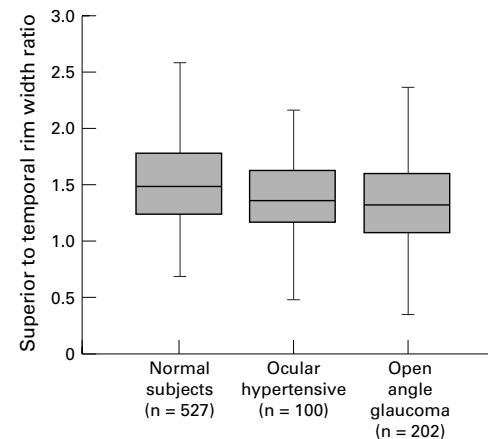


Figure 4 Box plot showing the distribution of the superior to temporal rim width ratio in the three study groups.

In the ocular hypertensive group, the ratio of inferior to temporal rim width and the ratio of superior to temporal rim width were significantly smaller than in the normal group ($p=0.0002$ and $p=0.004$, respectively) (Table 2). The difference between the normal group and the ocular hypertensive group was more marked (0.19 versus 0.15) and statistically more significant ($p=0.0002$ versus $p=0.004$) for the inferior to temporal rim width ratio than for the superior to temporal rim width ratio.

Despite the high significance of the differences between the normal group and the ocular hypertensive group, the diagnostic powers of the inferior to temporal rim width ratio and the superior to temporal rim width ratio were only 59% and 58%, respectively. Diagnostic power was defined as the percentage of the area under the receiver operator curve on the total area when sensitivity was plotted against $1 - \text{specificity}$. It indicates a marked overlap between both groups (Figs 3 and 4).

In an attempt to increase the diagnostic power, the rim width ratios were corrected for their dependence on the optic disc shape. We used two formulas: corrected rim width ratio = (measured rim width ratio)/(expected rim width ratio) \times (mean of rim width ratio in the normal group), and: rim width ratio defect = expected rim width ratio - measured rim width ratio.

Expected inferior to temporal rim width ratio and expected superior to temporal rim width ratio, respectively, were calculated as: 1.43 (1.22, respectively) \times (ratio of vertical to

horizontal disc diameter) + 0.13 (0.24, respectively). These were the equations of the regression lines when the rim width ratios were correlated with the vertical to horizontal disc diameter ratio.

Using these two formulas, the diagnostic power to separate normal eyes from ocular hypertensive eyes did not change.

In the glaucoma group with visual field loss, both rim width ratios were significantly ($p<0.0001$) smaller than in the normal group (Table 2). The differences between both groups were more marked for the ratio of inferior to temporal rim width (difference 0.29) than for the ratio of superior to temporal rim width (difference 0.18). Correspondingly, the differences between the ocular hypertensive group without visual field defects and the glaucoma group with visual field defects were more marked for the ratio of inferior to temporal rim width (difference 0.10) than for the ratio of superior to temporal rim width (difference 0.03) (Table 2).

Disc area and, consequently, the cup to disc diameter ratios in the normal eyes were higher in the present study than in previous reports.⁶ The reason is that, in the present investigation, eyes with an optic cup area of equal to or less than 0.2 mm² were excluded.

Discussion

Both neuroretinal rim width ratios in the ocular hypertensive group without visual field defects were significantly lower than in the normal group ($p<0.0001$) (Table 2). The

reasons are the physiological shape of the neuroretinal rim in normal eyes⁶ (Fig 1), and the pattern of loss of neuroretinal rim in glaucomatous eyes.

In normal eyes, the rim has a characteristic configuration with the rim width being broadest in the inferior disc region, followed by the superior disc sector, the nasal disc area, and finally the temporal disc sector⁶ (Fig 1). It corresponds with the finding that in the normal group of the present study the inferior to temporal rim width ratio was significantly higher than the superior to temporal rim width ratio (Table 2). In early glaucoma, neuroretinal rim is preferentially lost in the inferior and superior disc regions (Table 2)¹¹⁻²² (Fig 2). This also accounts for eyes with early glaucomatous optic nerve damage in which conventional achromatic perimetry can still be normal.^{7 17-22} Correspondingly, the difference between the ocular hypertensive group and the normal group in the present study was higher for the vertical cup to disc diameter ratio than for the horizontal cup to disc diameter ratio (Table 2). The preferred rim loss in the inferior and superior disc area leads to a change in the neuroretinal rim shape. Instead of being broadest in the inferior and superior disc regions, the rim width is then more or less even in all regions of the optic disc. It is the reason why the inferior to temporal rim width ratio and the superior to temporal rim width ratio decreased significantly ($p < 0.0001$) from the normal group to the ocular hypertensive group and the glaucoma group with visual field defect (Table 2).

Despite the statistically large difference between the normal group and the ocular hypertensive group, the diagnostic power of the inferior to temporal rim width ratio and the superior to temporal rim width ratio was only 59% and 58%, respectively, indicating a marked overlap between the groups (Figs 3 and 4). Despite the pronounced overlap, the highly significant differences between the normal eyes and the ocular hypertensive eyes suggest that abnormally low rim width ratios can indicate glaucomatous optic nerve damage in some ocular hypertensive eyes with normal perimetric results. In view of the overlap between the study groups (Figs 3 and 4), one must take into account that the rim width ratios are only additional variables among other variables for the quantitative optic disc analysis. Since they are independent of the optic disc size and the magnification by the ocular media and a fundus camera, they can also serve for the subjective ophthalmoscopic evaluation of the optic nerve head. It implies that in glaucoma suspects the shape of the neuroretinal rim should be checked whether it is in the inferior and superior disc regions markedly—that is, about 50% to 60%, broader than in the temporal disc sector, which suggests a normal optic nerve, or whether the rim width is more or less even in the inferior, superior, and temporal disc regions pointing at a glaucomatous loss of optic nerve fibres predominantly in the inferior and superior optic disc regions (Figs 1 and 2).

Using the neuroretinal rim width ratios, several aspects have to be taken into account. The

rim width ratios depend on the shape of the optic disc. The reason for this is that in horizontally oval shaped optic discs, the retinal nerve fibre bundles have a longer part of the disc circumference to enter the optic nerve head than they have in vertically oval optic discs. Correspondingly, the retinal nerve fibres in the inferior and superior disc regions are more crowded in vertically oval optic discs than in horizontally oval discs. This leads to a broader neuroretinal rim in the inferior and superior disc regions, and consequently to higher inferior to temporal rim width ratio and superior to temporal rim width ratio in vertically elongated optic nerve heads than in horizontally shaped optic discs.

Another factor which has to be taken into account is that the pattern of glaucomatous loss of neuroretinal rim depends on the type of glaucoma. In high pressure glaucoma, typically found in patients with juvenile onset primary open angle glaucoma, the neuroretinal rim is often concentrically diminished without development of neuroretinal rim notches.²³ Rim notches are present in eyes with the focal normal pressure glaucoma in which the neuroretinal rim typically shows localised defects in the temporal inferior and temporal superior disc sector.²⁴ This suggests that a glaucomatous shape of the neuroretinal rim can better be demonstrated by the neuroretinal rim width ratios in eyes with the focal normal pressure glaucoma than in eyes with high pressure glaucoma.

An additional aspect to consider is that the pattern of glaucomatous neuroretinal rim loss partially depends on the position of the central retinal vessel trunk in the lamina cribrosa.²⁵ Within the optic disc, the local susceptibility for glaucomatous neuroretinal rim loss is higher, the longer the distance to the exit of the central retinal vessel trunk out of the lamina cribrosa. In eyes with a normal position of the central retinal vessel trunk and a normal optic disc shape, the optic disc region with the longest distance to the vessel trunk is the temporal inferior disc sector. In eyes with an abnormal location of the central retinal vessel trunk or with an unusual optic disc shape, however, other disc sectors than the temporal inferior optic disc region can have the longest distance to the central retinal vessel trunk predisposing them to an early loss of neuroretinal rim. In these eyes, the ratio of inferior to temporal rim width and the ratio of superior to temporal rim width ratio will be less helpful for an early detection of glaucomatous optic nerve damage.

The rim width ratios will be helpful for the differentiation between glaucomatous optic nerve damage and non-glaucomatous optic nerve atrophy. In the latter, the neuroretinal rim shape has not markedly changed²⁶ so that the rim width ratios will be in the normal range, whereas in glaucomatous optic nerve damage the abnormal configuration of the neuroretinal rim is reflected in abnormal rim width ratios.

The rim width ratios as quotients of two linear measurements are independent of the magnification by the optic media of the eye, the

fundus camera, or the confocal scanning laser tomograph. This is an advantage since the various devices for quantification of the optic disc structure vary in the method for correction of the ocular and camera magnification. This leads to varying mean values of the optic disc area in the normal population when various techniques for measuring the optic nerve head are compared with each other.^{6 27-29}

Finally, the rim width ratios were statistically independent of the optic disc size. Considering the marked interindividual variability of the optic disc area,^{6 26-30} the independence of the rim width ratios from the optic disc size is an advantage. Otherwise one would have to measure the optic disc size ophthalmoscopically,³¹ before the rim width ratios could be used for glaucoma diagnosis. The independence of the neuroretinal rim width ratios on the optic disc size is further an advantage, since a recent study has shown that the diagnostic power of a subjective evaluation of the optic disc in glaucoma diagnosis depends on the disc size; the larger the optic disc the higher the chance for a normal optic disc to be rated as glaucomatous.³²

The values of the inferior to temporal rim width ratio and of the superior to temporal rim width ratio as measured planimetrically in this study may cautiously be transferred to the morphometric optic disc data as measured by a confocal scanning laser tomograph. One has to take into account that, owing to its algorithm, a confocal scanning laser tomograph considers parts of retinal vessel trunk to belong to the neuroretinal rim.³³ It leads to relatively larger rim width measurements by the confocal scanning laser system than by planimetry of optic disc photographs. Since the retinal vessel trunk is usually located in the nasal region of the optic disc, the differences in neuroretinal rim measurement between both methods are largest in the nasal disc region, while in the inferior, superior, and temporal disc areas both methods almost show congruent results.³³ This suggests that the findings of the present study may be transferred to studies using a confocal scanning laser tomograph.

The statistically high significance of the difference in the rim width ratios between the ocular hypertensive group and the normal group may not be exaggerated since the individuals in the ocular hypertensive group were highly preselected being referred to a university hospital. The subjects in the ocular hypertensive group had a relatively high risk of eventually developing glaucomatous perimetric defects, which is already shown by the high frequency of antiglaucomatous treatment in this group. One can infer that, in the general population, ocular hypertensive subjects with morphological optic disc changes form a considerably lower proportion of the total ocular hypertensive group than in the present study. Furthermore in the present study, some of the ocular hypertensive individuals received an antiglaucomatous treatment, suggesting that they were thought to be at rather high risk of developing glaucomatous visual field defects. On the other hand, reducing the intraocular pressure by antiglaucomatous

treatment, might have changed the optic disc morphology to a smaller optic cup and a larger area of neuroretinal rim.³⁴ This serves to underline the findings of the present study that the inferior to temporal rim width ratio and the superior to temporal rim width ratio are helpful for early detection of glaucomatous optic nerve damage in some ocular hypertensive eyes without glaucomatous visual field defects. In view of the pronounced overlap between the normal subjects and the ocular hypertensive group (Figs 3 and 4), however, one must take into account that the inferior to temporal neuroretinal rim width ratio and the superior to temporal neuroretinal rim width ratio are not at all sufficient for an early glaucoma detection in all eyes with preperimetric glaucomatous optic nerve damage, and that the rim width ratio is only one among several other variables for the recognition of glaucomatous changes.

Supported by Deutsche Forschungsgemeinschaft (grant SFB 539).

- 1 Betz Ph, Camps F, Collignon-Brach J, *et al.* Biometric study of the disc cup in open-angle glaucoma. *Graefes Arch Clin Exp Ophthalmol* 1982;218:70-4.
- 2 Airaksinen PJ, Drance SM, Schulzer M. Neuroretinal rim area in early glaucoma. *Am J Ophthalmol* 1985;99:1-4.
- 3 Burk ROW, Rohrschneider K, Takamoto T, *et al.* Laser scanning tomography and stereophotogrammetry in three-dimensional optic disc analysis. *Graefes Arch Clin Exp Ophthalmol* 1993;231:193-8.
- 4 Uchida H, Brigatti L, Caprioli J. Detection of structural damage from glaucoma with confocal laser image analysis. *Invest Ophthalmol Vis Sci* 1996;37:2393-401.
- 5 Schwartz B, Reinstein NM, Lieberman DM. Pallor of the optic disc; quantitative photographic evaluation. *Arch Ophthalmol* 1973;89:278-86.
- 6 Jonas JB, Gusek GC, Naumann GOH. Optic disc, cup and neuroretinal rim size, configuration, and correlations in normal eyes. *Invest Ophthalmol Vis Sci* 1988;29:1151-8. (Correction: *Invest Ophthalmol Vis Sci* 1991;32:1893.)
- 7 Jonas JB, Königsreuther KA. Optic disc appearance in ocular hypertensive eyes. *Am J Ophthalmol* 1994;117:732-40.
- 8 Weinreb RN, Shakiba S, Zangwil L. Scanning laser polarimetry to measure the nerve fiber layer of normal and glaucomatous eyes. *Am J Ophthalmol* 1995;119:627-36.
- 9 Jonas JB, Gusek GC, Naumann GOH. Optic disc morphometry in high myopia. *Graefes Arch Clin Exp Ophthalmol* 1988;226:587-90.
- 10 Littmann H. Zur Bestimmung der wahren Größe eines Objektes auf dem Hintergrund des lebenden Auges. *Klin Monatsbl Augenheilkd* 1982;180:286-9.
- 11 Becker B. Cup/disc ratio and topical corticosteroid testing. *Am J Ophthalmol* 1970;70:681-5.
- 12 Kirsch RE, Anderson DR. Clinical recognition of glaucomatous cupping. *Am J Ophthalmol* 1973;75:442-54.
- 13 Read RL, Spaeth GL. The practical clinical appraisal of the optic disc in glaucoma. The natural history of cup progression and some specific disc-field correlations. *Trans Acad Ophthalmol Otol* 1974;78:255-74.
- 14 Gloster J. Vertical ovalness of glaucomatous cupping. *Br J Ophthalmol* 1975;59:721-4.
- 15 Hart WM Jr, Yablonski M, Kass MA, *et al.* Quantitative visual field and optic disc correlates early in glaucoma. *Arch Ophthalmol* 1978;96:2209-11.
- 16 Pederson JE, Anderson DR. The mode of progressive disc cupping in ocular hypertension and glaucoma. *Arch Ophthalmol* 1980;98:490-5.
- 17 Balazsi AG, Drance SM, Schulzer M, *et al.* Neuroretinal rim area in suspected glaucoma and early open-angle glaucoma. Correlations with parameters of visual function. *Arch Ophthalmol* 1984;102:1011-4.
- 18 Caprioli J, Miller JM, Sears M. Quantitative evaluation of the optic nerve head in patients with unilateral visual field loss from primary open-angle glaucoma. *Ophthalmology* 1987;94:1484-7.
- 19 Tuulonen A, Airaksinen PJ. Initial glaucomatous optic disc and retinal nerve fiber layer abnormalities and the mode of their progression. *Am J Ophthalmol* 1991;111:485-90.
- 20 Funk J. Early detection of glaucoma by longitudinal monitoring of the optic disc structure. *Graefes Arch Clin Exp Ophthalmol* 1991;29:57-61.
- 21 Airaksinen PJ, Tuulonen A, Alanko HI. Rate and pattern of neuroretinal rim area decrease in ocular hypertension and glaucoma. *Arch Ophthalmol* 1992;110:206-10.
- 22 Zeyen TG, Caprioli J. Progression of disc and field damage in early glaucoma. *Arch Ophthalmol* 1993;111:62-5.
- 23 Jonas JB, Gründler AE. Optic disc morphology in juvenile primary open-angle glaucoma. *Graefes Arch Clin Exp Ophthalmol* 1996;234:750-4.

- 24 Spaeth GL, Hitchings RA, Sivalingam E. The optic disc in glaucoma: pathogenetic correlation of five patterns of cupping in chronic open-angle glaucoma. *Trans Am Acad Ophthalmol Otolaryngol* 1976;**81**:217-23.
- 25 Jonas JB, Fernández MC. Shape of the neuroretinal rim and position of the central retinal vessels in glaucoma. *Br J Ophthalmol* 1994;**78**:99-102.
- 26 Jonas JB, Xu L. Optic disc morphology in eyes after nonarteritic anterior ischemic optic neuropathy. *Invest Ophthalmol Vis Sci* 1993;**34**:2260-5.
- 27 Burk ROW, Rohrschneider K, Noack H, *et al.* Are large optic nerve heads susceptible to glaucomatous damage at normal intraocular pressure. A three-dimensional study by scanning laser tomography. *Graefes Arch Clin Exp Ophthalmol* 1992;**230**:552-60.
- 28 Tuulonen A, Airaksinen PJ. Optic disc size in exfoliative, primary open angle, and low-tension glaucoma. *Arch Ophthalmol* 1992;**110**:211-3.
- 29 Varma R, Tielsch JM, Quigley HA, *et al.* Race-, age-, gender-, and refractive error-related differences in the normal optic disc. *Arch Ophthalmol* 1994;**112**:1068-76.
- 30 Bengtsson B. The variation and covariation of cup and disc diameters. *Acta Ophthalmol* 1976;**54**:804-18.
- 31 Spencer AF, Vernon SA. Optic disc measurement with the Zeiss four mirror contact lens. *Br J Ophthalmol* 1994;**78**:775-80.
- 32 Heijl A, Molder H. Optic disc diameter influences the ability to detect glaucomatous disc damage. *Acta Ophthalmol* 1993;**71**:122-9.
- 33 Dichtl A, Jonas JB, Mardin CY. Comparison between laser tomographic scanning evaluation and photographic measurement of the neuroretinal rim. *Am J Ophthalmol* 1996;**121**:494-501.
- 34 Parrow KA, Shin DH, Tsai CS, *et al.* Intraocular pressure-dependent dynamic changes of optic disc cupping in adult glaucoma patients. *Ophthalmology* 1992;**99**:36-40.



Neuroretinal rim width ratios in morphological glaucoma diagnosis

Jost B Jonas, Wido M Budde and Peter Lang

Br J Ophthalmol 1998 82: 1366-1371

doi: 10.1136/bjo.82.12.1366

Updated information and services can be found at:

<http://bjo.bmj.com/content/82/12/1366.full.html>

These include:

References

This article cites 32 articles, 14 of which can be accessed free at:

<http://bjo.bmj.com/content/82/12/1366.full.html#ref-list-1>

Article cited in:

<http://bjo.bmj.com/content/82/12/1366.full.html#related-urls>

Email alerting service

Receive free email alerts when new articles cite this article. Sign up in the box at the top right corner of the online article.

Topic Collections

Articles on similar topics can be found in the following collections

[Angle](#) (788 articles)
[Glaucoma](#) (776 articles)
[Intraocular pressure](#) (786 articles)
[Optic nerve](#) (552 articles)
[Optics and refraction](#) (381 articles)

Notes

To request permissions go to:

<http://group.bmj.com/group/rights-licensing/permissions>

To order reprints go to:

<http://journals.bmj.com/cgi/reprintform>

To subscribe to BMJ go to:

<http://group.bmj.com/subscribe/>