

Nd:YAG laser iridotomy in pigment dispersion syndrome: an ultrasound biomicroscopic study

Roberto G Carassa, Paolo Bettin, Marina Fiori, Rosario Brancato

Abstract

Aims—Ultrasound biomicroscopy was used to study the shape of the iris and the iridolenticular contact in pigment dispersion syndrome (PDS) eyes, to compare them with matched normal eyes, and to assess the morphological effects of laser iridotomy in PDS eyes.

Methods—50 eyes of 50 patients suffering from PDS (group 1), and 15 normal eyes of 15 subjects matched for age and refraction (group 2), were studied by ultrasound biomicroscopy (UBM, Humphrey-Zeiss). Nd:YAG laser iridotomy was proposed to the 30 PDS patients with concave iris and 18 underwent the treatment.

Results—The iris was concave in 27 eyes in group 1, and three more eyes showed a concave iris during accommodation. Among normals, iris concavity was present in two eyes. The height of the iris convexity was -0.15 (0.24) mm (range -0.65 to $+0.21$), in the eyes of group 1, whereas it was $+0.07$ (0.10) mm (range -0.21 to $+0.16$) in group 2 ($p < 0.0012$). Group 1 had greater iridolenticular contact than group 2: 1.55 (0.78) mm (range 0.30 – 2.88) and 1.07 (0.61) (range 0.30 – 2.50 ; $p = 0.0304$). After laser iridotomy, only one eye still had a concave iris. Pre- and post-treatment deflections were -0.35 (0.18) mm (range -0.61 to -0.05) and $+0.01$ (0.06) mm (range -0.12 to $+0.17$), respectively ($p < 0.0001$). Pre- and post-treatment iridolenticular contact was 2.10 (0.65) mm (range 0.70 – 2.88) and 0.93 (0.38) mm (range 0.4 – 1.75), respectively ($p < 0.0001$). After laser iridotomy, the treated irises were flatter than normal ($p = 0.0207$), whereas the iridolenticular contact was not significantly different.

Conclusions—Laser iridotomy can restore a normal iris shape and iridolenticular contact in eyes suffering from PDS.

(*Br J Ophthalmol* 1998;82:150-153)

Laser iridotomy was proposed to reverse iris concavity thus reducing pigment granule release in pigment dispersion syndrome (PDS) by Campbell (oral communication at the meeting of the American Glaucoma Society, San Diego, 11-14 December 1991), and Karickhoff.¹

Using ultrasound biomicroscopy (UBM), Potash *et al*² showed the presence of iris concavity and iridozonular contact in PDS eyes and proved, although only on four patients, that laser iridotomy can restore a normal iris configuration.

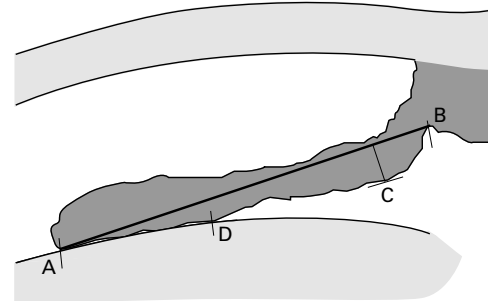


Figure 1 Iris deflection was measured by determining the maximum distance reached by the pigment epithelium (C) from a line joining the innermost point of the pigment epithelium in contact with the lens (A) with its outermost point at the iris root (B). Conventionally, the value was considered positive if the iris showed an anterior deflection (convexity) and negative in case of posterior deflection (concavity). Iridolenticular contact was quantified by measuring the distance between A and the outermost point of the pigment epithelium in contact with the lens (D).

The purpose of the present work was to study, by ultrasound biomicroscopy, the shape of the iris in PDS eyes, to compare it with the iris shape in age and refraction matched normal eyes and to assess the effects of laser iridotomy.

Materials and methods

Fifty eyes of 50 consecutive patients suffering from PDS³ were enrolled (group 1). In bilateral cases, one eye per subject was randomly chosen. No eye had undergone previous ocular surgery or laser and no medication affecting the pupillary diameter was in use. Fifteen eyes of 15 normal subjects were selected from our UBM database according to their age and refraction.

All eyes were examined with the ultrasound biomicroscope (UBM, Humphrey-Zeiss, San Leandro, CA, USA).^{4,5} The patient was lying supine under standard room illumination, fixating a target on the ceiling. All examinations were done by the same operator (MF) and the caliper present on the thermal printout was used for measurements by another operator (PB) unaware of the diagnosis.

The iris deflection (ID) and iridolenticular contact (ILC) were quantified as in Figure 1. ID was considered positive if the iris showed an anterior deflection (convexity) and negative in case of posterior deflection (concavity).

In PDS eyes, if ID was > 0 , the examination was repeated, asking the patient to fixate a target at the near point with the fellow eye.

All PDS patients with concave iris either in baseline conditions or under accommodation, were advised to undergo Nd:YAG laser iridotomy.

Department of Ophthalmology and Visual Sciences, University of Milano, H San Raffaele, Milan, Italy

R G Carassa
P Bettin
M Fiori
R Brancato

Correspondence to: Professor Rosario Brancato, Department of Ophthalmology and Visual Sciences, University of Milano, H S Raffaele, via Olgettina 60, I 20132 Milano, Italy.

Accepted for publication 27 August 1997

Table 1 Basic information on the population studied

	PDS (Group 1)	Normal (Group 2)	p Value
Eyes/subjects	50/50	15/15	
Race (W/B)	50/0	15/0	
Sex (M/F)	25/25	6/9	
Eye (R/L)	25/25	6/9	
Age (years)			
Mean (SD)	44.08 (11.25)	49.64 (15.88)	0.2623
(range)	(21 to 63)	(28 to 68)	
Refraction (dioptries)			
Mean (SD)	-3.38 (3.73)	-3.70 (5.84)	0.4024
(range)	(-15.5 to 0)	(-18.5 to 0)	

Table 2 Iris concavity in PDS and normal eyes

	PDS	Normals
Iris concavity (ID <0)		
Baseline	27/50 (54%)	2/15 (13%)
On accommodation	3/12 (25%)	
Total	30/50 (60%)	
Laser iridotomy	18/30 (60%)	None
Post-laser concavity	1/18 (5%)	

All treated eyes were re-examined by UBM 1–4 weeks after treatment.

Between group differences and within group changes were analysed using Mann-Whitney and paired Student's *t* tests, respectively.

Results

Population characteristics are given in Table 1. PDS and normal eyes did not differ significantly for age and refraction. Table 2 summarises the prevalence of iris concavity. In group 1, 12 of the 23 eyes with baseline ID >0 repeated UBM on accommodation. The effect on ID and ILC was not significant, but ID became <0 in three eyes and only the ID and ILC under accommodation were used for all study calculations. ID and ILC are set out in Table 3.

Treatment with Nd:YAG laser iridotomy was suggested to PDS patients with concave iris (Fig 2) and 18 out of 30 underwent the treatment. After laser iridotomy (Fig 3), the treated eyes had lower ID than normals ($p=0.0207$), and all but one displayed a flat iris (Fig 4); however, ILC was not significantly different. The UBM appearance of a normal iris is shown in Figure 5. The variables studied in the two groups are described by the box plots in Figures 6 and 7.

Discussion

The present study was meant to evaluate the iris configuration on a large sample of PDS eyes, comparing it with a group of matched normal eyes.

Table 3 Iris deflection (ID) and iridolenticular contact (ILC) (mm), in PDS and normal eyes

ID		ILC	
PDS (n=50)	Normal (n=15)	PDS	Normal
-0.15 (0.24) (-0.65 to +0.21)	+0.07 (0.10) (-0.21 to +0.16) $p=0.0207$	1.55 (0.78) (0.30 to 2.88)	1.07 (0.61) (0.30 to 2.50) $p=NS$
$p=0.0012$		$p=0.0304$	
pre-YAG (n=18)	post-YAG (n=18)	pre-YAG	post-YAG
-0.35 (0.18) (-0.61 to -0.05)	0.01 (0.06) (-0.12 to +0.17)	2.10 (0.65) (0.70 to 2.88)	0.93 (0.38) (0.40 to 1.75)
$p<0.0001$		$p<0.0001$	

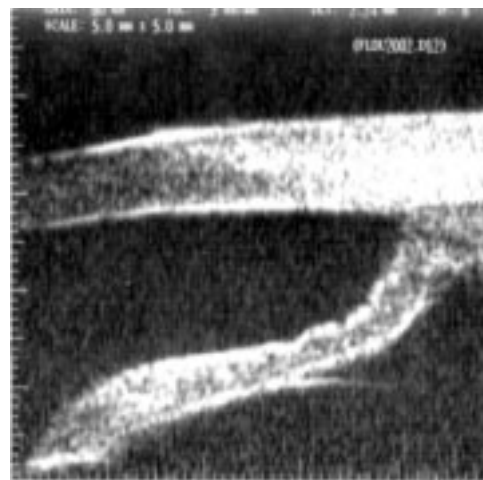


Figure 2 Ultrasound biomicroscopy image showing an evidently concave iris, before iridotomy.

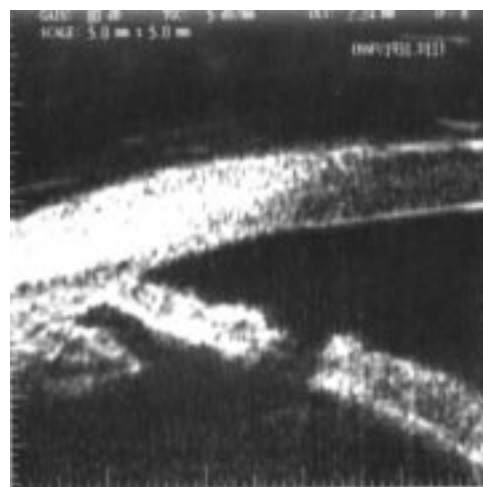


Figure 3 Ultrasound biomicroscopy image showing the iridotomy in the same eye as Figure 2.

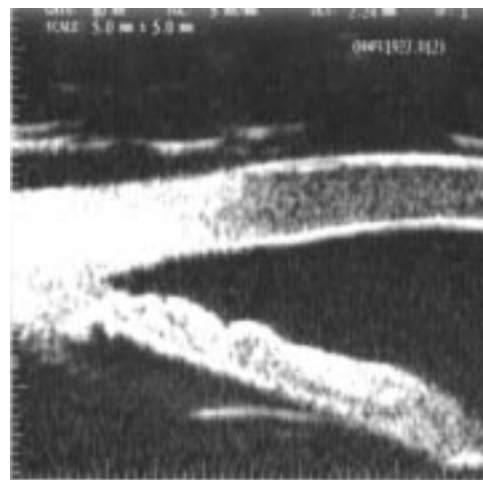

Figure 4 Same eye as Figures 2 and 3 after laser treatment: the iris is flat.

Using ultrasound biomicroscopy, we observed the presence of an iris concavity in 54% of the PDS eyes. This finding is consistent with the results reported by Potash *et al.*² in 16 eyes of 11 patients. In our study, we avoided artefacts such as iris flattening due to prevention of blinking⁶ by taking all images as quickly as

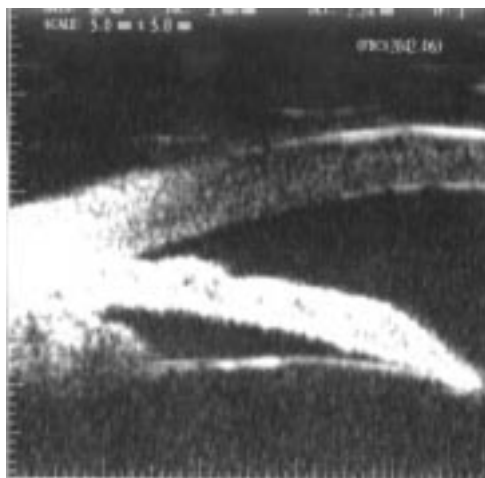

Figure 5 Ultrasound biomicroscopy appearance of a normal eye: the iris is slightly convex and iridolenticular contact is limited.

possible. We also considered the effects of accommodation, which is reported to induce a posterior bowing of the iris in PDS eyes,^{7,8} by repeating the examination under accommoda-

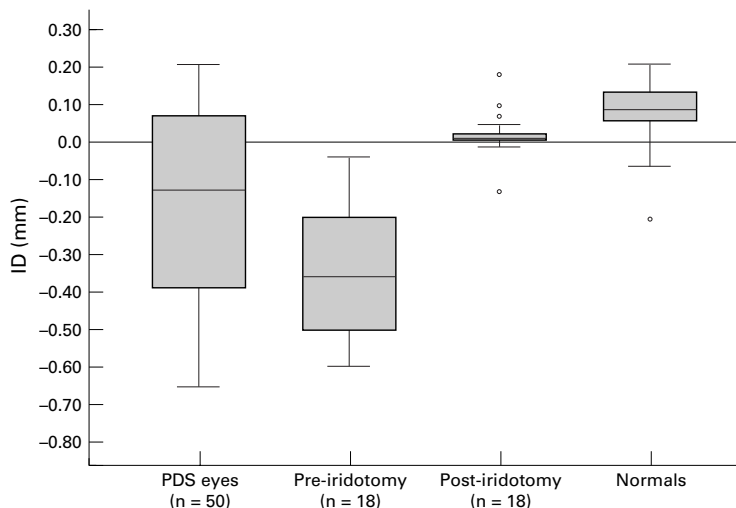


Figure 6 Box plot of the distribution of iris deflection (ID) in all PDS eyes, in PDS eyes before and after laser iridotomy, and in normal eyes.

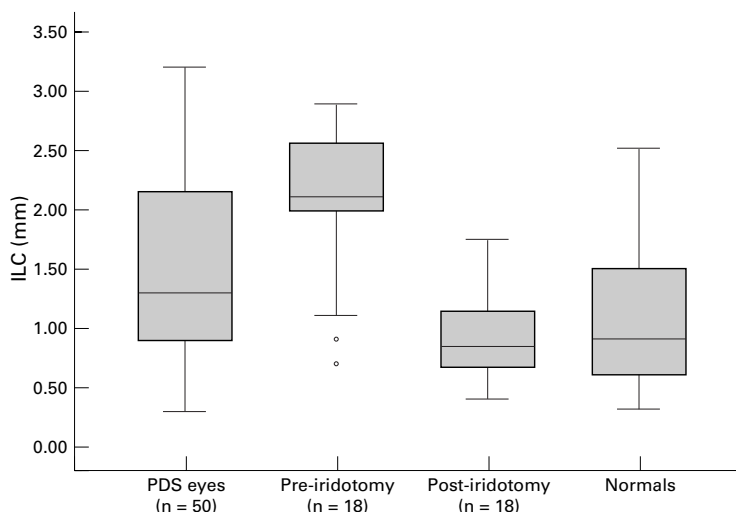


Figure 7 Box plot of the distribution of iridolenticular contact (ILC) in all PDS eyes, in PDS eyes before and after laser iridotomy, and in normal eyes.

tion when the iris was convex. This was done in only 12 out of 23 eyes due to poor collaboration, low vision in the fellow eye, or unwillingness to repeat the UBM analysis. Indeed, accommodation made the iris concave in three out of 12 non-concave eyes and in these cases only data under accommodation were used for calculations.

The iridolenticular contact was also analysed, proving to be significantly greater in PDS eyes than in normals, and this anatomical configuration could be considered a cause of reverse pupillary block. This finding confirms data obtained in another study on 10 PDS eyes.⁹ In order to make correct comparisons, we selected a control group matched for age and refraction with the PDS eyes studied.

Remarkably, among our normals, generally showing a slightly convex iris, two eyes displayed an iris concavity. ID was markedly negative in one case (-0.21 mm) characterised also by a large ILC (2.5 mm), while concavity was only borderline (ID = -0.02 mm) with a normal ILC (0.9 mm) in the second. Long term follow up will tell whether these eyes are prone to develop PDS over time. This is an original finding since Potash *et al*² found no concave iris in 300 control eyes, though these were not matched for age and refraction and belonged both to normal subjects and to patients with forms of glaucoma different from PDS (possible topical medication in use was not reported).

Eighteen patients with concave iris shape on UBM examination agreed to Nd:YAG laser iridotomy and post-treatment UBM examination showed that the iris concavity had been resolved in all eyes but one, in which a marked preoperative iris concavity was greatly reduced but not eliminated. Postoperatively, the treated eye group had a slightly flatter iris configuration than normal. The three eyes which had a concave iris under accommodation all underwent laser iridotomy and after the treatment their irises were flat both in baseline condition and under accommodation. One study⁷ on 10 eyes, observed concavity during accommodation in nine eyes and this was resolved by iridotomy in five cases.

In conclusion, UBM testing showed that approximately 60% of PDS eyes had posterior iris bowing either in baseline conditions or during accommodation. However, most normal eyes had a slightly convex iris but, interestingly, 13% had a posterior bowing. Nd:YAG laser iridotomy restored a normal iris configuration in all but one treated eye. A prospective randomised long term clinical study is nevertheless needed to clarify the real utility of iridotomy in preventing pigmentary glaucoma.

This paper was partly presented at the Annual ARVO Meeting, Ft Lauderdale, Florida, USA, 21–26 April 1996.

- 1 Karickhoff JR. Pigmentary dispersion syndrome and pigmentary glaucoma: a new mechanism concept, a new treatment and a new technique. *Ophthalmic Surg* 1992;23:269–77.
- 2 Potash SD, Tello C, Liebmann J, Ritch R. Ultrasound biomicroscopy in pigment dispersion syndrome. *Ophthalmology* 1994;101:332–9.

- 3 Richardson TM. Pigmentary glaucoma. In: Ritch R, Shields MB, Krupin T, eds. *The glaucomas*. Vol 2. St Louis: CV Mosby, 1989:981-5.
- 4 Pavlin CJ, Sherar MD, Foster FS. Subsurface ultrasound microscope imaging of the intact eye. *Ophthalmology* 1990; **97**:244-50.
- 5 Pavlin CJ, Harasiewicz K, Sherar MD, Stuart Foster F. Clinical use of ultrasound biomicroscopy. *Ophthalmology* 1991; **98**:287-95.
- 6 Liebmann JM, Tello C, Chew SJ, Cohen H, Ritch R. Prevention of blinking alters iris configuration in pigment dispersion syndrome and in normal eyes. *Ophthalmology* 1995; **102**:446-55.
- 7 Pavlin CJ, Macken P, Trope G, Harasiewicz K, Stuart Foster F. Accommodation and peripheral iridotomy in pigmentary glaucoma. *Ophthalmology* 1994; **101**:80.
- 8 Pavlin CJ, Harasiewicz K, Stuart Foster F. Posterior iris bowing in pigment dispersion syndrome caused by accommodation. *Am J Ophthalmol* 1994; **118**:114-6.
- 9 Liebmann JM, Tello C, Chew SJ, Ritch R. Iridolenticular contact and iris configuration in pigment dispersion syndrome. *Ophthalmology* 1994; **101**: 80.



Nd:YAG laser iridotomy in pigment dispersion syndrome: an ultrasound biomicroscopic study

Roberto G Carassa, Paolo Bettin, Marina Fiori, et al.

Br J Ophthalmol 1998 82: 150-153

doi: 10.1136/bjo.82.2.150

Updated information and services can be found at:

<http://bjo.bmj.com/content/82/2/150.full.html>

These include:

References

This article cites 7 articles

<http://bjo.bmj.com/content/82/2/150.full.html#ref-list-1>

Article cited in:

<http://bjo.bmj.com/content/82/2/150.full.html#related-urls>

Email alerting service

Receive free email alerts when new articles cite this article. Sign up in the box at the top right corner of the online article.

Notes

To request permissions go to:

<http://group.bmj.com/group/rights-licensing/permissions>

To order reprints go to:

<http://journals.bmj.com/cgi/reprintform>

To subscribe to BMJ go to:

<http://group.bmj.com/subscribe/>