

PERSPECTIVE

Albinism: modern molecular diagnosis

Susan M Carden, Raymond E Boissy, Pamela J Schoettker, William V Good

Albinism is no longer a clinical diagnosis. The past classification of albinism was predicated on phenotypic expression, but now molecular biology has defined the condition more accurately. With recent advances in molecular research, it is possible to diagnose many of the various albinism conditions on the basis of genetic causation. This article seeks to review the current state of knowledge of albinism and associated disorders of hypopigmentation.

The term albinism (*L albus*, white) encompasses genetically determined diseases that involve a disorder of the melanin system. Each condition of albinism is due to a genetic mutation on a different chromosome. The cutaneous hypopigmentation in albinism ranges from complete absence of melanin to a minimal reduction in skin and hair colour.¹ On the other hand, the ocular phenotypic characteristics of most types of albinism are rather constant and include reduced visual acuity, nystagmus, pale irides that transilluminate, hypopigmented fundi, hypoplastic foveae, and lack of stereopsis. Pleiotropy is exhibited by all types of albinism; single gene mutations have effects on different organ systems. The most obvious systems involved are the integument and the eyes, but the nervous, haematological, respiratory, and gastrointestinal systems may occasionally be affected.

Three major mechanisms exist by which mutations exert their effect on the pigmentation process. Firstly, abnormal pigmentation may occur early in the pathway of differentiation of melanocytes. Melanoblasts from the neural crest might be affected along with cells from the same lineage, such as occurs in Waardenberg and Waardenberg–Hirschsprung syndrome where the melanocyte fails to populate certain areas during embryogenesis. Secondly, a mutation can affect the melanin biochemical pathway causing a more specific abnormality. Oculocutaneous albinism type 1 (OCA 1) is an example of such a condition. Thirdly, the biogenesis of intracellular organelles of different cells may need a common set of genes and one gene mutation could affect seemingly unrelated cell types, including the melanocyte. Chediak–Higashi and Hermansky–Pudlak syndromes are disease examples.

Melanin physiology

Pigmented cells of the eye have one of two origins. The retinal pigment epithelium, the posterior and anterior iris epithelium, and the outer pigmented and inner non-pigmented (so called) ciliary epithelium are all derived from the neuroectoderm of the primitive forebrain. On the other hand, melanocytes in the iris stroma, ciliary stroma, and choroid are derived from the neural crest. Melanoblasts from the neural crest migrate to the skin, brain, inner ear, and uveal tract to develop into melanocytes.^{2–4}

The biochemical pathway converting tyrosine to melanin is shown in Figure 1. The pigment granule (melanosome) is an intracellular organelle produced by melano-

cytes and into which melanin is confined. In the skin, the melanosome is later transferred from the melanocyte to the surrounding keratinocytes. The melanosome precursor arises from the *smooth* endoplasmic reticulum. Tyrosinase and other enzymes regulating melanin synthesis are produced in the *rough* endoplasmic reticulum, matured in the Golgi apparatus, and translocated to the melanosome where melanin biosynthesis occurs.

Tyrosinase is a copper containing, monophenol, mono-oxygenase enzyme that has long been known to have a critical role in melanogenesis.⁵ It catalyses three reactions in the melanin pathway. The rate limiting step is the hydroxylation of tyrosine into dihydroxyphenylalanine (DOPA) by tyrosinase, but tyrosinase does not act alone. There is a melanogenic complex in the melanocyte, functioning as an integrated unit, which consists of tyrosinase, tyrosinase related protein 1 (TRP-1), TRP-2, lysosome associated membrane protein 1, and melanocyte stimulating hormone receptors.⁶ TRP-1 and TRP-2 have multiple functions, one of which is to stabilise tyrosinase activity.^{5,7}

A putative tyrosinase transporter is situated in the limiting membrane of the pre-melanosome. The *P* polypeptide is the product of the pink eye dilution locus (named from the mouse) and the counterpart on human chromosome 15 (15q11.2-13). It has been proposed,⁸ and refuted,⁹ that the *P* protein transports tyrosine into the melanosome.

Classification

See Table 1.

In the past, the classification of albinism has had a dichotomous foundation, based on whether the phenotype was oculocutaneous or simply ocular. Recently, investigations have become more sophisticated and some cases have been reclassified. For example, one third of cases initially labelled as OCA 2 can be reclassified as OCA 1B on the basis of molecular genetic studies.¹⁰ OCA 1 and OCA 2 were originally separated on the basis of the hair bulb test, which is now considered unreliable. We can now review the molecular classification of various albino conditions.

Oculocutaneous albinism

“Oculocutaneous albinism” refers to a heterogeneous group of autosomal recessive disorders in which melanin is reduced or absent. Pale skin and an increased risk of skin cancer, together with the previously mentioned ocular phenotype, are present.

OCA 1

OCA 1 results from mutations in the tyrosinase gene affecting its synthesis and/or catalytic activity.¹¹ Three steps in melanin biosynthesis are catalysed by tyrosinase.¹² OCA 1 is further divided into OCA 1A and OCA 1B. Different types of mutations of the gene for tyrosinase explain the two types of OCA 1. The gene position is on chromosome

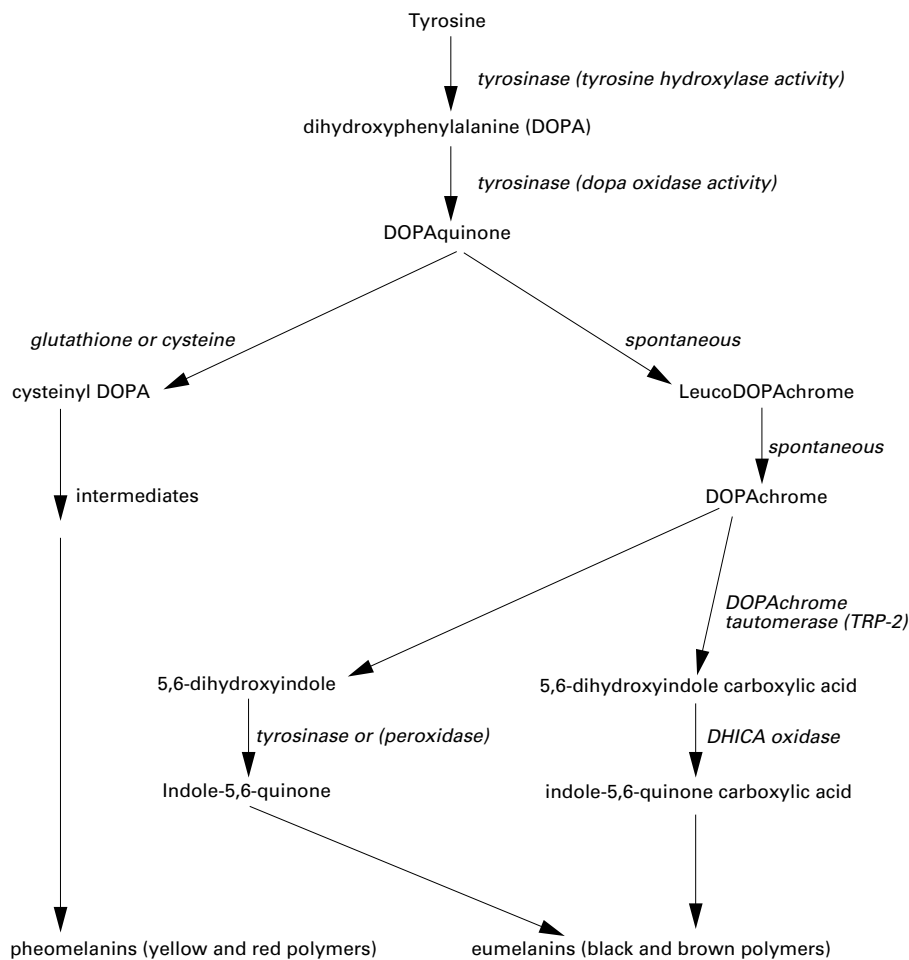


Figure 1 Biosynthesis of melanin.

11 (11q14-21).¹³ OCA 1A is the most severe form of OCA. Tyrosinase activity is completely absent and there is no melanin in the skin or eyes (fig 2). Visual acuity is decreased to 20/400.¹¹ Nonsense, frameshift, and missense mutations account for OCA 1A. OCA 1B has a greatly diminished, but not absent, level of tyrosinase. OCA 1B individuals may exhibit an increase in skin, hair, and eye pigment with age and do tan with sun exposure (Fig 2).

Fifty five mutations of the tyrosinase (TYR) gene have been found to date.¹⁴

The phenotype of OCA 1B is indistinguishable from OCA 1A at birth. Tyrosinase activity modulates pigmentation and causes a darker skinned phenotype during childhood.¹¹ OCA 1B was originally described in the Amish people,^{15 16} who are highly inbred. The condition was formerly referred to as “yellow mutant.”

Table 1 Conditions of albinism

Type of albinism	Gene position
OCA 1	11q14-21
OCA 1A	
OCA 1B	
OCA 2	15q11-13
OCA 3	9p23
OA 1	Xp22.3-22.2
OA 2	
Chediak-Higashi	1q42-44
Hermansky-Pudlak	10q23.1-23.3
Contiguous gene syndromes	
Prader-Willi (OCA 2)	15q11-13
Angelman (OCA 2)	15q11-13
Kallmann syndrome (OA 1)	Xp22.3-22.4
Late onset sensorineural deafness (OA 1)	Xp22
X linked ichthyosis and Kallmann syndrome (OA 1)	Xp22
Microphthalmia and linear skin defects (OA 1)	Xp22
Aicardi	Xp22
Goltz	Xp22
Waardenburg 1	2q35-q37.3
Waardenburg 2	3p12
Waardenburg 3	2q35-q37.3
Waardenburg-Hirschsprung	13q22

COMPOUND HETEROZYGOTES

OCA 1A/1B compound heterozygotes share phenotypic attributes of OCA 1A and 1B. OCA 1 phenotypes can result from homozygosity or compound heterozygosity of the alleles. In white people there is no one mutant TYR allele that is responsible for most of the mutations. Thus, if the parents are not related then the patient will probably be a compound heterozygote.¹⁴

An OCA 1A patient must have two type OCA 1A alleles; an OCA 1B can have two type OCA 1B alleles or one type 1A and one type 1B allele. This explains why the phenotype of OCA 1B has such a broad spectrum. Even a small amount of tyrosinase activity will alter the phenotypic expression.¹⁴

OCA 2

OCA 2 has a prevalence of 1:15 000. Patients with OCA 2 were formerly referred to as “tyrosinase positive” oculocutaneous albinos because the mutation causing OCA 2 does not affect the tyrosinase gene, instead affecting the P polypeptide.^{8 17 18} The disease is also autosomal recessive, but coded on a different chromosome from OCA 1—that

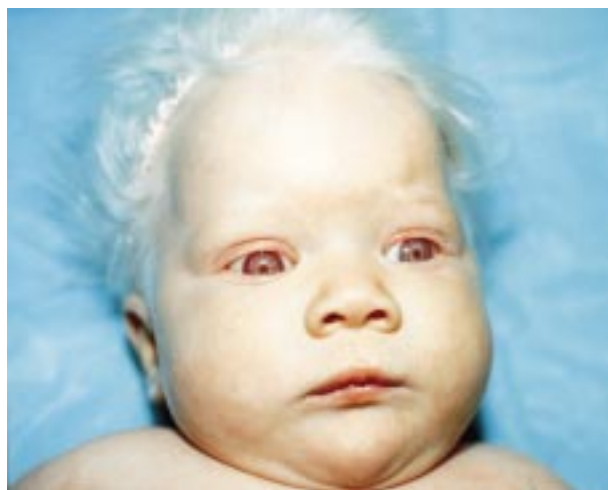

Figure 2 Photograph of child with oculocutaneous albinism 1A.

is, 15q11-13.¹⁰ Patients with OCA 2 generally are not as severely affected as those with OCA 1, but the phenotypic spectrum is broad, ranging from virtually no apparent pigmentation to nearly normal pigmentation.¹ Pigmentation is absent or poor at birth and develops during childhood. Vision in OCA 2 improves with age. In young childhood, it may be low (20/100–20/200) but with accumulation of pigment vision improves (20/40–20/70). Changes in acuity can occur up to adolescence, but whether improvement is specifically related to pigmentation is unknown.¹⁰ That delayed maturation of vision may occur in albinism is widely accepted.^{19 20} The mechanism of delay in albinism is unknown.

OCA 3

In OCA 1, the gene mutation affects tyrosinase and, in OCA 2, the mutation affects the gene for *P* protein. OCA 3 is caused by a defect in tyrosine related protein 1 (TRP-1).²¹ TRP-1 is the product of the *brown* locus in the mouse. A mutant allele in the mouse at that position causes the fur to be brown rather than black.²² The human gene coding for TRP-1 is on the short arm of chromosome 9 (9p23).²³ The phenotypic features of OCA 3 in black patients are light brown hair, light brown skin, blue/brown irides, nystagmus, and diminished visual acuity (Fig 3). OCA 3 has not been detected in white or Asian races, perhaps because the phenotype may not be obvious. It is autosomal recessive. Although the function of TRP-1 in human melanogenesis is not fully determined, it acts as a regulatory protein in the production of black melanin. Its

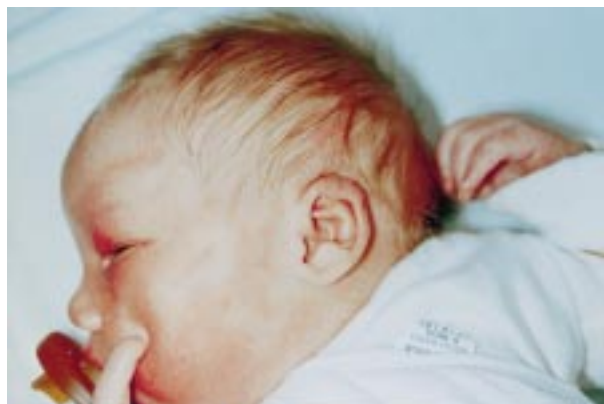

Figure 3 Photograph of baby with oculocutaneous albinism 3. Note brown colour of hair, a characteristic of this type of albinism. OCA 3 has only been reported in black patients.

mutation results in the dysregulation of tyrosinase activity and the synthesis of brown rather than black melanin.²¹ In mice, TRP-1 catalytically functions as a dihydroxyindole carboxylic acid (DHICA) oxidase^{24 25} and may aid in stabilisation of tyrosinase and other melanosomal enzymatic processes.⁷ There may be an interaction with TRP-1 and tyrosinase to affect tyrosinase hydroxylase activity. TRP-1 may also upregulate the availability of L-DOPA during the onset of melanogenesis.^{26 27}

Ocular albinism

OCULAR ALBINISM 1

X linked recessive ocular albinism (Nettleship–Falls type) is categorised as ocular albinism type 1 (OA 1). It has a prevalence of 1:50 000 in the United States.¹¹ The OA 1 locus is 5p22-3.²⁸⁻³² Charles *et al*³² looked at 72 cases of OA 1 and found nystagmus (in all cases except one), reduced visual acuity (to 6/36 in most cases), refractive errors (especially astigmatism), fundus hypopigmentation, lack of foveal reflex, strabismus, iris translucency in all cases, and posterior embryotoxon in 30% (implying some dysgenesis of the anterior segment). The ocular phenotype of OA 1 is similar to OCA 1 and OCA 2. Affected patients have a normal skin phenotype, although it may be paler than that of first degree relatives.³³

Patients with OA 1 may initially be diagnosed with congenital motor nystagmus.³² Examination of the mother usually shows signs of a carrier state—mud splattered fundus with hyperpigmented streaks in the periphery and marked iris translucency.³² Affected males exhibit the complete phenotype while female carriers have retinal and cutaneous signs.³³ In particular, there is a mosaic pattern of pigmentation in the female carriers, in keeping with the hypothesis of X inactivation (lyonisation).³³ It is, however, more distinct in the retinal periphery. Mild peripheral retinal changes are not definite indicators of carrier status, as 11% of age matched controls have similar changes.³⁴ On the other hand, definite changes in the peripheral retina identify at risk females as carriers quite sensitively.³⁴

The pathogenesis of OA 1 is unknown. The presence of skin macromelanosomes helps diagnose OA 1 and they are seen in most affected adult males,³² but there is uncertainty about their presence in infants.^{35 36} One Australian family showed two males with OA 1 and one female carrier, none of whom had macromelanosomes,³⁶ raising the possibility of different types of OA 1.

Macromelanosomes are formed putatively when premelanosomes do not separate from the endoplasmic reticulum–Golgi system. The accumulating proteins cause distension of the organelle.³³ The OA 1 gene product could be a membrane protein necessary for the maturation of melanosomes.³⁷ Skin biopsy for macromelanosomes also aids in determining the carrier state.³⁴ Mutation in the OA 1 gene in Xp22.3 accounts for a third of the X linked albinism, suggesting that different gene defects on the X chromosome could cause the same phenotype—that is, locus heterogeneity could exist.³⁷

AUTOSOMAL RECESSIVE OCULAR ALBINISM?

Patients diagnosed with autosomal recessive ocular albinism (AROA) have appeared similar to mild cases of OCA 1 or OCA 2.³⁸ However, genetic analysis has shown that some have abnormalities of the tyrosinase gene and so are OCA 1, while others have abnormalities of the *P* gene, thus categorising them as OCA 2. In fact, AROA may not be a distinct entity: 14% of those previously diagnosed with AROA have an abnormality of the tyrosinase gene, making them OCA 1 (chromosome 11); 36% have an abnormality of the *P* gene, relabelling them OCA 2 (chromosome 15);

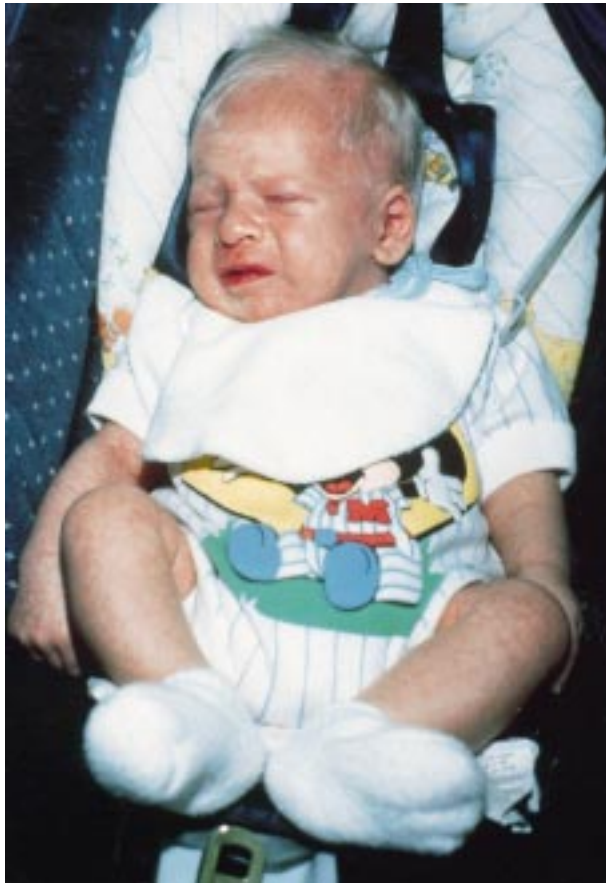

Figure 4 Photograph of child with Chediak-Higashi syndrome. Note colour of hair.

50% have neither an abnormality of the tyrosinase gene nor the *P* gene.³⁸

Two patients labelled as AROA had one OCA 1 mutant allele and one allele that had a polymorphism coding for a functionally normal, but heat sensitive, tyrosinase.³⁹ The patients, technically, were compound heterozygotes for OCA 1.³⁸ Meanwhile, patients who are homozygous for the heat sensitive tyrosinase polymorphism are phenotypically normal.³⁸

Heat sensitive tyrosinase has approximately one quarter of the activity of normal tyrosinase at 37°C and improved activity at lower temperatures.³⁸ The temperature of the fetus is high so the heat sensitive tyrosinase is thought to have low activity. Postnatally the skin is cooler. There may be increased pigmentation as a result of a higher activity of the heat sensitive tyrosinase. The skin and hair then achieve almost normal pigmentation. The eye is warmer than the skin and, possibly as a consequence, does not develop additional pigmentation.³⁸

Conditions associated with albinism: close linkage

CONDITIONS LINKED TO OCA 2

Prader-Willi syndrome and Angelman syndrome

Prader-Willi syndrome (PWS) and Angelman syndrome (AS) are both due to a microdeletion on the human chromosome 15q11-13. The *P* gene defective in OCA 2 is also coded in the region q11-13 on chromosome 15, adjacent to the area commonly deleted in PWS or AS syndrome.⁴⁰ One per cent of patients with PWS or AS have OCA 2.¹⁴ Therefore, if a patient has a deletion of one allele, as in Prader-Willi syndrome, and the fellow allele has a mutation for OCA 2, the patients will be albino.^{10 11}

Angelman syndrome is characterised by mental retardation and absence of speech. Affected patients have a happy

disposition, bursts of laughter, hyperactive behaviour, microcephaly, brachycephaly, tongue protrusion, widely spaced teeth, wide based gait, and stiff movements.⁴¹ PWS is also a multisystem disorder, characterised by obesity, hypotonia, hypogonadism, intellectual impairment, short stature, and dysmorphic facial features.⁴²⁻⁴⁵

Both AS and PWS are caused by the same, cytogenetically indistinguishable, chromosomal deletion. Yet, two separate phenotypes occur because of the phenomenon of *genomic imprinting*. If the microdeletion of 15q11-13 occurs on the paternally derived chromosome, then PWS occurs. Maternally derived chromosomal deletions of 15q11-13 cause AS. A difference in the *imprint* of the chromosome occurs, depending on whether it is paternal or maternal in origin,⁴⁶ even though both chromosomes have the same DNA sequence. The cause of imprinting is unknown. One theory holds that genes from the mother may differ in their level of methylation from paternally inherited genes. This may influence the level of expression of the genes. Highly methylated genes seem to be less likely to be transcribed into messenger RNA.⁴⁶

CONDITIONS LINKED TO OA 1

Many patients with contiguous gene syndromes involving the Xp22.3 region have been described and have albino phenotypes if the deleted region includes the OA 1 gene. X linked ichthyosis, Kallmann syndrome (hypogonadotropic hypogonadism with anosmia due to olfactory lobe agenesis)⁴⁷ and X linked recessive chondrodysplasia punctata have been linked to the OA 1 gene.⁴⁸

A patient has been described with impaired visual acuity, nystagmus, hypopigmentation of the retina, iris translucency, ichthyosis, hypogonadism, anosmia, and neurological abnormalities.⁴⁹ A contiguous gene syndrome, which includes three X linked recessive disorders—that is, X linked ocular albinism, X linked ichthyosis, and Kallmann syndrome, is proposed.⁴⁹

X linked ocular albinism and late onset sensorineural deafness (OASD) causes visual impairment and deafness by middle age.⁵⁰ OA 1 and OASD are caused either by allelic variants or by contiguous gene defects. OASD differs from X linked albinism deafness syndrome by the presence of patchy, cutaneous hypopigmentation and hyperpigmentation and the absence of significant eye involvement in the latter disorder. These two conditions may be pleiotropic manifestations of the OA 1 gene or a result of a contiguous gene defects.⁵⁰

The loci for OA 1 and “microphthalmia with linear skin defects” (MLS) are closely situated on the X chromosome.⁵¹ MLS is characterised by microphthalmia, corneal opacities, and patches of erythematous skin in the head and neck in female patients.

A review of 16 patients with a deletion of the terminal end of the Xp arm, including Xp22 (Xpter-Xp22), was undertaken by Wapenaar *et al.*⁵¹ Two male patients had OA 1 based on the presence of nystagmus, iris translucency, pale fundi, and poor visual acuity. One female patient has areas of hyperpigmentation and hypopigmentation in her fundus, indicating that she might be a carrier of OA 1. MLS features were found in eight of nine female patients. When other features in the female patients were looked for, chorioretinal abnormalities, agenesis of the corpus callosum, costovertebral abnormalities, mental retardation, and seizures were found. These findings overlap with two other conditions—Aicardi and Goltz syndromes. Both of the syndromes are X linked dominant and lethal in males. Aicardi syndrome consists of retinal lacunae, absence of the corpus callosum, and seizures. Goltz syndrome is characterised by microphthalmia, focal dermal hypoplasia, and skeletal abnormalities. It is hypothesised that these condi-

tions could be caused by a defect in the same gene.⁵¹ The pattern of inactivation of genes could alter the phenotype and promote one or another various phenotypes (Aicardi, Goltz, or MLS). It is interesting that patients with very large deletions of the X chromosome, including the Xp22 region, did not show the MLS syndrome. It is possible that the X chromosome, with the large deletion, is preferentially inactivated (that is, not randomly), leaving the normal X chromosome active.⁵¹

Conditions associated with albinism and not due to close linkage

CHEDIAK–HIGASHI SYNDROME

Chediak–Higashi syndrome (CHS) is an autosomal recessive disease characterised by oculocutaneous albinism and severe immunological deficiency. An increased susceptibility to infections and deficient natural killer cell activity occurs. Giant intracytoplasmic inclusion bodies are seen in most granulated cells, granulocytes, lymphocytes, mast cells, histiocytes, platelets, melanocytes, Schwann cells, neurons, fibroblasts, and renal tubular epithelium.⁵² CHS has recently been mapped to chromosome 1q42.1–q42.2⁵³ and the gene has been cloned and sequenced,⁵⁴ but the CHS gene product is unknown. Patients have defective vesicular transport to and from the lysosome and late endosome.⁵⁵ Without a bone marrow transplant, CHS patients die during childhood from organ infiltration or haemorrhage. The oldest documented patient with CHS is aged 39 years.⁵⁶ Seizures, mental retardation, cranial nerve palsies, clumsiness, gait abnormalities, and peripheral neuropathy develop with time.⁵²

Giant inclusions of cells are derived from lysosomes or secretory granules. CHS melanocytes are characterised by the presence of giant melanosomes.⁵⁷ It is likely that CHS is caused by a mutation in a gene for a protein that is necessary for the normal functioning of intracellular organelles, including melanosomes, and lysosomes may develop from a similar precursor.⁵⁸

Thus, CHS patients have hypopigmentation due to *abnormal* melanosomes; the hypopigmentation is caused by a different mechanism from other albino disorders. The presence of giant melanosomes causes dilution of pigmentation, producing hypopigmentation of the hair, skin, and ocular fundi.⁵⁷ The hair in CHS appears a metallic frosted grey colour (Fig 4).⁵⁹

Cats with CHS have misrouting of the optic nerve fibres at the chiasm, disorganisation of the dorsal lateral geniculate nuclei, and an abnormality of the superior olivary complex. CHS cats, other albino cats, and human albinos have anomalies in the brain stem auditory structures involved in transmitting information to the contralateral portion of the brain stem.^{59–64} The fact that CHS cats have neurological abnormalities similar to other albino subjects suggests that the abnormal pigmentation itself may be the cause.

HERMANSKY–PUDLAK SYNDROME

The Hermansky–Pudlak syndrome (HPS) is an autosomal recessive inherited disease characterised by albinism, a bleeding diathesis due to storage pool deficiency of platelets, and a lysosomal caeroid storage disorder. Three organelles are affected—melanosomes, platelet dense bodies, and lysosomes.⁶⁵ Late complications of HPS include interstitial pulmonary fibrosis, inflammatory bowel disease, renal failure, and cardiomyopathy due to caeroid-like material deposition.⁶⁶ Pulmonary fibrosis is the most common cause of death, but haemorrhage and granulomatous colitis can be fatal.^{67 68} The carrier frequency in Puerto Rico is estimated at 1:21. HPS represents the most frequent type of albinism in the Puerto Rican population,

with a frequency of 1:1800.⁶⁹ Five out of six albinos in Puerto Rico have HPS.⁷⁰ It is thought that a founder effect may be operating. The original mutation may have occurred after attacks by mutant British soldiers in 1595, Dutch attackers in 1625, the presence of aboriginal tribes, or slave traders.⁷⁰ HPS is also over-represented in an isolated Swiss village.⁶⁵

The HPS gene is localised to 10q23.1–q23.3^{65 71} and has recently been cloned.⁷² Cutaneous pigmentation varies from none to almost normal, with the majority developing ocular signs of nystagmus, strabismus, reduced acuity, foveal hypoplasia, and decreased retinal pigment.⁶⁶ The melanosomes are decreased in number, have a reduced amount of melanin, and have an abnormal morphology.⁶⁵ Absence of dense bodies in platelets (these are storage granules for adenine nucleotides and other compounds for secondary aggregation) predispose to bleeding and bruising.⁷¹ It is not known how all the components of HPS are related.

Congenital hypopigmentation resembling albinism

WAARDENBURG SYNDROME

Waardenburg syndrome is characterised by heterochromic irides and congenital hypopigmentation of the remainder of the uveal tract. Other findings include lateral displacement of the medial canthi, dystopia of the lacrimal puncta, blepharophimosis, synophrys, white forelock, pale skin, premature greying, defective pigmentation, congenital deafness, and a broad root of the nose. There are various genetic forms of Waardenburg syndrome that express subtle phenotype distinctions.⁷³ Waardenburg syndrome types one and three result from mutations in the PAX 3 gene encoding a transcription factor and localised to chromosome 2q35–q37.3.^{74 75} Waardenburg syndrome type 2 results from mutations in the MITF (microphthalmia transcription factor) located at 3p12.^{76 77} A fourth type, Waardenburg–Hirschsprung disease, results from mutations in the ENDRB gene at 13q22 that encodes a G protein coupled plasma membrane receptor that can bind endothelin 1, 2, and 3. Patients present primarily with congenital aganglionic megacolon, resulting from the absence of neural crest derived Meissner's and Auerbach's autonomic plexuses in the intestinal smooth muscle wall. Hirschsprung syndrome is also associated with hypopigmentation of varying extent, heterochromic irides, and deafness. The hypopigmentation is thought to result from the inability of a subset of neural crest cells—that is, melanoblasts and enteric ganglions, to reach their target site during embryogenesis.^{73 78–80}

Conditions of possible relevance

CONGENITAL MOTOR NYSTAGMUS

Congenital motor nystagmus (CMN) is diagnosed by the presence of nystagmus at birth, or shortly thereafter, and the absence of any obvious anterior visual pathway disease. Anecdotally, CMN may occur in children more lightly pigmented than first degree relatives.^{32 81} Kriss *et al*⁸² studied vision evoked potentials looking for signs of abnormal decussations of the visual pathways in patients with CMN, and found none. However, Shiono *et al*⁸¹ found that some males diagnosed with CMN, in fact, have XLOA.

Mechanisms of impaired vision in albinism

Mechanisms of vision impairment in albinism are multifactorial and undoubtedly related to pigmentation. In foveal hypoplasia, as occurs in albinism, the central cones are spaced apart and so the central visual acuity is decreased while the peripheral visual acuity is normal.³² Refractive errors are more common, especially astigmatism.^{32 81} Some degree of amblyopia may, thus, be

present. It is noted that the refractive error in many infants is due to poor visual acuity rather than its course. The albino has a high risk of strabismus.³²⁻⁶⁶ Stereopsis is absent as a result of misrouting of the optic pathways. Intraocular light scatter will also degrade the retinal image.⁸³

Neurological ramifications of disordered pigmentation

Melanin plays an important role in the developing visual system; a critical level of pigment production is required for the normal development of visual pathways.² Lower levels lead to a stereotypic set of defects of neuronal migration, vision impairment, nystagmus, and strabismus.

An increased number of decussating axons at the chiasm is a regular feature of all types of albinism. At the cellular level, decussation is caused by a complex interaction between ganglion cell and optic chiasm embryonic neurons. Embryonic neurons of the optic chiasm apparently control the orientation and decussation of ganglion cells via the expression of surface cell molecules, L1 and CD44.⁸⁴ When monoclonal antibody and complement are used to ablate embryonic chiasmal neurons, the chiasm does not form and the retinal ganglion cells are truncated at the position where they would be expected to enter the chiasm.⁸⁵

The level of pigmentation and the amount of tyrosinase activity is related to the amount of ipsilateral innervation.⁸⁶ In some cases, the tyrosinase gene may play a role in controlling ganglion cell growth. An elegant study performed by Jeffery *et al*² found that introduction of a tyrosinase gene in transgenic mice corrected the abnormal pathway that occurred in the albino mice strain investigated. The amount of tyrosinase activity appears closely related to the number of uncrossed optic chiasm axons, adding further evidence to the theory that some factor in the retinal axon development plays a pivotal role in the direction of ganglionic axons in the regions of optic chiasmata.⁸⁶ The manner in which albinism affects ganglionic axon guidance through the optic chiasm is controlled at the level of the retina and not at the level of the chiasm. Albinism changes, at the chiasm, the number of ganglion cells specified to respond to cues for decussating. Albinism does not alter signals from the chiasm to the ganglion axons.⁸⁷

Steps in assessing an albino suspect

In order to define more precisely the type of albinism a patient has, the following steps can be undertaken.

(1) In assessing the phenotype of the patient, if the newborn, and especially the adult, completely lacks pigment in the skin and hair, the individual probably has OCA 1A. If minimal pigment is apparent, the individual could be classified as either OCA 1B, OCA 2, or OCA 3. If the individual has silvery coloured hair and neutrophils with large inclusions, as observed by light microscopy of a blood smear, the diagnosis would be Chediak-Higashi syndrome. If the individual has moderate to minimal hypopigmentation and exhibits reduced blood clotting upon testing, the diagnosis would be Hermansky-Pudlak syndrome.

(2) A hair bulb assay could be performed to identify OCA 1A more definitely. In this test, hair bulbs are plucked from the scalp and the catalytic activity of tyrosinase is determined either (a) by a histochemical procedure in which the samples are incubated in the substrate DOPA and the consequential induction of melanin determined by visual inspection,⁸⁸ or (b) by a radioactive biochemical assay in which the samples are incubated with a radiolabelled tyrosine precursor and the amount of radiolabel released after enzymatic conversion quantified spectrophotometrically.⁸⁹ A negative result with either

assay indicates OCA 1A, a positive result indicates OCA 1B, OCA 2, or OCA 3. OA 1 will also be positive.

(3) To differentiate between OCA 1B, OCA 2, OCA 3, sequence analysis of the genes encoding tyrosinase, *P* protein, and TRP-1, respectively, must be performed. This is not a routine laboratory procedure and currently can be done in only a few research laboratories. Alternatively, a 5–8 mm shave skin biopsy can be obtained from the patient. Cultures of melanocytes can be established in order to assess the expression and/or function of tyrosinase, *P* protein, and TRP-1. Again, this is not a routine laboratory procedure and currently can be done in only a few research laboratories.

(4) If X linked ocular albinism (OA 1) is suspected after examining the ocular phenotype, female family members need to be assessed for the presence of a mud splattered fundus, indicating carrier status. A skin biopsy can be sent to a histology laboratory to look for macromelanosomes in the epidermis. A few laboratories will attempt to sequence the gene, but that mutation has not been found to account for all patients.

We thank Dr J Nordlund, Department of Dermatology, University of Cincinnati, Cincinnati, Ohio, USA.

SUSAN M CARDEN

Royal Children's Hospital, Melbourne, Australia and Smith-Kettlewell Eye Research Institute, San Francisco, California, USA.

RAYMOND E BOISSY

Department of Dermatology, University of Cincinnati Medical Center, Cincinnati, Ohio, USA

PAMELA J SCHOETTKER

Department of Ophthalmology, University of Cincinnati Medical Center, Cincinnati, Ohio, USA

WILLIAM V GOOD

Smith-Kettlewell Eye Research Institute, 2232 Webster Street, San Francisco, CA 94115, USA

Correspondence to: William V Good, MD.

- Oetting WS, Brilliant MH, King RA. The clinical spectrum of albinism in humans. *Mol Med Today* 1996;2:330–5.
- Jeffery G, Schutz G, Montoliu L. Correction of abnormal retinal pathways found with albinism by introduction of a functional tyrosinase gene in transgenic mice. *Dev Biol* 1994;166:460–4.
- Boissy RE, Nordlund JJ. Biology of melanocytes. In: Arndt KA, LeBoit PE, Robinson JK, Wintroub BU, eds. *Cutaneous medicine and surgery: an integrated program in dermatology*. Philadelphia: Saunders, 1995:1203–9.
- Hogan MJ, Alvarado JA, Weddell JE. *Histology of the human eye; an atlas and textbook*. Philadelphia: Saunders, 1971:38–40.
- Zhao H, Boissy RE. Distinguishing between the catalytic potential and apparent expression of tyrosinase activities. *Am J Med Sci* 1994;308:322–30.
- Orlow SJ, Zhou BK, Chakraborty AK, *et al*. High molecular-weight forms of tyrosinase and the tyrosinase-related proteins: evidence for a melanogenic complex. *J Invest Dermatol* 1994;103:196–201.
- Winder AJ, Kobayashi T, Tsukamoto K, *et al*. The tyrosinase gene family: interactions of melanogenic proteins to regulate melanogenesis. *Cell Mol Biol Res* 1994;40:613–26.
- Rinчик EM, Bultman SJ, Horsthemke B, *et al*. A gene for the mouse pink-eyed dilution locus and for human type II oculocutaneous albinism. *Nature* 1993;361:72–6.
- Gahl WA, Potterf B, Durham-Pierre D, Brilliant MH, Hearing VJ. Melanosomal tyrosine transport in normal and pink-eyed dilution murine melanocytes. *Pigment Cell Res* 1995;8:229–33.
- Spritz RA. Molecular genetics of oculocutaneous albinism. *Semin Dermatol* 1993;12:167–72.
- King RA, Hearing VJ, Creel DJ, Oetting WS. Albinism. In: Scriver CR, Beaudet AL, Sly WS, Valle D, eds. *The metabolic and molecular bases of inherited disease*. 7th ed. Vol II. New York: McGraw Hill, 1995:4353–92.
- Hearing VJ, Tsukamoto K. Enzymatic control of pigmentation in mammals. *FASEB J* 1991;5:2902–9.
- Hu F, Hanifin JM, Prescott GH, Tongue AC. Yellow mutant albinism: cytochemical, ultrastructural, and genetic characterization suggesting multiple allelism. *Am J Hum Genet* 1980;32:387–95.
- Spritz RA. Molecular genetics of oculocutaneous albinism. *Hum Mol Genet* 1994;3:1469–75.
- Nance WE, Jackson CE, Witkop CJ Jr. Amish albinism: a distinctive autosomal recessive phenotype. *Am J Hum Genet* 1970;22:579–86.
- Giebel LB, Spritz RA. The molecular basis of type I (tyrosinase-deficient) human oculocutaneous albinism. *Pigment Cell Res* 1992;Suppl 2:101–6.
- Ramsay M, Colman MA, Steven G, *et al*. The tyrosinase-positive oculocutaneous albinism locus maps to chromosome 15q11.2-q12. *Am J Hum Genet* 1992;51:879–84.

- 18 Lee ST, Nicholls RD, Bunday S, *et al*. Mutations in the P gene in oculocutaneous albinism, ocular albinism, and Prader-Willi syndrome plus albinism. *N Engl J Med* 1994;330:529-34.
- 19 Hoyt CS, Good WV. Visual factors in developmental delay and neurological disorders in infants. In: Simons K, ed. *Infant vision: basic and clinical research*. Committee on Vision, Commission on Behavioral and Social Sciences and Education, National Research Council. New York: Oxford University Press, 1993:505-12.
- 20 Tresidder J, Fielder AR, Nicholson J. Delayed visual maturation: ophthalmic and neurodevelopmental aspects. *Dev Med Child Neurol* 1990;32:872-81.
- 21 Boissy RE, Zhou H, Oetting WS, *et al*. Mutation in and lack of expression of tyrosinase-related protein-1 (TRP-1) in melanocytes from an individual with brown oculo-cutaneous albinism: a new subtype of albinism classified as "OCA3". *Am J Hum Genet* 1996;58:1145-56.
- 22 Jackson JJ. A cDNA encoding tyrosinase-related protein maps to the brown locus in mice. *Proc Natl Acad Sci USA* 1988;85:4392-6.
- 23 Murty VV, Bouchard B, Mathew S, Vijayasaradhi S, Houghton AN. Assignment of the human TYRP (brown) locus to chromosome region 9p23 by nonradioactive in situ hybridization. *Genomics* 1992;13:227-9.
- 24 Jimenez-Cervantes C, Solano F, Kobayashi T, *et al*. A new enzymatic function in the melanogenic pathway: the DHICA oxidase activity of tyrosinase related protein-1 (TRP1). *J Biol Chem* 1994;269:17993-8001.
- 25 Kobayashi T, Urabe K, Winder AJ, *et al*. Tyrosinase-related protein 1 (TRP1) functions as a DHICA oxidase in melanin biosynthesis. *EMBO J* 1994;13:5818-25.
- 26 Zhao H, Zhao Y, Nordlund JJ, Boissy RE. Human TRP-1 has tyrosine hydroxylase activity but no dopa oxidase activity. *Pigment Cell Res* 1994;7:131-40.
- 27 Zhao H, Eiling DJ, Medrano EE, Boissy RE. Retroviral infection with human tyrosinase-related protein-1 (TRP-1) cDNA upregulates tyrosinase activity and melanin synthesis in a trp-1-deficient melanoma cell line. *J Invest Dermatol* 1996;106:744-52.
- 28 Bergen AA, Samanns C, Van Dorp DB, *et al*. Localization of the X-linked ocular albinism gene (OA1) between DXS278/DXS237 and DXS143/DXS16 by linkage analysis. *Ophthalmic Paediatr Genet* 1990;11:165-70.
- 29 Bergen AA, Samanns C, Schuurman EJ, *et al*. Multipoint linkage analysis in X-linked ocular albinism of the Nettleship-Falls type. *Hum Genet* 1991;88:162-6.
- 30 Schnur RE, Nussbaum RL, Anson-Catwright L, *et al*. Linkage analysis in X-linked ocular albinism. *Genomics* 1991;9:605-13.
- 31 Charles SJ, Moore AT, Yates JR. Genetic mapping of X linked ocular albinism: linkage analysis in British families. *J Med Genet* 1992;29:552-4.
- 32 Charles SJ, Green JS, Grant W, Yates JR, Moore AT. Clinical features of affected males with X linked ocular albinism. *Br J Ophthalmol* 1993;77:222-7.
- 33 Bassi MT, Schiaffino MV, Renieri A, *et al*. Cloning of the gene for ocular albinism type 1 from the distal short arm of the X chromosome. *Nat Genet* 1995;10:13-9.
- 34 Charles SJ, Moore AT, Zhang Y, *et al*. Carrier detection in X linked ocular albinism using linked DNA polymorphisms. *Br J Ophthalmol* 1994;78:539-41.
- 35 Charles SJ, Moore AT, Grant JW, Yates JR. Genetic counselling in X-linked ocular albinism: clinical features of the carrier state. *Eye* 1992;6:75-9.
- 36 Schnur RE, Wick PA, Bailey C, *et al*. Phenotypic variability in X-linked ocular albinism: relationship to linkage genotypes. *Am J Hum Genet* 1994;55:484-96.
- 37 Schiaffino MV, Bassi MT, Galli L, *et al*. Analysis of the OA1 gene reveals mutations in only one-third of patients with X-linked ocular albinism. *Hum Mol Genet* 1995;4:2319-25.
- 38 Fukai K, Holmes SA, Lucchese NJ, *et al*. Autosomal recessive ocular albinism associated with a functionally significant tyrosinase gene polymorphism. *Nat Genet* 1995;9:92-5.
- 39 Giebel LB, Tripathi RK, King RA, Spritz RA. A temperature-sensitive tyrosinase in human albinism: a human homologue to the Siamese cat and the Himalayan mouse. *J Clin Invest* 1991;87:1119-22.
- 40 Gardner JM, Nakatsu T, Gondo Y, *et al*. The mouse pink-eyed dilution gene: association with human Prader-Willi and Angelmann syndromes. *Science* 1992;257:1121-4.
- 41 Buntinx IM, Hennekam RC, Brouwer OF, *et al*. Clinical profile of Angelman syndrome at different ages. *Am J Med Genet* 1995;56:176-83.
- 42 Prader A, Labhart A, Willi H. Ein Syndrom von Adipositas, Kleinwuchs, Kryptorchismus und Oligophrenie nach Myotonieartem Zustand im Neugeborenenalter. *Schweiz Med Wochenschr* 1956;86:1260-2.
- 43 Holm VA. The diagnosis of Prader-Willi syndrome. In: Holm VA, Sulzbacher S, Pipes PL, eds. *Prader-Willi syndrome*. Baltimore: University Press, 1981:27-44.
- 44 Cassidy SB. Prader-Willi syndrome. *Curr Probl Pediatr* 1984;14:1-55.
- 45 Krautmann PJ, Barenie JT, Myers DR. Clinical manifestations of Prader-Willi syndrome. *J Pediatr* 1981;5:256-61.
- 46 Jorde LB, Carey JC, White RL. *Medical genetics*. St. Louis: Mosby, 1995:74-6.
- 47 Bouloux PM, Kirk J, Munroe P, *et al*. Deletion analysis maps ocular albinism proximal to the steroid sulphatase locus. *Clin Genet* 1993;43:169-73.
- 48 Meindl A, Hosenfeld D, Bruckl W, *et al*. Analysis of a terminal Xp22.3 deletion in a patient with six monogenic disorders: implications for the mapping of X linked ocular albinism. *J Med Genet* 1993;30:838-42.
- 49 Sunohara N, Sakuragawa N, Satoyoshi E, Tanaka A, Shapiro LJ. A new syndrome of anosmia, ichthyosis, hypogonadism, and various neurological manifestations with deficiency of steroid sulfatase and arylsulfatase C. *Ann Neurol* 1986;19:174-81.
- 50 Winship IM, Babaya M, Ramesar RS. X-linked ocular albinism and sensorineural deafness: linkage to Xp22.3. *Genomics* 1993;18:444-5.
- 51 Wapenaar MC, Bassi MT, Schaefer L, *et al*. The genes for X-linked ocular albinism (OA1) and microphthalmia with linear skin defects (MLS): cloning and characterization of the critical regions. *Hum Mol Genet* 1993;2:947-52.
- 52 Fukai K, Oh J, Karim MA, *et al*. Homozygosity mapping of the gene for Chediak-Higashi syndrome to chromosome 1q42-q44 in a segment of conserved synteny that includes the mouse beige locus (bg). *Am J Hum Genet* 1996;59:620-4.
- 53 Barrat FJ, Auloge L, Pastural E, *et al*. Genetic and physical mapping of the Chediak-Higashi syndrome on chromosome 1q42-43. *Am J Hum Genet* 1996;59:625-32.
- 54 Nagle DL, Karim MA, Woolf EA, *et al*. Identification and mutation analysis of the complete gene for Chediak-Higashi syndrome. *Nat Genet* 1996;14:307-11.
- 55 Barbosa MD, Nguyen QA, Tchernev VT, *et al*. Identification of the homologous beige and Chediak-Higashi syndrome genes. *Nature* 1996;382:262-5.
- 56 Uyama E, Hirano T, Ito K, *et al*. Adult Chediak-Higashi syndrome presenting as parkinsonism and dementia. *Acta Neurol Scand* 1994;89:175-83.
- 57 Zhao H, Boissy YL, Abdel-Malek Z, *et al*. On the analysis of the pathophysiology of Chediak-Higashi syndrome. Defects expressed by cultured melanocytes. *Lab Invest* 1994;71:25-34.
- 58 Orlov SJ. Melanosomes are specialized members of the lysosomal lineage of organelles. *J Invest Dermatol* 1995;105:3-7.
- 59 Creel DJ, Conlee JW, Collier LL, Prieur DJ. Auditory brainstem responses in cats with Chediak-Higashi syndrome. *Acta Otolaryngol (Stockh)* 1994;114:373-5.
- 60 Creel D, Garber SR, King RA, Witkop CJ Jr. Auditory brainstem anomalies in human albinos. *Science* 1980;209:1253-5.
- 61 Creel D, Conlee JW, Parks TN. Auditory brainstem anomalies in albino cats. I Evoked potential studies. *Brain Res* 1983;260:1-9.
- 62 Conlee JW, Parks TN, Romero C, Creel DJ. Auditory brainstem anomalies in albino cats. II Neuronal atrophy in the superior olive. *J Comp Neurol* 1984;225:141-8.
- 63 Conlee JW, Parks TN, Creel DJ. Reduced neuronal size and dendritic length in the medial superior olivary nucleus of albino rabbits. *Brain Res* 1986;363:28-37.
- 64 Baker GE, Guillery RW. Evidence for the delayed expression of a brainstem abnormality in albino ferrets. *Exp Brain Res* 1989;74:658-62.
- 65 Fukai K, Oh J, Frenk E, Almodovar C, Spritz RA. Linkage disequilibrium mapping of the gene for Hermansky-Pudlak syndrome to chromosome 10q23.1-q23.3. *Hum Mol Genet* 1995;4:1665-9.
- 66 Izquierdo NJ, Townsend W, Hussels IE. Ocular findings in the Hermansky-Pudlak syndrome. *Trans Am Ophthalmol Soc* 1995;93:191-200.
- 67 Witkop CJ, Nunez Babcock M, Rao GH, *et al*. Albinism and Hermansky-Pudlak syndrome in Puerto Rico. *Bol Assoc Med P Rico* 1990;82:333-9.
- 68 Witkop CJ Jr, White JG, King RA. Oculocutaneous albinism. In: Nyhan WL, ed. *Heritable disorders of amino acid metabolism: patterns of clinical expression and genetic variation*. New York: Wiley, 1974:177-261.
- 69 Witkop CJ, Almodovar C, Pineiro B, Nunez Babcock M. Hermansky-Pudlak syndrome (HPS). An epidemiological study. *Ophthalmic Paediatr Genet* 1990;11:245-50.
- 70 Izquierdo NJ, Royuela MA, Maumenee IH. Possible origins of the gene of Hermansky-Pudlak in Puerto Rico. *Puerto Rico Health Sci J* 1993;12:147-8.
- 71 Wildenberg SC, Oetting WS, Almodovar C, *et al*. A gene causing Hermansky-Pudlak syndrome in a Puerto Rican population maps to chromosome 10q2. *Am J Hum Genet* 1995;57:755-65.
- 72 Oh J, Bailin T, Fukai K, *et al*. Positional cloning of a gene for Hermansky-Pudlak syndrome, a disorder of cytoplasmic organelles. *Nat Genet* 1996;14:300-6.
- 73 Boissy RE, Nordlund JJ. The molecular basis of congenital hypopigmentary disorders in humans—a review. *Pigment Cell Res* 1997;10:12-24.
- 74 Tassabehji M, Read AP, Newton VE, *et al*. Waardenburg's syndrome patients have mutations in the human homologue of the Pax-3 paired box gene. *Nature* 1992;355:635-6.
- 75 Hoth CF, Milunsky A, Lipsky N, *et al*. Mutations in the paired domain of the human PAX3 gene cause Klein-Waardenburg syndrome (WS-III) as well as Waardenburg syndrome type I (WS-I). *Am J Hum Genet* 1993;52:455-62.
- 76 Hughes AE, Newton VE, Liu XZ, Read AP. A gene for Waardenburg syndrome type 2 maps close to the human homologue of the microphthalmia gene at chromosome 3p12-p14.1. *Nat Genet* 1994;7:509-12.
- 77 Tassabehji M, Newton VE, Read AP. Waardenburg syndrome type 2 caused by mutations in the human microphthalmia (MITF) gene. *Nat Genet* 1994;8:251-5.
- 78 Attie T, Till M, Pelet A, *et al*. Mutation of the endothelin-receptor B gene in Waardenburg-Hirschsprung disease. *Hum Mol Genet* 1995;4:2407-9.
- 79 Puffenberger EG, Hosoda K, Washington SS, *et al*. A missense mutation of the endothelin-B receptor gene in multigenic Hirschsprung's disease. *Cell* 1994;79:1257-66.
- 80 Puffenberger EG, Kauffman ER, Bolk S, *et al*. Identity-by-descent and association mapping of a recessive gene for Hirschsprung disease on human chromosome 13q22. *Hum Mol Genet* 1994;3:1217-25.
- 81 Shiono T, Tsunoda M, Chida Y, Nakazawa M, Tamai M. X linked ocular albinism in Japanese patients. *Br J Ophthalmol* 1995;79:139-43.
- 82 Kriss A, Russell-Eggitt I, Taylor D. Childhood albinism. Visual electrophysiological features. *Ophthalmic Paediatr Genet* 1990;11:185-92.
- 83 Abadi RV, Dickinson CM, Pascal E, Papas E. Retinal image quality in albinos. A review. *Ophthalmic Paediatr Genet* 1990;11:171-6.
- 84 Sretavan DW, Feng L, Pure E, Reichardt LF. Embryonic neurons of the developing optic chiasm express L1 and CD44, cell surface molecules with opposing effects on retinal axon growth. *Neuron* 1994;12:957-75.
- 85 Sretavan DW, Pure E, Siegel MW, Reichardt LF. Disruption of retinal axon ingrowth by ablation of embryonic mouse optic chiasm neurons. *Science* 1995;269:98-101.
- 86 LaVail JH, Nixon RA, Sidman RL. Genetic control of retinal ganglion cell projections. *J Comp Neurol* 1978;182:399-422.
- 87 Marcus RC, Wang LC, Mason CA. Retinal axon divergence in the optic chiasm: midline cells are unaffected by the albino mutation. *Development* 1996;122:859-68.
- 88 Kugelmann TP, van Scott EJ. Tyrosinase activity in melanocytes of human albinos. *J Invest Dermatol* 1961;37:73-6.
- 89 King RA, Witkop CJ Jr. Hairbulb tyrosinase activity in oculocutaneous albinism. *Nature* 1976;263:69-71.



Albinism: modern molecular diagnosis

SUSAN M CARDEN, RAYMOND E BOISSY, PAMELA J SCHOETTKER, et al.

Br J Ophthalmol 1998 82: 189-195

doi: 10.1136/bjo.82.2.189

Updated information and services can be found at:

<http://bjo.bmj.com/content/82/2/189.full.html>

These include:

References

This article cites 77 articles, 18 of which can be accessed free at:

<http://bjo.bmj.com/content/82/2/189.full.html#ref-list-1>

Article cited in:

<http://bjo.bmj.com/content/82/2/189.full.html#related-urls>

Email alerting service

Receive free email alerts when new articles cite this article. Sign up in the box at the top right corner of the online article.

Topic Collections

Articles on similar topics can be found in the following collections

[Eye \(globe\)](#) (543 articles)

Notes

To request permissions go to:

<http://group.bmj.com/group/rights-licensing/permissions>

To order reprints go to:

<http://journals.bmj.com/cgi/reprintform>

To subscribe to BMJ go to:

<http://group.bmj.com/subscribe/>