

Efficacy of probing as treatment of epiphora in adults with blocked nasolacrimal ducts

Ana Guinot-Saera, Peter Koay

Abstract

Aims—To determine the efficacy of probing in the initial treatment of epiphora and the symptom free period in adults with blocked nasolacrimal ducts.

Methods—The results of probing in 85 eyes with epiphora due to nasolacrimal duct obstruction were studied retrospectively after a mean follow up of 7.4 months (SD 11.6) by a questionnaire and interview survey of patients.

Results—35% of the eyes had an outcome of no watering after probing, 17% mild watering, 35% moderate watering, and 11% severe watering. The patients' satisfaction (watering subjectively improved) after undergoing this procedure was 82%, which is higher than previously reported. The mean symptom free period in eyes with no watering was 11.25 months, in eyes with mild watering 8.20 months, in eyes with moderate watering 5.35 months, and in eyes with severe watering 0.95 months. There was a significant difference ($p=0.001$) in the symptom free period between the no watering and severe watering groups.

Conclusions—Probing in adults with confirmed nasolacrimal duct obstruction can be recommended as an initial treatment procedure because of its relatively good efficacy and high patient satisfaction without compromising subsequent surgical treatment if unsuccessful.

(Br J Ophthalmol 1998;82:389-391)

Idiopathic or primary acquired nasolacrimal duct obstruction (NLDO)¹ is a syndrome of unknown aetiology and accounts for the majority of NLDO found in adults. It is postulated that inflammation of unknown cause results in possible occlusive fibrosis² of the nasolacrimal system (NLS) causing obstruction and subsequent epiphora^{3,4} or "watering eye". Studies in children below the age of 4 months show that probing is an effective treatment. However, the risk of failure from probing increases with age, doubling every 6 months.⁵ To our knowledge, only one published study has investigated the efficacy of probing as a method for treating epiphora in adults.⁶ The authors of that study reported a 52% success rate measured by subjective improvement in watering after probing. Probing in adults is quick, safe, easily performed with local anaesthesia,⁷ cost effective, and potentially an outpatient procedure. Probing as an initial procedure for adult epiphora has been carried out in this institution for the past 7 years

providing the opportunity for the analysis of its efficacy by a survey of the probed patients.

Methods

In this retrospective study, adult patients aged 18 or older, of either sex who had probing for epiphora from January 1992 to November 1996 were selected. All probing were carried out by ophthalmologists at the consultant level. Patients were excluded if they had epiphora present from birth (congenital abnormality of NLS),^{5,8} watering secondary to a herpetic canaliculitis, dacryocystitis, and lacrimal sac mucocele.^{9,10} Patients with previous trauma,⁹ surgical intervention, intranasal disease, neoplasm of the lacrimal sac,^{10,11} corneal ulcer or foreign body, and any overproduction of tears (that is, any condition that causes reflex stimulation of the ophthalmic division of the trigeminal area) were excluded. Patients with abnormal punctal apposition, ectropion, and those with minimal symptoms (watering outdoors, only in cold wind that may occur in individuals with normal lacrimal excretory system) were also excluded.⁹⁻¹⁴

Of the 108 eyes identified in the study period, eight eyes did not meet the study criteria and were excluded. Of these eyes, five had dacryocystitis and two had unsatisfactory probing on the operating table (characterised by difficulty in passing the probe and subsequent inability to irrigate saline through the NLS to the nose) and one patient had died (see Table 2). From the 100 eyes which met the criteria, 15 eyes with an unknown outcome belonging to 11 patients (four patients with bilateral and seven patients with unilateral NLDO) were also excluded. This study is based on the remaining 85 eyes (41 right NLS and 44 left NLS) from 65 patients; 45 patients had unilateral and 20 patients had bilateral NLDO.

All patients had symptomatic epiphora and blockage of the lacrimal system confirmed on syringing.¹⁵ The mean age of the patients was 64.1 (SD 15.5, range 19-89) years. There were 38 females and 27 males. Table 1 summarises the demographic data.

Probing was carried out with a Foster's probe usually size 0.8 and through the upper canaliculus. We used the anaesthetic amethocaine drops to the conjunctival sac and lignocaine 2% and adrenaline infiltration around the medial canthus, the lower lid and deep up to the periosteum. The probe was advanced to the point of obstruction and pushed through with a gentle pressure.¹⁶ Patency following the probing was confirmed by syringing. Patients were treated with topical chloramphenicol,

Department of
Ophthalmology,
Darlington Memorial
Hospital, Darlington,
County Durham
DL3 6HX
A Guinot-Saera
P Koay

Correspondence to:
Dr A Guinot-Saera, C/Alvaro
de Bazan, 22, 17,
46010-Valencia, Spain.

Accepted for publication
28 October 1997

Table 1 Demographic data

Eyes in study	85	41 (right NLD)	44 (left NLD)
Patients in study	65		
Age (years)	Mean 64.16	SD 15.58	Range 19–89
Sex distribution	Male 27	Female 38	

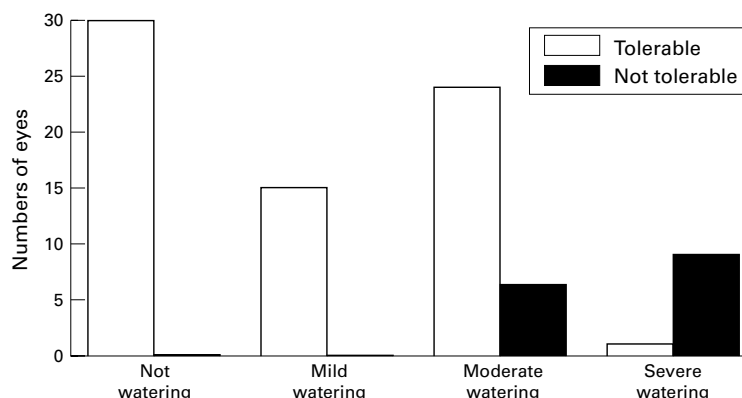


Figure 1 The number of eyes in each category of epiphora after probing.

four times daily, following the procedure¹⁷ for a period of 7–10 days.

The results obtained by questionnaire and by interview following the probing procedure were recorded. Patients' post probing epiphora was graded into four groups: no watering, mild watering (watering outdoors only), moderate watering, and severe watering. These groups were considered as excellent, good, medium, and failure, respectively. If the epiphora was present, patients were asked if this was tolerable or not. Special attention was paid to the length of time free of symptoms (symptom free period). Probing was arbitrarily judged to be a success if there was no watering or mild watering for at least 6 months following the procedure. Patient satisfaction with the procedure was also determined. Statistical comparison of discrete variables between the outcome groups was made with the unpaired Student's *t* test.

Table 2 Outcome following the probing procedure

Group	No of eyes	% of total (n=85)	Tolerable	Not tolerable
No watering	30	35	—	—
Mild watering	15	17	100% (n=15)	0%
Moderate watering	30	35	80% (n=24)	20% (n=6)
Severe watering	10	11	10% (n=1)	90% (n=9)

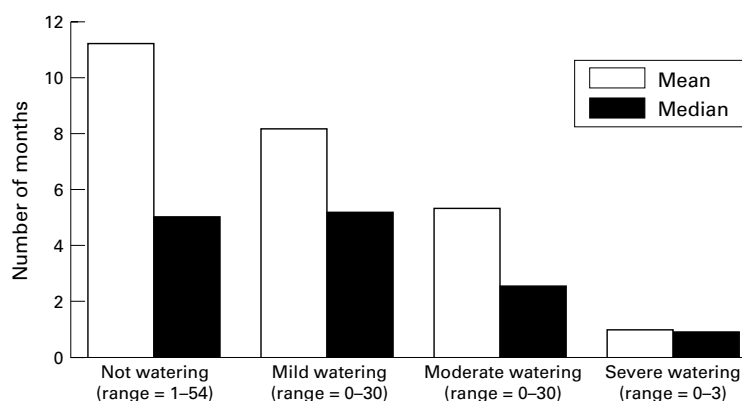


Figure 2 Length of time from probing to reported symptoms.

Table 3 Symptom free period after probing procedure in months (SD) for each group

	Mean (months)	Median (months)
No watering	11.25 (15.96)	5
Mild watering	8.20 (9.54)	5
Moderate watering	5.35 (7.66)	2.5
Severe watering	0.95 (1.06)	0.75

Results

Ninety eight per cent of the NLDs were patent in the operating theatre following the probing procedure. This includes the 85 eyes that met the criteria. The mean follow up time of probed patients was 7.4 (SD 11.6) months. There were no significant age and sex ratio differences between patients of the different outcome groups (that is, no watering, mild, moderate, and severe watering). Thirty eyes (35%) had an outcome of no watering and 15 (17%) were mild watering (waters only out of doors, in cold weather, or wind). The clinical success rate of the procedure was of 52% in terms of either completely relieving or resulting in only mild watering. Thirty eyes (35%) had an outcome of moderate watering and only 10 of the eyes (11%) still suffering of severe watering after the procedure (Fig 1).

Of the 15 patients with mild watering after probing, all of them (100%) describe their symptoms as tolerable. In patients with moderate and severe watering, 80% and 1% describe their symptoms as tolerable, respectively (Table 2). Eighty two per cent of the patients felt that their symptoms of watering had improved after probing, reflecting patient satisfaction with the procedure. Figure 2 and Table 3 show the mean symptom free period in the eyes after probing for each of the groups. There was significant difference ($p=0.001$, unpaired *t* test) in the symptom free period between the no watering and severe watering groups. No statistical significance ($p>0.01$) was found between the others groups.

Out of the 85 probing procedures carried out, there were two postoperative complications consisting of one nasal obstruction and one dacryocystitis. The complication rate for probing in this study was 2%. Nine of the 85 eyes (10.5%) subsequently required a dacryocystorhinostomy (DCR), eight of these eyes were in the outcome group of severe watering, and one was in the moderate watering outcome group.

Discussion

Epiphora due to obstruction of the nasolacrimal system is a common ophthalmic problem¹ causing discomfort, visual disturbances, and skin problems such as excoriation.⁹ Probing is a simple operative procedure easily performed in adults under local anaesthesia with minimal postoperative morbidity.^{18–19} In contrast, other treatments for adult epiphora due to NLDO are more invasive and are associated with a greater risk of complications. Such procedures include DCR^{9–20–21–22} Jones's procedure,²³ Palmaz balloon expandable metallic stents,²⁴ and canaliculodacry intubation.²⁵ These procedures

are complex, time consuming, requiring more resources, and often involve general anaesthesia with its attendant risks. The success rates (that is, not watering and mild watering) for DCR with comparable criteria to this study range from 83% to 87.4%.²⁶⁻²⁹ However, complications of DCR includes intraoperative problems such as haemorrhage, trauma, loss of nasal mucosa, CSF leak, and postoperative problems such as haemorrhage, infections, acute dacryocystitis, tube complications (granuloma formation), and scar complications (webbing).

In conclusion, probing for NLDO in adults with symptomatic watering has an 82% success in relieving symptoms. These results are more favourable than the earlier report.⁶ It is a simple, quick, cost effective, day case procedure and does not compromise the patient for further nasolacrimal surgery. A single probing procedure is effective in producing symptomatic improvement, when limited to use in patients with complete obstruction of the nasolacrimal duct and when watering was the only symptom. Our investigation confirms that probing, as an initial procedure, is an adequate and minimally invasive treatment for adult epiphora and can be an alternative to DCR, especially in elderly patients.

We wish to acknowledge assistance of Mr M S Dang, Mr L Singh, and Mr J D Haslam in the survey of their patients.

I want to specially than Dr K Narayanan and Dr J Ritter for their help.

- Shermetaro C, Gladstone GJ. Adult nasolacrimal duct obstruction. (Review) *J Am Osteopathic Assoc* 1994;3:229-32.
- Bartley GB. Acquired lacrimal drainage obstruction: an etiologic classification system, case reports, and a review of the literature. Part 1. (Review) *Ophthalmic Plastic Reconstruct Surg* 1992;8:237-42.
- Hurwitz JJ, Cooper PR, McRae DL, Chenoweth DR. The investigation of epiphora. *Can J Ophthalmol* 1977;12:196-8.
- Ellingham TR. Epiphora. *Trans Ophthalmol Soc NZ* 1977;29:119-22.
- Paul TO, Shepherd R. Congenital nasolacrimal duct obstruction: natural history and the timing of optimal intervention. (Review) *J Paediatr Ophthalmol Strabismus* 1994; 31:362-7.
- Bell TA. An investigation into the efficacy of probing the nasolacrimal duct as a treatment for epiphora in adults. *Trans Ophthalmol Soc UK* 1986;105(Pt 4):494-7.
- Collin JRC. *A manual of systematic eyelid surgery*. 2nd ed. Edinburgh: Churchill Livingstone, 1989:112.
- Boerner M, Seiff SR, Arroyo J. Congenital absence of the lacrimal puncta. *Ophthalmic Surg* 1995;6:53-6.
- Kansky JJ, ed. *Clinical ophthalmology*. 3rd ed. London: Butterworth-Heinemann, 1994:68.
- Kansky JJ, ed. *Clinical ophthalmology*. 3rd ed. London: Butterworth-Heinemann, 1994:66.
- Meyer DR, Kersten RC, Kulwin DR, Paskowski JR, Selkin RP. Management of canalicular injury associated with eyelid burns. *Arch Ophthalmol* 1995;113:900-3.
- Asiyo MN, Stefani FH. Pyogenic granulomas of the lacrimal sac. *Eye* 1992;6(Pt 1):97-101.
- Stefanescu-Dima A, Petria I, Craitoiu S. Carcinomul sacului lacrimal. *Rev Chirug Oncol Radiol Orl Oftalmol Stomatol, Seria: Oftalmologie* 1989;33:231-4.
- McNab A. In: Willshaw H, ed. *Practical ophthalmic surgery*. 1st ed. Edinburgh: Churchill Livingstone, 1992:191-211.
- Collin JRC. *A manual of systematic eyelid surgery*. 2nd ed. Edinburgh: Churchill Livingstone, 1989:110.
- Gonnering RS, Cahill KV, Nerad JA, et al. In: Denny M, ed. *Orbit, eyelids, and lacrimal system*. San Francisco: American Academy of Ophthalmology, 1994-1995;7:202-3.
- Kansky JJ, ed. *Clinical ophthalmology*. 3rd ed. London: Butterworth-Heinemann 1994:65.
- McCurrach F, Elder JE. Severe epistaxis—an unusual complication of lacrimal probing. *Aust NZ J Ophthalmol* 1993; 21:199-200.
- Yeatts RP, Crum B. An unusual complication of nasolacrimal duct probing. *Ophthalmic Surg* 1989;20:490-3.
- Fayet B, Bernard JA, Ritleng P, Assouline M, Pouliguen Y. Inocclusion palpebrale interne transitoire apres dacryocystirrhinostomie. *J Fr Ophthalmol* 1994;17:195-9.
- Beiran I, Pikkil J, Gilboa M, Miller B. Meningitis as a complication of dacryocystorhinostomy. *Br J Ophthalmol* 1994; 78:417-8.
- Hurwitz JJ, Eplett CJ, Fliss D, Freeman JL. Orbital haemorrhage during dacryocystorhinostomy. *Can J Ophthalmol* 1992;27:139-42.
- Bartley GB, Gustafson RO. Complication s of malpositioned Jones tubes. *Am J Ophthalmol* 1990;109:66-9.
- Ilgit ET, Yuksel D, Unal M, Akpek S, Isik S. Treatment of recurrent nasolacrimal duct obstructions with balloon-expandable metallic stents: results of early experience. *Am J Neuroradiol* 1996;17:657-63.
- al-Hussain H, Nasr AM. Silastic intubation in congenital nasolacrimal duct obstruction: an study of 129 eyes. *Ophthalmic Plastic Reconstruct Surg* 1993;9:32-7.
- Lawin-Brussel CA, Huttenbrink KB, Krebs A, Emmeich KH, Busse H. Endonasale implantation von Silikonfolie verbessert die Langzeitergebnisse der Revisionsoperation bei Tränenwegrestenosen. *Klin Monatsbl Augenheilkd* 1995; 206:33-8.
- Walther EK, Herberhold C, Lippel R. Digitale Subtraktions-Dakryozystographie (DS-DCG) und Ergebnisbilanz endonasaler Tränenwegschirurgie. *Laryng-Rhin-Otol* 1994;73:609-13.
- Weidembecher M, Hosemann W, Buhr W. Endoscopic endonasal dacryocystorhinostomy: results in 56 patients. *Ann Otol Rhinol Laryng* 1994;103:363-7.
- Weber R, Draf W, Kolb P. Die endonasale mikrochirurgische Behandlung von Tränenwegsstenosen. Indikation, Technik und Ergebnisse. *HNO* 1993;41:11-8.



Efficacy of probing as treatment of epiphora in adults with blocked nasolacrimal ducts

Ana Guinot-Saera and Peter Koay

Br J Ophthalmol 1998 82: 389-391

doi: 10.1136/bjo.82.4.389

Updated information and services can be found at:

<http://bjo.bmj.com/content/82/4/389.full.html>

References

These include:

This article cites 18 articles, 3 of which can be accessed free at:

<http://bjo.bmj.com/content/82/4/389.full.html#ref-list-1>

Article cited in:

<http://bjo.bmj.com/content/82/4/389.full.html#related-urls>

Email alerting service

Receive free email alerts when new articles cite this article. Sign up in the box at the top right corner of the online article.

Topic Collections

Articles on similar topics can be found in the following collections

[Lacrimal gland](#) (70 articles)

[Tears](#) (70 articles)

Notes

To request permissions go to:

<http://group.bmj.com/group/rights-licensing/permissions>

To order reprints go to:

<http://journals.bmj.com/cgi/reprintform>

To subscribe to BMJ go to:

<http://group.bmj.com/subscribe/>