

# Tono-Pen determination of intraocular pressure in patients with band keratopathy or glued cornea

Augusto Azuara-Blanco, Tahera K Bhojani, Abdul R Sarhan, C T Pillai, Harminder S Dua

## Abstract

**Aims**—To evaluate the intraocular pressure (IOP) measurements in patients with band keratopathy or glued corneas obtained from affected and non-affected areas.

**Methods**—15 patients with band keratopathy or glued corneas were prospectively recruited. When both eyes were affected, only the right eye was analysed. Tono-Pen readings of IOP were obtained sequentially from the affected and non-affected corneal surface. Additionally, Goldmann applanation tonometry was attempted.

**Results**—Determination of IOP with the Tono-Pen was possible in all cases, while Goldmann tonometry was not performed in three patients because of severe corneal irregularities. The average of the Tono-Pen readings obtained from the affected cornea (34.8 (SD 14.0) mm Hg) was consistently and significantly higher ( $p < 0.001$ ) than mean IOP obtained by the Tono-Pen from the non-affected area (14.8 (4.3) mm Hg). The average of Goldmann tonometry readings (14.4 (6.1) mm Hg) did not differ significantly from the Tono-Pen values obtained from the non-affected corneal area ( $p = 0.47$ ) but was significantly lower than the Tono-Pen measurements obtained from the affected area ( $p < 0.001$ ).  
**Conclusion**—In patients with band keratopathy or glued corneas determination of IOP by Tono-Pen tonometry varies from affected to non-affected area. The Tono-Pen overestimates the level of IOP when it is applied to areas with band keratopathy or with glue.

(Br J Ophthalmol 1998;82:634-636)

Department of  
Ophthalmology,  
University Hospital,  
Queen's Medical  
Centre, University of  
Nottingham,  
Nottingham

A Azuara-Blanco  
T K Bhojani  
A R Sarhan  
C T Pillai  
H S Dua

Correspondence to:  
Professor Harminder S Dua,  
B-Floor, South Block,  
Department of  
Ophthalmology, Queen's  
Medical Centre, University  
Hospital, Nottingham  
NG7 2UH.

Accepted for publication  
22 January 1998

The determination of the intraocular pressure (IOP) in patients with corneal pathology is problematic. Irregularities of the corneal surface cause inaccurate readings with the Goldmann applanation tonometer, which is the standard technique. Readings with the Goldmann applanation tonometer are not reproducible because the irregular corneal surfaces cause pooling of the fluorescein dye and irregular images of the circles.<sup>1,2</sup> Pneumotonometry<sup>3,4</sup> can overestimate the IOP when compared with Goldmann applanation tonometry. To our knowledge, it has not been validated in scarred or irregular corneas. Other commonly used techniques, such as Schiotz tonometry, non-contact tonometry, and palpation, are not accurate.<sup>5,6</sup>

The Tono-Pen tonometer has been validated in human studies and is considered an accept-

able measuring device in several clinical settings. The Tono-Pen is similar in principle to the MacKay-Marg tonometer, which provides accurate measurements in eyes with corneal oedema and surface irregularity.<sup>7-9</sup> Rootman *et al* reported that the Tono-Pen provided similar IOP measurements to the MacKay-Marg after keratoplasty, epikeratophakia and in scarred corneas, suggesting that the Tono-Pen was as accurate as the MacKay-Marg tonometer.<sup>10</sup> These authors recommended its use for irregular corneas. Some clinicians consider the Tono-Pen an useful device to estimate the IOP in patients with corneal abnormalities. However, this practice has not been validated. The purpose of this study was to analyse the IOP measurements obtained with the Tono-Pen in patients with band keratopathy or glued corneas and compare the values obtained from tonometry on affected and non-affected areas on the same eye.

## Material and methods

Patients with band keratopathy or glued corneas were prospectively recruited from the Department of Ophthalmology of the University of Nottingham. A total of 15 consecutive patients gave their permission to be included in the study. When both eyes were affected, only the right eye was analysed.

The Tono-Pen consists of a 1.2 mm central plunger attached to a micro strain gauge transducer, surrounded by a stationary 3.2 mm annulus. The transducer creates a waveform on each applanation of the cornea. A microprocessor chip analyses these waveforms, rejects those of improper shape, and averages the remainder. It produces a readout on a liquid crystal display. The instrument indicates an acceptable measurement sequence by a beep and gives a digital readout of the pressure and standard error of means (SEM) as a percentage of the average.

In this study, the Tono-Pen was calibrated before each day of use as suggested in the manufacturer's instructions. Tono-Pen tonometry was then carried out to obtain a measurement of the highest reliability (SEM <5% of the average). If the digital display indicated less than the highest reliability, the procedure was repeated until the highest reliability was achieved. All Tono-Pen measurements were made with a disposable latex cover over the tip, which was renewed after each patient. All measurements were made by ophthalmologists in a similar fashion. Tono-Pen readings of IOP were obtained sequentially from the affected area and from the non-affected cornea. In glued corneas the contact lens was not removed to determine the IOP.

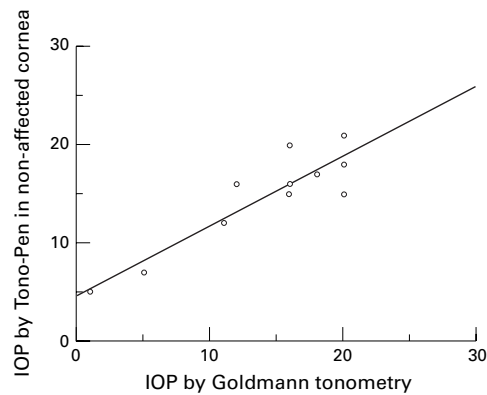


Figure 1 Scatter plot showing the values of IOP obtained by Tono-Pen tonometry on non-affected areas of the cornea (y axis) and Goldmann applanation tonometry (x axis). Linear regression analysis ( $r=0.90$ ).

An attempt to measure the IOP with a calibrated Goldmann applanation tonometer was then made. In glued corneas the contact lens was removed before IOP estimation. Astigmatism was not considered, and the biprism was adjusted such that the interface between the two prisms was oriented horizontally. With an arbitrary criterion, if the images obtained with the Goldmann applanation tonometer were relatively regular, the reading was recorded. If the images were considered too irregular, the IOP was not recorded. An attempt was made to avoid affected corneal areas with the Goldmann tonometer.

The two tailed paired *t* test and regression analysis were used to analyse the data. A nominal significance level of  $\alpha = 0.05$  was specified in advance of data analysis.

## Results

Eleven patients (73.3%) had band keratopathy and four (26.6%) had glued corneas. All patients except one with band keratopathy had plaques. The density of the plaques was variable. Intraocular pressure measured by the Tono-Pen was obtained in all patients. Goldmann tonometry was not recorded in three cases because of severe corneal irregularities. The mean Tono-Pen reading obtained from the affected cornea (34.8 (14.0) mm Hg) was consistently and significantly higher ( $p<0.001$ ) than the mean Tono-Pen reading obtained

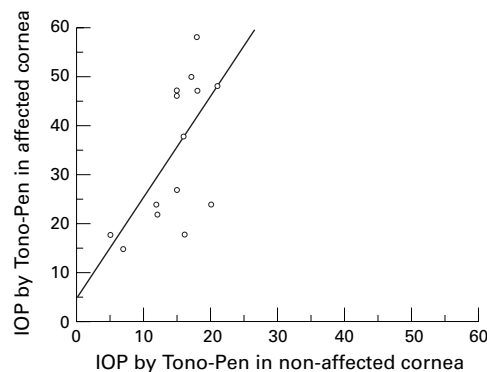


Figure 2 Scatter plot showing the values of IOP obtained by Tono-Pen tonometry on non-affected (x axis) and affected areas of the cornea (y axis). Linear regression analysis ( $r=0.61$ ).

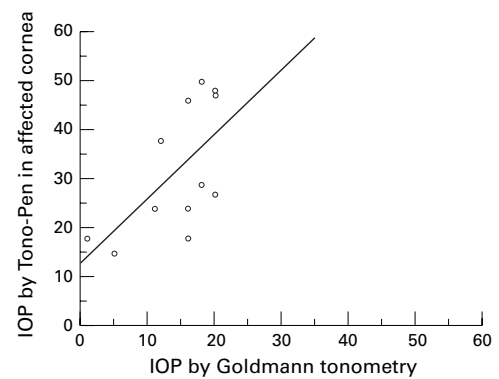


Figure 3 Scatter plot showing the values of IOP obtained by Goldmann applanation tonometry (x axis) and Tono-Pen tonometry on affected areas of the cornea (y axis). Linear regression analysis ( $r=0.62$ ).

from the non-affected area (14.8 (4.3) mm Hg). The case with calcium deposition but no plaque showed similar IOP values in the affected and non-affected cornea.

The mean Goldmann tonometry reading (14.4 (6.1) mm Hg) did not differ significantly from the Tono-Pen reading obtained from the non-affected corneal area ( $p=0.47$ ), but was significantly lower than the Tono-Pen readings obtained from the affected area ( $p<0.001$ ).

A scatter plot and linear regression analysis of IOP measurements can be observed in Figures 1, 2 and 3.

## Discussion

Band keratopathy is a non-specific condition that usually occurs from ocular inflammation, degenerative conditions, glaucoma, drugs, or systemic disease that causes hypercalcaemia. Other less common causes are possible. The calcium is deposited in Bowman's layer, in the basement membrane of the corneal epithelium, and in the most superficial lamellae of the stroma. The mechanism of calcium deposit has not been determined, although it is most often seen in the interpalpebral area. Cyanoacrylate glue can be helpful to close small corneal perforations. After application, the surface of the glue is hard, and is usually kept in place for several days to allow healing of the corneal tissues. This study demonstrates that in patients with band keratopathy and glued corneas, the IOP readings obtained with the Tono-Pen depend on the area where the tonometer is placed. To our knowledge, this finding has not been previously reported, and may have clinical relevance in patients with keratopathy.

The Tono-Pen has several advantages when compared with other tonometers: it is a small, hand held, portable tonometer, the use of which can be learned quickly and easily. The end point is not open to interpretation as it is with the Goldmann tonometer, which employs a visual end point. According to the literature, the Tono-Pen is not as accurate as the Goldmann tonometer in normal corneas, especially when measuring the IOP above 30 mm Hg.<sup>11-14</sup> Considering its limitations, the IOP estimation by Tono-Pen may be clinically useful in several clinical settings.<sup>15 16</sup> Especially helpful can be the determination of IOP by a

Tono-Pen in patients with corneal oedema or scarring because of its similarities with the MacKay-Marg tonometer.

In this study the accuracy of tonometry in patients with band keratopathy or glued corneas was not evaluated. Therefore, the question whether the obtained IOP reading through non-affected or through affected corneas accurately reflects the current level of IOP cannot be answered with certainty. The readings obtained by Goldmann applanation tonometry in this study, which were similar to the Tono-Pen values from non-affected corneas, should be interpreted with caution, owing to the irregularity of the corneas. Although acceptable mires were obtained in all but three patients, it might have been more appropriate to measure the IOP with the axis of the two prisms interfaces which gave the most regular images. Interestingly, Khan *et al* compared Tono-Pen readings obtained from various corneal and scleral locations, and concluded that mean readings from the mid-peripheral and clear limbal cornea did not differ significantly from central corneal readings over a 10–35 mm Hg IOP range.<sup>17</sup> Based on those observations, we hypothesise that the Tono-Pen readings obtained from non-affected corneas do not differ greatly from the actual IOP. The higher levels of IOP readings obtained with the Tono-Pen from affected areas are probably fictitious, and due to the hardness associated with the plaques of calcium or the glue.

In conclusion, in patients with band keratopathy or glued corneas, determination of IOP by Tono-Pen tonometry varies from affected to non-affected areas. The Tono-Pen appears to overestimate the level of IOP when it is applied to areas with band keratopathy or with glue.

Dr Azuaara-Blanco is the current Vision Express Cornea Fellow.

- 1 Moses RA. The Goldmann applanation tonometer. *Am J Ophthalmol* 1958;**46**:865–9.
- 2 McMillan F, Forster RK. Comparison of MacKay-Marg, Goldmann, and Perkins tonometers in abnormal corneas. *Arch Ophthalmol* 1975;**93**:420–4.
- 3 Langham ME, McCarthy E. A rapid pneumatic applanation tonometer. Comparative findings and evaluation. *Arch Ophthalmol* 1968;**79**:388–99.
- 4 Moses RA, Grodzki WJ. The pneumotonograph, a laboratory study. *Arch Ophthalmol* 1979;**97**:547–52.
- 5 Kauffman HR. Pressure measurement: which tonometer? *Invest Ophthalmol Vis Sci* 1972;**11**:80–5.
- 6 Baum J, Chaturvedi N, Netland PA, *et al*. Assessment of intraocular pressure by palpation. *Am J Ophthalmol* 1995;**119**:650–1.
- 7 MacKay RS, Marg E, Oechsli R. Automatic tonometer with exact theory and various biological applications. *Science* 1960;**131**:1668–9.
- 8 West CE, Capella JA, Kauffman HE. Measurement of intraocular pressure with a pneumatic applanation tonometer. *Am J Ophthalmol* 1972;**74**:505–8.
- 9 Kauffman HE, Wind CA, Waltman S. Validity of MacKay-Marg electronic applanation tonometer in patients with scarred irregular corneas. *Am J Ophthalmol* 1970;**69**:1003–7.
- 10 Rootman DS, Insler MS, Thompson HW, *et al*. Accuracy and precision of the Tono-Pen in measuring intraocular pressure after keratoplasty and epikeratophakia and in scarred corneas. *Arch Ophthalmol* 1988;**106**:1607–700.
- 11 Kao SF, Lichter PR, Bergstrom TJ, *et al*. Clinical comparison of the Oculab Tono-Pen to the Goldmann applanation tonometer. *Ophthalmology* 1987;**94**:1541–4.
- 12 Frenkel REP, Hong YJ, Shin DH. Comparison of the Tono-Pen to the Goldmann applanation tonometer. *Arch Ophthalmol* 1988;**106**:750–3.
- 13 Midelfart A, Wiggers A. Clinical comparison of the ProTon and Tono-Pen tonometers with the Goldmann applanation tonometer. *Br J Ophthalmol* 1994;**78**:895–8.
- 14 Menage MJ, Kaufman PL, Croft MA, *et al*. Intraocular pressure measurement after penetrating keratoplasty: mini-fied Goldmann applanation tonometer, pneumatonometer, and Tono-Pen versus manometry. *Br J Ophthalmol* 1994;**78**:671–6.
- 15 Geyer O, Mayron Y, Loewenstein A, *et al*. Tono-Pen tonometry in normal and in post-keratoplasty eyes. *Br J Ophthalmol* 1992;**76**:538–40.
- 16 Minckler DS, Baerveldt G, Heuer DK, *et al*. Clinical evaluation of the Oculab Tono-Pen. *Am J Ophthalmol* 1987;**104**:168–73.
- 17 Khan JA, Davis M, Graham CE, *et al*. Comparison of Oculab Tono-Pen readings obtained from various corneal and scleral locations. *Arch Ophthalmol* 1991;**109**:1444–6.



## Tono-Pen determination of intraocular pressure in patients with band keratopathy or glued cornea

Augusto Azuara-Blanco, Tahera K Bhojani, Abdul R Sarhan, et al.

*Br J Ophthalmol* 1998 82: 634-636

doi: 10.1136/bjo.82.6.634

---

Updated information and services can be found at:

<http://bjo.bmj.com/content/82/6/634.full.html>

---

*These include:*

### References

This article cites 17 articles, 9 of which can be accessed free at:

<http://bjo.bmj.com/content/82/6/634.full.html#ref-list-1>

Article cited in:

<http://bjo.bmj.com/content/82/6/634.full.html#related-urls>

### Email alerting service

Receive free email alerts when new articles cite this article. Sign up in the box at the top right corner of the online article.

---

### Topic Collections

Articles on similar topics can be found in the following collections

[Cornea](#) (383 articles)

[Ocular surface](#) (455 articles)

---

### Notes

---

To request permissions go to:

<http://group.bmj.com/group/rights-licensing/permissions>

To order reprints go to:

<http://journals.bmj.com/cgi/reprintform>

To subscribe to BMJ go to:

<http://group.bmj.com/subscribe/>