

## ORIGINAL ARTICLES—Clinical science

## Evidence that upregulation of serum IGF-1 concentration can trigger acceleration of diabetic retinopathy

E Chantelau

### Abstract

**Background**—Acute reduction of chronic hyperglycaemia can accelerate early diabetic retinopathy. In adolescent patients with Mauriac's syndrome, this phenomenon is related to an upregulation of subnormal serum IGF-1 levels.

**Aim**—To obtain longitudinal data on serum IGF-1 and retinopathy status in poorly controlled adult insulin dependent (type 1) diabetic patients without Mauriac's syndrome, in whom hyperglycaemia is reduced by intensive insulin therapy.

**Methods**—Four patients with chronic severe insulin deficiency and early microangiopathy were studied prospectively. Changes in plasma glucose, HbA<sub>1c</sub>, serum IGF-1 levels, proteinuria, retinopathy, and clinical status were followed up closely.

**Results**—Reducing hyperglycaemia from >16 mmol/l (equivalent to HbA<sub>1c</sub> >11%) to <10 mmol/l (HbA<sub>1c</sub> <8%) within 5 months increased serum IGF-1 levels by 70–220%. While proteinuria and symptomatic neuropathy regressed, retinopathy progressed from the mild to the severe non-proliferative stage with maculopathy (n=4), and to the proliferative stage (n=1). Laser coagulation was commenced upon the appearance of sight threatening macular oedema (n=4).

**Conclusion**—Upregulation of serum IGF-1 preceding retinal deterioration in these patients suggests a cause-effect relation, consistent with earlier experimental and clinical data.

(Br J Ophthalmol 1998;82:725–730)

Animal experiments have shown that intravitreal injection of insulin-like growth factor 1

Medical Department,  
Heinrich-Heine-  
Universität  
Düsseldorf, Germany  
E Chantelau

Correspondence to:  
Ernst Chantelau, MD, PhD,  
Diabetesambulanz  
MNR-Klinik,  
Heinrich-Heine-Universität  
Düsseldorf, Postfach 10 10  
07, D-40001 Düsseldorf,  
Germany.

Accepted for publication  
22 January 1998

Table 1 Patient data (before/after improving diabetes control)

Patient	Sex/age (years)	Height (cm)	Weight (kg)	Proteinuria (mg/l)	HbA <sub>1c</sub> (%)	GH (ng/ml)	IGF BP-3 (µg/ml)
CH	F/22	172	51/61	247/113	11.3/9.0	2.0/1.2	4.2/4.7
SK	F/28	170	65/73	170/23	12.0/7.2	3.7/1.3	3.8/4.2
CO	F/26	160	58/67	401/103	15.6/9.6	1.5/1.7	3.7/4.8
JA	M/45	185	62/72	108/34	16.8/8.3	NA/1.2	NA/3.4

HbA<sub>1c</sub> = glycated haemoglobin A<sub>1c</sub>; GH = growth hormone; IGF BP-3 = insulin-like growth factor binding protein 3.  
NA = not available.

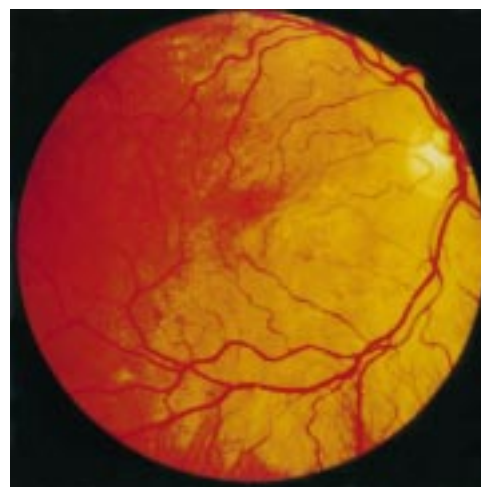

Figure 1 Fundus photograph of the right eye of patient CH. Start of improved diabetes control. Retinopathy level 1 (minimal non-proliferative retinopathy<sup>9</sup>); serum IGF-1 concentration 167 ng/ml.

(IGF-1) dose dependently causes retinal microangiopathy in pigs,<sup>1</sup> and neovascularisation in rabbits,<sup>2</sup> whereas reduction of serum IGF-1 levels inhibits neovascularisation in the ischaemic mouse model.<sup>3</sup> In human diabetic retinopathy, intravitreal growth factors (including IGF-1<sup>4</sup>) are elevated in relation to treatment

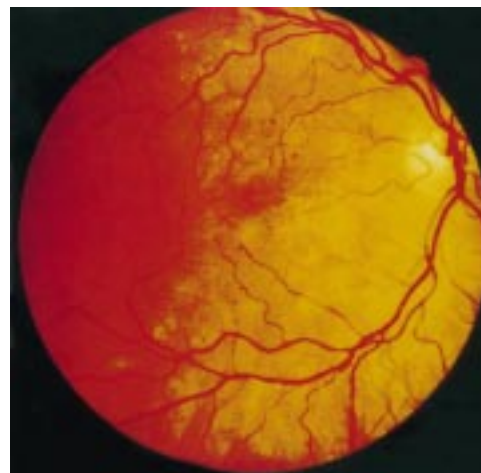

Figure 2 Fundus photograph of the right eye of patient CH 1 month after improving diabetes control. Retinopathy level 1, serum IGF-1 concentration 282 ng/ml.

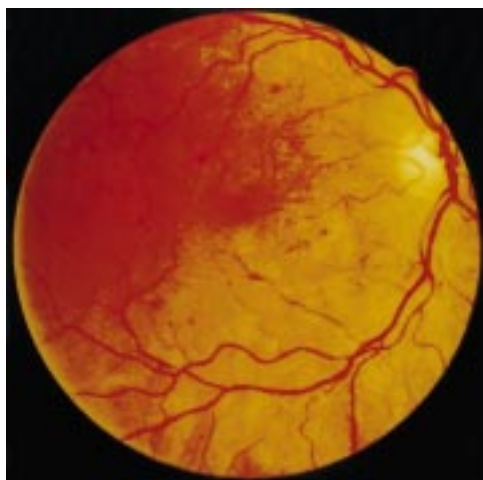

Figure 3 Fundus photograph of the right eye of patient CH 5 months after improving diabetes control. Retinopathy level 2 (moderate non-proliferative retinopathy<sup>9</sup>); serum IGF-1 level 284 ng/ml.

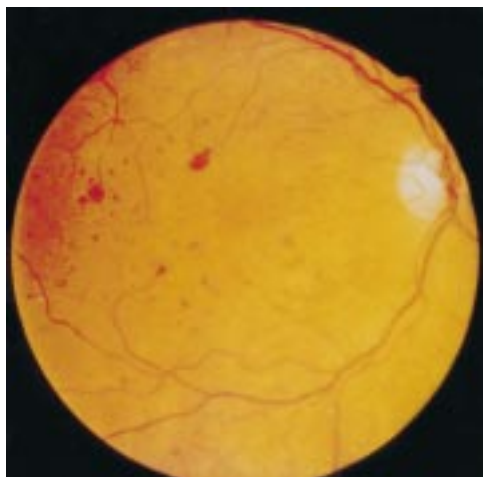


Figure 4 Fundus photograph of the right eye of patient CH 9 months after improving diabetes control. Retinopathy level 5 (proliferative retinopathy<sup>9</sup>); serum IGF-1 level 307 ng/ml.

with insulin.<sup>5</sup> We have reported recently that an increase in serum IGF-1 level preceded acute progression of retinopathy in an prepubertal insulin dependent (type 1) diabetic patient, in whom chronic insulin deficiency (Mauriac's syndrome) was corrected by appropriate insulin therapy.<sup>6</sup> In diabetes mellitus, chronic insulin deficiency decreases serum IGF-1 levels, which are upregulated again within some days after restoration of appropriate insulin therapy.<sup>7</sup> Whether acceleration of retinopathy following IGF-1 upregulation can also be observed in type 1 diabetic patients without Mauriac's syndrome, remains to be demonstrated. The following case report describes the clinical courses of four adult patients with type 1 diabetes mellitus, in whom diabetic retinopathy deteriorated significantly following improvement of insulin therapy and upregulation of serum IGF-1 levels.

#### Methods

An analysis of clinical and laboratory data was obtained on four cases of sexually mature adults with type 1 (insulin dependent) diabetes

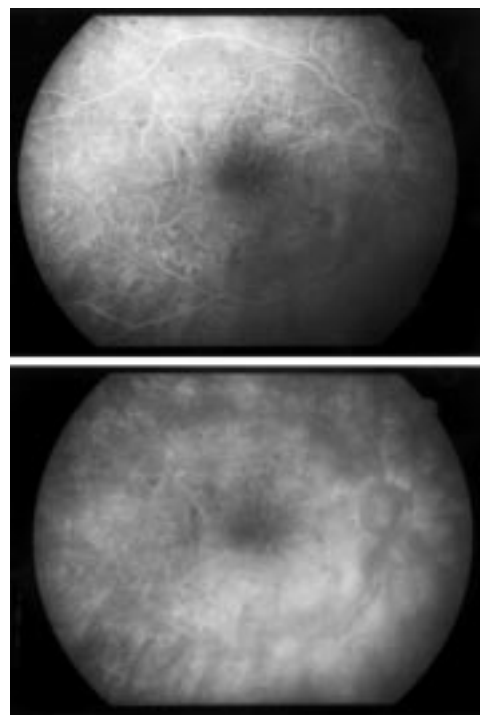


Figure 5 Fluorescein angiogram of the same eye as in Figure 3, before laser coagulation treatment.

mellitus. These patients were at risk of acceleration of diabetic retinopathy from improving glycaemic control because of the following features<sup>8</sup>: extremely high glycated haemoglobin A<sub>1c</sub> (HbA<sub>1c</sub>) for extended periods of time, incipient diabetic organ damage like neuropathy, microproteinuria, and early retinopathy, despite relatively short duration of diabetes.<sup>8</sup> They were studied prospectively for up to 20 months before and during intensification of insulin therapy. Routine laboratory assessments were carried out including measurements of microproteinuria (by nephelometry, normal <45 mg/l), of plasma glucose (Beckman Glucoseanalyzer, Fullerton, USA), of HbA<sub>1c</sub> (HPLC method, normal <5.6%), of serum levels of IGF-1 (IGF BP blocked radioimmunoassay, bio-Merieux, Nürtingen, Germany; assay sensitivity 0.02 ng/ml), and of IGF BP-3 (radioimmunoassay bio-Merieux, Nürtingen, Germany, normal range 2.28–4.93 µg/ml). Serum growth hormone was sampled at 9.00 am and measured by immunochemiluminometry (Nicolis Institute Diagnostics, San Juan Capistrano, USA). Ketouria was assessed semiquantitatively by dipstick (Ketertest, Boehringer Mannheim, Germany). Retinopathy status was assessed by fundus photography according to the EURODIAB-IDDM complications study,<sup>9</sup> and by fluorescein angiography.

#### Patients

There were three women and one man, whose diabetes was extremely poorly controlled for up to 3 years, owing to lack of motivation or fear of injections. Relevant clinical characteristics not mentioned in the text are summarised in Table 1.

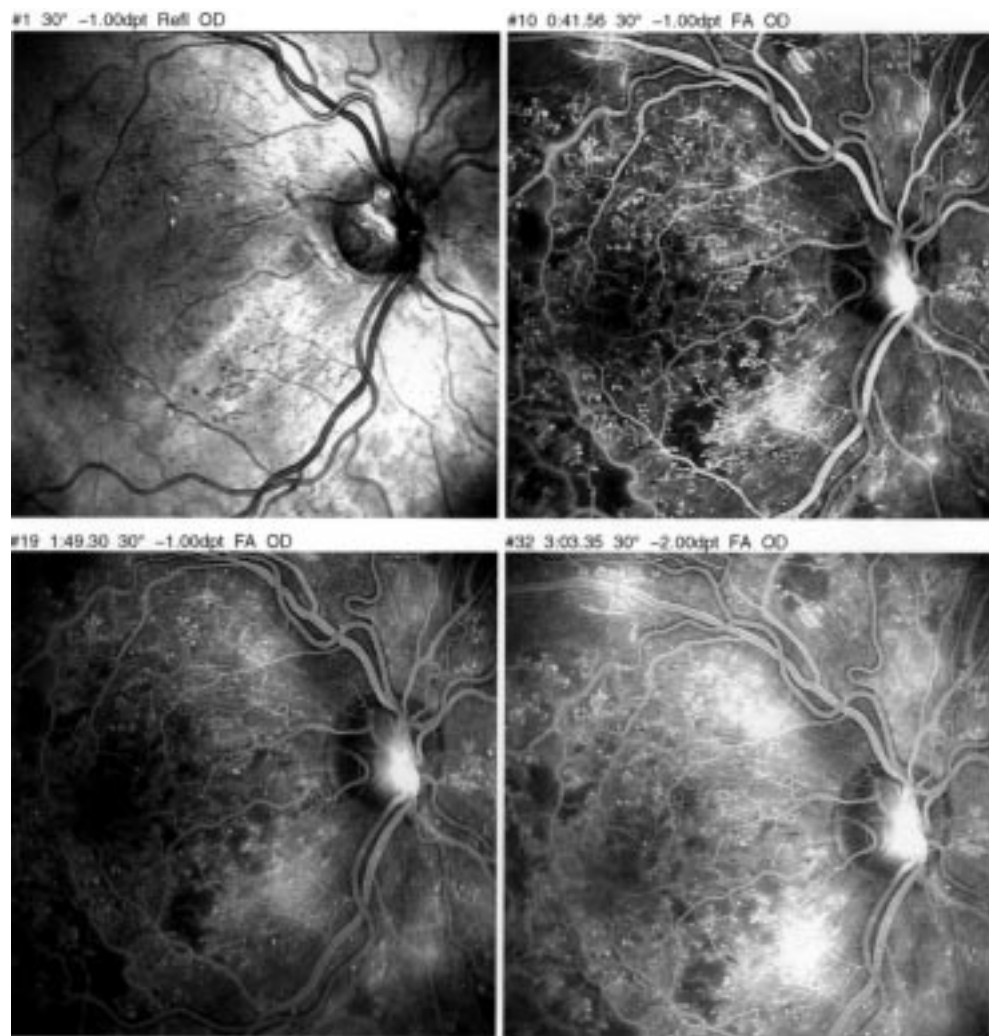


Figure 6 Fluorescein angiogram of the same eye as in Figure 4, showing new vessel on the disc.

#### CASE 1

CH was born 1974, and was diagnosed as diabetic in 1983. She was suffering from bulimia, and was poorly controlled for several years. In October 1996 she had sought medical advice because of incipient painful neuropathy, unresponsive to intravenous infusions of  $\alpha$  lipoic acid, which her family doctor had applied. On her presentation to the diabetic clinic she complained about fatigue and pain in the legs; she was under weight and amenorrhoeic. Clinical examination was normal except for hyperaesthesia of the feet. Fundus photography revealed minimal non-proliferative diabetic retinopathy (Fig 1).

#### CASE 2

SK was born 1968 and was diagnosed diabetic in 1986. She had been referred to the diabetes clinic in January 1996 because of necrobiosis diabetorum of her legs. At least during the previous 3 years, her metabolic control was very poor. During this time, she has been under weight and amenorrhoeic. On her first presentation, sensory polyneuropathy was found with reduced vibration sensation. There was extensive necrobiosis diabetorum on

both shins. Fundus photography showed minimal non-proliferative retinopathy.

#### CASE 3

CO was born 1971 and was diagnosed as diabetic in 1985. She had been referred in September 1997 because of amenorrhoea, neuropathic foot ulcer, and microproteinuria. She feared weight gain from appropriate insulin treatment. Fundus photography disclosed mild non-proliferative diabetic retinopathy.

#### CASE 4

The man (JA) was born in 1952 and was diagnosed as diabetic in 1995 (although the history of symptoms dates back to 1992). He had sought medical advice because of muscular weakness and fatigue, and increasing pains in the legs. He had lost 8 kg of body weight within the past year. He was under weight and showed signs of sensory neuropathy on his first presentation. Fundus photography showed minimal non-proliferative retinopathy.

#### Results

The clinical course during intensive insulin therapy was very similar in all four patients. It

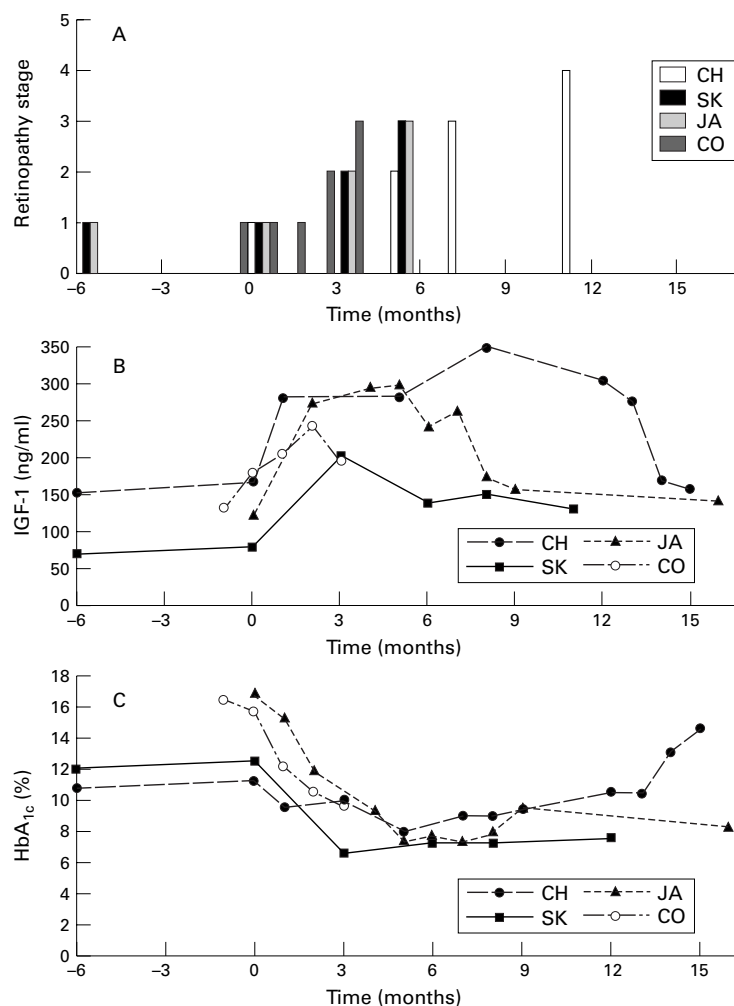


Figure 7 Dynamics of retinopathy level (A), serum IGF-1 (B), HbA<sub>1c</sub> (C), before and after initiation of improved diabetes control (time 0) in four type 1 diabetic patients (CH, SK, JA, CO).

is, therefore, summarised as follows. On presentation, all patients were hyperglycaemic and mildly ketonuric; plasma glucose ranged from 5.9 to 18.4 mmol/l, and HbA<sub>1c</sub> levels ranged from 16.8 to 11.3%. Serum IGF-1 was low with levels ranging from 78 to 167 ng/ml, respectively. For two patients (CH and SK), HbA<sub>1c</sub>, serum IGF-1, and retinopathy status were available 6 months before improving diabetes control; they were essentially the same as at time zero (see Fig 1). At time zero, insulin therapy was started in one patient (JA) and intensified in the others, reducing random plasma glucose concentrations to 4.6–10.8 mmol/l, and HbA<sub>1c</sub> to 7.2–8.3%, and abolishing ketonuria. IGF-1 levels increased by 70–220% immediately after improving insulin therapy, while retinopathy progressed from level 1 (minimal), to level 2 (moderate), and further to level 3 (severe non-proliferative retinopathy) with macula ischaemia and oedema. Patient CH further progressed to level 5 (proliferative retinopathy); as an example, her fundus photographs and angiograms are shown in Figures 1–6.

Changes in IGF-1, HbA<sub>1c</sub> and retinopathy over time are depicted in Figure 7. All patients required laser coagulation because of sight

threatening macular oedema (according to fluorescein angiography). Initially, serum IGF-1 levels increased in all patients from low normal to high normal levels.<sup>10</sup> After some months with the HbA<sub>1c</sub> level around 8%–10% (corresponding to an average glycaemia of 10–14 mmol/l), serum IGF-1 levels declined in three patients (Fig 7).

In patient CH IGF-1 levels did not decline, while macular oedema persisted with reduction in visual acuity to 0.4. Laser coagulation treatment was suspended. Only after the insulin dosage was reduced in order to lower her IGF-1 level to 160 ng/ml, did macular oedema resolve, and she regained full visual acuity. Laser treatment was continued.

Growth hormone levels were in the normal range before, and decreased within the normal range after improving diabetes control; serum levels of IGF BP-3 behaved accordingly (Table 1). After 7 to 16 months, proteinuria had normalised in two, and symptomatic neuropathy had disappeared in all patients. All of them had regained normal body weight (Table 1) without clinical evidence of oedema, and the women reported regular menstrual bleeding.

## Discussion

The present longitudinal data extend previous observations on a role of elevated serum IGF-1 in accelerating human diabetic retinopathy,<sup>4 11 12</sup> which cross sectional studies<sup>13 14</sup> were unable to disclose. In all four cases, the institution of sufficient insulin substitution induced an overshooting upregulation of serum IGF-1 within some weeks, which 2–8 weeks later was followed by a significant progression of early diabetic retinopathy to a sight threatening stage with macular oedema. One patient with severe macular oedema was re-exposed to insulin deficiency; while glycaemia and HbA<sub>1c</sub> levels increased serum IGF-1 decreased and the macular oedema improved. Paradoxical worsening of pre-existing diabetic retinopathy after improved diabetes control (by intensive insulin therapy) had been noted repeatedly, and termed “normoglycaemic re-entry phenomenon”.<sup>15–20</sup> Most recently, this phenomenon was observed in the secondary intervention cohort of the DCCT.<sup>21</sup> The present data may help to explain it. A decreased hepatic IGF-1 production in the presence of elevated growth hormone secretion<sup>10</sup> is a less well known consequence of chronic insulin deficiency; another consequence is hyperglycaemia. Adequate insulin substitution to improve glycaemic control reverses this abnormality by upregulating IGF-1. The present data show that, if the increase in serum IGF-1 is large enough and the retina is already sufficiently damaged from hypoxia, this IGF-1 upregulation is followed by acute progression of retinopathy. The progression started with severe oedematous changes. A cause-effect relation is highly likely, since serum and vitreous IGF-1 concentrations are positively correlated (at least in proliferative diabetic retinopathy<sup>4</sup>), owing to leaking of IGF-1 from the bloodstream.<sup>22</sup> Furthermore, adverse effects on the normal<sup>23</sup>

and the diabetic retina<sup>24</sup> have been reported with systemic application of recombinant human IGF-1. The exact mechanism by which IGF-1 exerts its action on the retina is still unknown. Possibly, IGF-1 acts as a mediator to other factors that may be involved, such as the rate of fall of blood glucose,<sup>25</sup> other growth factors<sup>4, 26</sup>—for example, vascular endothelial growth factor (VEGF), the local production of which is increased by chronic retinal hypoxia.<sup>27</sup> Hypoxia also increases retinal IGF-1 production.<sup>28</sup> Thus, increased serum IGF-1 would enhance its local effects by adding to its local concentrations, and/or enhance hypoxia induced VEGF activity,<sup>27, 29</sup> thereby accelerating diabetic retinopathy. Serum VEGF, although positively correlated with HbA<sub>1c</sub>,<sup>30</sup> is unrelated to vitreous VEGF.<sup>31</sup>

The hypothesis that serum IGF-1 can accelerate diabetic retinopathy may also work in physiological conditions with elevation of serum IGF-1, like puberty and pregnancy, both of which carry an increased risk of progression of diabetic retinopathy.<sup>32–35</sup> It further explains why pituitary ablation (substantially reducing growth hormone and IGF-1<sup>10</sup>) acutely improved visual acuity in some cases of diabetic retinopathy,<sup>36</sup> and invariably stopped proliferative diabetic retinopathy.<sup>37</sup>

In summary, the present data show that an increase in serum IGF-1 levels by 70–220% subsequent to improving diabetes control was followed by severe deterioration of diabetic retinopathy in four type 1 diabetic patients with early diabetic microangiopathy. In one patient, re-exposure to poor diabetes control lowered serum IGF-1 and resolved macular oedema consistent with a previous report.<sup>38</sup> In consideration of the established adverse effects of exogenous IGF-1 on the diabetic microcirculation, and the benefit of pituitary ablation on proliferative diabetic retinopathy, a causal effect of the increased serum IGF-1 is highly probable. These data are preliminary and need further studies before firm recommendations with respect to treatment can be given—for example, watchful waiting,<sup>39</sup> suppression of IGF-1 with a somatostatin analogue,<sup>3</sup> temporary restoration of former insulin deficiency, or early preventive laser coagulation.<sup>15</sup> However, the present cases suggest that the “normoglycaemic re-entry phenomenon” should be regarded as another particular risk factor for the progression of diabetic retinopathy, like cataract surgery or diabetic nephropathy.

Presented in parts at the annual meeting of the European Association for the Study of Diabetes (EASD) in Helsinki 1997, and at the Joint EASD/Juvenile Diabetes Foundation Meeting in Oxford, 1997.

The cooperation of Dr K Lemmen, PhD, director of the Eye Clinic at the St Martinus-Krankenhaus in Düsseldorf is gratefully acknowledged. I am also indebted to the staff of the diabetic outpatient clinic—namely, Drs S Bott and G Neises, and Mrs S Scholz, and to Dr Feldkamp and his endocrinology laboratory staff.

- 1 Danis RP, Bingaman DP. Insulin-like growth factor-1 retinal microangiopathy in the pig eye. *Ophthalmology* 1997; **104**:1661–9.
- 2 Grant MB, Mames RN, Fitzgerald C, et al. Insulin-like growth factor-1 acts as an angiogenic agent in rabbit cornea and retina: comparative studies with basic fibroblast growth factor. *Diabetologia* 1993; **36**:282–91.

- 3 Smith LEH, Kopchick JJ, Chen W, et al. Essential role of growth hormone in ischaemia induced retinal neovascularisation. *Science* 1997; **276**:1706–8.
- 4 Grant M, Russell B, Fitzgerald C, et al. Insulin-like growth factors in vitreous. *Diabetes* 1986; **35**:416–20.
- 5 Boulton M, Gregor Z, McLeod D, et al. Intravitreal growth factors in proliferative diabetic retinopathy: correlation with neovascular activity and glycaemic management. *Br J Ophthalmol* 1997; **81**:228–33.
- 6 Chantelau E, Eggert H, Seppel T, et al. Elevation of serum IGF-1 precedes proliferative diabetic retinopathy in Mauriac's syndrome. *Br J Ophthalmol* 1997; **81**:169–70.
- 7 Glaser EW, Goldstein S, Phillips LS. Nutrition and somatomedin. *Diabetes* 1987; **36**:1152–60.
- 8 Moskalets E, Galstyan G, Starostina E, et al. Association of blindness to intensification of glycemic control in insulin-dependent diabetes mellitus. *J Diab Comp* 1994; **8**:45–50.
- 9 Aldington SJ, Kohner EM, Meurer S, et al for the EURODIAB-IDD Complications Study Group. Methodology for retinal photography and assessment of diabetic retinopathy: the EURODIAB-IDD Complications Study. *Diabetologia* 1995; **38**:437–44.
- 10 LeRoith D. Insulin-like growth factors. *N Engl J Med* 1997; **336**:633–40.
- 11 Merimee TJ, Zapf J, Froesch ER. Insulin-like growth factors: studies in diabetics with and without retinopathy. *N Engl J Med* 1983; **309**:527–30.
- 12 Hyer SL, Sharp PS, Sleightholm M, et al. Progression of diabetic retinopathy and changes in serum insulin-like growth factor I (IGF-1) during continuous subcutaneous insulin infusion (CSII). *Horm Metabol Res* 1989; **21**:18–22.
- 13 Dills DG, Moss SE, Klein R, et al. Is insulin-like growth factor 1 associated with diabetic retinopathy? *Diabetes* 1990; **39**:191–5.
- 14 Wang Q, Dills DG, Klein R, et al. Does insulin-like growth factor 1 predict incidence and progression of diabetic retinopathy? *Diabetes* 1995; **44**:161–4.
- 15 Chantelau E, Kohner EM. Why some cases of retinopathy worsen when diabetic control improves. *BMJ* 1997; **315**:1105–6.
- 16 Kingsley R, Ghosh G, Lawson P, et al. Severe diabetic retinopathy in adolescents. *Br J Ophthalmol* 1983; **67**:73–89.
- 17 Dahl-Jorgensen K, Brinchmann-Hansen O, Hanssen KF, et al for Diabetes Group. Rapid tightening of blood glucose control leads to transient deterioration of diabetic retinopathy in insulin-dependent diabetes mellitus: the Oslo Study. *BMJ* 1985; **290**:811–15.
- 18 Kroc Collaborative Study Group. Diabetic retinopathy after 2 years of intensified insulin treatment. *JAMA* 1988; **260**:37–41.
- 19 Carroll PB, Herskowitz RD, Goodman AD, et al. Rapid onset of severe retinopathy, cataracts and neuropathy in young patients with diabetes mellitus. *Acta Paediatr* 1992; **8**:355–8.
- 20 Agardh CD, Eckert B, Agardh E. Irreversible progression of severe retinopathy in young type-1 insulin-dependent diabetes mellitus after improved metabolic control. *J Diab Comp* 1992; **6**:96–100.
- 21 Diabetes Control and Complications Trial Research Group. The effect of intensive treatment of diabetes on the development and progression of long-term complications in insulin-dependent diabetes mellitus. *N Engl J Med* 1993; **329**:977–86.
- 22 Spranger J, Bühnen J, Meyer-Schwickerath R, et al. Anstieg von IGF-1, IGF-2 und IGFBP-3 im menschlichen Glaskörper als Konsequenz einer Blut-Retina-Schrankenstörung bei Patienten mit proliferativer diabetischer Retinopathie. (Abstract.) *Diab Stoffw* 1998; **7**(Suppl 1):32.
- 23 Hussain MA, Studer K, Messmer EP, et al. Treatment with insulin-like growth factor I alters capillary permeability in skin and retina. *Diabetes* 1995; **44**:1209–12.
- 24 Genentech/Roche Inc. *IGF-1 in diabetes*. Clinical background brochure. London, 1996.
- 25 Li W, Liu X, Yanoff M, et al. Cultured retinal capillary pericytes die by apoptosis after an abrupt fluctuation from high to low glucose levels: a comparative study with retinal capillary endothelial cells. *Diabetologia* 1996; **39**:537–47.
- 26 Schlingemann RO, van Hinsbergh VWM. Role of vascular permeability factor/vascular endothelial growth factor on eye disease. *Br J Ophthalmol* 1997; **81**:501–12.
- 27 Aiello LP, Northrup KM, Keyt BA, et al. Hypoxic regulation of vascular endothelial growth factor in retinal cells. *Arch Ophthalmol* 1995; **113**:1538–44.
- 28 Averbukh EA, Weiss O, Yanko R, et al. IGF system gene expression in hypoxic retina. (abstract) *Diabetologia* 1997; **40**(Suppl 1):A 493.
- 29 Punglia RS, Lu M, Hsu J, et al. Regulation of vascular endothelial growth factor expression by insulin-like growth factor I. *Diabetes* 1997; **46**:1619–26.
- 30 Al-Mrayat M, Sharp P, Chong P. Circulating vascular endothelial growth factor in diabetic patients. (abstract) *Diabetic Med* 1997; **14**(Suppl 4):S 39.
- 31 Burgos R, Simo R, Audi L, et al. Vitreous levels of vascular endothelial growth factor are not influenced by its serum concentrations in diabetic retinopathy. *Diabetologia* 1997; **40**:1107–9.
- 32 Bhaumick B, Danilkewich AD, Bala RM. Insulin-like growth factors (IGF) I and II in diabetic pregnancy: suppression of normal pregnancy-induced rise of IGF-I. *Diabetologia* 1986; **29**:792–7.
- 33 Roger D, Sherman LD, Gabbay KH. Effect of puberty on insulin-like growth factor I and HbA1 in type-1 diabetes. *Diabetes Care* 1991; **14**:1031–5.

- 34 Klein BEK, Moss SE, Klein R. Is menarche associated with diabetic retinopathy? *Diabetes Care* 1990;**13**:1034-8.
- 35 Chew EY, Mills JL, Metzger BE, *et al*. Metabolic control and progression of retinopathy. The Diabetes in Early Pregnancy Study. *Diabetes Care* 1995;**18**:631-7.
- 36 Lundbaek K, Jensen VA, Olsen TS, *et al*. Diabetes, diabetic angiopathy, and growth hormone. *Lancet* 1970;ii:131-3.
- 37 Sharp PS, Fallon TJ, Brazier OJ, *et al*. Long-term follow-up of patients who underwent yttrium-90 pituitary implantation or treatment of proliferative diabetic retinopathy. *Diabetologia* 1987;**30**:199-207.
- 38 Shigetou M, Sagawa T, Ishibashi T, *et al*. Exacerbation of diabetic retinopathy following systemic insulin-like growth factor-1. *Jpn J Clin Ophthalmol* 1997;**51**:1251-5.
- 39 Rosenlund EF, Haakens K, Brinchmann-Hansen O, *et al*. Transient proliferative diabetic retinopathy during insulin treatment. *Am J Ophthalmol* 1988;**105**:618-25.



## Evidence that upregulation of serum IGF-1 concentration can trigger acceleration of diabetic retinopathy

E Chantelau

*Br J Ophthalmol* 1998 82: 725-730

doi: 10.1136/bjo.82.7.725

---

Updated information and services can be found at:

<http://bjo.bmj.com/content/82/7/725.full.html>

---

*These include:*

### References

This article cites 34 articles, 14 of which can be accessed free at:

<http://bjo.bmj.com/content/82/7/725.full.html#ref-list-1>

Article cited in:

<http://bjo.bmj.com/content/82/7/725.full.html#related-urls>

### Email alerting service

Receive free email alerts when new articles cite this article. Sign up in the box at the top right corner of the online article.

---

### Topic Collections

Articles on similar topics can be found in the following collections

[Retina](#) (1217 articles)

[Paediatrics](#) (278 articles)

[Ophthalmologic surgical procedures](#) (971 articles)

---

### Notes

---

To request permissions go to:

<http://group.bmj.com/group/rights-licensing/permissions>

To order reprints go to:

<http://journals.bmj.com/cgi/reprintform>

To subscribe to BMJ go to:

<http://group.bmj.com/subscribe/>