

# Correlation between Octopus perimetry and fluorescein angiography after strontium-90 plaque brachytherapy for subfoveal exudative age related macular degeneration

Aino Jaakkola, Eija Vesti, Ilkka Immonen

## Abstract

**Aim**—To evaluate the correlation between the central visual field and changes in fluorescein angiography and fundus photography in patients treated with strontium plaque radiotherapy for subfoveal exudative age related macular degeneration (AMD).

**Methods**—Octopus program 34 automated static perimetry, fluorescein angiography, and colour fundus photography were performed on 19 patients at baseline and at 12 months after strontium-90 plaque therapy. A schematic picture outlining the areas of hyperfluorescent neovascular membranes and subretinal blood was drawn of a projected 30° fundus fluorescein angiogram. This drawing was superimposed on the size adjusted Octopus visual field. The changes in retinal sensitivity were calculated and related to angiographic changes.

**Results**—Three of the 19 patients had a reliability factor (RF) >15% and were excluded from further analysis. In the remaining 16 patients the mean defect (MD) and loss variance (LV) values remained unchanged in patients showing regression of the choroidal neovascular membrane (CNVM) to irradiation at 12 months. MD was 7.7 (SD 1.7) at baseline and 7.6 (1.9) at 12 months ( $p = 0.86$ ), and LV was 32.6 (13.9) at baseline and 32.4 (15.7) at 12 months ( $p = 0.94$ ). However, in patients with progression of the CNVM at 12 months, both the MD and LV increased significantly during the 12 month follow up (MD from 7.3 (2.9) to 13.1 (3.6) ( $p = 0.05$ ) and LV from 31.0 (22.9) to 71.8 (24.1) ( $p = 0.017$ )). When comparing the mean retinal sensitivity in the area of the primary CNVM (including classic, occult, and haemorrhagic components), the results were analogous: in patients with a regression of the CNVM after irradiation the mean sensitivity remained almost unchanged. It was 10.3 (6.4) dB at baseline and 9.4 (7.3) dB at 12 months ( $p = 0.58$ ). In five out of 11 patients (45%) with regression of the CNVM, the mean retinal sensitivity even improved by 2.0–5.0 dB in the area of the original lesion during follow up. Instead, in patients showing progression of the CNVM at 12 months, there was a significant loss in mean retinal sensitivity—from 9.9 (4.6) dB at baseline

to 1.0 (1.1) dB at 12 months ( $p = 0.019$ ). The mean retinal sensitivity in the area of the irradiated but clinically normal retina during follow up was not significantly altered (21.5 dB at baseline, 19.7 dB at 12 months ( $p = 0.10$ )).

**Conclusions**—Regression of subfoveal choroidal membranes in AMD after focal strontium irradiation is connected with stabilisation or even improvement of retinal sensitivity in central visual field measured by automated perimetry. Strontium plaque irradiation does not change the sensitivity in clinically normal paramacular retina during a 12 month follow up.

(Br J Ophthalmol 1998;82:763-768)

The majority of choroidal neovascular membranes (CNVM) in patients with age related macular degeneration (AMD) are subfoveal or occult at initial presentation.<sup>1</sup> Subfoveal CNVMs are usually large (>1500 µm in diameter) and further progression of these membranes leads to severe loss of central vision and a large central scotoma.<sup>2,3</sup> The size and depth of the scotoma caused by CNVMs has been evaluated only in relatively few studies.<sup>3-7</sup> Although laser photocoagulation of subfoveal CNVMs has been shown to bring long term benefit,<sup>8</sup> the acute loss of vision after laser treatment is seldom accepted by the patient. Furthermore, only a minority of all patients with exudative AMD are suitable for this treatment.<sup>9</sup> Recently, new, more selective experimental treatments have made it possible to induce regression of CNVMs without acute destruction of overlying photoreceptors.

We have treated 20 patients showing recent subfoveal CNVMs associated with AMD with strontium-90 plaque brachytherapy. We found regression of the CNVM in 74% of patients at 12 month follow up. Visual acuity (VA) was unchanged (within one line) or improved in 45% of the patients at 12 months.<sup>10,11</sup> In view of the fact that central scotoma is the main symptom of AMD, it is of interest to study how the scotoma changes after irradiation of the macula. In this study the changes in Octopus central visual field are assessed and compared with changes seen in fluorescein angiography (FA) before irradiation and 1 year thereafter.

## Patients and methods

Twenty patients treated with local episcleral strontium-90 applicator for recent (duration of

Department of  
Ophthalmology,  
Helsinki University  
Central Hospital,  
Finland  
A Jaakkola  
E Vesti  
I Immonen

Correspondence to:  
Aino Jaakkola, MD, Helsinki  
University Central Hospital,  
Department of  
Ophthalmology,  
Haartmaninkatu 4 C,  
FIN-00290 Helsinki,  
Finland.

Accepted for publication  
11 February 1998

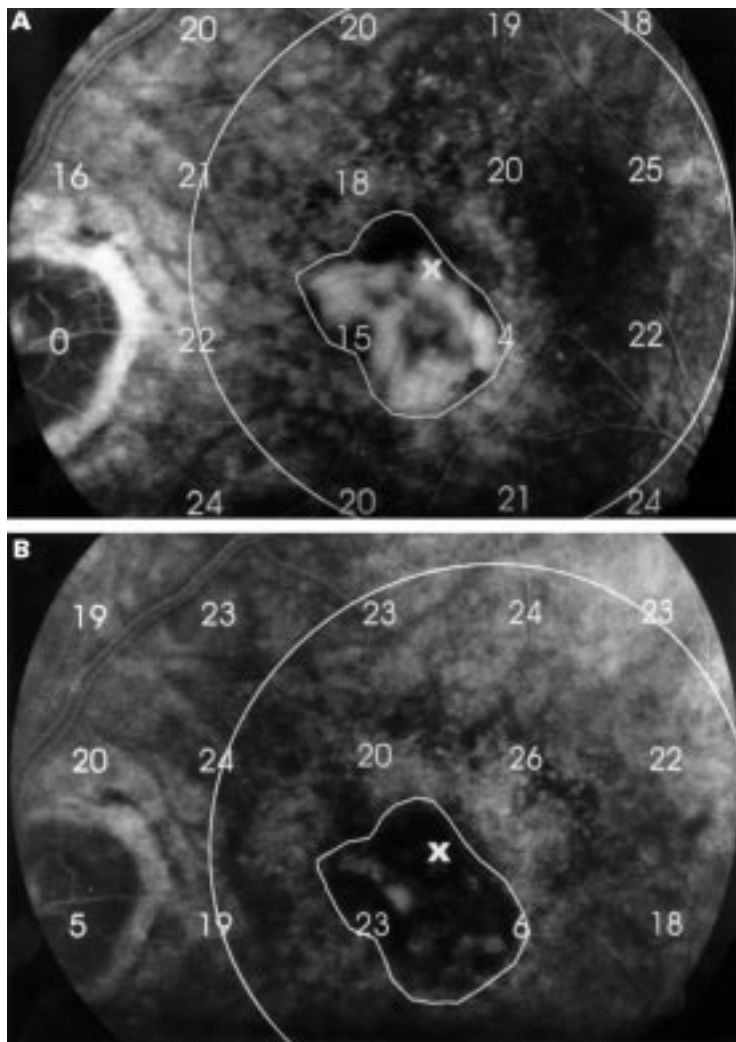


Figure 1 (A, B) Examples of visual field overlays on fluorescein angiograms. The boundaries of the choroidal neovascular membranes are delineated. The large circle corresponds to the irradiated area. A and B: baseline and 12 month follow up angiograms of patient no 2.

symptoms <3 months) subfoveal CNVM associated with AMD were studied. The calculated radiation dose used was 15 Gy at a depth of 1.75 mm. Mean age of the patients was 76.8 years (range 63–90 years). Pretreatment mean VA was 20/126 (ETDRS charts).

All 20 irradiated eyes were tested with the Octopus 2000 (Interzeag, Schlieren, Switzerland) automated static perimetry program 34 at baseline and 19 eyes at 12 months (one patient refused the examination at 12 months). The visual field of this program extends 30° from the fixation in all directions. The test conditions for program 34 include Goldmann III stimulus size (0.43°), stimulus exposure time of 100 ms, and background illumination of 4 asb (apostilb).<sup>12</sup> The scale of stimulus intensity ranges from 1000 asb to 0.1 asb. The program tests the threshold sensitivity at 76 test points with 6° resolution. The optic nerve gives a 5° absolute scotoma. The duration of the program was about 15 min/eye, with the complete testing time being 30–45 minutes. A fixation target of four light spots at 3° distance was used. The technician controls the position of the pupil in relation to a fixed centred cursor

on a video screen continuously and stops the program when the patient loses fixation.

Results were presented in standard printout form giving the absolute retinal sensitivity in decibels (dB) and in grey scales. The mean defect (MD) index, which is related to global damage and is the best measure for the general condition of the field, and loss variance (LV), the indicator for localised damage, were recorded from the whole 60° visual field of the Octopus 34 program.

False positive responses (a positive response to audible stimulus signal without actual light) and false negative responses (no response to a strong stimulus in an area where the patient showed sensitivity in prior questions), which reflect the reliability of the test, were evaluated. The reliability factor (RF) was calculated as the ratio of false positive to false negative answers. Since care should be exercised with results showing a higher than 10–15% rate of false responses<sup>12</sup> the patients with RF >15% were excluded from this study.

Fluorescein angiography and colour fundus photography (Canon CF-60Z) were performed on all 20 patients at baseline and on 19 patients at 6 month and 12 month follow up (one patient refused the angiogram at 6 and 12 months). The response of the CNVM to irradiation was based on masked evaluation of FAs, as described elsewhere.<sup>10</sup> In brief, two graders arranged the baseline, 6 month and 12 month FAs in order of increasing size and amount of leakage of the CNVM. The patients were subdivided into groups according to the type of the lesion at baseline (classic, occult, or haemorrhagic) and further into those with either regression or progression of the CNVM at 12 month follow up.

Only the FAs and colour fundus images taken at baseline and after 12 months were analysed in this study. The 30° fundus angiogram and colour photograph were projected on paper and a schematic picture was drawn delineating the areas of hyperfluorescent classic and occult CNVM, and areas of subretinal or intraretinal haemorrhage (Fig 1). The centre of the foveal avascular zone was determined. Subsequently the schematic fundus drawing was rotated horizontally and superimposed on the central visual field. The magnification of the 60° visual field was adjusted to correspond with the horizontal 30° scope of the Canon 30° fundus picture. The overlay of visual field on the fundus drawing was done by estimating the site of the scotoma caused by the optic nerve. The site of the deepest scotoma and corresponding hyperfluorescent lesion were also used in adjusting the overlay. The accuracy of the overlay was within one test point location in all patients accepted for the final analysis. The spherical aberration was not considered to affect the central 30° field.

The sensitivity values (dB) for each test point at the site of primary subretinal lesion (including the classic, occult, and haemorrhagic components) were counted for every patient at baseline. The changed sensitivity values for every test point were recorded from

Table 1 Average mean defect (MD) and loss variance (LV) values for the 60° visual field in eyes with different types of choroidal neovascular lesions at baseline and at 12 months

Type of CNVM	No of patients	MD			LV		
		at 0 months	at 12 months	p Value*	at 0 months	at 12 months	p Value*
Cl regression	8	8.1	7.6	0.60	32.8	34.5	0.80
Occ regression	3	6.7	7.6	0.60	31.9	26	0.10
<b>All regression</b>	<b>11</b>	<b>7.7 (SD 1.7)</b>	<b>7.6 (1.9)</b>	<b>0.86</b>	<b>32.6 (13.9)</b>	<b>32.4 (15.7)</b>	<b>0.94</b>
Cl progression	3	8.0	12.6	0.08	36.3	65.4	0.15
Occ progression	1	7.3	15.0		31.5	81.6	
Haem progression	1	5.4	12.6		14.5	81.3	
<b>All progression</b>	<b>5</b>	<b>7.3 (2.9)</b>	<b>13.1 (3.6)</b>	<b>0.05</b>	<b>31.0 (22.9)</b>	<b>71.8 (24.1)</b>	<b>0.017</b>
All irradiated eyes	16	7.6 (2.0)	9.3 (3.6)	0.05	32.1 (16.4)	44.6 (26.1)	0.076
Fellow eyes, no late AMD	8	4.8 (0.8)			7.0 (5.2)		
Fellow eyes, late AMD	9	10.0 (3.6)		p=0.028† p=0.145‡	53.1 (15.6)		p=0.008§ p=0.102§

CNVM = choroidal neovascular membrane; Cl = classic; Occ = occult; Haem = haemorrhagic.

\*Paired *t* test.

†Compared with eyes with regression of CNVM at 12 months, Mann-Whitney rank sum test.

‡Compared with eyes with progression of CNVM at 12 months, *t* test.

§Compared with eyes with regression of CNVM at 12 months, *t* test.

§Compared with eyes with progression of CNVM at 12 months, *t* test.

the 12 month visual field. The whole retinal area being irradiated by the strontium-90 plaque was evaluated by drawing a circle corresponding to the diameter of the strontium plaque. The nasal margin of the circle was extended to one half disc diameter from the optic disc. The retinal sensitivity outside the AMD lesion but within the irradiated retina was evaluated. Also the amount and direction of sensitivity change at every test point in the irradiated area was calculated at baseline and at 12 months.

The patients gave their written informed consent to participate the study. The study protocol followed the tenets of the declaration of Helsinki and was accepted by the local institutional ethics committee.

The changes in mean retinal sensitivity were calculated using paired and unpaired *t* tests or non-parametric tests, as indicated by the data being analysed.

## Results

Fourteen out of 20 patients (70%) had a classic subfoveal CNVM, four (20%) had occult CNVM, and two (10%) had a haemorrhagic subfoveal lesion. The size of the primary CNVM lesion was >1 disc area (DA) for all except one patient and >2 DA for 13 out of 20 patients.

At 12 months, CNVM was partially or totally regressed in 14 out of 19 (74%) irradiated patients (FA was not obtained for one patient at 12 months). The neurosensory detachment dried in 14 out of 20 patients (70%). Two patients had retinal pigment epithelium (RPE) tear. The medium VA at 1 year was 20/200 with a mean decrease of 2.6 lines. VA improved two to three lines in two patients (10%) and remained the same (within one line) in seven patients (35%). Three out of 19 patients were excluded from the analysis having RF >15% either at baseline or at 12 month follow up. These eyes included one with haemorrhagic and two with classic lesions, all showing regression of the CNVM at 12 months.

The average MD value of the 60° visual field for all of the material was 7.6 (2.0) at baseline and 9.3 (3.6) after 12 months ( $p = 0.05$ )

(Table 1). The corresponding MD values calculated separately for patients with regression of the CNVM at 12 months were 7.7 and 7.6 ( $p = 0.86$ ), and for patients with progression of the CNVM at follow up 7.3 and 13.1 ( $p = 0.05$ ). The average LV value in all patients was 32.1 (16.4) at baseline and 44.6 (26.1) at 12 months. In patients with regression of the CNVM at follow up, the corresponding LV values were 32.6 and 32.4 ( $p = 0.94$ ). In patients with progression of the CNVM, the LV value was 31.0 at baseline and 71.8 after 12 months ( $p = 0.017$ ). The results for different subgroups are shown in Table 1.

We also analysed the mean retinal sensitivity in the area of the whole active AMD lesion (that is, the area including the classic, occult, and the haemorrhagic components) at baseline and the same area (same number of test points and same location) at 12 months. The mean sensitivity in patients with a regression of the CNVM was 10.3 (6.4) dB at baseline and 9.4 (7.3) dB at 12 months ( $p = 0.58$ ). In patients with a progressing CNVM the mean sensitivity was 9.9 (4.6) dB at baseline and 1.0 (1.1) dB at 12 months ( $p = 0.019$ ). The changes in the mean retinal sensitivity for different groups (primary classic, occult, or haemorrhagic lesion) are presented in detail in Table 2. The mean sensitivity values are also presented separately for each individual patient. The net decrease in mean retinal sensitivity was 8.9 dB in all patients with a progression of the CNVM, but only 0.9 dB in patients with a regression of the CNVM at follow up ( $p = 0.011$ ). Retinal sensitivity improved in the primary lesion area in five out of 11 patients with regression of the CNVM at follow up.

To find out the possible effect of irradiation on "normal" retina, apparently unaffected by the exudative AMD, we evaluated retinal sensitivities in the areas covered by the strontium-90 plaque, but appearing clinically and morphologically normal throughout the follow up. Since the disciform lesion or neurosensory detachment covered the whole irradiated area at 12 months in many of the patients with progression of the CNVM, sensitivities for unaffected irradiated retina could be calculated in only 10 patients. In these patients the mean

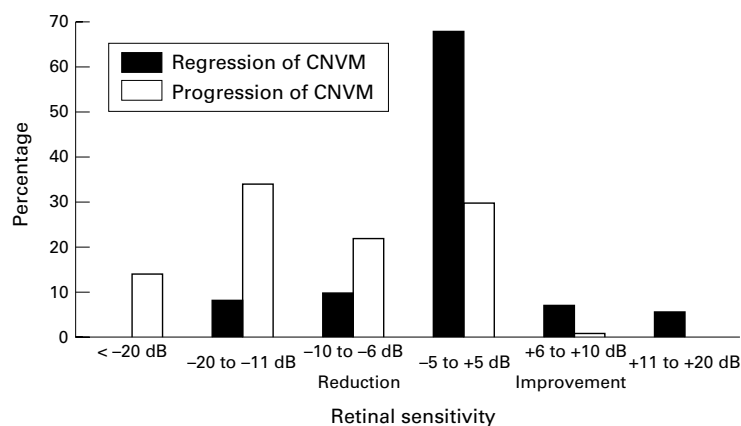


Figure 2 The sensitivity change from baseline to 12 months at each individual point in the whole irradiated area. The x axis represents the change of sensitivity in decibels, negative values representing reduction in retinal sensitivity and positive values improvement in retinal sensitivity. The y axis represents the changed points as percentages of the total number of points.

retinal sensitivity was 21.5 (2.4) dB at baseline and 19.7 (3.0) dB at 12 months ( $p = 0.10$ ) in irradiated but normal retinal areas.

The sensitivity change was calculated separately at each individual test point in the whole irradiated area (thus including the entire lesion area). In patients with regression of the membrane, the retinal sensitivity remained unchanged (within 5 dB) in most (68%) of the test points in the irradiated area, or even improved 6–20 dB in 20% of points (Fig 2). In patients with a progressive AMD lesion, the sensitivity decreased in 69% of points and remained unchanged in 30% of points. The mean sensitivity in the area covered by the strontium-90 plaque in patients with regression of the CNVM was 16.3 (3.0) dB at baseline and 15.7 (3.3) dB at 12 months ( $p = 0.68$ ). In patients with progression of the

CNVM, the corresponding values were 16.2 (3.9) dB at baseline and 5.2 (4.2) dB at 12 months ( $p = 0.002$ ).

We also performed automatic perimetry on the fellow eyes of the irradiated eyes. Since all the fellow eyes retained unchanged visual acuity and clinical appearance during the follow up, the perimetry with the best reliability factor was chosen for further analysis. The mean retinal sensitivity was better in the fellow eyes with no late AMD than in any of the groups with exudative AMD. In the fellow eyes with late AMD, the mean sensitivity values tended to be lower than in strontium treated eyes with regression of the CNVM, whereas they appeared better than those of strontium treated eyes with progression of the CNVM at 12 months (Table 2). A similar pattern was evident for the corresponding MD and LV values (Table 1).

## Discussion

These results indicate that treatment with focal strontium irradiation can stabilise the central visual field in some patients with subfoveal CNVMs related to AMD. Mean retinal sensitivity remained unchanged in the area of primary subretinal neovascular lesion in most of the patients showing regression of the membrane 12 months after irradiation. MD and LV values of these patients did not worsen during follow up, as they did in patients with growing CNVM. There was, however, no significant improvement of retinal sensitivity in the affected areas, and some degree of central scotoma always remained. It is known that without treatment the growth of subfoveal CNVMs leads to severe loss of vision. This is accompanied with a loss of central visual field.<sup>2,3</sup> In this study, too, the growth of CNVM

Table 2 Mean sensitivity in the area of the original lesion

Patient no	Type of CNVM lesion	0 months		12 months		p Value*	Net change in mean sensitivity 0–12 months (dB)	VA	
		dB (SD)	dB (SD)	dB (SD)	dB (SD)			0 months	12 months
2	Cl regression	16 (4.6)	5.3 (4.6)				-10.7	20/160	20/400
6	Cl regression	7.8 (6.8)	12.7 (8.3)				4.9	20/126	20/640
13	Cl regression	3.6 (5)	5.6 (7.1)				2	20/160	20/320
15	Cl regression	6.3 (6.6)	4.2 (5.4)				-2.2	20/200	20/250
17	Cl regression	9.5 (7.8)	14.5 (12)				5	20/40	20/80
18	Cl regression	14.6 (3.2)	10.1 (5.8)				-4.5	20/80	20/126
19	Cl regression	14.2 (6.5)	9.2 (9.1)				-5	20/50	20/64
20	Cl regression	7 (7.8)	10.4 (7.3)				3.4	20/80	20/100
	Mean (SD)	9.9 (6.0)	9 (7.4)		0.67				
8	Occ regression	10.8 (11.2)	8.3 (8.5)				-2.5	20/500	20/250
12	Occ regression	10 (6)	6 (6.2)				-4	20/80	20/50
16	Occ regression	13.4 (4.8)	17.3 (6.4)				3.9	20/200	20/200
	Mean (SD)	11.4 (7.3)	10.5		0.75				
<b>All patients with regression of CNVM</b>		<b>10.3 (6.4)</b>	<b>9.4 (7.3)</b>		<b>0.58</b>		<b>-0.9</b>		
1	Cl progression	4.9 (5.4)	0				-4.9	20/160	20/400
3	Cl progression	17 (2.2)	3.5				-13.5	20/126	20/400
14	Cl progression	2.3 (3.1)	0				-2.3	20/50	20/640
	Mean (SD)	8.1 (3.6)	1.2 (0.9)		0.18				
11	Occ progression	9.8 (6.6)	0 (0)				-9.8	20/80	20/500
7	Haem, progression	15.8 (5.8)	1.5 (2.8)				-14.3	20/40	20/126
<b>All patients with progression of CNVM</b>		<b>9.9 (4.6)</b>	<b>1.0 (1.1)</b>		<b>0.019</b>		<b>-8.9</b>		
Fellow eyes, no late AMD (n = 8)		22.9 (0.8)					p=0.011†	20/32**	
Fellow eyes, late AMD (n = 9)		5.6 (2.9)					p=0.14‡, p<0.001§	20/400**	

CNVM = choroidal neovascular membrane; Cl = classic; Occ = occult; Haem = haemorrhagic.

\*Paired *t* test.

†*t* test.

‡Compared with eyes with regression of CNVM, *t* test.

§Compared with eyes with progression of CNVM, *t* test.

\*\*Mean visual acuity (VA).

was associated with loss of retinal sensitivity and thus deepening and widening of the central scotoma.

Perimetric changes in AMD have not been studied extensively. In patients with poor visual acuity, the instability in fixation is a major problem in obtaining reliable perimetric results. In a recent study by Tezel *et al*,<sup>7</sup> scanning laser ophthalmoscope (SLO) microperimetry was used to correlate anatomical abnormalities associated with absolute scotoma in patients with subfoveal CNVMs. Fixation was found to be stable in only 29% of patients with AMD, and the mean visual acuity in these patients with a stable fixation was as good as 20/60. Schneider *et al*<sup>5</sup> performed Humphrey automatic perimetry on patients with subfoveal neovascularisation treated with perifoveal laser photocoagulation sparing the central avascular zone. They found that central fixation was present in only 13 out of 26 patients before perifoveal laser treatment and in five patients till the end of the average follow up of 18 months. In this study the Octopus 2000 program 34 was used. The resolution of test points was 6°, which was considered to be suitable for patients with poor visual acuity. Apparently more frequent test points and a longer testing time would have increased the instability of fixation. To obtain the best possible fixation, a fixation target of four light spots was used instead of one fixation light. It is possible that in spite of the effort to control the fixation, the stability of fixation in this study may not have been as good as in regular perimetry in patients without macular disease or in SLO microperimetry, where the anatomical correlation of the tested region can be controlled in vivo. On the other hand, the 6° matrix of test points employed is quite robust in relation to macular anatomy and thus not very sensitive to small variations in fixation. Also, the easy alignment of the baseline and 12 month fields, as well as the clear correlation of the sensitivity values with clinical changes in the AMD lesion, suggest that the results reflect retinal sensitivity at the estimated sites quite accurately.

Using the SLO in patients with AMD or ocular histoplasmosis, Tezel *et al*<sup>7</sup> have found that an absolute scotoma develops in the areas of chorioretinal scar, RPE atrophy, subretinal haemorrhage, and neovascular membrane. According to the study, the absolute scotoma was 1.4 times larger than the area of the subfoveal neovascular membrane. In our study the size of the central scotoma was not separately calculated because the central scotoma became absolute only in patients with further growth of the CNVM at 12 months. Instead, in patients with regression of the membrane at follow up, all patients had some retinal function left in the area of the primary subfoveal lesion. It may be that photoreceptors can survive to some degree if the neurosensory detachment (NSD) is dried. Prevention of the disciform scar formation can also improve the function of retinal pigment epithelium.

There are few studies with follow up examinations of the central visual field after laser photocoagulation of CNVMs. In the study of

Nichols *et al*<sup>4</sup> seven patients were analysed with Octopus perimetry (using a specially designed 14° Sargon program) before and 3 months after the laser photocoagulation of extrafoveal CNVMs. There was a net negative change (reduction in retinal sensitivity) of 5.6 (SD 1.6) dB/area units in all patients after follow up.

In our study, net change in mean retinal sensitivity in the primary lesion area was a reduction of 8.9 dB in patients with progression of the CNVM at 12 months. However, in patients with regression of the CNVM and drying of the NSD, the net change in mean sensitivity was negligible. Schneider *et al*<sup>5</sup> treated 26 patients having large subfoveal CNVMs with a perifoveal krypton laser. In their study, the size and depth of the central scotoma increased in all patients after laser treatment. In patients with central fixation before treatment, the average loss of sensitivity was 15–25 dB already at baseline and the depth in the central scotoma increased immediately after laser treatment and over the next 1–2 years. In our study, the mean sensitivity in the CNVM area had declined to a level of 10 dB at baseline (meaning the average loss of 15–20 dB compared with normal age corrected values), but in patients with regression of the CNVM, the depth in the relative scotoma had not deepened significantly at 12 months. Instead, in patients with progression of the CNVM, the scotoma usually deepened to absolute scotoma.

Recently, Chakravarthy *et al*,<sup>13</sup> Bergink *et al*,<sup>14</sup> and Finger *et al*<sup>15</sup> have reported visual and anatomical results after external beam irradiation to exudative AMD. Although non-randomised, their studies have indicated stabilisation of VA after radiotherapy for the CNVM, especially in patients with regression of the CNVM. Perimetric evaluation was not performed in these studies but the stabilisation of VA after radiotherapy is in agreement with our finding of unchanged retinal sensitivity in patients with regression of the CNVM. Although the estimated exposure of the retina to radiation in strontium plaque therapy was lower than the reported threshold for radiation retinopathy,<sup>16</sup> the risk of radiation induced damage to the retina in this kind of treatment has to be taken into account. Such damage may take more than 12 months to develop. But our findings on unchanged retinal sensitivities in the irradiated retina outside the AMD lesion confirm our clinical impression that the radiation dose employed is not harmful to the normal retina during 12 month follow up.

This work was supported by grants from the Eye Foundation (Silmäsäätiö), Finland, Clinical Research Institute of the Helsinki University Central Hospital, and the Uulo Aarho Foundation, Finland.

- 1 Bressler NM, Bressler SB, Gragoudas ES. Clinical characteristics of choroidal neovascular membranes. *Arch Ophthalmol* 1987;105:209–13.
- 2 Bressler SB, Bressler NM, Fine SL, *et al*. Subfoveal neovascular membranes in senile macular degeneration. *Retina* 1983;3:7–11.
- 3 Boldrey EE. Foveal ablation for subfoveal choroidal neovascularization. *Ophthalmology* 1989;96:1430–6.

- 4 Nichols PF, Charles HC, Read JS, *et al.* Evaluation of choroidal neovascular membranes by Octopus perimetry. *Retina* 1988;**8**:24–9.
- 5 Schneider U, Kuck H, Kreissig I. Fixation and central visual field after perifoveal krypton laser treatment of subfoveal neovascularizations. *Eur J Ophthalmol* 1993;**3**:193–200.
- 6 Avila MP, Jalkh AE, Mainster MA, *et al.* Photofield mapping in the evaluation and management of subretinal neovascularization. *Ann Ophthalmol* 1985;**17**:13–19.
- 7 Tezel TH, Del Priore LV, Flowers BE, *et al.* Correlation between scanning laser ophthalmoscope micropertimetry and anatomic abnormalities in patients with subfoveal neovascularization. *Ophthalmology* 1996;**103**:1829–36.
- 8 Macular Photocoagulation Study Group. Laser photocoagulation of subfoveal neovascular lesions in age-related macular degeneration. *Arch Ophthalmol* 1991;**109**:1220–31.
- 9 Moisseiev J, Alhalel A, Masuri R, *et al.* The impact of the macular photocoagulation study results on the treatment of exudative age-related macular degeneration. *Arch Ophthalmol* 1995;**113**:185–9.
- 10 Jaakkola A, Heikkonen J, Tommila P, *et al.* Strontium plaque irradiation of subfoveal neovascular membranes in age-related macular degeneration. *Graefes Arch Clin Exp Ophthalmol* 1998;**236**:24–30.
- 11 Immonen I, Jaakkola A, Heikkonen J, *et al.* Strontium plaque irradiation of subfoveal CNVMs in age-related macular degeneration. (ARVO Abstracts) *Invest Ophthalmol Vis Sci* 1997: 447.
- 12 *Octopus visual field digest*. 01/96 Interzeag AG, Schlieren, Switzerland.
- 13 Chakravarthy U, Houston RF, Archer DB. Treatment of age-related subfoveal neovascular membranes by teletherapy: a pilot study. *Br J Ophthalmol* 1993;**77**:265–73.
- 14 Bergink GJ, Deutman AF, van den Broek JFCM, *et al.* Radiation therapy for subfoveal choroidal neovascular membranes in age-related macular degeneration. A pilot study. *Graefes Arch Clin Exp Ophthalmol* 1994;**232**:591–8.
- 15 Finger PT, Berson A, Sherr D, *et al.* Radiation therapy for subretinal neovascularization. *Ophthalmology* 1996;**103**: 878–89.
- 16 Parsons JT, Fitzgerald CR, Hood CI, *et al.* The effects of irradiation on the eye and optic nerve. *Int J Radiation Oncology Biol Phys* 1983;**9**:609–22.



## Correlation between Octopus perimetry and fluorescein angiography after strontium-90 plaque brachytherapy for subfoveal exudative age related macular degeneration

Aino Jaakkola, Eija Vesti and Ilkka Immonen

*Br J Ophthalmol* 1998 82: 763-768

doi: 10.1136/bjo.82.7.763

---

Updated information and services can be found at:

<http://bjo.bmj.com/content/82/7/763.full.html>

---

*These include:*

### References

This article cites 13 articles, 4 of which can be accessed free at:

<http://bjo.bmj.com/content/82/7/763.full.html#ref-list-1>

Article cited in:

<http://bjo.bmj.com/content/82/7/763.full.html#related-urls>

### Email alerting service

Receive free email alerts when new articles cite this article. Sign up in the box at the top right corner of the online article.

---

### Topic Collections

Articles on similar topics can be found in the following collections

[Retina](#) (1217 articles)

---

### Notes

---

To request permissions go to:

<http://group.bmj.com/group/rights-licensing/permissions>

To order reprints go to:

<http://journals.bmj.com/cgi/reprintform>

To subscribe to BMJ go to:

<http://group.bmj.com/subscribe/>