

Commentary

Sense and nonsense of corticosteroid administration in the treatment of ocular toxoplasmosis

There is no consensus about the use of corticosteroids for the treatment of ocular toxoplasmosis. In clinical practice, corticosteroids are usually given in combination with antiparasitic drugs to reduce the inflammatory reaction during active chorioretinitis and to minimise tissue damage.¹ Specifically, in the case of pericentral location, this presumed effect might help to retain central visual acuity and limit scotomas. However, the use of corticosteroids can lead to progression of the underlying infectious disease, as repeatedly demonstrated by the occurrence of fulminant ocular toxoplasmosis following both systemic and periocular administration (Fig 1).^{2–8} On the other hand, low dose corticosteroid monotherapy has been administered without severe side effects.¹ To our knowledge, a well defined study of the effect of corticosteroid monotherapy in ocular toxoplasmosis as well as the additional value of corticosteroids as adjuvant therapy has not been performed. Thus, the use of corticosteroids for the treatment of ocular toxoplasmosis is controversial, and the timing and dosages during the course of the disease are not well defined.

During an acute infection with *Toxoplasma gondii*, oocysts ingested by the host give rise to the extracellular forms (tachyzoites), which actively penetrate host cells and replicate; subsequently the disease enters the chronic stage when cysts are formed.⁹ The signal for formation of cysts is not known; the onset and the quality of the host immune response may be an important factor.⁹ The mechanism of chronic recurrent ocular toxoplasmosis is unknown; it is presumed that the multiplication of parasites, liberated from the cysts, causes damage to adjacent retinal tissue.⁹ The hypothesis of autoimmunity, directed against retinal S-antigen, has not been proved unequivocally.^{10–11} In fact, the interaction between *T gondii* and the competent immune system does not lead to parasite elimination, but to a reduction in parasite load and changes in morphology and surface antigen expression.

Host response and effect of corticosteroids on *T gondii* infection

T cell mediated immunity plays a major role in resistance against toxoplasmosis and probably also controls brain cyst formation; B cell mediated humoral immunity is not protective.^{12–13} CD8+ T cells are the principal mediators of resistance against acute toxoplasmosis by means of their cytotoxic activity and the secretion of cytokines, including interferon γ (IFN- γ), which plays a crucial role in the response to *T gondii*.¹³

The effects of corticosteroids on the immune system are complex, and not completely understood.¹⁴ The anti-inflammatory and immunosuppressive effects of corticosteroids are linked to changes in cellular immunity and attributed mainly to inhibition of communication among leucocytes responsible for production and action of cytokines. In low doses, corticosteroids dramatically inhibit exudation of plasma and accumulation of leucocytes at sites of inflammation and suppress cellular immune response.¹⁵ As a consequence they influence the production of IFN- γ and IL-2 by T cells, the effect of

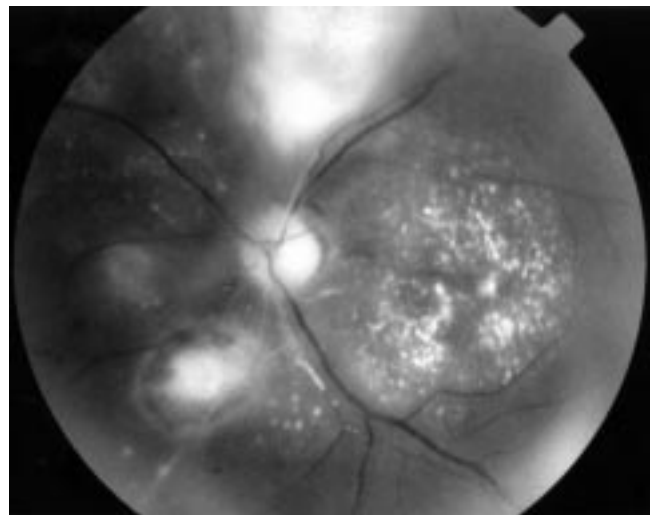


Figure 1 A 23 year old male patient with fulminant toxoplasmic chorioretinitis following periocular corticosteroid injection. Note the multiple lesions, pronounced vasculitis (arteriitis), and extensive exudation in the macular area.

IFN- γ on macrophages, and the interaction of IL-2 with its receptor on activated T cells. The effect on cellular immune response is dose dependent.¹⁶ Corticosteroids have a minor effect on antigen stimulated B cells and plasma cells.¹⁴ Higher doses are required to retard the processing and presentation of antigens by monocytes and macrophages, to inhibit natural killer cell function, and to inhibit the release of tumour necrosis factor by activated macrophages. The compromised leucocyte function counteracts the intracellular destruction of parasites and may lead to unrestrained replication of parasites.

An inadequate cell mediated immunity (specifically in patients with AIDS and during iatrogenic immunosuppression) leads to severe, sometimes fatal toxoplasmic infections and is associated with reactivations of latent disease. Although intact tissue cysts were reported not to evoke an inflammatory response, shedding of parasites from tissue cysts was described.¹⁷ It might be possible that, in patients with an insufficient cellular immunity, these escaped parasites may replicate and cause reactivation. Aging is also associated with a decline in cell mediated immunity (especially CD8+ T cells).¹⁸ Severe ocular toxoplasmosis in elderly patients has been attributed to the above mentioned reduction of cell mediated immunity in the elderly.¹⁹

Effect of corticosteroids on toxoplasmosis: animal studies

A lethal effect of corticosteroids in acute toxoplasmosis was found in the majority of animal studies (mice and rabbits)^{20–24}; however, the therapy also induced less effective resistance to subsequent reactivations.²² In contrast with untreated animals, in corticosteroid treated mice with acute toxoplasmosis, persistence of free parasites together with cysts in the brain and lung tissue was observed.^{20–21} Furthermore, cyst formation in the brain

Table 1 Administration of corticosteroids without antiparasitic drugs to patients with ocular toxoplasmosis

	No of patients	Age at onset >50 years No (%)	Evidence for primary acquired infection		Corticosteroid administration		Retinal scars > 3 PD No (%)	Legal blindness of affected eye No (%)
			Laboratory No (%)	Clinical* No (%)	Systemic No (%)	Periocular No (%)		
Literature survey†	16	10 (63)	NS	9 (56)	15 (94)	6 (38)	11 (69)	12 (75)
Present study	10	6 (60)	6(60)	7 (70)	8 (80)	6 (60)	5 (50)	7 (70)
Total	26	16 (62)		16 (62)	23 (88)	12 (46)	16 (62)	19 (73)

*Chorioretinitis without associated old scars.

†See references 2–8; three patients received additional medication (two azathioprine, one sulphisoxazole respectively); five patients received systemic and periocular steroids.

‡Four patients received systemic and periocular steroids.

NS= not specified.

started earlier and was more prolific in corticosteroid treated mice.²² However, corticosteroid treated rabbits with ocular toxoplasmosis had localised retinal lesions with preservation of normal tissue in contrast with non-treated animals in which retinal destruction was considerably more massive and areas of normal retina were not encountered.²³

In studies assessing the effect of corticosteroids in chronic toxoplasmosis, the majority of the corticosteroid treated animals died while untreated animals survived.^{21 22 24 25} Administration of corticosteroids to animals with chronic toxoplasmosis resulted in reactivation of the disease, generally leading to fatal encephalitis or pneumonia; the latter was characterised by the absence of an inflammatory reaction on histological examination.^{24 26} Frequent relapses of toxoplasmic chorioretinitis were reported in corticosteroid treated hamsters with chronic disease.²⁴ It was suggested that corticosteroids, because of their effect on the immune system, trigger rupture of the cysts followed by dissemination of parasites to adjacent tissues and other organs, thus causing chronic relapsing disease.^{25 27} In contrast, small numbers of animals treated with corticosteroids exhibited no changes in their ocular or systemic symptoms.²³

Effect of corticosteroids on toxoplasmosis: human studies

Various case reports provide information on the effects of corticosteroids in human ocular toxoplasmosis. In the past, duration and the number of recurrences were not different for 10 patients with presumed toxoplasmic chorioretinitis treated with low dose systemic corticosteroids compared with 10 patients treated with antiparasitic drugs together with corticosteroids.²⁸ In contrast, destructive and disseminated ocular toxoplasmosis was repeatedly demonstrated in case reports of presumably immunocompetent patients (n=16) after administration of corticosteroids without a shield of antiparasitic drugs (Table 1).^{2–8} We examined 10 additional patients with fulminant ocular toxoplasmosis following monotherapy with corticosteroids (Table 1).

Many of corticosteroid treated patients were initially not recognised as having toxoplasmosis (recent series 4/10; literature 8/16; total 12/26); in 4/26 patients (2/10 in the present series) corticosteroid therapy was given for an unrelated systemic disease. The remaining patients (10/26) were known to have toxoplasmic retinitis but received corticosteroids without an antiparasitic shield anyway.

Legal blindness (visual acuity less than 0.1) in at least one eye developed in 19 of 26 reported patients (73%). Recurrent disease occurred subsequently in four of our 10 patients (40%); the number of recurrences among the previously reported 16 patients is unknown. The dosages of administered corticosteroids varied between 20 mg and 150 mg per day (or were not specified). The eventual relation of ocular disease to the dosage of corticosteroids used cannot be assessed and therefore it is not possible to define something as a "safe dose".

Laboratory evidence of primary infection was found in the present series for six of 10 patients (60%): four with positive IgM titres, two additional patients had an initial serum IgG titre <1:512 which increased within 4 weeks to 1:4096 in both cases. It was not possible to evaluate the frequency of primary infection for previously reported patients. An absence of retinal scars, suggesting a primary infection, was noted however for 9/16 of these patients (61%).

Although toxoplasmic chorioretinitis is more common during the second and third decades of life, 16/26 patients (61%) were older than 50 years. Severe toxoplasmic retinitis resembling herpetic retinitis was recently described in seven elderly patients.^{19 29} The authors hypothesised that the susceptibility of older patients to severe toxoplasmic chorioretinitis may be due to the previously mentioned age related decrease in immunological resistance, which might also have played a role in our patients.¹⁹ It is noteworthy that the initial diagnosis was acute retinal necrosis in four of the 10 present cases (40%). The advanced age of the patients together with severe and atypical retinitis, may explain why toxoplasmosis was not suspected and initially misdiagnosed. In the past, eight eyes of patients treated with corticosteroids were examined histologically with consistent results—large areas of necrotic tissue with multiple cysts, located between the necrotic retina and remnants of normal tissue. In the necrotic regions were numerous free parasites without an inflammatory reaction.^{2 3 6–8}

Evaluation of the efficacy of corticosteroids as an adjunct to antiparasitic regimens has never been performed. Studies addressing the efficacy of multiple therapies were not designed for evaluation of the effects of corticosteroids. However, no adverse effects of additional corticosteroids were noted.^{30 31} No differences in onset of inactivity were seen between patients treated with pyrimethamine and sulphadiazine with or without added corticosteroids, even at high doses in a study by Fajardo *et al.*³² In a meta-analysis of three studies, involving 134 patients altogether (antiparasitic therapy without corticosteroids in 16 cases and with corticosteroids in 118 cases), no striking differences were found in the duration of activity.^{33–35} Although occasionally a poor ocular outcome was reported, this might be explained by the bias of added corticosteroids in a selected group of patients with extremely severe inflammation. Similar visual outcomes were found for patients treated with antiparasitic drugs with and without corticosteroids in a retrospective non-randomised study of 75 patients.³⁶

In conclusion, our results confirm the case report based assumption that in ocular toxoplasmosis corticosteroids, whether given systemically or periocularly, should be administered with a shield of antiparasitic drugs, especially if the patients are elderly or exhibit evidence of a primary infection. Owing to its frequent atypical clinical features, it is important to include the possibility of ocular

toxoplasmosis in the differential diagnosis for elderly patients. Further research is indicated to evaluate the beneficial effect of corticosteroids in combination therapy.

Supported in part by the Dr F P Fischer Foundation, Netherlands.

E H BOSCH-DRIESSEN
A ROTHOVA

Donders Institute of Ophthalmology, University Hospital Utrecht, Utrecht, Netherlands

Correspondence to: E H Bosch-Driessen, Donders Institute of Ophthalmology, University Hospital Utrecht, E-03-136, Heidelberglaan 100, 3584 CX Utrecht, Netherlands.

- Engstrom RE Jr, Holland GN, Nussenblatt RB, *et al.* Current practices in the management of ocular toxoplasmosis. *Am J Ophthalmol* 1991;111:601-10.
- Sabates R, Pruett RC, Brockhurst RJ. Fulminant ocular toxoplasmosis. *Am J Ophthalmol* 1981;92:497-503.
- Pauleikhoff D, Messmer E, Beelen DW, *et al.* Bone marrow transplantation and toxoplasmic retinochoroiditis. *Graefes Arch Clin Exp Ophthalmol* 1987;225:239-43.
- Gallino A, Maggiorini M, Kiowski W, *et al.* Toxoplasmosis in heart transplant recipients. *Eur J Clin Microbiol Infect Dis* 1996;14:389-93.
- Morhun PJ, Weisz JM, Elias SJ, *et al.* Recurrent ocular toxoplasmosis in patients treated with systemic corticosteroids. *Retina* 1996;16:383-7.
- Nicholson DH, Wolchock EB. Ocular toxoplasmosis in an adult receiving long-term corticosteroid therapy. *Arch Ophthalmol* 1976;94:248-54.
- Crawford JB, Bethesda. Toxoplasma retinochoroiditis. *Arch Ophthalmol* 1966;76:829-32.
- Benson MT, Parsons MA, Talbot JF, *et al.* Aggressive toxoplasma retinitis. *Acta Ophthalmol* 1992;70:795-800.
- Pavesio CE, Lightman S. Toxoplasma gondii and ocular toxoplasmosis: pathogenesis. *Br J Ophthalmol* 1996;80:1099-107.
- Nussenblatt RB, Mittal KK, Fuhrman S, *et al.* Lymphocyte proliferative responses of patients with ocular toxoplasmosis to parasite and retinal antigens. *Am J Ophthalmol* 1989;107:632-41.
- Kijlstra A. Humoral and cellular immune reactions. *Curr Eye Res (suppl)* 1996;9:85-9.
- Sher A, Denkers EY, Gazzinelli RT. Induction and regulation of host cell-mediated immunity by Toxoplasma gondii. *Ciba Found Symp* 1995;195:95-104; discussion 104-9.
- Däubener W, Hadding U. Cellular immune reactions directed against Toxoplasma gondii with special emphasis on the central nervous system. *Med Microbiol Immunol* 1997;185:195-206.
- Goodman-Gilman A. *The pharmacological basis of therapeutics*. Vol II. Singapore: McGraw-Hill, 1992;1439-57.
- Boumpas DT, Chrousos GP, Wilder RL, *et al.* Glucocorticoid therapy for immune-mediated diseases: basic and clinical correlates. *Ann Intern Med* 1993;119:1198-208.
- Cupps TR, Fauci AS. Corticosteroid-mediated immunoregulation in man. *Immunol Rev* 1982;65:133-55.
- Wong S, Remington JS. Biology of Toxoplasma gondii. *AIDS* 1993;7:299-316.
- Hirokawa K. Understanding the mechanism of the age related decline in immune function. *Nutr Rev* 1992;50:361-6.
- Johnson MW, Greven GM, Jaffe GJ, *et al.* Atypical, severe toxoplasmic retinochoroiditis in elderly patients. *Ophthalmology* 1997;104:48-57.
- Hofflin JM, Conley FK, Remington JS. Murine model of intracerebral toxoplasmosis. *J Infect Dis* 1987;155:550-6.
- Sumyuen MH, Garin YJF, Derouin F. Effect of immunosuppressive drug regimens on acute and chronic murine toxoplasmosis. *Parasitol Res* 1996;82:681-6.
- Stahl W, Matsubayashi H, Akao S. Modification of subclinical toxoplasmosis in mice by cortisone, 6-mercaptopurine and splenectomy. *Am J Trop Hyg* 1966;15:869-74.
- Kaufman HE. The effect of corticosteroids on experimental ocular toxoplasmosis. *Am J Ophthalmol* 1960;50:919-25.
- Frenkel JK, Nelson BM, Arias-Stella J. Immunosuppression and toxoplasmic encephalitis, clinical and experimental aspects. *Human Pathol* 1975;6:97-111.
- Chinchill AM, Guerrero OM, Catarinella G, *et al.* Natural and induced blood dissemination of toxoplasma gondii: experimental model in white mice and hamsters. *Rev Biol Trop* 1993;41:197-202.
- Frenkel JK. Pathogenesis of toxoplasmosis and of infections with organisms resembling toxoplasma. *Ann NY Acad Sci* 1956;115:215-51.
- Odaert H, Soete M, Fortier B, *et al.* Stage conversion of Toxoplasma gondii in mouse brain during infection and immunodepression. *Parasitol Res* 1996;82:28-31.
- Acers TE. Toxoplasmic retinochoroiditis: a double blind therapeutic study. *Arch Ophthalmol* 1964;71:58-61.
- Ronday MJH, Luyendijk L, Baarsma GS, *et al.* Presumed acquired ocular toxoplasmosis. *Arch Ophthalmol* 1995;113:1524-9.
- Lam S, Tessler H.H. Quadruple therapy for ocular toxoplasmosis. *Can J Ophthalmol* 1993;28:58-61.
- Rothova A, Meenken C, Buitenhuis HJ, *et al.* Therapy for ocular toxoplasmosis. *Am J Ophthalmol* 1993;115:517-23.
- Fajardo RV, Furgiuele FP, Leopold IH. Treatment of toxoplasmosis uveitis. *Arch Ophthalmol* 1962;67:712-20.
- Ghosh M, Levy PM, Leopold IH. Therapy of toxoplasmosis uveitis. *Am J Ophthalmol* 1963;55-61.
- Guldsten H. Clindamycin and sulphonamides in the treatment of ocular toxoplasmosis. *Acta Ophthalmol* 1983;61:51-7.
- Lakhanpal V, Schocket SS, Nirankari VS. Clindamycin in the treatment of toxoplasmic retinochoroiditis. *Am J Ophthalmol* 1983;95:605-13.
- Damms T, Bohnke M, Behrend-Berdin B. Ergebnisse der therapie bei okularer toxoplasmose. *Ophthalmologe* 1993;90:737-41.



Sense and nonsense of corticosteroid administration in the treatment of ocular toxoplasmosis

E H BOSCH-DRIESSEN and A ROTHOVA

Br J Ophthalmol 1998 82: 858-860

doi: 10.1136/bjo.82.8.858

Updated information and services can be found at:
<http://bjo.bmj.com/content/82/8/858.full.html>

These include:

References

This article cites 29 articles, 6 of which can be accessed free at:
<http://bjo.bmj.com/content/82/8/858.full.html#ref-list-1>

Article cited in:

<http://bjo.bmj.com/content/82/8/858.full.html#related-urls>

Email alerting service

Receive free email alerts when new articles cite this article. Sign up in the box at the top right corner of the online article.

Notes

To request permissions go to:

<http://group.bmj.com/group/rights-licensing/permissions>

To order reprints go to:

<http://journals.bmj.com/cgi/reprintform>

To subscribe to BMJ go to:

<http://group.bmj.com/subscribe/>