

Effects of short term increase of intraocular pressure on optic disc cupping

Augusto Azuara-Blanco, Alon Harris, Louis B Cantor, Marcio M Abreu, Monika Weinland

Abstract

Aims—To evaluate the effect of acute elevation of intraocular pressure (IOP) on optic disc cupping.

Methods—10 emmetropic and 10 myopic volunteers were included in this study. The cup area (CA) and cup volume (CV) of the optic disc were determined with the Heidelberg retina tomograph (HRT). After baseline determinations, a suction cup was used to increase the intraocular pressure (IOP) to 20–25 mm Hg above the baseline and HRT images were obtained.

Results—Baseline IOP was 13.5 (SD 1.3) mm Hg and 12.6 (2.6) mm Hg in the emmetropic and myopic groups, respectively. The IOP was elevated to 35.4 (3.3) mm Hg and 34.4 (2.5) mm Hg in the emmetropic and myopic groups, respectively. When compared with their baseline values, the cupping variables (CA and CV) were significantly increased ($p < 0.05$) during the suction treatment in both emmetropic and myopic subjects.

Conclusion—There was a significant enlargement in the optic disc cupping during the artificial increment of intraocular pressure in both emmetropic and myopic eyes. In non-glaucomatous eyes the optic nerve head has a partially dynamic topography dependent upon the level of IOP.

(*Br J Ophthalmol* 1998;82:880-883)

Materials and methods

Ten white emmetropic volunteers (nine right eyes, one left eye; mean age 27.8 (SD 8.4) years, range 22–45 years) and 10 white myopic subjects (nine right eyes, one left eye; mean age 28.9 (6.5) years, range 22–40 years), who had a mean refractive error of -5.7 (1.86) dioptres (range -3.0 to -8.5 dioptres), were studied. The exclusion criteria included a family history of glaucoma, previous ocular surgery or chronic eye disease, intraocular pressure > 21 mm Hg, glaucoma-like optic disc (by direct ophthalmoscopy: rim notching, cup/disc ratio > 0.7 , or asymmetry between the two optic discs), and best corrected visual acuity worse than 20/25.

The methods of this study were approved by the Indiana University institutional review board and informed consent was obtained from the participants. The IOP was measured with a Tono-Pen tonometer (Mentor O & O, Norwell, MA, USA). The Tono-Pen was calibrated before each day of use as per the instruction manual. Tono-Pen tonometry was then carried out to obtain a measurement of the highest reliability (SEM $< 5\%$ of the average). If the digital display indicates less than the highest reliability, the procedure was repeated until the highest reliability was achieved.

Images of the optic disc were obtained with the Heidelberg retina tomograph (HRT) (Heidelberg Instruments, Heidelberg, Germany). The HRT is based on the principle of confocal detection. The instrument has been described in detail.¹²⁻¹⁴ It is a confocal scanning diode (670 nm) laser ophthalmoscope that obtains topographic images as a series of 32 optical sections at consecutive focal planes. The image consists of 256×256 pixels, each pixel corresponding to the retinal height at that location. In this study three HRT images were obtained (see below) at each setting with a 10 degree field of view. A mean image was created from the three images (before and after increased IOP) and used in the analyses. For each eye the optic disc margin was outlined along the inner margin of the scleral ring by a trained operator. This contour line was stored, and the same line was used to analyse the images of the same eye obtained during suction by importing the previously stored line. The import function of a previously stored contour line was done automatically by the software, and without examiner's input. The reference plane was located 50 μm posterior to the mean height of the disc margin contour line in a temporal peripapillary segment between 350 and 356 degrees. The total area of those parts

It is believed that the axonal damage in glaucoma occurs in the optic nerve head near the lamina cribrosa.^{1,2} A displacement of the lamina cribrosa after artificial changes of intraocular pressure (IOP) in enucleated human eyes^{3,4} as well as in living monkey eyes^{5,6} has been recognised and quantified. However, the role of IOP dependent acute displacements of the optic nerve head tissues (that is, compliance of the optic disc) in the pathogenesis of glaucomatous damage is not entirely known.

Other studies in glaucomatous eyes also suggest that the tissues of the optic disc have viscoelastic properties. The optic disc cupping in patients with glaucoma can present reversible changes after lowering the IOP. The mechanisms and clinical consequences of the reversibility of glaucomatous cupping are unknown.⁷⁻¹¹

The influence of IOP on optic disc topography in healthy living human eyes has not been well established. The purpose of this study was to assess whether acute changes in IOP affect the cupping of the optic nerve head in non-glaucomatous emmetropic and myopic subjects.

Department of
Ophthalmology,
Nottingham University
Medical School,
Nottingham
A Azuara-Blanco

Department of
Ophthalmology,
Indiana University
School of Medicine,
Indianapolis, Indiana,
USA
A Azuara-Blanco
A Harris
L B Cantor

Department of
Physiology and
Biophysics, Indiana
University School of
Medicine,
Indianapolis, Indiana,
USA
A Harris
M M Abreu
M Weinland

Correspondence to:
Alon Harris, PhD,
Department of
Ophthalmology, 702 Rotary
Circle, Indianapolis, IN
46202-5175, USA.

Accepted for publication
26 February 1998

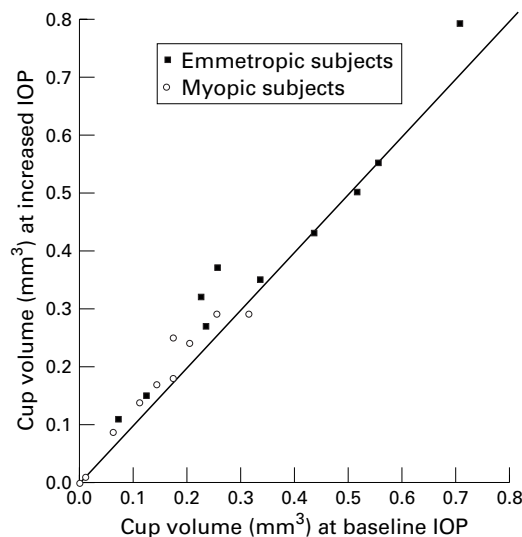


Figure 1 Heidelberg retina tomograph values of cup volume.

within the disc margin located below the reference plane was the cup area (CA). The total volume of those parts within the disc margin located below the reference plane was the cup volume (CV). Other measurements of the optic disc topography provided by the HRT were also evaluated: neuroretinal rim area and volume (the neuroretinal rim corresponds to those parts within the disc margin located above the reference plane), and maximum cup depth.

The suction cup oculopressor is an ophthalmodynamometer which consists of a suction pump that is connected by plastic tubing to a rigid, plastic suction cup with an inner diameter of 11 mm. The cup is placed on the temporal conjunctiva and with an increment of the negative pressure in the suction cup the intraocular pressure rises.^{15 16}

Topical tropicamide 1% and phenylephrine 2.5% were applied to the eye 30 minutes before the test. Baseline IOP was then determined and three baseline HRT images were taken. One drop of benoxinate was applied to the eye under investigation place the suction cup on the temporal conjunctiva. The device was placed at least 2 mm posterior to the limbus. The intraocular pressure was increased to 20–25 mm Hg above the baseline (confirmed by tonometry) and three HRT images were then acquired.

Table 1 Average cup area and cup volume measurements (SD) in emmetropic and myopic subjects: baseline values and values during suction (with high intraocular pressure)

	Cup area (mm ²)		p Value (Wilcoxon test)
	Baseline	During suction	
Emmetropic subjects	0.48 (0.35)	0.60 (0.34)	0.013
Myopic subjects	0.22 (0.18)	0.29 (0.21)	0.005
	Cup volume (mm ³)		p Value (Wilcoxon test)
	Baseline	During suction	
Emmetropic subjects	0.34 (0.20)	0.38 (0.19)	0.006
Myopic subjects	0.14 (0.10)	0.16 (0.10)	0.006

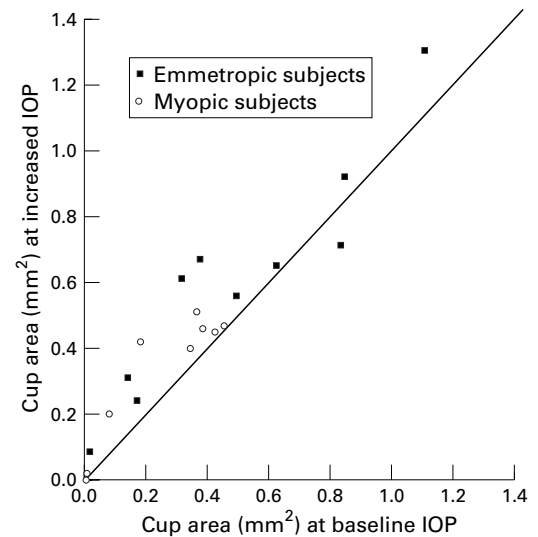


Figure 2 Heidelberg retina tomograph values of cup area.

STATISTICAL ANALYSIS

Each variable was evaluated separately by comparing the baseline measurements with those obtained during the artificially induced IOP elevation (Wilcoxon test). Emmetropic and myopic populations were studied separately. The differences among groups in optic disc changes were evaluated with the Mann-Whitney test.

Results

No side effects, such as subconjunctival haemorrhage, corneal erosion, or subjective alteration of visual function, were observed after this test. Moderate hyperaemia and localised oedema of the temporal conjunctiva were commonly observed after the examination. The suction cup was maintained for approximately 2–3 minutes.

The baseline IOP in the emmetropic group, 13.5 (SD 1.3) mm Hg (range 11–15 mm Hg) was increased to 35.4 (3.3) mm Hg (31–41 mm Hg). In the myopic group the baseline IOP, 12.6 (2.6) mm Hg (9–17 mm Hg) was elevated to 34.4 (2.5) mm Hg (31–40 mm Hg). The imported contour line appropriately outlined the inner margin of the scleral ring of the optic disc of the images obtained during suction. Figures 1 and 2 show the HRT values of CV and CA, respectively, at baseline and suction conditions. The mean baseline values of CA and CV of the emmetropic and myopic subjects were increased during suction (Table 1). These changes were statistically significant ($p < 0.05$, Wilcoxon test).

The differences between emmetropic and myopic groups in suction induced changes in CA and CV were not statistically significant ($p = 0.19$ and $p = 0.42$ respectively, Mann-Whitney test).

The neuroretinal rim area and volume did not change with increased IOP. The maximum cup depth significantly increased during suction in emmetropic (from 0.69 (0.2) mm before suction to 0.75 (0.21) mm after increased IOP, $p = 0.02$) and in myopic eyes (from 0.47 (0.31) mm to 0.52 (0.29) mm before and after suction, respectively, $p = 0.01$).

Discussion

Several experimental studies in cadaver^{3 4} and monkey eyes^{5 6} have demonstrated that there is a posterior displacement of the lamina cribrosa after acute elevation in IOP. To our knowledge, the present study is the first to demonstrate an increased optic disc cupping in normal living human eyes with acute increments of IOP. The most likely explanation of the IOP dependent changes of the topography of the optic disc is a mechanical displacement of the optic nerve head tissues. According to Laplace's equation for spherical shells, a change in IOP is related to a change in the eye wall stress. Additionally, at the scleral canal the relative stress is concentrated.¹⁷ Therefore, an elevation of IOP could compress, rearrange, and/or displace the tissues of the optic nerve head, resulting in a larger cupping. The compliance appeared to be variable between cases. Some eyes appear to have no compliance, especially those with larger cup volumes (Fig 1). The explanation and significance of this variable behaviour to changes of intraocular pressure is not known. Maximum cup depth significantly increased during increased IOP. This indicates that posterior bowing of the lamina cribrosa is probably responsible for part or most of the changes in disc topography observed in this study.

An optical illusion, caused by a movement of the position of the crystalline lens or the axial length of the eye, could be possible. However, Burgoyne *et al* demonstrated that the area of the optic disc did not change after IOP changes, while the optic disc cupping showed significant differences.¹⁸ The imported contour line appropriately outlined the inner margin of the scleral ring of the optic disc of the images obtained during suction, indicating that the disc area did not change. In this study there may be a selection bias because of the use of the right eye in most cases. However, it is very unlikely that right eyes have different compliance from left eyes. A mild downward fluctuation of IOP probably occurred during the test because of a tonographic effect.

The presence of a large amount of elastin within the lamina cribrosa of the optic nerve head might explain why these tissues behave in a viscoelastic manner.^{19 20} There are several factors that may affect the compliance of the optic nerve head. In human necropsy eyes glaucomatous cases have less posterior displacement of the optic nerve head with elevation of IOP than normal eyes.³ This fact may be related to changes in the elastic fibres of the lamina cribrosa that occur in patients with glaucoma.¹⁹ The age of the subject may also influence the IOP dependent changes of optic disc cupping. The reversal of cupping that occurs in infants with glaucoma after treatment is often profound, probably due to the high plasticity of young tissues.^{21 22} Hernandez *et al* demonstrated that the elastic fibres of the lamina cribrosa change with age.²³ In the present study the compliance of the optic nerve head in myopic and emmetropic subjects was similar. The viscoelastic properties of the optic disc may not be affected by the alterations of microarchitecture that are present in myopic eyes.²⁴

Jonas *et al* evaluated healthy and glaucomatous patients and reported a lack of change in optic disc contour after a short term increase of IOP.²⁵ These contradictory results could be due to differences in methodologies (that is, use of non-simultaneous stereophotograph analysis *v* laser confocal tomography, duration of elevation of IOP) or differences in populations (younger population in the present study).

The implications of the findings of this study in the pathogenesis of glaucoma are unknown. It might be possible that in glaucomatous eyes IOP dependent changes of the topography of the optic disc could compromise the vascular support and/or metabolism of axons of the optic disc. Further studies would help to determine whether the dynamic association between IOP and disc topography, as observed in this study, extends to more elderly individuals (more prone to develop glaucomatous disease) and to glaucomatous patients, in order to determine the role of this phenomenon in the pathogenesis of glaucomatous damage.

Supported by NIH grant EY 10801, the Boston Research Fund of the Glaucoma Research Foundation, and the Glaucoma Foundation. Dr Harris is a recipient of the William and Mary Greve Award from Research to Prevent Blindness.

- 1 Levy NS. The effects of elevated intraocular pressure on slow axonal protein flow. *Invest Ophthalmol Vis Sci* 1974;13:691-5.
- 2 Anderson DR, Hendrickson A. Effect of intraocular pressure on rapid axoplasmic transport in monkey optic nerve. *Invest Ophthalmol Vis Sci* 1974;13:771-83.
- 3 Zeimer RC, Ogura Y. The relation between glaucomatous damage and optic nerve head mechanical compliance. *Arch Ophthalmol* 1989;107:1232-4.
- 4 Levy NS, Crapps EE. Displacement of optic nerve head in response to short-term intraocular pressure elevation in human eyes. *Arch Ophthalmol* 1984;102:782-6.
- 5 Coleman AL, Quigley HA, Vitale S, *et al*. Displacement of the optic nerve head by acute changes in intraocular pressure in monkey eyes. *Ophthalmology* 1991;98:35-40.
- 6 Burgoyne CF, Varma R, Quigley HA, *et al*. Global and regional detection of induced optic disc change by digitized image analysis. *Arch Ophthalmol* 1994;112:261-8.
- 7 Spaeth GL. Reversibility of optic disc cupping. A phenomenon that may change the management of glaucoma. *Arch Ophthalmol* 1989;107:1583-4.
- 8 Shirakashi M, Nanba K, Iwata K. Changes in reversal of cupping in experimental glaucoma. *Ophthalmology* 1992;99:1104-10.
- 9 Shin DH, Bielik M, Hong YJ, *et al*. Reversal of glaucomatous optic disc cupping in adult patients. *Arch Ophthalmol* 1989;115:1599-603.
- 10 Irak I, Zangwill L, Garden V, *et al*. Change in optic disk topography after trabeculectomy. *Am J Ophthalmol* 1996;122:690-5.
- 11 Weinreb RN, Dreher AW. Effect of lowering intraocular pressure on optic nerve head topography. In: Nasemann JE, Burk ROW, eds. *Scanning laser ophthalmoscopy and tomography*. Munich: Quintessenz, 1990:193-6.
- 12 Dreher AW, Tso PC, Weinreb RN. Reproducibility of topographic measurements of the normal and glaucomatous optic nerve head with the laser tomographic scanner. *Am J Ophthalmol* 1991;111:221-9.
- 13 Mikelberg FS, Wijsman K, Schulzer M. Reproducibility of topographic parameters obtained with the Heidelberg retina tomograph. *J Glaucoma* 1993;2:101-3.
- 14 Weinreb RN, Lusky M, Bartsch DU, *et al*. Effect of repetitive imaging on topographic measurements of the optic nerve head. *Arch Ophthalmol* 1993;111:636-8.
- 15 Galin MA, Baras I, Cavero R, *et al*. Compression and suction ophthalmodynamometry. *Am J Ophthalmol* 1969;67:388-92.
- 16 Ulrich WD, Ulrich C, Neunhoffer E, *et al*. Oculopression tonometry (OPT): a new tonographic procedure in glaucoma diagnosis. *Klin Monatsbl Augenheilkd* 1987;190:109-13.
- 17 Wo SL-Y, Kobayashi AS, Schlegel WA, *et al*. Nonlinear material properties of intact cornea and sclera. *Exp Eye Res* 1972;14:29-39.
- 18 Burgoyne CF, Quigley HA, Thompson HW, *et al*. Measurement of optic disc compliance by digitized image analysis in the normal monkey eye. *Ophthalmology* 1995;102:1790-9.
- 19 Hernandez MR. Ultrastructural immunocytochemical analysis of elastin in the human lamina cribrosa changes in elastic fibers in primary open-angle glaucoma. *Invest Ophthalmol Vis Sci* 1992;33:2891-903.

- 20 Quigley HA, Brown A, Dorman-Pease ME. Alterations in elastin of the optic nerve head in human and experimental glaucoma. *Br J Ophthalmol* 1991;**75**:552-7.
- 21 Shaffer RN, Hetherington J Jr. The glaucomatous disc in infants. A suggested hypothesis for disc cupping. *Trans Am Acad Ophthalmol Otolaryngol* 1969;**73**:923-35.
- 22 Quigley HA. Childhood glaucoma: results with trabeculotomy and study of reversible cupping. *Ophthalmology* 1982;**89**:219-26.
- 23 Hernandez MR, Luo XX, Igoe F, *et al*. Extracellular matrix of the human lamina cribrosa. *Am J Ophthalmol* 1987;**104**:567-76.
- 24 Curtin BJ: Pathology. In: Curtin BJ, ed. *The myopias. Basic science and clinical management*. Philadelphia: Harper & Row, 1985:247-69.
- 25 Jonas JB, Gareis O, Naumann GOH. Optic disc topography and short-term increase in intraocular pressure. *Graefes Arch Clin Exp Ophthalmol* 1990;**228**:524-7.



Effects of short term increase of intraocular pressure on optic disc cupping

Augusto Azuara-Blanco, Alon Harris, Louis B Cantor, et al.

Br J Ophthalmol 1998 82: 880-883

doi: 10.1136/bjo.82.8.880

Updated information and services can be found at:

<http://bjo.bmj.com/content/82/8/880.full.html>

References

These include:

This article cites 22 articles, 9 of which can be accessed free at:

<http://bjo.bmj.com/content/82/8/880.full.html#ref-list-1>

Article cited in:

<http://bjo.bmj.com/content/82/8/880.full.html#related-urls>

Email alerting service

Receive free email alerts when new articles cite this article. Sign up in the box at the top right corner of the online article.

Notes

To request permissions go to:

<http://group.bmj.com/group/rights-licensing/permissions>

To order reprints go to:

<http://journals.bmj.com/cgi/reprintform>

To subscribe to BMJ go to:

<http://group.bmj.com/subscribe/>