

# Anti-GQ1b ganglioside antibody and ophthalmoplegia of undetermined cause

Tone Suzuki, Atsuro Chiba, Susumu Kusunoki, Makoto Chikuda, Tsuneaki Fujita, Kazuo Misu

## Abstract

**Background/aim**—Serum antibody against ganglioside GQ1b is reported to be closely associated with immune mediated ophthalmoplegia in the Fisher and Guillain-Barré syndromes. Its presence against glycolipids, in particular ganglioside GQ1b, was investigated in patients with ophthalmoplegia of unknown origin. **Methods**—16 patients with ophthalmoplegia, the cause of which could not be confirmed from clinical findings or diagnostic testing, were tested. 34 patients who had ophthalmoplegia of definite cause, 16 healthy people, and 23 patients with typical Fisher syndrome served as the controls. The ELISA was used to check for serum antibodies against glycolipids in all study participants.

**Results**—Two of the 16 patients with ophthalmoplegia of unknown cause had serum IgG antibody against GQ1b but not against other glycolipids, and 22 of the 23 patients with typical Fisher syndrome had this antibody. No anti-GQ1b antibodies were found in the patients with ophthalmoplegia of definite cause or in the normal controls.

**Conclusion**—A common underlying cause appears to bring about the pathogenesis of palsy in Fisher syndrome and in the ophthalmoplegia with positive anti-GQ1b IgG antibody, called atypical Fisher syndrome. This antibody may prove a useful clinical marker for differentiating Fisher syndrome, typical and atypical, in patients with ophthalmoplegia.

(*Br J Ophthalmol* 1998;82:916-918)

Patients with various neurological diseases, including Guillain-Barré syndrome (GBS), have serum antibodies to glycolipids, indicative that an autoimmune mechanism contributes to these diseases.<sup>1-2</sup> Patients in the acute phase of Fisher syndrome (FS), a variant of GBS, characteristically have the IgG antibody against the glycolipid GQ1b.<sup>3-5</sup>

Ophthalmoplegia, a main clinical sign of FS, is closely associated with anti-GQ1b IgG antibody in GBS with ophthalmoplegia, as it is in FS.<sup>6</sup> Eight patients with acute ophthalmoparesis with antecedent infection appeared to have this antibody,<sup>7</sup> but no studies have been done on large numbers of patients with ophthalmoplegia. We investigated whether these antibodies are present in patients with ophthalmoplegia of various origins, including undetermined ones.

## Materials and methods

EXAMINATION OF ANTIGLYCOLIPID ANTIBODY IN PATIENTS' SERA

### Patients

Serum samples were obtained from 50 patients with ophthalmoplegia who were treated at Dokkyo University's Koshigaya Hospital between June 1993 and October 1994. Of the ophthalmoplegia cases studied, 16 were of undiagnosed causes based on the clinical signs, results of neuroimaging, and laboratory studies, and 34 of definite causes (20 vascular origin, four myasthenia gravis, three head trauma, two brain tumour accompanied by multiple sclerosis or dysthyroid ophthalmopathy, and one congenital). Patients in the "vascular origin" group had lesions on computed tomography (CT) scans or magnetic resonance images (MRI), indicative of infarction of the brain stem or atherosclerotic diseases such as diabetes mellitus or hypertension.

Except in the case of congenital origin, all the samples were obtained within 1 month of the initial onset. Information on the patients with ophthalmoplegia of undiagnosed cause is given in Table 1. Serum samples from 16 normal subjects and 23 patients with typical FS, all of whom had the triad (ophthalmoplegia, ataxia, and hypoflexia) of this syndrome were also tested.

### Enzyme linked immunosorbent assay (ELISA)

Serum IgG and IgM antibody activities against eight gangliosides (GM1, GM2, GM3, GD1a, GD1b, GD3, GT1b, and GQ1b) and two neutral glycolipids (asialo-GM1 (GA1) and galactocerebroside) were investigated using the ELISA as reported elsewhere.<sup>6</sup> All the glycolipids, except GQ1b and GA1, were purchased from Funakoshi (Tokyo, Japan). GQ1b was bought from Dia-Iatron (Tokyo, Japan), and GA1 was prepared in our laboratory from the GM1 of bovine brain.

## Results

EXAMINATION OF ANTIGLYCOLIPID ANTIBODY IN PATIENTS' SERA

Two of the 16 patients with ophthalmoplegia of undetermined cause had anti-GQ1b IgG antibody (Fig 1) but no other antiglycolipid antibodies. The anti-GQ1b IgG antibody titre in patient No 13, which was estimated serially three times, decreased with the patient's recovery from ophthalmoplegia (Fig 2). No anti-GQ1b antibody was found in the ophthalmoplegic patients for which the cause was known or in the normal subjects, whereas, except for

Department of Ophthalmology, Dokkyo University School of Medicine, Koshigaya Hospital, Saitama, Japan

T Suzuki  
M Chikuda  
T Fujita  
K Misu

Department of Neurology, University of Tokyo, Tokyo, Japan  
A Chiba  
S Kusunoki

Correspondence to:  
Tone Suzuki, MD,  
Department of Ophthalmology, Dokkyo University School of Medicine, Koshigaya Hospital, 2-1-50 Minamikoshigaya, Koshigaya, Saitama, 343-8555, Japan.

Accepted for publication  
26 February 1998

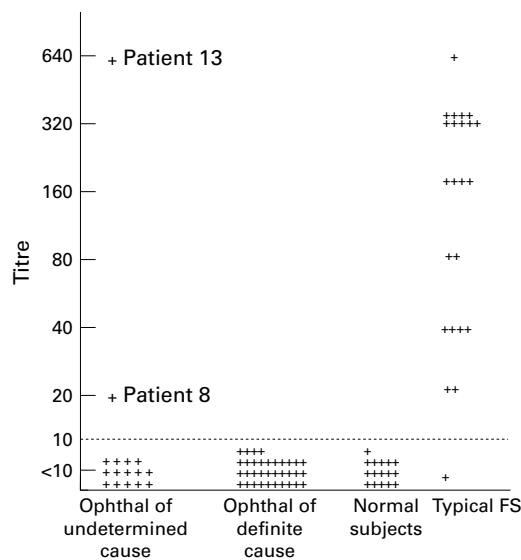


Figure 1 Anti-GQ1b IgG antibody titres in patients with ophthalmoplegia. Serum antibodies were examined by the ELISA. Two of the 16 patients with ophthalmoplegia of undetermined cause and 22 of the 23 patients with typical FS had high anti-GQ1b antibody titres. Titres of the patients with ophthalmoplegia caused by vascular disorders, myasthenia gravis, etc, and those of the normal subjects were less than 1:10. Ophthalmal = ophthalmoplegia. Patient numbers are given in Table 1.

one patient, all those with typical FS had increased anti-GQ1b IgG antibody (Fig 1).

#### PATIENTS

##### Case 1 (patient 13)

A 56 year old woman referred to our clinic had the chief complaint of diplopia (Fig 2). She had had fever and headache 7 days before referral and horizontal diplopia 4 days before. At the initial examination, her visual acuity was normal. No abnormalities were found in the slit lamp and ophthalmoscopic examinations. She had mild abducens palsy bilaterally, but the other cranial nerves were intact. The biceps reflex was absent bilaterally, but there was no ataxia. A head CT scan and blood and urine analyses, including virus titres, were all normal. A cerebrospinal tap was not performed. Anti-GQ1b antibody was positive in her serum, and its titres decreased with the clinical course. Oral prednisolone was given in a tapered off dose of 15 mg. Her abducens palsy was resolved after 2 months.

Table 1 Patients with ophthalmoplegia of undetermined cause

Patient No	Age (years)	Sex	Pattern of palsy	Anti-GQ1b IgG antibody titre	Steroid treatment	Period for recovery	Neurological signs	Neuroimaging study
1	24	F	R, VI	<10	+	4 m	R, proptosis	CT, MRI
2	64	M	L, VI	<10	+	3 m	—	CT
3	56	M	L, VI	<10	—	2 w	—	—
4	52	F	B, total	<10	+	1 y	—	CT, MRI
5	47	M	R, So	<10	+	3 m	—	—
6	73	F	B, VI	<10	—	2 m	ataxic gait	CT
7	40	M	B, VI	<10	+	3 w	—	CT, MRI
8	62	F	R, total	20	+	3 m	—	CT
9	51	M	R, VI	<10	+	4 m	—	CT, MRI
10	45	M	R, total	<10	+	4 m	R, proptosis	CT
11	57	M	L, VI	<10	+	6 m	decreased reflex	CT
12	69	M	L, So	<10	—	4 m	—	CT
13	56	F	B, VI	640	+	2 m	areflexia	CT
14	37	M	GPN	<10	—	1 m	—	CT, MRI
15	40	F	L, So	<10	+	4 m	—	MRI
16	61	M	R, total+L, VI	<10	—	4 m	—	CT

B = bilateral; VI = abducens palsy; total = total ophthalmoplegia; Sr = superior rectus muscle palsy; So = superior oblique muscle palsy; GPN = gaze paretic nystagmus; m = month(s), w = week(s), y = year(s); CT = head CT scan; MRI = magnetic resonance imaging.

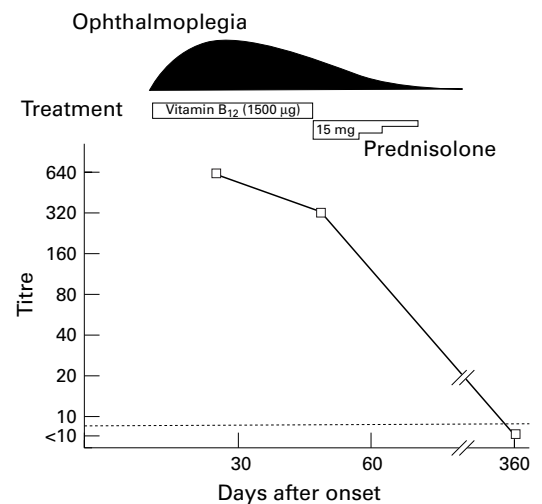


Figure 2 Profiles of the clinical manifestations and anti-GQ1b titre of patient 13 who had bilateral abducens palsy. The ophthalmoplegia schema shows the degree of ocular limitation towards abduction. The decrease in anti-GQ1b IgG titre paralleled the improvement of ocular movement.

##### Case 2 (patient 8)

A 62 year old woman visited our hospital with the chief complaint of blepharoptosis and diplopia. Ptosis on the right side had occurred 1 month earlier but had disappeared after 3 weeks. She experienced horizontal diplopia 1 week before the consultation at our hospital. There had been no viral infection nor a past history of hypertension or diabetes mellitus. At the initial examination no visual acuity abnormality was found, and results of the slit lamp and ophthalmoscopic examinations were normal. She had 15 prism esotropia and severe limitation of right eye movement in all directions, particularly the lateral direction. The pupils and trigeminal nerves were normal, and there was no blepharoptosis or proptosis. Results of the other neurological, blood, and urine examinations were normal. Serum acetylcholine receptor antibodies were negative. A head CT scan was negative around the brain stem, orbit, and cavernous sinus. Painful ophthalmoplegia was diagnosed. Anti-GQ1b antibody was positive in a serum sample obtained 30 days after onset. Her ophthalmoplegia was resolved after 3 months of corticosteroid treatment.

## Discussion

Ophthalmoplegia is caused by various underlying factors, the most common ones being vascular disorder, neoplasm, and head trauma. Despite advances in diagnostic techniques, the causes of about 20% of ophthalmoplegia cases are undetermined.<sup>8</sup> We could find no definite cause of the ophthalmoplegia of 16 of the 50 patients studied. Some patients with ophthalmoplegia of undetermined cause may have microvascular disorders that are undetectable by CT scan only or even other additional procedures, as judged by their relatively benign recoveries and older ages (mean 52 years). Some patients may have such postinfectious syndromes as GBS or FS, but confirmation is difficult because of incomplete clinical findings.

FS, characterised by the clinical triad of ophthalmoplegia, ataxia, and areflexia, is considered a variant of GBS because of their common clinical features.<sup>9</sup> Plasmapheresis brings about rapid recovery in both FS and GBS,<sup>10 11</sup> indicative that a humoral factor is involved in the pathogenesis of both syndromes. Serum antiganglioside antibodies are present in patients with GBS<sup>1 2</sup>: Chiba *et al*, who reported the frequent presence of serum IgG antibody against ganglioside GQ1b in patients with FS in the acute phase, speculated that an immune feature common to FS and GBS, antiganglioside antibody, exists.<sup>3</sup> Subsequent studies have confirmed that almost all patients with FS have the anti-GQ1b antibody.<sup>4 11</sup>

Most patients with GBS *with* ophthalmoplegia also have the anti-GQ1b IgG antibody, but it has not been found in patients with GBS *without* ophthalmoplegia.<sup>6</sup> Investigations have been made to ascertain the immune mechanism that induces ophthalmoplegia. An anti-GQ1b mouse monoclonal antibody immunostains the extramedullary portions of the human oculomotor, trochlear, and abducens nerves.<sup>6</sup> Although anti-GQ1b antibody may be elevated, owing to tissue destruction, it is likely that the serum IgG antibody against GQ1b functions in the pathogenesis of acute ophthalmoplegia in FS and GBS on the basis of the time lag between the peaks of antibody activity and the clinical symptoms.<sup>6</sup>

In our study, two (Nos 8 and 13) of the 16 patients with ophthalmoplegia of undetermined cause had IgG antibody against GQ1b

but no antibodies against other glycolipids. Yuki reported eight patients with acute ocular paresis after an antecedent infection who had IgG anti-GQ1b antibody.<sup>7</sup> Only our patient 13, however, had signs of post-infectious syndrome. Both our patients probably have immune damage to the ocular motor nerves similar to that seen in FS.

These facts indicate that some patients with ophthalmoplegia of unknown cause may be categorised as having an autoimmune disease related to FS. Patients with probable FS sometimes have ophthalmoplegia but without ataxia or areflexia, and some of them have been diagnosed as having atypical FS on the basis of clinical features alone. The determination of the presence of serum antibodies against ganglioside GQ1b in such patients is useful for verifying the diagnosis. Our two patients with anti-GQ1b antibody seem to have atypical FS, even though they showed apparent ophthalmoplegia without other characteristic signs.

The administration of corticosteroids was effective to some extent. A favourable response to plasmapheresis has been reported,<sup>9 10</sup> but steroid therapy also appears to be useful for patients with ophthalmoplegia related to immune disease.

- 1 Ilyas AA, Willison HJ, Quarles RH. Serum antibodies to gangliosides in Guillain-Barré syndrome. *Ann Neurol* 1988;23:440-7.
- 2 Kusunoki S, Chiba A, Kon K, *et al*. N-acetylgalactosaminyl GD1a is a target molecule for serum antibody in Guillain-Barré syndrome. *Ann Neurol* 1994;35:570-6.
- 3 Chiba A, Kusunoki S, Shimizu T, *et al*. Serum IgG antibody to ganglioside GQ<sub>1b</sub> is a possible marker of Miller Fisher syndrome. *Ann Neurol* 1992;31:677-9.
- 4 Willison HJ, Veitch J, Paterson G, *et al*. Miller-Fisher syndrome is associated with serum antibodies to GQ<sub>1b</sub> ganglioside. *J Neurol Neurosurg Psychiatry* 1993;56:204-6.
- 5 Yuki N, Sato S, Tsuji S, *et al*. Frequent presence of anti-GQ<sub>1b</sub> antibody in Fisher's syndrome. *Neurology* 1993;43:414-7.
- 6 Chiba A, Kusunoki S, Obata H, *et al*. Serum anti-GQ<sub>1b</sub> IgG antibody is associated with ophthalmoplegia in Miller Fisher syndrome and Guillain-Barré syndrome: clinical and immunohistochemical studies. *Neurology* 1993;43:1911-7.
- 7 Yuki N. Acute paresis of extraocular muscles associated with IgG anti-GQ<sub>1b</sub> antibody. *Ann Neurol* 1996;39:668-72.
- 8 Richards BW, Jones FR, Younge BR. Causes and prognosis in 4,278 cases of paralysis of the oculomotor, trochlear, and abducens cranial nerves. *Am J Ophthalmol* 1992;113:489-96.
- 9 Fisher CM. An unusual variant of acute idiopathic polyneuritis (syndrome of ophthalmoplegia, ataxia and areflexia). *N Engl J Med* 1956;225:57-65.
- 10 French Cooperative group on plasma exchange in Guillain-Barré syndrome. Efficiency of plasma exchange in Guillain-Barré syndrome: role of replacement fluids. *Ann Neurol* 1987;22:753-61.
- 11 Yuki N, Ohsawa T. Beneficial effect of plasmapheresis on Fisher's syndrome. *Muscle Nerve* 1993;16:1267-8.



## Anti-GQ1b ganglioside antibody and ophthalmoplegia of undetermined cause

Tone Suzuki, Atsuro Chiba, Susumu Kusunoki, et al.

*Br J Ophthalmol* 1998 82: 916-918

doi: 10.1136/bjo.82.8.916

---

Updated information and services can be found at:

<http://bjournal.bmj.com/content/82/8/916.full.html>

---

*These include:*

### References

This article cites 11 articles, 3 of which can be accessed free at:

<http://bjournal.bmj.com/content/82/8/916.full.html#ref-list-1>

Article cited in:

<http://bjournal.bmj.com/content/82/8/916.full.html#related-urls>

### Email alerting service

Receive free email alerts when new articles cite this article. Sign up in the box at the top right corner of the online article.

---

### Topic Collections

Articles on similar topics can be found in the following collections

[Muscles](#) (184 articles)

[Neurology](#) (1042 articles)

---

### Notes

---

To request permissions go to:

<http://group.bmj.com/group/rights-licensing/permissions>

To order reprints go to:

<http://journals.bmj.com/cgi/reprintform>

To subscribe to BMJ go to:

<http://group.bmj.com/subscribe/>