

MAILBOX

Peripapillary coloboma simulating double optic disc

EDITOR.—Doubling of the optic disc is rare and can manifest as true or pseudo doubling. A 64 year old man was referred by his physician who noted “a clear area between each optic disc on both sides” during a routine check. Visual acuities and anterior segments were normal. Funduscopy revealed an appearance simulating double optic discs on each side. The right eye showed a 2 disc diameter (DD) sized pale excavation 1 DD below the optic disc inferotemporally (Fig 1A), with patchy pigmentation along the margins. The inferotemporal branches of retinal vessels dipped into the lesion before re-emerging. The left eye also revealed a similar but slightly larger (3 DD) lesion 1 DD below the optic disc, the two being connected by parallel retinal vessels (Fig 1B). These vessels bifurcated just above the inferior lesion before dipping into its excavation and emerging to supply the inferior retina. The retina surrounding these lesions was hypopigmented. On fluorescein angiography the inferior disc-like lesions were hypofluorescent in the early frames (Fig 1C) and on late frames the entire lesion showed scleral staining (Fig 1D). B-scan ultrasound revealed ectatic coloboma below the optic discs in both eyes (Fig 1E, F).

Duke-Elder¹ describes duplication of the optic disc as a rare anomaly wherein two discs, each provided with retinal vessels are seen in an otherwise normal eye. Rare cases of true duplication of optic discs with separation of optic nerve into two or more strands have been reported, based either on incidental necropsy findings,^{2,3} demonstration of two optic foramina in the same orbit on x ray,⁴ or angioscotomas⁵ as indirect evidence of the existence of double optic nerves. Pseudo doubling of the optic discs caused by lesions such as optic disc coloboma, peripapillary chorioretinal coloboma, or inflammatory foci are more common.⁶⁻⁹ Our case had bilateral isolated ectatic peripapillary chorioretinal coloboma simulating double optic discs.

GIRISH G KAMATH
SOMDUTT PRASAD
YOGESH J PATWALA
MARK T WATTS

Department of Ophthalmology, Arrouw Park Hospital,
Upton, Wirral, Merseyside, L49 5PE

Correspondence to: Mr G G Kamath.

- 1 Duke-Elder SS, ed. Congenital deformities. In: *System of ophthalmology*. Vol II-2, St Louis: Mosby, 1963:671-2.
- 2 Snead CM. Congenital division of the optic nerve at the base of the skull. *Arch Ophthalmol* 1915;44:418-20.
- 3 Gasner S. Cited in Slade HW, Weekley RD. Diastasis of the optic nerve. *J Neurosurg* 1957;14:571-4.
- 4 Lamba PA. Doubling of the papilla. *Acta Ophthalmol Copenh* 1969;47:4-9.
- 5 Collier M. Communications sur le sujet du rapport les doubles papilles optiques. *Bull Soc Ophthalmol Fr* 1958;71:328-52.
- 6 Brink JK, Larsen FE. Pseudodoubling of the optic disc. A fluorescein angiographic study of a case with coloboma. *Acta Ophthalmol Copenh* 1977;55:862-70.

- 7 Boynton JR, Pheasant TR, Johnson BL, et al. Ocular findings in Kenny's syndrome. *Arch Ophthalmol* 1979;97:896-900.
- 8 Donoso LA, Magargal LE, Eiferman RA, et al. Ocular anomalies simulating double optic discs. *Can J Ophthalmol* 1981;16:85-7.
- 9 Barboni P, Deluigi M, De Bonis C, et al. Pseudodoubling of the optic disc. *Arch Ophthalmol* 1998;116:1400-1.

Pupillary abnormality

EDITOR.—A 33 year old female patient, who was born in the far east of Nepal where there were no medical facilities, had a noticeable bilateral pupillary abnormality at birth. It was not until she was 12 years of age that she was first seen by an ophthalmologist in Kathmandu.

Her present visual status is an acuity of 6/6 partly and N5 in each eye. She had no visual complaints but slit lamp examination shows a gross persistent pupillary membrane in each eye with an almost identical appearance.

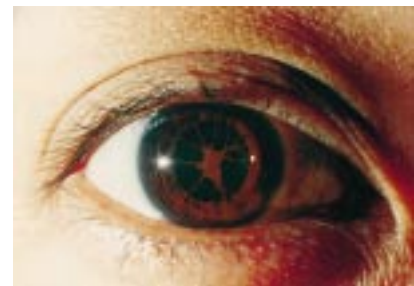


Figure 1 Gross persistent pupillary membrane in the eye

The membrane is not adherent to the lens capsule. It bulges forward into the anterior chamber when the pupil constricts to light and is flat with the pupil dilated (see Fig 1). The ocular fundi are normal.

It is interesting that in the presence of this gross pupillary abnormality visual acuity is unaffected with no significant visual deprivation amblyopia.

K S MALLA

Ga 2-696 Bagh Bazar, Kathmandu 2, Nepal

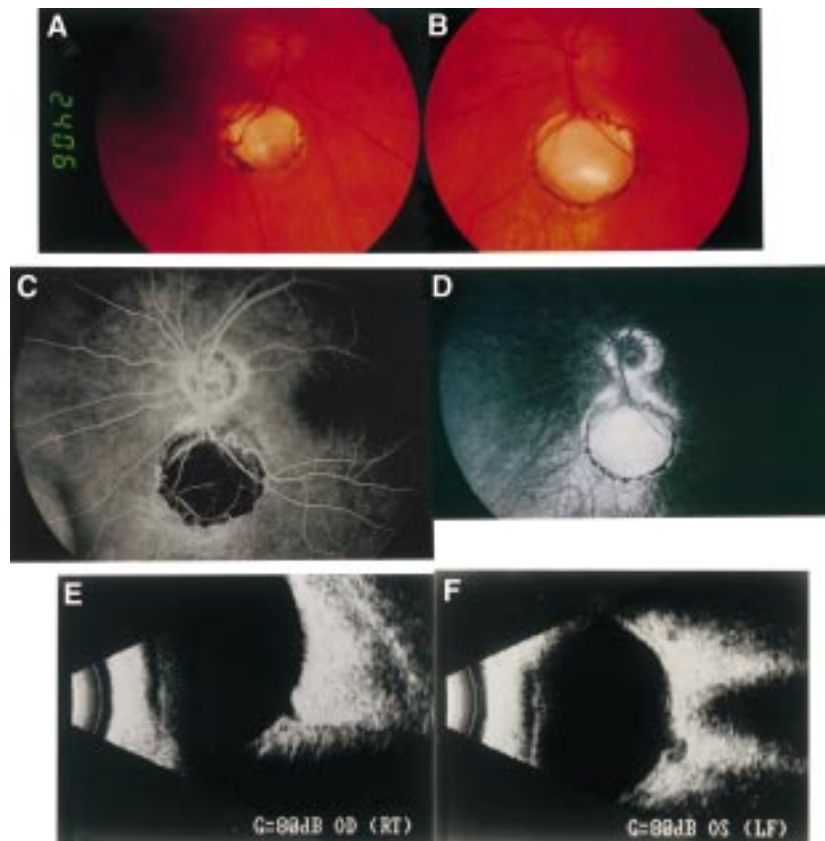


Figure 1 Fundus photographs of right (A) and left (B) eyes showing inferior pale lesions simulating double optic discs. Early (C) and late (D) frames of fluorescein angiogram of the left eye showing hypofluorescence and scleral staining respectively of inferior disc like lesion. B-scan ultrasound of right (E) and left (F) eyes showing ectatic coloboma inferior to the optic discs.

BOOK REVIEWS

Cosmetic Oculoplastic Surgery—Eyelid, Forehead, and Facial Techniques. 3rd ed. By Allen M Putterman. Pp 500; £96. London: WB Saunders, 1999. ISBN 0-7216-7076-8.

This book is designed principally as a reference for surgeons engaged in cosmetic blepharoplasty work, but also covers forehead, eyebrow and facelifts, and adjunctive treatments such as chemical and laser skin resurfacing. Despite this, there is an enormous amount of information within this volume that is extremely useful for those engaged in oculoplastic work outside the aesthetic field. There is no reason at all why surgery for functional abnormalities should not be planned with regard to the eventual cosmetic result and the two aims are often coincidental. Most surgeons will be able to find a lot of helpful advice

that can be used in improving the results of surgery for ectropion or for lid retraction or involutional ptosis.

This book has contributions from a number of different authors, but is prolifically illustrated throughout by the same artist, with great clarity, lending a cohesion to the volume which is reinforced by introductions to each chapter from the principal author.

Each chapter tends to explore one particular surgical technique, with clear step by step instructions. Many stages, such as excision of orbital fat prolapse, are common to a number of different procedures and are described in similar detail in several chapters; this leads to much repetition if one is reading the book from end to end, but is very helpful in reducing the number of cross references if it is being used as a surgical manual.

Although the main part of the book is devoted to surgical techniques, there are a number of extremely useful chapters on more general topics such as the assessment of the oculoplastic patient, patient selection, and the factors involved in determining patient satisfaction with the outcome of treatment. People presenting for cosmetic surgery often have high expectations of what surgery has to offer and a low tolerance of suboptimal results, but they are not necessarily very different from patients seeking other forms of elective surgery and much of the advice on preoperative assessment, counselling, and communication is widely applicable to much of ophthalmology.

This is a very usable surgical textbook that offers ample information and advice to enable most oculoplastic surgeons to feel confident to extend and modify their repertoire to give their patients the optimum results functionally and aesthetically. It manages to achieve this while challenging us to look hard at the way we practise and the way we relate to our patients.

COLIN HUTCHINSON

Low Vision Rehabilitation: Caring for the Whole Person. Ophthalmology Monograph 12. Ed by D C Fletcher. Pp 162. £75. San Francisco: American Academy of Ophthalmology, 1999. ISBN 1-56055-170-4.

This book is one component of the *Lifelong Education for the Ophthalmologist* (LEO) framework, produced by the American Academy of Ophthalmology. Those not claiming credits can still benefit from the multiple choice questions (with answers and explanations).

The preface sets out a comprehensive range of educational objectives which are largely met by the text, but one has the impression that its primary (and most challenging goal) is persuading ophthalmologists that something can be done for the low vision patient. Ophthalmologists, more than any other group, apparently see vision loss as the "arch enemy", and usually encounter visually impaired patients in the upsetting early stages of the condition, rather than when they are coping successfully. This is not to suggest that vision loss does not have profound effects on all aspects of the patient's life, because seeing to read at near, intermediate, and distance is fundamental to independent living. Rehabilitation is the key to coping, and the patient is the prime mover in this: one can give them a magnifier but they have to want to read again, and must practise new skills to achieve this aim. By contrast, in traditional medical

treatment, the physician is the source of action, the patient being asked simply for compliance.

Although the book emphasises this shift of philosophical perspective, it also gives much practical guidance on patient assessment (psychological state, visual performance, needs in activities of daily living) and "treatment" (choosing and dispensing optical aids, and teaching the patient to use these and other strategies to make the best use of residual vision). All these topics are dealt with succinctly and clearly, although the text does verge at times on the overly simplistic: to dismiss the optics of stand magnifiers by saying that they are "designed for use with a standard bifocal add or reading glasses" makes the purist cringe, but is a perfectly acceptable assumption in 90% of cases. The brevity has perhaps led to some surprising omissions: the logMAR notation, although the design of the charts is described; the possible lack of correspondence as distance and near VA are interconverted; the effect of eye to magnifier distance on field of view (although it is incorrectly stated that it alters the magnification); the beneficial quadrupling of illuminance as the light source moves to half the distance from the task; the conversion of dioptric power of a magnifier to magnification.

The book is least useful where its US origin becomes obvious—for example, driving regulations, useful addresses, and the qualification and certification of orientation and mobility instructors. There are occasions in the book when something is referred to but is not explained until the following chapter—PRL and ETRS charts are two examples. This is perhaps inevitable in a multiauthor book, although the editor was co-author on most chapters, and should have been able to resolve this. These are minor quibbles, however, in a beautifully produced, easy to read book, with many high quality colour photographs and colour highlighted tables. The take home message comes through loud and clear: "A positive attitude, more than any other factor, serves to minimize the handicap caused by visual impairment". This book seeks to engender this attitude among professionals, knowing that only then can they transmit this to their patients. It should be essential reading for all those working in ophthalmology clinics.

CHRISTINE M DICKINSON

NOTICES

External eye infections

The latest issue of *Community Eye Health* (no 30) discusses external infections of the eye. Included are papers on conjunctivitis, corneal ulcer, and transmission and control of infection. For further information please contact *Community Eye Health*, International Centre for Eye Health, Institute of Ophthalmology, 11-43 Bath Street, London EC1V 9EL. (Tel: (+44) 171 608 6909/6910/6923; fax: (+44) 171 250 3207; email: eyeresource@ucl.ac.uk) Annual subscription £25. Free to workers in developing countries.

Residents' Foreign Exchange Programme

Any resident interested in spending a period of up to one month in departments of ophthalmology in the Netherlands, Finland, Ireland, Germany, Denmark, France, Austria, or Portugal should apply to: Mr Robert Acheson, Secretary of the Foreign Exchange Committee, European Board of Ophthalmology, Institute of Ophthalmology, University College Dublin, 60 Eccles Street, Dublin 7, Ireland.

Ophthalmological Clinic, University of Creteil

An international symposium on the macula will be held on 1-2 October 1999 at the Ophthalmological Clinic, University of Creteil. Further details: Professor G Soubrane, Chef de Service, Clinique Ophthalmologique Universitaire de Creteil, Centre Hospitalier Intercommunal, 40 Avenue de Verdun, 94010 Creteil, France (fax: 01 45 17 52 27).

Jules François Prize

The 2000 Jules François Prize of \$100 000 for scientific research in ophthalmology will be awarded to a young scientist who has made an important contribution to ophthalmology. All topics in the field of fundamental and/or clinical research in ophthalmology will be considered. The application should be sent jointly with a curriculum vitae, the list of all publications, and three copies of the candidate's 10 most relevant publications to Jules François Foundation Secretary, Professor Dr M Hanssens, Dienst Oogheelkunde, de Pintelaan 185, B-9000 Gent, Belgium. Deadline for applications 31 December 1999.

Joachim Kuhlmann Fellowship for Ophthalmologists 2000

The Joachim Kuhlmann AIDS Foundation, Essen, Germany, is sponsoring two fellowships per year for ophthalmologists at a well known institute, who want to train in CMV retinitis and other HIV related ophthalmological diseases. The fellowships are valued at \$US5000 each. Deadlines for applications are 31 January and 31 July. Detailed applications, including CV and publication list, should be sent to the Joachim Kuhlmann AIDS Foundation, Bismarckstrasse 55, 45128 Essen, Germany (tel: 0201 87910-87; fax: 0201 87910-99; email: jk-stiftung@t-online.de).

XXXIV Nordic Congress of Ophthalmology

The XXXIV Nordic Congress of Ophthalmology will be held in Reykjavik, Iceland, 18-21 June 2000. This meeting celebrates the 100 year anniversary of the Nordic Ophthalmology Conference. Further details: Iceland Incentives Inc, Hamraborg 1-3, Is-Kopavogur, Iceland (tel: +354 554 1400; fax: +354 554 1472; email: incentiv@itn.is).

Vith Mediterranean Ophthalmological Society

The combined meeting of the Vith Mediterranean Ophthalmological Society and the Vith Michaelson Symposium on Ocular Circulation and Neovascularisation will be

held in Jerusalem on 21–26 May 2000. Further details: Secretariat, c/o Unitours Israel Ltd, PO Box 3190, 61031 Tel Aviv, Israel (tel: +972-3-5209999; fax: +972-3-5239099; email: meetings@unitours.co.il).

The VIth Michaelson medal and award will be delivered on 24 May 2000 in Jerusalem. The medal and award (\$15 000 monetary prize) are sponsored by the Israel Academy of Sciences and Humanities and by the Hadassah Hebrew University Hospital and Medical School of Jerusalem, Israel. Nominations are sought from the ophthalmic community at large. Suggestions and reasons for choice and CV highlights should be sent to Professor David BenEzra, Secretary for the International Nominating Committee, Pediatric Ophthalmology Unit, Hadassah Hebrew University Hospital, PO Box 12000, Jerusalem 91120, Israel.

5th International Viteoretinal Meeting–IIV 2000

The 5th International Viteoretinal Meeting–IIV 2000 will be held in Parma, Italy, on 26–27 May 2000. The main topics will include “Hypotony and glaucoma in viteoretinal surgery”, “Internal limiting membrane surgery”, “Macula oedema”, “Open globe injuries”, and “News in retinal pigment epithelium”. Further details: C Cantu, MA De Giovanni, or S Tedesco, Scientific Secretariat, Institute of Ophthalmology, University of Parma, Via Gramsci 14, 43100 Parma, Italy (tel: ++39 0521 259106; fax: ++39 0521 292358; email: nuzzi@ipruniv.cce.unipr.it).

DR-2000, International Forum on Diabetic Retinopathy

The International Forum on Diabetic Retinopathy will take place on 7–9 September 2000

at the Palazzo Reale, Naples, Italy. Further details: Francesco Bandello, Congress Secretariat, MGR Congressi, Via Servio Tullio, 4, 20123 Milano, Italy (tel: 39 02 430071; fax: 39 02 48008471; email: dr2000@mgr.it).

12th Afro-Asian Congress of Ophthalmology

The 12th Afro-Asian Congress of Ophthalmology (Official Congress for the Afro-Asian Council of Ophthalmology) will be held on 11–15 November 2000 in Guangzhou (Canton), China. The theme is “Advances of ophthalmology and the 21st century”. Further details: Professor Lezheng Wu, Zhongshan Eye Center, SUMS, New Building, Room 919, 54 Xianlie Nan Road, Guangzhou 510060, PR China (tel: +86-20-8760 2402; fax: +86-20-8777 3370; email: lwuicv@gzsums.edu.cn).



Peripapillary coloboma simulating double optic disc

GIRISH G KAMATH, SOMDUTT PRASAD, YOGESH J PATWALA, et al.

Br J Ophthalmol 1999 83: 1207
doi: 10.1136/bjo.83.10.1207

Updated information and services can be found at:
<http://bjo.bmj.com/content/83/10/1207.1.full.html>

References

These include:

This article cites 8 articles
<http://bjo.bmj.com/content/83/10/1207.1.full.html#ref-list-1>

Article cited in:
<http://bjo.bmj.com/content/83/10/1207.1.full.html#related-urls>

Email alerting service

Receive free email alerts when new articles cite this article. Sign up in the box at the top right corner of the online article.

Notes

To request permissions go to:
<http://group.bmj.com/group/rights-licensing/permissions>

To order reprints go to:
<http://journals.bmj.com/cgi/reprintform>

To subscribe to BMJ go to:
<http://group.bmj.com/subscribe/>