

PERSPECTIVE

Scanning laser ophthalmoscopy and fundus fluorescent leucocyte angiography

Parwez Hossain

Leucocytes have a central role in the pathogenesis of retinal and choroidal inflammatory disease. The traffic of different leucocyte subsets such as neutrophils, lymphocytes, and monocytes into retinal and choroidal tissue greatly determines the type of immune response that is observed. Infiltration of these cells can lead to tissue destruction with resulting visual loss.¹ To allow these cells to accumulate at these sites, leucocytes must pass from the intravascular compartment and into the extravascular space. Until recently, it has not been possible to observe this leucocyte traffic in the retina and choroid *in vivo*. Most of our understanding of the movement of leucocytes from the intravascular compartment to the extravascular space has been based on studies of leucocyte traffic in the rat mesentery² or the mouse peripheral lymph node.³ Whether the observations made in these systems are applicable to the circulations of the retina and the choroid is not clear.

The scanning laser ophthalmoscope (SLO) provides real time imaging of the ocular fundus using low levels of illumination.⁴ This advantage has been used to perform real time fundus fluorescein and indocyanine green angiography but the use of SLO technology to perform these tasks has limited benefits. The real time imaging facility of the SLO, however, has the greatest application in visualising leucocyte traffic in the fundus *in vivo*. This development is becoming an important tool to study the circulation of leucocytes in different types of retinal and choroidal pathology and this review will describe the current methods of leucocyte angiography and their applications.

Current methods to observe leucocyte circulation in the fundus with the SLO

The current methods are:

- Acridine orange leucocyte angiography
- Fluorescein isothiocyanate (FITC) labelled leucocyte angiography
- Sodium fluorescein labelled leucocyte angiography
- Carboxyfluorescein labelled leucocyte angiography
- Indocyanine green leucocyte angiography.

Each method has its own relative advantages and disadvantages mainly based on the types of dye in use.

ACRIDINE ORANGE LEUCOCYTE ANGIOGRAPHY

Acridine orange leucocyte angiography (AO) is the most frequently used method and most investigations with this technique have been done in rodents.⁵⁻⁷

The dye is administered intravenously and can penetrate cell membranes. Once through the cell membrane it binds to nucleic acids, leading to the formation of a fluorescent compound which has an excitation and emission spectrum similar to sodium fluorescein (Table 1). Since nearly all the nuclear material in blood is located in leucocytes then these cells stain preferentially to other cells such as the red blood cells and platelets. Using a SLO with an argon laser (490 nm), the fluorescent leucocytes stand out from the non-fluorescent plasma. Cells which lack nuclear material such as the platelets and the majority of red blood cells do not fluoresce.

The dye stains all nuclear material and therefore cell nuclei of the retinal vascular endothelium will also fluoresce. This aids the location of the circulating leucocytes which can be seen moving through fluorescein outlined retinal vessels. However, the retinal pigment epithelial cell nuclei will also fluoresce and this obscures the view of the leucocytes circulating in the choroid.

The dye stains all the leucocytes in the body so the behaviour of different types of leucocyte subsets cannot be studied. However, since the majority of circulating leucocytes are neutrophils, the technique gives an indication of the behaviour of these cells *in vivo* and therefore has use in studies of acute inflammation.⁸

The main drawbacks of acridine orange is that it is carcinogenic⁹ and can be phototoxic to cellular lysosomes,¹⁰ which thus limits its use to animal studies.

FLUORESCIN ISOTHIOCYANATE LABELLED LEUCOCYTE ANGIOGRAPHY

Fluoroisothiocyanate (FITC) is a fluorescent dye which has similar spectral characteristics to sodium fluorescein (Table 1). This agent has been used to label donor lymphocytes which are then transferred to recipient animals.¹¹ Using the SLO the fluorescent leucocytes can be observed circulating in the fundus *in vivo*, after injection of $2.5-5 \times 10^7$ labelled cells. The flow of fluorescent leucocytes can be identified in the retina and choroid.

Table 1 Staining and spectral features of the different agents used in fluorescent leucocyte angiography

Fluorescent agent	Molecular weight	Staining features	Absorption wavelength (nm)	Emission wavelength (nm)
Acridine orange	302	Binds to nucleic acids to produce fluorescent chromophore	500	526
Carboxyfluorescein diacetate (CFDA)	460	Converted by intracellular esterases to a fluorescent derivative	492	517
Calcein-am	995	Converted by intracellular esterases to a fluorescent derivative	494	517
Fluorescein isothiocyanate (FITC)	389	Binds to proteins	494	519
Sodium fluorescein	376	Binds to proteins	485	530
Indocyanine green	775	Binds to proteins	805	835

However, without the presence of an intravascular contrast agent, the method cannot resolve the architecture of the retinal and choroidal vessels in sufficient detail to permit the location of the circulating leucocytes in small vessels, such as the retinal capillaries or the choriocapillaris.

FITC leucocyte angiography has the benefit that a selected population of labelled leucocytes can be observed but the method does not provide quantitative information on the velocity of the circulating leucocytes in the fundus. There is also evidence that FITC may interfere with cell function.¹²

SODIUM FLUORESCEIN LABELLED LEUCOCYTE ANGIOGRAPHY

In this method autologous blood is taken and stained *in vitro* with sodium fluorescein.¹³ The blood is then centrifuged, after which the buffy coat containing leucocytes and platelets is separated. This layer contains fluorescent labelled cells. These cells are then injected intravenously either back into the same animal or into another recipient. Using a SLO with an argon laser, the sodium fluorescein labelled leucocytes can be observed circulating in the fundus. The main difficulty with this method is that the dye rapidly elutes from stained material¹⁴ and using the stated methodology plenty of platelets are also stained. Additionally, flow cytometric analysis shows changes in leucocyte morphometry¹⁴ and it is not clear whether the staining process causes leucocyte activation. The key advantage, however, is that it is safe and the method can be used in humans.¹⁵

CARBOXYFLUORESCEIN DIACETATE (CFDA) LABELLED LEUCOCYTE ANGIOGRAPHY

With CFDA labelled leucocyte angiography, the donor leucocytes are stained *in vitro*.¹⁶ The labelling agent itself is not fluorescent and requires intracellular esterases to convert the carboxyfluorescein diacetate to carboxyfluorescein. The latter has fluorescent properties which are similar to sodium fluorescein (Table 1). Since the dye only stains viable cells, it ensures that only live cells are observed. The major benefit of this dye is that it is non-toxic and does not affect cell function.¹⁷ Additionally, the dye is well retained in cells and imaging of fluorescent leucocytes can be maintained in excess of 30 minutes. At present, the method has only been used in animals.

A further advantage with this technique is that by performing a low dose fluorescein angiogram (using one tenth of the normal dose of sodium fluorescein) permits localisation of the labelled leucocytes in both the retinal and choroidal circulation. Bright fluorescent cells can be observed circulating in a faintly fluorescing retinal and choroidal vasculature (Figs 1 and 2).

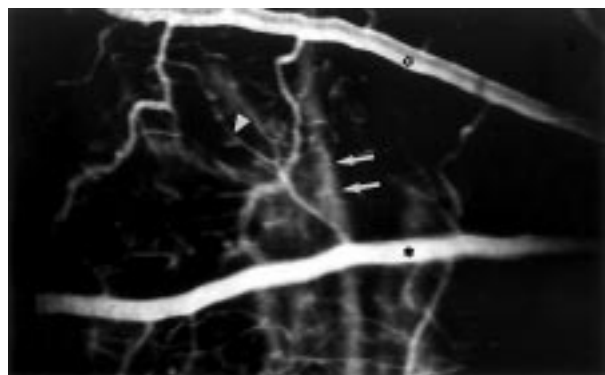


Figure 1 A digital scanning laser ophthalmoscopy image of the rat fundus during fluorescein angiography. The retinal vessels: retinal artery (open star), retinal vein (solid star), and retinal capillary (arrowhead) can be distinguished. The choroidal vessels (white arrows) can also be observed as faint structures behind the retinal vasculature.

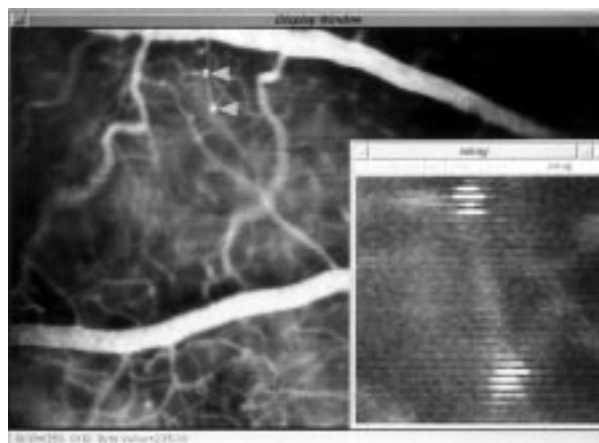


Figure 2 A "pair" of carboxyfluorescein labelled leucocytes flowing through a retinal capillary (main window, arrowheads). The "pair" of cells (see smaller window), actually represent only one flowing leucocyte and appear double owing to the combined result of the interlaced scanning system of the SLO and the rapid movement of the leucocyte. The leucocyte is travelling so fast that it is captured "twice" by the scanning system of the SLO, thus giving the misleading appearance of two cells. This feature can be used to calculate the velocity of the leucocyte.

INDOCYANINE GREEN LEUCOCYTE ANGIOGRAPHY

Indocyanine green binds avidly to proteins. When administered intravenously its half life is 3–4 minutes with most of the dye disappearing from the plasma after about 10–20 minutes. The dye has spectral properties in the infrared range (Table 1) and this allows better penetration of the choroid. The authors of this technique have shown that leucocytes retain the dye for longer than 30 minutes and once the peak fluorescence of indocyanine green in the plasma has subsided, the indocyanine green stained leucocytes become apparent.¹⁸ In this "window" of opportunity, measurements of the leucocyte velocity can be made of choroidal leucocytes. However, this technique is again limited to the study of the heterogeneous peripheral blood leucocyte population which, like acridine orange angiography, reflects the circulating activity of neutrophils.

Measuring leucocyte velocity

Measurement of leucocyte velocity may indicate the relative blood flow through retinal and choroidal tissue and could be helpful in detecting the changes of blood flow that occur in diabetic retinopathy.¹⁹ Previously, leucocyte velocity has been measured by the blue field entoptic technique which has shown changes in leucocyte velocity in the perifoveal capillaries in patients with diabetic retinopathy.¹⁹ However, the subjective nature of this method and the need of highly cooperative patients limits its value in clinical practice. With fluorescent leucocyte angiography an objective method is now available.

To measure leucocyte velocity, most SLO studies initially digitise the recorded video images by computer. Then in each image leucocytes are identified. When a moving leucocyte is identified in two consecutive frames, the pair of images are processed by subtracting one frame from the other. This allows the relative positions of a moving leucocyte in two consecutive frames to be determined and the leucocyte velocity to be calculated.^{7 20} Using this method, leucocyte velocity values of in retinal arteries, retinal veins, retinal capillaries, and in the choroid can be calculated.¹⁸

Another method of quantifying leucocyte velocity is to take advantage of the interlaced scanning system of the SLO. It has been found that in digital SLO sequences moving leucocytes travel in pairs (see Fig 2); the basis for this feature is that the SLO uses interlaced scanning to

compose each image frame. An image frame is composed of an odd field and an even field, and since the leucocyte is moving relatively fast the same leucocyte is scanned twice and erroneously appears as two cells (Fig 2). Since the scanning time is known and the direct pixel distance can be measured, the velocity can be calculated. A computer program can be formulated to identify these cells and calculate the distance between a pair of cells.¹⁶

These methods have provided values for leucocyte velocity in retinal vessels and the choroid in different species. In retinal capillaries the value of leucocyte velocity has been measured at 1.4 mm/s for rats,²¹ 0.92 mm/s for cynomolgus monkeys,⁷ and 1.37–1.41 mm/s for human¹⁵ foveal capillaries. In comparison, the blue field entoptic (BFE) method shows a human macular capillary leucocyte velocity of 0.89 mm/s.²² The difference in values of leucocyte velocity between the BFE method and human fluorescent leucocyte angiography may be due to different anatomical positions of measured cells by the entoptic method and the subjective nature using the BFE method compared with fluorescent leucocyte angiography.²²

Application of fluorescent leucocyte angiography to studies of retinal and choroidal pathology

The benefits of these methods are shown in studies of disease processes.

ANIMAL MODELS OF UVEITIS

The role of leucocytes is critical to the pathogenesis of any inflammatory condition. Although there have been numerous studies showing leucocytes circulating in vivo in areas outside the central nervous system,^{23, 24} little is known about how leucocytes circulate in ocular inflammation. Recently, SLO studies have shown the leucocyte flow patterns that occur in retinal and choroidal inflammation.

Acridine orange angiography has been used to study endotoxin induced uveitis (EIU)⁸ and experimental autoimmune uveoretinitis (EAU).⁶ In EIU the leucocytes are found to roll in the retinal venules and studies of EAU have also shown similar results.⁹ However, since these studies have been performed using acridine orange angiography, most of the visualised circulating leucocytes are likely to be neutrophils. Little is known about how lymphocytes circulate in retinal and choroidal inflammation.

DIABETIC RETINOPATHY AND RETINAL ISCHAEMIA

Acridine orange angiography has been used to study the pathogenesis of diabetic retinal microangiopathy. Using streptozocin induced diabetic rats, it has been found that leucocytes adhere to the retinal capillary endothelia in vivo, plugging the lumen.²⁵ This may be one of the factors that contributes to the capillary occlusion, subsequent vascular non-perfusion, and endothelial cell loss observed in early diabetic retinopathy. The work confirms histological studies showing leucocyte plugging in the retinal vessels in diabetic rats.²⁶

Another study, using acridine orange in an animal model of retinal ischaemia reperfusion injury, shows the presence of rolling leucocytes in retinal venules. Leucocyte plugging of retinal capillaries in ischaemic retina is also found.²⁷ This corroborates evidence found in studies outside the eye of ischaemia reperfusion injury²⁸ and the results indicate that similar events may follow retinal ischaemia.²⁷

Acridine orange angiography has also demonstrated the effects of retinal laser photocoagulation on leucocyte circulation. Leucocyte flow was found to slow down in laser treated retinal tissue, as well as the adjacent untreated tissue.²⁹

ASSESSMENT OF THERAPEUTIC AGENTS IN RETINAL INFLAMMATION

By using leucocyte angiography in EIU, the effects of immunomodulatory agents have been assessed by measuring the changes in leucocyte behaviour during retinal inflammation. Prednisolone and platelet activating factor have been shown to reduce leucocyte adherence in EIU in vivo.³⁰ The action of agents such as interferon has also been assessed and is found to increase leucocyte adhesion to retinal vessels.²⁹

The effect of blocking the action of adhesion molecules such as P-selectin has also been assessed. Using acridine orange angiography in animals with EIU, the number of rolling leucocytes was greatly reduced in animals treated with monoclonal antibodies against P-selectin compared with controls.³¹

ASSESSMENT OF LEUCOCYTE CIRCULATION IN HUMANS

Yang *et al* have shown that autologous sodium fluorescein labelled leucocytes (leucocytes collected from 50 ml of blood) can be observed circulating in the fundus.¹⁵ The study provides the first direct measurement of leucocytes in the human retinal circulation. However, an improvement of this method may be found by the use of fluorescent markers such as carboxyfluorescein diacetate and calcein AM. These agents provide brighter and more stable fluorescent cell labelling than sodium fluorescein and, in future, may be used in human studies.^{16, 32}

There has been a debate regarding the appearances of SLO fundus fluorescein angiography images in humans. During SLO fluorescein angiography, it is found that hyperfluorescent “dots” can be observed flowing through the perifoveal capillaries. The key question is do these hyperfluorescent dots represent fluorescently stained leucocytes or merely fluorescent segments of plasma between rouleaux of red blood cells?^{33, 34} A study by Yang *et al*, using fluorescent leucocyte angiography, has shown the presence of hyperfluorescent dots after injecting fluorescent labelled leucocytes and these appear similar to those observed in SLO fluorescein angiography.¹⁵

Future applications of in vivo leucocyte angiography

As leucocytes have a central role in so many disease processes, the use of SLO technology has the potential to increase our understanding of how leucocytes behave in vivo in retinal and choroidal diseases such as retinal vasculopathies and chorioretinal inflammation.

Methods of leucocyte angiography, which allow visualisation of labelled leucocyte subsets, may reveal the temporal events that lead to individual leucocyte subclasses to cause retinal and choroidal inflammation. Histopathological studies of experimental autoimmune uveitis have shown the presence of antigen specific T lymphocytes in the retina and choroid.³⁵ A method to observe this traffic in vivo may demonstrate the precise events of T cell migration into the retinal and choroidal tissue.

A strategy to visualise the circulation of the different subsets of leucocytes such as CD4, CD8 cells, monocytes, and neutrophils could help to distinguish the different phases of the immune response in the fundus. For example, observation of a transferred population of either cytotoxic T cells (CD8) or monocytes may determine the start of the effector phase of chronic inflammation. Animal models of uveitis have already shown that molecular changes occur to the vascular endothelia of the retina and choroid before onset of disease³⁶ and in future in vivo fluorescent leucocyte angiography could help in the early detection of impending inflammation.

It has already been mentioned that some of the mechanisms that influence leucocyte adhesion in an

inflamed retinal endothelium have been studied using inhibitory monoclonal antibodies and other therapeutic agents.³¹ The use of these methods allows other adhesion molecules, such as LFA-1 and VLA-4, to be studied and future investigations may allow the different molecular events involved in leucocyte homing in the retina and choroid to be determined. The benefit of this information is that it will allow new treatment strategies for retinal and choroidal inflammation to be developed.

Fluorescent leucocyte angiography in humans can be applied to examine changes in leucocyte velocity in diabetic retinopathy and other retinal vasculopathies and provides an objective method to measure leucocyte velocity. This may allow the earlier detection of retinal ischaemia and thus provides the clinician with another tool for the management of patients with retinal vascular disease.

Conclusions

The SLO is showing a way of observing the immune system in action in the fundus. Using animal models, opportunities are here to refine our knowledge on how different leucocytes interact during the development of diseases such as posterior uveitis and diabetic retinopathy. Different treatment modalities can be assessed in vivo and may help us to develop new therapeutic strategies for retinal and choroidal pathology. The feasibility of leucocyte imaging studies in the human fundus now offers the SLO an important role in the clinical management of patients.

Proprietary interest: Nil.
Grant support: Wellcome Trust.

PARWEZ HOSSAIN

Academic Department of Ophthalmology, Nottingham University Hospital, Queen's Medical Centre, Nottingham NG7 2UH

- Chan CC, Li Q. Immunopathology of uveitis. *Br J Ophthalmol* 1999;**82**:91–6.
- Firrell EB, Lipowsky HH. Leukocyte margination and deformation in mesenteric venules of rats. *Am J Physiol* 1999;**256**:1667–74.
- Von Andrian UH. Intravital microscopy of the peripheral lymph node microcirculation in mice. *Microcirculation* 1999;**3**:287–300.
- Manivannan A, Sharp PF, Phillips RP, et al. Digital fundus imaging using a scanning laser ophthalmoscope. *Physiol Meas* 1993;**14**:43–56.
- Kimura H, Kiryu J, Nishiwaki H, et al. A new fluorescent imaging procedure in vivo for evaluation of the retinal microcirculation in rats. *Curr Eye Res* 1995;**14**:223–8.
- Parnaby-Price A, Stanford MR, Biggerstaff J, et al. Leukocyte trafficking in experimental autoimmune uveitis in vivo. *J Leuk Biol* 1998;**64**:434–40.
- Nishiwaki H, Ogura Y, Kimura H, et al. Quantitative evaluation of leucocyte dynamics in retinal microcirculation. *Invest Ophthalmol Vis Sci* 1995;**36**:123–30.
- Miyamoto K, Ogura Y, Hamada M, et al. In vivo quantification of leucocyte behaviour in the retina during endotoxin-induced uveitis. *Invest Ophthalmol Vis Sci* 1996;**37**:2708–15.
- Molnar J, Petofi S, Kurihara T, et al. Antiplasmid and carcinogenic molecular orbitals of benz[c]acridine and related compounds. *Anticancer Res* 1993;**13**:263–6.
- Zdolsek JM, Olsson GM, Brunk UT. Photooxidative damage to lysosomes of cultured macrophages by acridine orange. *Photochem Photobiol* 1990;**51**:67–76.
- Fillacier K, Peyman GA, Luo Q, et al. Study of lymphocyte dynamics in the ocular circulation: technique of labelling cells. *Curr Eye Res* 1995;**14**:579–84.
- Horan PK, Melnicoff MJ, Jensen BD, et al. Fluorescent cell labelling for in vivo and in vitro cell tracking. *Methods Cell Biol* 1990;**33**:469–90.
- Kim J, Yang Y, Shin B, et al. Visualisation and flow of platelets and leucocytes in vivo in rat retinal and choroidal vessels. *Ophthalmic Res* 1997;**29**:374–80.
- Le Gargasson JF, Paques M, Guez JE, et al. Scanning laser ophthalmoscope imaging of fluorescein-labelled blood cells. *Graefes Arch Clin Exp Ophthalmol* 1997;**235**:56–8.
- Yang Y, Kim S, Kim J. Fluorescent dots in fluorescein angiography and fluorescein leucocyte angiography using a scanning laser ophthalmoscope in humans. *Ophthalmology* 1997;**104**:1670–6.
- Hossain P, Liversidge J, Cree MJ, et al. In vivo cell tracking by scanning laser ophthalmoscopy: quantification of leucocyte kinetics. *Invest Ophthalmol Vis Sci* 1998;**39**:1879–87.
- Price EA, Coombe DR, Murray JC. A simple fluorometric assay for quantifying the adhesion of tumour cells to endothelial monolayers. *Clin Exp Metastasis* 1995;**13**:155–64.
- Matsuda N, Ogura Y, Nishiwaki H, et al. Visualisation of leucocyte dynamics in the choroid with indocyanine green. *Invest Ophthalmol Vis Sci* 1996;**37**:2228–33.
- Fallon TJ, Maxwell DL, Kohner EM. Measurement of retinal blood flow in diabetes by the blue field entoptic phenomenon. *Br J Ophthalmol* 1987;**70**:1410–15.
- Yang Y, Moon S, Lee S, et al. Measurement of retinal blood flow with fluorescein leucocyte angiography using a scanning laser ophthalmoscope in rabbits. *Br J Ophthalmol* 1996;**80**:475–9.
- Nishiwaki H, Ogura Y, Kimura H, et al. Visualisation and quantitative analysis of leucocyte dynamics in retinal microcirculation of rats. *Invest Ophthalmol Vis Sci* 1996;**37**:1341–7.
- Arend O, Harris A, Sponsel WE, et al. Macular capillary particle velocities: a blue field and scanning laser comparison. *Graefes Arch Clin Exp Ophthalmol* 1995;**233**:244–9.
- Springer TA. Traffic signals for lymphocyte recirculation and leukocyte emigration: the multistep paradigm. *Cell* 1994;**76**:301–14.
- Muller WA. Transendothelial migration of leukocytes. In: Peltz G, ed. *Leukocyte recruitment in inflammatory disease*. Austin, Texas: RG Landes Company, 1996:3–18.
- Miyamoto K, Hiroshiba N, Tsujikawa A, et al. In vivo demonstration of increased leucocyte entrapment in retinal microcirculation of diabetic rats. *Invest Ophthalmol Vis Sci* 1998;**39**:2190–4.
- Schroder S, Palinski W, Schmid-Schonhein GW. Activated monocytes and granulocytes, capillary nonperfusion and neovascularisation in diabetic retinopathy. *Am J Pathol* 1991;**139**:81–100.
- Tsujikawa A, Ogura Y, Hiroshiba N, et al. In vivo evaluation of leucocyte dynamics in retinal ischaemia reperfusion injury. *Invest Ophthalmol Vis Sci* 1998;**39**:793–800.
- Romson JL, Hook BG, Kunkel SL, et al. Reduction of the extent of ischaemic myocardial injury by neutrophil depletion in the dog. *Circulation* 1983;**67**:1016–10.
- Hiroshiba N, Ogura Y, Nishiwaki H, et al. Alterations of retinal microcirculation in response to scatter photocoagulation. *Invest Ophthalmol Vis Sci* 1998;**39**:769–76.
- Nishiwaki H, Ogura Y, Miyamoto K, et al. Prednisolone, platelet-activating factor receptor antagonist, or superoxide dismutase reduced leucocyte entrapment induced by interferon alpha in retinal microcirculation. *Invest Ophthalmol Vis Sci* 1997;**38**:811–16.
- Miyamoto K, Ogura Y, Hamada M, et al. In vivo neutralisation of P-selectin inhibits leucocyte-endothelial interactions in retinal microcirculation during ocular inflammation. *Microvasc Res* 1998;**55**:230–40.
- Braut-Boucher F, Pichon J, Rat P, et al. A non-isotopic, highly sensitive, fluorimetric, cell-cell adhesion microplate assay using calcein AM-labeled lymphocytes. *J Immunol Methods* 1995;**178**:41–51.
- Tanaka T, Muraoka K, Shimizu K. Fluorescein fundus angiography with scanning laser ophthalmoscope. *Ophthalmology* 1991;**98**:1824–9.
- Nasemann JE, Muller M. Scanning laser angiography. In: Nasemann JE, Burk R, eds. *Scanning laser ophthalmoscope and tomography*. 1st ed. Munich: Quinlensen, 1990:63–79.
- Prendergast RA, Liff CE, Coskuncan NM, et al. T cell traffic and the inflammatory response in experimental autoimmune uveoretinitis. *Invest Ophthalmol Vis Sci* 1998;**39**:754–62.
- Whitcup SM, DeBarge LR, Caspi RR. Monoclonal antibodies against ICAM-1 (CD54) and LFA-1 (CD11A/CD18) inhibit experimental autoimmune uveitis. *Clin Immunol Immunopathol* 1993;**67**:143–50.



Scanning laser ophthalmoscopy and fundus fluorescent leucocyte angiography

PARWEZ HOSSAIN

Br J Ophthalmol 1999 83: 1250-1253

doi: 10.1136/bjo.83.11.1250

Updated information and services can be found at:

<http://bjo.bmj.com/content/83/11/1250.full.html>

References

These include:

This article cites 34 articles, 14 of which can be accessed free at:

<http://bjo.bmj.com/content/83/11/1250.full.html#ref-list-1>

Article cited in:

<http://bjo.bmj.com/content/83/11/1250.full.html#related-urls>

Email alerting service

Receive free email alerts when new articles cite this article. Sign up in the box at the top right corner of the online article.

Notes

To request permissions go to:

<http://group.bmj.com/group/rights-licensing/permissions>

To order reprints go to:

<http://journals.bmj.com/cgi/reprintform>

To subscribe to BMJ go to:

<http://group.bmj.com/subscribe/>