

Indocyanine green guided laser photocoagulation in patients with occult choroidal neovascularisation

Andreas W A Weinberger, Hildegard Knabben, Uta Solbach, Sebastian Wolf

Abstract

Aims—To determine whether indocyanine green (ICG) guided laser photocoagulation of occult choroidal neovascularisations (OCNV) is beneficial for patients with occult choroidal neovascularisation secondary to age related macular degeneration (AMD).

Methods—A prospective pilot study was performed in 21 eyes with OCNV secondary to AMD that could be identified extrafoveolarly or juxtafoveolarly in an early ICG angiographic study. Laser photocoagulation was applied to the neovascular membrane identified in the early ICG angiographic study.

Results—Visual acuity ranged from 20/400 to 20/20 (logMAR 0.54 (SD 0.29)) before and hand movements and 20/30 (logMAR 0.81 (0.69)) at the last follow up after laser photocoagulation. During the follow up (30 (13) months) vision improved in four eyes (two lines), in seven eyes the initial visual acuity could be stabilised (two lines), in five eyes vision dropped moderately (three to five lines), and in five eyes vision decreased severely (six or more lines). Recurrences (seven patients) or persistent CNV (six patients) was observed in 13 patients.

Conclusion—This preliminary study of ICG guided laser photocoagulation of occult extrafoveal and juxtafoveal choroidal neovascularisations suggests that this technique may improve the visual prognosis of these patients. Further prospective controlled studies are necessary to confirm these data.

(Br J Ophthalmol 1999;83:168-172)

Age related macular degeneration (AMD) is the most common cause of vision loss in the Western world.¹ In the majority of cases, the loss of central vision is secondary to exudative changes and fibrovascular scarring following choroidal neovascularisation (CNV) or vascularised pigment epithelial detachment (PED). These lesions are commonly associated with subretinal exudation, blood, and lipid deposition. The Macular Photocoagulation Study demonstrated that laser photocoagulation of well defined CNV improved the visual outcome compared with the natural course.^{2,3} However, most patients with newly diagnosed exudative maculopathy secondary to AMD have poorly defined or occult choroidal neovascularisation (OCNV) that is not amenable to photocoagulation therapy by the standards

recommended by the Macular Photocoagulation Study Group.⁴

Recently, indocyanine green angiography (ICGA) has become a clinical tool in the diagnosis and management of choroidal neovascular membranes secondary to AMD.⁵⁻¹¹ The infrared absorption and emission spectrum of indocyanine green dye helps to delineate OCNV in many cases since it is capable of penetrating the retinal pigment epithelium, exudates, and, to some degree, even overlying blood.¹²

In general, OCNV can be classified into two groups depending on the clinical manifestation¹¹: group 1 includes patients presenting with OCNV in association with PED, group 2 includes patients with CNV beneath the retinal pigment epithelium without a distinct PED. The latter corresponds to the type 2 CNV defined by the MPS.¹³

We and others have reported previously that OCNV defined by the MPS standards could be converted into well defined CNV in up to 50% of cases by ICGA.¹⁴⁻¹⁶ However, depending on the imaging technique various approaches were used to delineate OCNV.^{6,11,14,17,18} In this study we report our results of laser photocoagulation of OCNV that could be visualised in the early ICGA studies using a scanning laser ophthalmoscope.

Patients and methods

A total of 175 patients with AMD who were followed at the outpatient department of the University Hospital Aachen were recruited to the study. Inclusion criteria were age older than 51 years and the presence of OCNV in the fluorescein angiogram (FA). Patients were excluded if they had undergone previous treatment for AMD such as drusen photocoagulation, laser photocoagulation, or radiation therapy for exudative AMD or had any other eye disease that affected visual acuity.

Patients were included in the pilot study of ICG guided argon laser photocoagulation if the early ICGA studies revealed a juxtafoveal or extrafoveal choroidal neovascular network. Additional inclusion criteria were visual acuity equal to or better than 20/400, size of CNV smaller than four disc areas, and duration of symptoms less than 6 weeks. After the experimental nature of the treatment was explained to the patients informed consent was obtained.

Initial examination included a postrefractive ophthalmological examination to determine the best corrected Snellen visual acuity, followed by slit lamp biomicroscopy, Goldmann applanation tonometry, indirect and

Augenlinik der Med
Fak der RWTH
Aachen, Aachen,
Germany
A W A Weinberger
H Knabben
U Solbach
S Wolf

Correspondence to:
Dr S Wolf, Augenlinik der
Med Fak der RWTH
Aachen, Pauwelsstrasse 30,
52057 Aachen, Germany.

Accepted for publication
1 September 1998

Table 1 Visual acuity of study eyes and outcome during follow up graded as “improved” (I), “stabilised” (S), “decreased” (D), or “severely decreased” (SD)

Eye No	Baseline visual acuity	6 months		12 months		24 months		36 months		No of re-treatments
		Visual acuity	Outcome	Visual acuity	Outcome	Visual acuity	Outcome	Visual acuity	Outcome	
1	20/20	20/20	S	20/20	S	20/20	S	20/25	S	0
2	20/30	20/250	SD	20/70	D	20/200	SD	20/200	SD	2
3	20/30	20/40	S	20/70	D	—	—	—	—	0
4	20/30	20/20	I	20/20	I	—	—	—	—	0
5*	20/30	20/20	S	20/20	I	20/25	S	—	—	0
6	20/40	20/100	D	20/150	D	—	—	—	—	1
7*	20/40	20/60	S	20/200	SD	20/200	SD	20/200	SD	3
8	20/50	20/40	S	20/40	S	20/40	S	—	—	0
9	20/70	20/25	I	20/30	I	20/50	S	20/70	S	3
10	20/80	20/200	D	20/200	D	—	—	—	—	2
11	20/80	20/200	D	20/400	SD	20/400	SD	20/400	SD	1
12	20/100	20/800	SD	20/800	SD	20/800	SD	—	—	0
13	20/100	20/70	S	20/50	I	20/100	S	20/200	D	2
14	20/100	20/70	S	20/50	I	20/200	D	CF	SD	2
15	20/100	20/70	S	20/100	S	20/200	D	20/200	D	1
16	20/100	20/70	S	20/100	S	—	—	—	—	2
17	20/100	20/50	I	20/50	I	—	—	—	—	1
18	20/100	20/50	I	20/50	I	20/200	D	20/200	D	0
19	20/100	20/25	I	20/25	I	—	—	—	—	1
20	20/125	20/50	I	20/50	I	20/40	I	20/30	I	2
21	20/400	20/200	I	20/200	I	20/400	S	—	—	0

*Eyes with pigment epithelial detachment (PED).

direct ophthalmoscopy, colour fundus photography, fluorescein angiography (FA), and ICGA. Our technique of ICGA using a scanning laser ophthalmoscope (SLO 101, Rodenstock, Germany; HRA, Heidelberg Engineering, Germany) has been described elsewhere.⁸ After diagnostic ICGA was performed the neovascular membrane was traced and then transposed to a FA picture using a

customised digital image manipulation software (NIH image 1.6). We performed ICG guided laser photocoagulation with argon green to the neovascular membrane. Laser photocoagulation was performed according to a standard protocol similar to the MPS guidelines. The area of the visible extrafoveal chorioidal neovascular network was covered with laser confluent burns. In addition, treatment was to extend 100 µm beyond the boundaries of the neovascular membrane. In general, we used a 200 µm spot with a 0.5–1.0 second duration.

Follow up visits were scheduled at 2 weeks, 6 weeks, 3 months, 6 months, and in 6 month intervals thereafter. At each visit a postrefractive ophthalmological examination to determine the best corrected Snellen visual acuity, followed by slit lamp biomicroscopy, Goldmann applanation tonometry, indirect and direct ophthalmoscopy, colour fundus photography, FA, and ICG were performed. In cases of membrane persistency (neovascular network identifiable with ICGA or FA within 6 weeks after initial photocoagulation) or recurrence (identifiable membrane later than 6 weeks after initial photocoagulation) patients received additional laser treatment.

At each follow up examination visual acuity was compared with the initial visual acuity and was considered “improved” if visual acuity improved by two or more lines, as “stable” if visual acuity did not change beyond two lines to the better or worse, as “moderate loss” if vision dropped three to five lines, and as “severe loss” if vision dropped more than six lines. For statistical analysis (Student’s *t* test, significance if $p < 0.05$) visual acuity data were transformed to log MAR values.

Results

A total of 21 eyes of 21 patients (12 female, 11 male) with a minimal follow up of 12 months were included in the pilot study of ICG guided argon laser photocoagulation. The patients’ ages ranged from 65 to 85 years (mean 73 (SD 5) years). Two eyes had a pigment epithelium

Table 2 Obliteration after laser photocoagulation observed in fluorescein angiograms (FA) and ICG angiograms (ICGA) during follow up

Follow up	Obliteration in FA (patients, (%))	Obliteration ICGA (patients, (%))	Retreatment (patients, (%))
2 weeks	9/21 (43)	13/21 (62)	8/21 (38)
6 weeks	12/21 (57)	14/21 (67)	9/21 (43)
6 months	14/21 (67)	14/21 (67)	7/21 (33)
12 months	13/21 (62)	15/21 (71)	8/21 (38)
24 months	9/14 (64)	11/14 (79)	5/14 (36)
36 months	6/10 (60)	9/10 (90)	4/10 (40)

Table 3 Percentage of eyes with improved, stabilised, decreased, and severely decreased visual acuity during follow up

Vision	6 months	12 months	18 months	24 months	36 months
Improved >2 lines	38.1%	47.7%	26.7%	7.1%	10%
Stabilised ±2 lines	38.1%	19.0%	46.7%	42.9%	20%
Decreased 3–5 lines	14.3%	19.0%	6.7%	21.4%	30%
Severely decreased >6 lines	9.5%	14.3%	20%	28.6%	40%
Number of patients	21	21	15	14	10

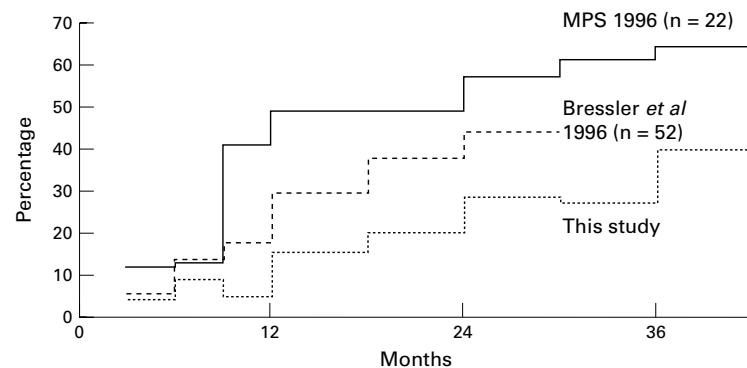


Figure 1 Cumulative percentage of patients with severe visual loss. Data from the Macular Photocoagulation Study (MPS)¹³ and from Bressler et al¹¹ for the natural course of occult CNV are included in the diagram.

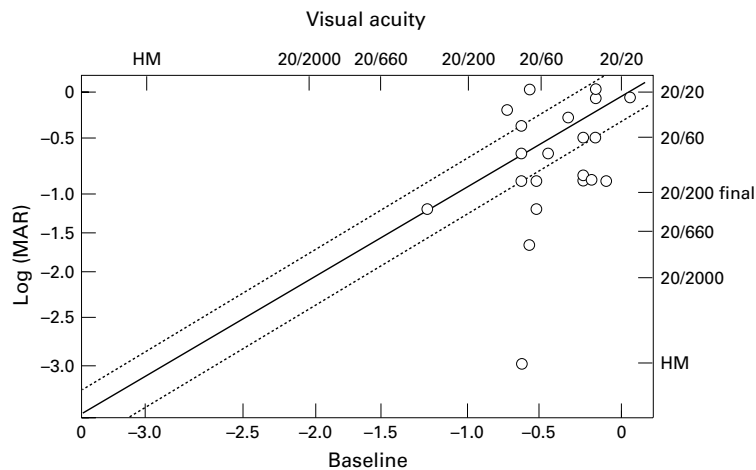


Figure 2 Scattergram depicting initial and final visual acuity. Points within the dotted lines indicate stabilised visual acuity, points above improved, and points under these lines decreased visual acuity.

Table 4 Visual acuity in logMAR units (mean (SD)) from study entry to 36 months of follow up

Timepoint	Log MAR
Baseline	0.54 (0.29)
6 months	0.52 (0.42)
12 months	0.56 (0.45)
18 months	0.79 (0.51)
24 months	0.79 (0.51)
36 months	1.01 (0.80)

detachment (group 1 OCNV, Table 1). Five additional patients showed an extrafoveal plaque-like lesion on late phase ICGA without an identifiable CNV network on early frames but were not included in the study.

Initial mean CNV size as seen in ICGA was 0.72 (0.49) disc diameters, mean initial exudation extension was moderate (1.48 (0.512)) on a scale from 0 to 4 (0 = no exudation, 4 = mas-

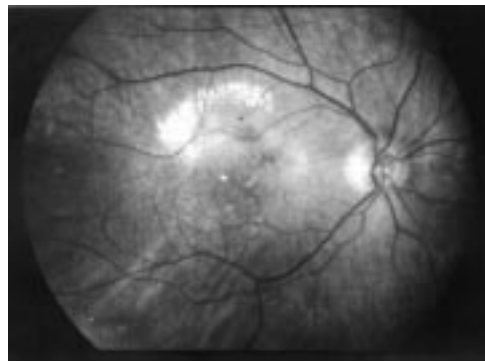


Figure 3 Fundus photograph of a patient with occult CNV (FA) and visible neovascular network in the early ICG angiographic study, visual acuity was 20/70.

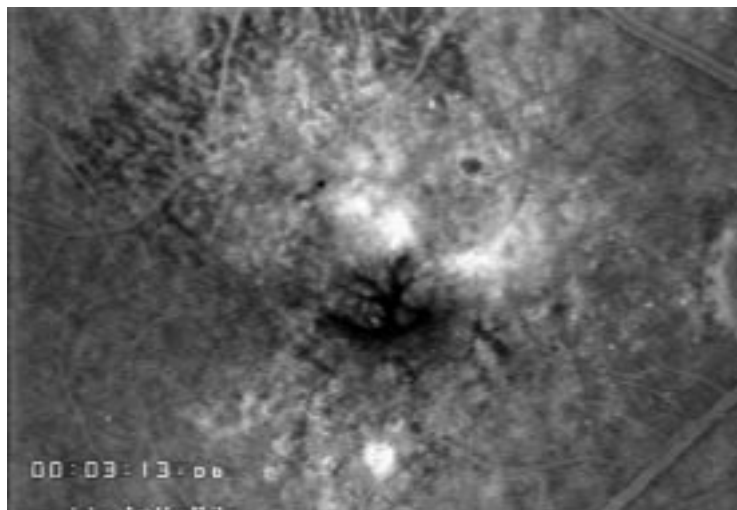


Figure 4 Fluorescein angiogram of a study patient showing diffuse leakage in the macular area and cystoid macular oedema.

sive exudation). Duration of symptoms before presenting to the clinic was 2 (1.1) weeks. Seven patients had recurrent CNV, six patients persistent CNV. Four recurrences were observed within 6 months after initial treatment, two recurrences between 6 and 12 months, and one recurrence 18 months after initial treatment. Patients received up to three retreatments during follow up. Persistent CNV was located within the laser photocoagulation scar while recurrence was observed in five cases at the foveal edge of the laser photocoagulation scar. No correlation between the initial appearance, location, or size of the OCNV and the rate of recurrence or persistence could be detected. Additionally, the differences between the tracing of ICGA defined CNV and OCNV in FA could not be related to the appearance of recurrences or persistence. Table 2 shows the number of eyes with persistent or recurrent neovascular membranes and the number of eyes that were re-treated at each follow up visit. Persistent CNV were best identified in ICGA, whereas recurrences were seen easier in FA. Treatment was performed using either ICGA or FA (Table 2).

The mean follow up was 30 (13) months, ranging from 12 to 48 months. Initial visual acuity ranged from 20/20 to 20/400 (mean log MAR 0.54 (0.29)). Final visual acuity was counting fingers (CF) to 20/25 (mean log MAR 0.81 (0.69)). Best visual acuity during follow up ranged from 20/20 to 20/800 (mean log MAR 0.34 (0.33)).

Stabilised or improved visual acuity was noted in 76% of eyes, whereas 10% of the eyes experienced a severe visual loss after 6 months of follow up. At 12 months of follow up 66% of eyes had stabilised or improved vision, 14% had a severe visual loss. After 24 months 50% of eyes had stabilised or improved vision while 29% had severe visual loss. Finally, after 36 months the percentage of eyes with stabilised or improved vision decreased to 30% and 40% had experienced a severe visual loss (Tables 3 and 4). The location of recurrent CNV (subfoveal or not) was of greater importance to visual outcome than the number of retreatments applied (Table 1). However, with an increasing number of recurrences the final visual outcome deteriorated. Mean logMAR was initially 0.54 (0.29), after 12 months 0.56 (0.45), after 24 months 0.79 (0.51) and after 36 months 1.01 (0.80) (see Table 4, Figs 1–8). The increase of the logMAR value after 36 months is statistical significant compared with baseline values.

Discussion

The treatment of patients with newly diagnosed, exudative AMD with an OCNV remains a challenge. At present, guidelines provided by the Macular Photocoagulation Study^{3, 19} require the presence of a well defined CNV diagnosed by fluorescein angiography. However, more than 80% of patients with newly diagnosed exudative AMD present with an untreatable or occult lesion.⁴ For this reason, new imaging techniques along with alternative treatment such as submacular

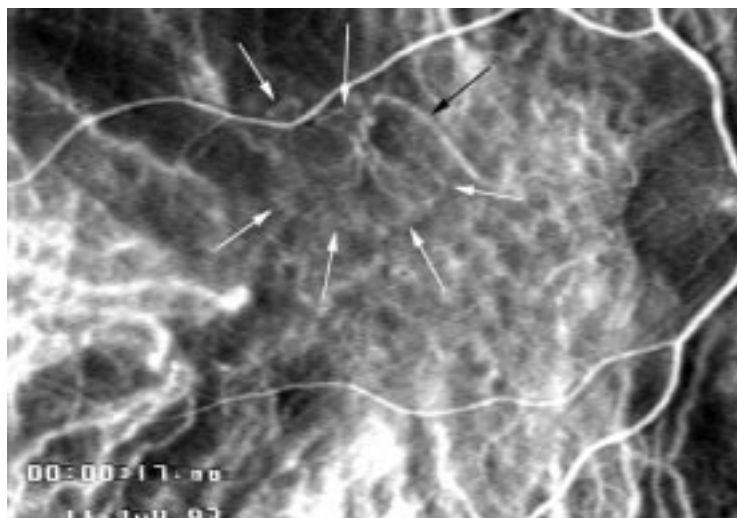


Figure 5 Early phase indocyanine green angiogram reveals a discrete neovascular network above the fovea with a feeding vessel at its nasal superior rim. The white arrows delineate the borders of the CNV, the dark arrow points to the feeding vessel. Same patient as in Figure 3.

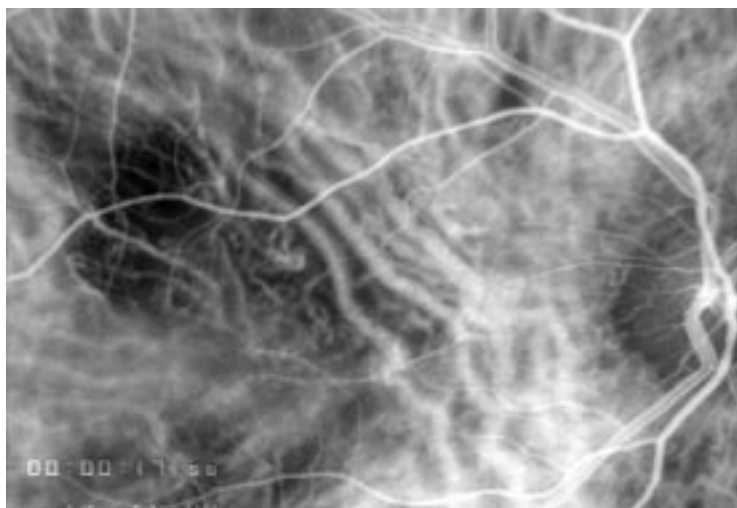


Figure 6 Follow up ICG angiogram 18 months after initial treatment. Visual acuity was 20/200. One re-treatment was performed. Same patient as in Figure 3.

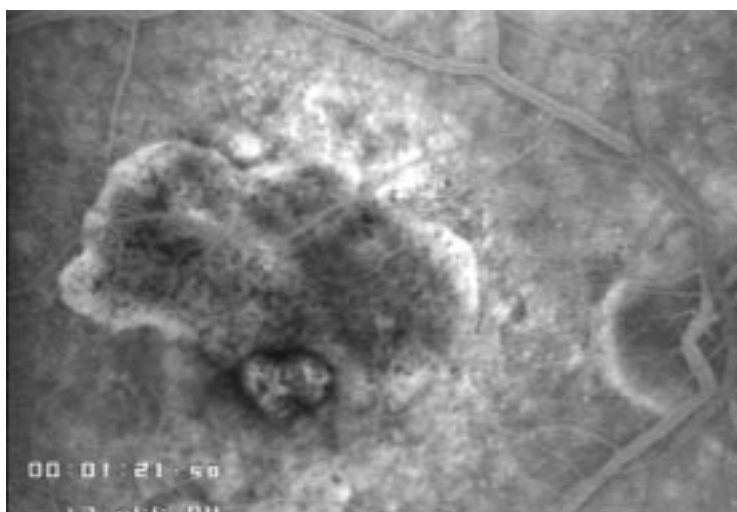


Figure 7 Follow up fluorescein angiogram 18 months after initial treatment. Visual acuity was 20/200. One re-treatment was performed. Same patient as in Figure 3.

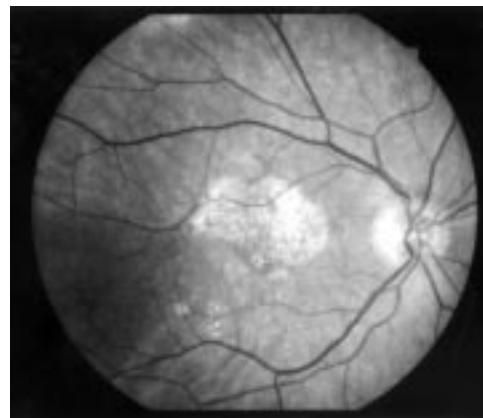


Figure 8 Fundus photograph of the patient 18 months after initial laser photocoagulation, visual acuity was 20/200.

surgery,²⁰ radiation therapy,²¹⁻²⁴ or antiangiogenic treatment²⁵ are under investigation to offer better diagnosis and treatment to patients with exudative AMD and OCNV. ICGA has been shown to be a valuable tool in identifying occult CNV and to convert them into visible CNV either as neovascular capillary network in the early phase angiogram or as plaque-like hyperfluorescence in the late phase angiogram.^{6 7 11 14-16 26 27} Recently, it has been demonstrated that plaque-like hyperfluorescence can be found in the late phase ICGA images not only in eyes with exudative AMD.²⁸ Therefore, plaque-like hyperfluorescence may not only represent active OCNV but other pathological changes of the RPE complex. In our study we included only eyes with OCNV that demonstrated a visible neovascular network in the early ICGA. These eyes may represent a special subgroup of eyes with OCNV that may be very similar to eyes with classic CNV. In our series of 175 patients we were able to identify the OCNV by ICGA in 94 cases. Most of them were subfoveal; therefore, only 12% of eyes with OCNV could be included in this study.

Previous pilot series of ICG guided laser photocoagulation have been encouraging and showed resolution of the exudative findings in 56% of cases. However, the mean follow up of patients treated has been 6 months only.⁶ Our data show that patients benefit from laser photocoagulation of OCNV which are identifiable in an early ICGA study. With follow up time the percentage of eyes with visual loss increases overall, but compared with the natural history and radiation therapy the prognosis is still better.^{13 29 30} Compared with the data published by the Macular Photocoagulation Study Group¹⁹ the visual outcome of our study patients compares with those who received laser photocoagulation for well defined extrafoveal and juxtafoveal membranes. This is not surprising since the ICGA basically converts OCNV into a visible neovascular network similar to a well defined CNV; thus, making them suitable for laser photocoagulation treatment. Anatomical differences between these membrane types seem to have little influence on the overall outcome.

Recurrence or persistence was observed in about 60% of cases. This number is similar to findings in classic CNV. Neither the initial appearance, location, size of the OCNV, nor differences between the tracing of ICGA defined CNV and OCNV in FA could be correlated with the appearance of recurrence or persistence. FA proved to be more sensitive than ICGA in detecting recurrence of CNV at the rim of the laser photocoagulation scar (except within the first 2 weeks after treatment) while persistence within the scar area was better defined by ICGA.

In order to validate our findings, further prospective controlled studies are required. Our data suggest that laser photocoagulation of choroidal neovascular membranes which are occult by the means of fluorescein angiography but well defined in the early ICGA study is beneficial for visual prognosis.

Proprietary interest: None

- 1 Kinik MM, Leibowitz HM, Colton T, et al. Prevalence of senile cataract, diabetic retinopathy, senile macula degeneration and open-angle glaucoma in the Framingham Eye Study. *Am J Ophthalmol* 1978;**85**:28–34.
- 2 Macular Photocoagulation Study Group. Laser photocoagulation of subfoveal neovascular lesions of age-related macular degeneration. *Arch Ophthalmol* 1993;**111**:1200–9.
- 3 Macular Photocoagulation Study Group. Five-year follow-up of fellow eyes of patients with age-related macular degeneration and unilateral extrafoveal choroidal neovascularization. *Arch Ophthalmol* 1993;**111**:1189–99.
- 4 Freund KB, Yannuzzi LA, Sorenson JA. Age-related macular degeneration and choroidal neovascularization. *Am J Ophthalmol* 1993;**115**:786–91.
- 5 Guyer DR, Puliafito CA, Mones JM, et al. Digital indocyanine-green angiography in chorioretinal disorders. *Ophthalmology* 1992;**99**:287–91.
- 6 Slakter JS, Yannuzzi LA, Sorenson JA, et al. A pilot study of indocyanine green videoangiography-guided laser photocoagulation of occult choroidal neovascularization in age-related macular degeneration. *Arch Ophthalmol* 1994;**112**:465–72.
- 7 Sorenson JA, Yannuzzi LA, Slakter JS, et al. A pilot study of digital indocyanine green videoangiography for recurrent occult choroidal neovascularization in age-related macular degeneration. *Arch Ophthalmol* 1994;**112**:473–9.
- 8 Wolf S, Remky A, Kuckelkorn R, et al. Indocyanine green angiography as clinical tool in the management of subretinal neovascularizations. *Invest Ophthalmol Vis Sci* 1993;**34**:1159.
- 9 Monés J, Guyer DR, Krupsky S, et al. Indocyanine green videoangiography. *Principles and Practice of Ophthalmology* 1994;**2**:718–26.
- 10 Wald KJ, Elsner AE, Wolf S, et al. Indocyanine green videoangiography for the imaging of choroidal neovascularization associated with macular degeneration. *Int Ophthalmol Clin* 1994;**34**:311–25.
- 11 Yannuzzi LA, Slakter JS, Sorenson JA, et al. Digital indocyanine green videoangiography and choroidal neovascularization. *Retina* 1992;**12**:191–223.
- 12 Hayashi K, Lacy JJ. Indocyanine green angiography of choroidal neovascular membranes. *Ophthalmologica* 1985;**190**:30–9.
- 13 Macular Photocoagulation Study Group. Occult choroidal neovascularisation. Influence on visual outcome in patients with age-related macular degeneration. *Arch Ophthalmol* 1996;**114**:1023.
- 14 Wolf S, Knabben H, Krombach G, et al. Indocyanine green angiography in patients with occult choroidal neovascularization. *Ger J Ophthalmol* 1996;**5**:251–6.
- 15 Wolf S, Remky A, Elsner AE, et al. Indocyanine green video angiography in patients with age-related maculopathy-related retinal pigment epithelial detachments. *Ger J Ophthalmol* 1994;**3**:224–7.
- 16 Guyer DR, Yannuzzi LA, Slakter JS, et al. Digital indocyanine-green videoangiography of occult choroidal neovascularization. *Ophthalmology* 1994;**101**:1727–37.
- 17 Wolf S, Wald KJ, Elsner AE, et al. Indocyanine green choroidal videoangiography: a comparison of imaging analysis with the scanning laser ophthalmoscope and the fundus camera. *Retina* 1993;**13**:266–9.
- 18 Kuck H, Inhoffen W, Schneider U, et al. Diagnosis of occult subretinal neovascularization in age-related macular degeneration by infrared scanning laser videoangiography. *Retina* 1993;**13**:36–9.
- 19 Macular Photocoagulation Study Group. Laser photocoagulation for juxtafoveal choroidal neovascularization. *Arch Ophthalmol* 1994;**112**:500–9.
- 20 Thomas MA, Grand MG, Williams DF, et al. Surgical management of subfoveal choroidal neovascularization. *Ophthalmology* 1992;**99**:952–68.
- 21 Bergink GJ, Deutman AF, van den Broek JFCM, et al. Radiation therapy for subfoveal choroidal neovascular membranes in age-related macular degeneration. *Graefes Arch Clin Exp Ophthalmol* 1994;**232**:591–8.
- 22 Finger PT, Berson A, Sherr D, et al. Radiation therapy for subretinal neovascularisation. *Ophthalmology* 1996;**103**:878–89.
- 23 Chakravarthy U, Houston RF, Archer DB. Treatment of age-related subfoveal neovascular membranes by teletherapy: a pilot study. *Br J Ophthalmol* 1993;**77**:265–73.
- 24 Schleicher UM, Andreopoulos D, Wolf S, et al. Radiotherapy of macular degeneration. Experience with two fractionation schemes. *Front Radiat Ther Oncol* 1997;**30**:253–8.
- 25 Chan CK, Kempin SJ, Noble SK, et al. The treatment of choroidal neovascular membranes by alpha interferon. *Ophthalmology* 1994;**101**:289–300.
- 26 Yannuzzi LA, Hope-Ross M, Slakter JS, et al. Analysis of vascularized pigment epithelial detachments using indocyanine green videoangiography. *Retina* 1994;**14**:99–113.
- 27 Kuhn D, Meunier I, Soubrane G, et al. Imaging of chorioretinal anastomoses in vascularized retinal pigment epithelium detachments. *Arch Ophthalmol* 1995;**113**:1392–8.
- 28 Guyer DR, Hanutsaha P, Yannuzzi LA, et al. Indocyanine green video angiography of drusen as a possible predictive indicator of exudative maculopathy. *Invest Ophthalmol Vis Sci* 1996;**37**:S413.
- 29 Soubrane G, Coscas G, François C, et al. Occult subretinal new vessels in age-related macular degeneration: natural history and early laser treatment. *Ophthalmology* 1990;**97**:649–57.
- 30 Stevens TS, Bressler NM, Maguire MG, et al. Occult choroidal neovascularisation in age-related macular degeneration. A natural history study. *Arch Ophthalmol* 1997;**115**:345–50.
- 31 Bressler NM, Maguire MG, Murphy PL, et al. Macular scatter ('grid') laser treatment of poorly demarcated subfoveal choroidal neovascularisation in age-related macular degeneration. *Arch Ophthalmol* 1996;**114**:1456–64.



Indocyanine green guided laser photocoagulation in patients with occult choroidal neovascularisation

Andreas W A Weinberger, Hildegard Knabben, Uta Solbach, et al.

Br J Ophthalmol 1999 83: 168-172

doi: 10.1136/bjo.83.2.168

Updated information and services can be found at:

<http://bjo.bmj.com/content/83/2/168.full.html>

These include:

References

This article cites 31 articles, 10 of which can be accessed free at:

<http://bjo.bmj.com/content/83/2/168.full.html#ref-list-1>

Article cited in:

<http://bjo.bmj.com/content/83/2/168.full.html#related-urls>

Email alerting service

Receive free email alerts when new articles cite this article. Sign up in the box at the top right corner of the online article.

Topic Collections

Articles on similar topics can be found in the following collections

[Ophthalmologic surgical procedures](#) (971 articles)

[Choroid](#) (435 articles)

[Retina](#) (1217 articles)

Notes

To request permissions go to:

<http://group.bmj.com/group/rights-licensing/permissions>

To order reprints go to:

<http://journals.bmj.com/cgi/reprintform>

To subscribe to BMJ go to:

<http://group.bmj.com/subscribe/>