

Aetiological study of the presumed ocular histoplasmosis syndrome in the Netherlands

J V Ongkosuwito, L M Kortbeek, A Van der Lelij, E Molicka, A Kijlstra, M D de Smet, M S A Suttorp-Schulten

Abstract

Aim—To investigate whether presumed ocular histoplasmosis syndrome in the Netherlands is caused by *Histoplasma capsulatum* and whether other risk factors might play a role in the pathogenesis of this syndrome.

Methods—23 patients were clinically diagnosed as having presumed ocular histoplasmosis syndrome based on the following criteria: peripapillary atrophy, punched out lesions, a macular disciform lesion or scar in one eye without vitritis. As controls, 66 sex and age matched healthy volunteers were used. Serum samples from both patients and controls were tested for the presence of antibodies against *H capsulatum*, *Toxoplasma gondii*, *Toxocara canis et cati*, *Ascaris* sp, and for the presence of antigens of *Cryptococcus neoformans*. Serum samples were also tested for the presence of autoantibodies against retinal or choroidal proteins. To investigate other risk factors, patients and controls were asked to fill in a health and travel related questionnaire. Ten patients with ocular toxoplasmosis were used as a disease control group.

Results—None of the patients with presumed ocular histoplasmosis syndrome or controls had circulating antibodies directed against *H capsulatum*. No risk factors could be identified and no indications for autoimmunity and no evidence for the role of the other infectious agents could be demonstrated.

Conclusions—In a Dutch group of patients fulfilling the criteria of a disease currently named presumed ocular histoplasmosis syndrome, no risk factors or relation with the fungus *H capsulatum* could be detected.

(Br J Ophthalmol 1999;83:535-539)

Presumed ocular histoplasmosis is a distinct syndrome characterised by a macular disciform lesion or scar caused by choroidal neovascularisation, peripapillary and chorioretinal scarring, and multiple, often sharply circumscribed white atrophic scars (punched out lesions) in combination with a clear vitreous¹ (Fig 1A and B). This syndrome is mainly seen in the midwest of the United States and is thought to be caused by *Histoplasma capsulatum*, endemic in this area.² In Europe a clinically similar syndrome has been observed in areas where the infectious agent *H capsulatum* is absent.^{3,4}

The direct role of *H capsulatum* in the pathogenesis of presumed ocular histoplasmosis has not been clearly demonstrated, hence the prefix “presumed”. This ocular syndrome is likely to be immunologically mediated.⁵ However, serologically there has been no confirmation of a direct correlation between *Histoplasma* infection and ocular histoplasmosis even in endemic areas.⁶ The relation has been based on epidemiological studies.^{7,8} In European patients the direct contact with this infectious agent preceding the ocular symptoms is unlikely, unless the patient has lived or travelled to endemic areas before the start of ocular symptoms. It is possible that *H capsulatum* does not play a role in this syndrome and that other risk factors are more important in the aetiology of presumed ocular histoplasmosis syndrome. This study was undertaken to investigate possible risk factors associated with the ocular syndrome presenting as ocular histoplasmosis in the Netherlands.

Patients and methods

PATIENTS

In this study, patients were included who had been clinically diagnosed in the ophthalmological departments of the university hospitals

Department of
Ophthalmology-Immunology,
Netherlands
Ophthalmic Research
Institute, Amsterdam,
Netherlands
J V Ongkosuwito
A Kijlstra
M S A Suttorp-Schulten

Department of
Ophthalmology,
Academic Medical
Centre, Amsterdam,
Netherlands
J V Ongkosuwito
A Kijlstra
M D de Smet

Diagnostic Laboratory
for Infectious Diseases
and Perinatal
Screening, National
Institute of Public
Health and the
Environment,
Bilthoven, Netherlands
L M Kortbeek

Department of
Ophthalmology,
F C Donders Institute,
University Hospital
Utrecht, Netherlands
A Van der Lelij

Department of
Ophthalmology,
Diaconessenhuis,
Leiden, Netherlands
E Molicka
M S A Suttorp-Schulten

Correspondence to:
Jenny V Ongkosuwito,
Netherlands Ophthalmic
Research Institute,
Department of
Ophthalmology-Immunology,
PO Box 12141, 1100 AC
Amsterdam, Netherlands.

Accepted for publication
25 November 1998

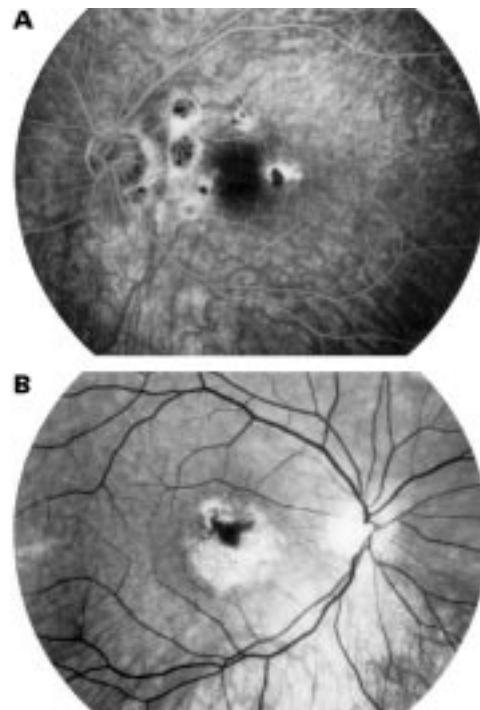


Figure 1 (A) Left eye with peripapillary atrophy, peripapillary punched out lesions. (B) Right eye with disciform macular lesion.

of Utrecht and Amsterdam as suffering from presumed ocular histoplasmosis. Only patients with both fundus photography and data concerning the ophthalmic examination and therapy were included. All patients had to exhibit a macular disciform lesion or scar caused by a choroidal neovascularisation, peripapillary and chorioretinal scarring, and multiple, often sharply circumscribed white atrophic scars (punched out lesions) in combination with a clear vitreous.¹

Fundus photographs were judged by an experienced ophthalmologist (MdS) in a masked fashion; fundus photographs from patients were mixed in a file with fundus photographs of patients with other macular disciform lesions. Patients were included in the study when the fundus pictures were judged as typical as described above.

From the patients who were diagnosed as having presumed ocular histoplasmosis syndrome, a serum sample was obtained and stored at the serum bank at the Netherlands Ophthalmic Research Institute.

Patients who were immunocompromised, or who suffered from any ocular disease that may mimic this syndrome, such as high myopia, age related macular degeneration, and other white dot syndromes were excluded from this study.

CONTROLS

Two control groups were used: group I consisted of 66 sex and age matched healthy volunteers; group II contained 10 patients diagnosed as having a toxoplasma chorioretinitis by means of clinical diagnosis which had been confirmed by intraocular antibody production against *Toxoplasma gondii* (and in five of these 10 cases also DNA of *T gondii* was detected by polymerase chain reaction (PCR)).

All subjects included in the study gave their informed consent to participate in this study.

METHODS

All patients and all healthy controls answered a detailed questionnaire. Questions were asked about travel to areas endemic for *H capsulatum*; possible contacts with infectious agents, use of untreated or poorly treated drinking water and swimming in endemic areas; contacts with pets or professional animal contacts; contact with soil and sand; eating habits particularly the consumption of raw meat, or the frequency of barbecuing. In addition, a medical history regarding systemic infectious diseases and previous blood transfusions was recorded.

LABORATORY TESTS

To exclude *H capsulatum* as a possible causative agent in our patients suffering from presumed ocular histoplasmosis, antibodies against this fungus were measured. Antibodies against *Toxoplasma gondii*, *Ascaris* sp, *Toxocara canis et cati* were tested since these parasites can also give symptoms of inflammation of the posterior segment. In order to exclude the presence of any other fungal infection, antigens of *Cryptococcus neoformans* were tested, since this fungus is also present in Europe. Antibodies against *Candida* sp were not tested, as *Candida*

sp is endemic in this region and all sera were expected to be positive. Sera were not tested for antibodies against *Blastomyces* and *Coccidioides* because both these fungi are not present in Europe and no positive serology has been described in European patients.

The presence of antibodies against *H capsulatum* was tested by immunodiffusion (Fungal immunodiffusion system, Meridian diagnostics, Inc, OH, USA) following the manufacturer's protocol.⁹ Immunodiffusion is highly specific for the detection of antibodies directed against *H capsulatum*.¹⁰ As a positive control, serum from a patient with an active systemic histoplasmosis was used (courtesy of Dr Wheat, Indianapolis, IN, USA).

The presence of *Cryptococcus neoformans* antigens was tested by a latex agglutination test (Crypto-LA test, Whampoule Laboratories, International Biological Labs, Inc, Cranbury, USA) according to the manufacturer's instructions.

The presence of antibodies to *T gondii* was tested in a 1:20 dilution and the presence of antibodies directed to *Toxocara canis et cati* and *Ascaris* sp was tested in a 1:40 dilution. These antibodies were measured by an in house enzyme linked immunosorbent assay at the Diagnostic Laboratory for Infectious Diseases and Perinatal Screening, National Institute of Public Health and the Environment, Bilthoven, Netherlands. Tests were considered positive when the respective dilutions showed a signal.

To exclude a possible autoimmune component we also tested for the presence of autoantibodies against retinal or choroidal proteins. Retina and choroid were retrieved from human donor eyes. Total protein extracts were obtained by dissolving retina or choroid tissue in SDS-PAGE loading buffer containing 2% SDS and 5% β -mercapto-ethanol followed by boiling for 5 minutes. After centrifugation, the proteins were size fractionated by SDS-PAGE gel electrophoresis and followed by western blotting. Blots were incubated with a 1:50 dilution of sera from patients and controls. After 1 hour incubation, blots were washed and incubated with peroxidase labelled rabbit anti-human immunoglobulins (Dako) for 1 hour. Blots were stained with diaminobenzidine tetrahydrochloride (Sigma-Aldrich Chemie, Zwijndrecht, Netherlands) and photographed directly after the reaction was stopped. Sera that gave bands other than the control sera were considered positive.

To further investigate the presence of autoantibodies, cryosections of rat eyes were incubated with sera of 13 patients with presumed ocular histoplasmosis in a 1:100 dilution for 2 hours. After washing one cryosection was incubated with peroxidase labelled rabbit anti-human immunoglobulins and one with peroxidase labelled rabbit anti-human IgG. The cryosections were stained with diaminobenzidine tetrahydrochloride. Cryosections were independently judged by two observers. As a negative control a sample of pooled normal human sera was used, and as a positive control a serum sample was used

Table 1 Participant characteristics

	Patients (n=23)	Controls (n=66)	Disease controls (n=10)
Median age (years)			
Female	40 (range 29–60)	42 (range 26–60)	46 (range 29–55)
Male	33 (range 28–48)	36 (range 26–44)	53 (range 36–65)
Mean age at start of symptoms (years)	30 (SD 6.5) (range 18–44)		
Time interval between start of symptoms and sample collection (years)	8 (SD 6.7) (range 0.5–23)		
Sex	16 F/7 M	49 F/17 M	7 F/3 M

Table 2 Results of tests to detect antibodies

	<i>H capsulatum</i>	<i>C neoformans</i> *	<i>T gondii</i>	<i>Toxocara sp</i>	<i>Ascaris sp</i>
Patients with presumed ocular histoplasmosis syndrome (n=23)	0 (0%)†	0 (0%)‡	13 (57%)	2 (8%)	6 (26%)
Controls (n=66)	0 (0%)	0 (0%)	42 (64%)	4 (6%)	22 (33%)
Controls with toxoplasma chorioretinitis (n=10)	0 (0%)	0 (0%)	10 (100%)	2 (20%)	8 (80%)

*Sera were tested for the presence of antigens of *C neoformans*.

†The positive control serum used showed only the presence of antibodies against *H capsulatum* and was negative in all other tests.

‡The positive control was included in the kit.

known to have antibodies against retinal antigens.

STATISTICS

Data were evaluated by the Student's *t* test, Fisher's exact probability test or χ^2 test.

Results

Twenty three patients with presumed ocular histoplasmosis syndrome were selected (median age 35 years; range 28–60), seven men (median age 33 years; range 28–48) and 16 women (median age 40 years; range 29–60). The mean age at the onset of symptoms was 30 years. Blood samples were collected in the course of the disease with a mean of 8 years after the start of symptoms, 15 of those samples were taken within 10 years after the onset of disease and eight within 5 years (Table 1).

As healthy controls, we used 17 men (median age 36 years, range 26–44) and 49 women (median age 42 years, range 26–60), from whom a venous blood sample was collected at the time the questionnaire was completed. Ten patients with toxoplasma chorioretinitis (mean age 50, range 29–65), three men and seven women, confirmed by detection of intraocular anti-*Toxoplasma* IgG production, were used as disease controls in the serological tests.

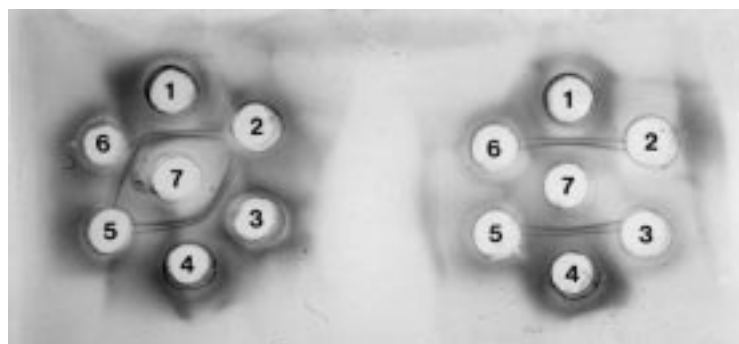


Figure 2 Immunodiffusion test for antibodies against *H capsulatum*. Left: positive control serum, showing H and M bands. Wells 1 and 4 positive serum provided with the kit, wells 2 and 5 serum from a patient positive for antibodies against *H capsulatum*, wells 3 and 6 serum from a patient negative for antibodies against *H capsulatum*. Well 7 Histoplasmin. Right: two negative sera. Wells 1 and 4 positive serum provided with the kit, wells 2, 3, 5, and 6 serum from two patients negative for antibodies against *H capsulatum*. Well 7 Histoplasmin.

LABORATORY TEST RESULTS

Testing for *H capsulatum* antibodies was negative in all people tested, both in patients and in controls (Table 2). The serum of the positive control, from a patient with systemic histoplasmosis, showed H and M bands in the immunodiffusion test (Fig 2).

All sera of patients and controls were negative for *C neoformans* antigens.

Thirteen of 23 patients (57%) with presumed ocular histoplasmosis syndrome were positive for IgG antibodies against *T gondii* compared with 42 of 66 healthy controls (64%). This was not significantly different ($p > 0.01$).

IgG antibodies to *Toxocara canis et cati* were positive in two out of 23 patients with presumed ocular histoplasmosis syndrome compared with four out of 66 healthy controls and three out of 10 patients with toxoplasma chorioretinitis ($p > 0.01$).

Six of 23 patients with presumed ocular histoplasmosis syndrome had IgG antibodies to *Ascaris sp* in their serum. Twenty two out of 66 controls (33%) had IgG antibodies, and eight of 10 patients (80%) with toxoplasma chorioretinitis. The patients with toxoplasma chorioretinitis had antibodies against *Ascaris sp* significantly more often than the healthy controls and patients with presumed ocular histoplasmosis ($p < 0.01$).

Sera from 23 patients and 20 healthy controls were tested for the presence of retinal or choroidal autoantibodies by western blotting. Eight patients had chorioretinal autoantibodies compared with five of the healthy controls. No distinctive banding pattern was seen between the two groups.

Analysis of chorioretinal autoantibodies using immunohistochemistry on cryosections did not reveal a positive staining in the patients tested.

RESULTS FROM THE QUESTIONNAIRE

Twenty two of 23 (95%) patients returned the questionnaire and all controls of group I (healthy volunteers). Only six out of 22 (27%) patients had lived or travelled to areas endemic for *H capsulatum* before the onset of their ocular symptoms compared with 38 out of 66

(57%) controls before obtaining the blood sample.

Animal contact was not significantly different between patients and controls. No difference could be demonstrated when comparing patients and controls who gardened with or without gloves.

In both groups, one participant was vegetarian, and no difference could be found in the frequency of barbecuing or eating "raw" meat.

None of the patients, nor any controls, had had therapy for infection with herpes viruses, *T gondii*, *H capsulatum*, or *Cryptococcus neoformans*.

One of the patients and eight of the controls remembered having had contact with *Ascaris* sp or being treated with mebendazole for an infection with *Ascaris* sp; this was not statistically significant.

Three of 22 patients had a blood transfusion some time before the onset of ocular symptoms, as did six of 66 controls. One of the patients and also one of the controls had suffered from gonorrhoea in the past.

Eight out of 22 patients did mention a period of stress around the onset of ocular symptoms, compared with 11 of 66 controls during a similar period before blood sampling. This seemed statistically significant ($p=0.05$). Patients indicated the start of a new job, moving to another town or pregnancy among stress factors.

Discussion

In Europe, an ocular syndrome identical to that called presumed ocular histoplasmosis syndrome in the USA has been described,^{3 4} while *H capsulatum* is not endemic in this area. Several studies support an association between *H capsulatum* infection and the classic ocular triad of presumed ocular histoplasmosis in humans. This association is mainly based on epidemiological data from endemic areas^{7 8} and animal models, in which *H capsulatum* was injected into the carotid artery of primates which developed atypical choroidal lesions 4 weeks after inoculation.¹¹ There are no reports of positive *H capsulatum* cultures in patients with presumed ocular histoplasmosis syndrome, but *H capsulatum* has been cultured from a patient with postoperative endophthalmitis.¹² In another report, two immunocompetent patients with systemic histoplasmosis (confirmed by antibodies in serum as well as in urine) showed choroiditis, but no intraocular fluid analysis was performed.¹³ In these two patients the clinical picture did not show the complete typical clinical characteristics of presumed ocular histoplasmosis syndrome.¹³ Furthermore, one would expect that opportunistic ocular infections should be more frequently seen in immunocompromised patients, as up to 16% of these patients have a disseminated infection by *H capsulatum* in endemic areas.¹⁴ In the literature, however, positive cultures from ocular fluid samples obtained from patients with AIDS are described only twice. In these two patients the clinical picture did not resemble the typical

clinical characteristics of presumed ocular histoplasmosis syndrome.^{15 16}

Serologically there has been no confirmation of a direct link between infection with *H capsulatum* and presumed ocular histoplasmosis syndrome, even in endemic areas. In histopathological studies of eyes from patients with presumed ocular histoplasmosis syndrome no direct correlation could be demonstrated by immunohistochemical staining.¹⁷ In surgically removed membranes of patients suffering from presumed ocular histoplasmosis no fungi could be detected by electron microscopy and only non-specific inflammatory reaction tissue could be shown.¹⁸ Therefore, the ocular changes might be late immunological reactions to a previous infection with *H capsulatum*, or *H capsulatum* does not play a role at all in this syndrome.^{7 19}

In our study, no risk factors could be identified through our questionnaire that might have played a role in the pathogenesis of presumed ocular histoplasmosis syndrome. Careful assessment of travelling, eating habits, and animal contacts did not reveal any shared possible infectious risks.

None of our patients with presumed ocular histoplasmosis syndrome showed serological evidence of previous contact with *H capsulatum*, as was also the case in the group of healthy controls and disease controls. It is generally assumed that the manifestations of presumed ocular histoplasmosis syndrome is a late sequela of a previous infection with *H capsulatum* and that the interval between the primary infection and the first ocular symptoms might take many years.²⁰ IgG antibodies against *H capsulatum* persist for years after an acute infection.²¹ Therefore, at least some of our patients with this ocular syndrome should have shown serological evidence of previous contact. Skin testing was not performed because of described reactivation of the ocular lesions in patients with macular disease.²²

It was possible to exclude as a causative mechanism other infectious agents that are present in Europe and that might induce chorioretinopathy, such as *C neoformans*, *T gondii*, *Toxocara* sp, and *Ascaris* sp. Of these, the first was negative in all people, while antibodies to the others were evenly distributed in all groups. When the group of patients with ocular toxoplasmosis (eight out of 10 had antibodies against *Ascaris* sp) was compared with the controls (22 out of 66 had antibodies against *Ascaris* sp), this difference seemed statistically significant ($p < 0.01$). But when the eight patients with ocular toxoplasmosis and positive serology against *Ascaris* sp were compared with the 19 controls who had antibodies against *Toxoplasma gondii* as well as antibodies against *Ascaris* sp the difference was not significant ($p = 0.2$). This might be due to similar risk factors shared by both groups for infection with *T gondii* and *Ascaris* sp.

Autoimmunity might also play an aetiological role in this syndrome. There have been reports of a relation with HLA-DRw2 or HLA-B7, showing a higher frequency in these patients with disciform lesions compared with

healthy people.^{23 24} Racial differences might also play a role as this ocular disease occurs predominantly in white females. This is in accordance with our results, which included only white Europeans.²⁵ Nevertheless, no clear evidence was found by western blotting and immunohistochemistry to suggest that the ocular syndrome might be the result of autoantibodies against choroid or retina.

In conclusion, no risk factors and no relation with the fungus *H capsulatum* could be detected. We therefore suggest that this ocular syndrome in patients from non-endemic areas should no longer be called presumed ocular histoplasmosis. The cause in our patients is probably multifactorial and might depend, as in other white dot syndromes, on interactions between triggering factors involved in presentation of antigens and the host immune system.²⁶ Subsequent inflammation around choriocapillary dendritic cells can lead to scars seen in several white dot syndromes.²⁶ Therefore, in European patients, it might be better to use as basis for the nomenclature not the aetiology but the clinical and histopathological presentation. Even in the United States presumed ocular histoplasmosis syndrome might be a misnomer; "multifocal choroidopathy" is, in our opinion, a more appropriate description.

We thank Dr L J Wheat from the Wishard Memorial Hospital, Indianapolis, Indiana, USA, for providing us with the serum of a patient with systemic histoplasmosis.

- 1 Gass JD, Wilkinson CP. Follow-up study of presumed ocular histoplasmosis. *Trans Am Acad Ophthalmol Otol* 1972;**76**:672-94.
- 2 Ellis FD, Schlaegel Jr TF. The geographic localization of presumed ocular histoplasmic choroiditis. *Am J Ophthalmol* 1973;**75**:953-6.
- 3 Suttorp-Schulten MSA, Bollemeijer JG, Bos PJM, et al. Presumed ocular histoplasmosis in the Netherlands: an area without histoplasmosis. *Br J Ophthalmol* 1997;**81**:7-11.
- 4 Braunstein RA, Rosen A, Bird AC. Ocular histoplasmosis syndrome in the United Kingdom. *Br J Ophthalmol* 1974;**58**:893-9.
- 5 Smith RE. Commentary on histoplasmosis. *Ocul Immunol Inflamm* 1997;**5**:69-70.
- 6 Brahmi Z, Wheat J, Rubin RH, et al. Humoral and cellular immune response in ocular histoplasmosis. *Ann Ophthalmol* 1985;**17**:440-4.
- 7 Smith RE, Ganley JP. An epidemiological study of presumed ocular histoplasmosis. *Trans Am Acad Ophthalmol Otolaryngol* 1971;**75**:994.
- 8 Ganley JP. Epidemiologic study of presumed ocular histoplasmosis. *Acta Ophthalmol Scand Suppl* 1973;**119**:1-63.
- 9 Ouchterlony O, Nilsson L-A. Immunodiffusion and immunoelectrophoresis. In: Weir DM, Blackwell C, Herzenberg LA, eds. *Handbook of experimental immunology. Vol 1. Immunochimistry*. Oxford: Blackwell, 1986:32.1-32.50.
- 10 Sekhon AS, Kaufman L, Kobayashi GS, et al. Comparative evaluation of the Premier enzyme immunoassay, micro-immunodiffusion and complement fixation tests for the detection of *Histoplasma capsulatum* var *capsulatum* antibodies. *Mycoses* 1994;**37**:313-16.
- 11 Smith RE. Natural history and reactivation studies of experimental ocular histoplasmosis in a primate model. *Trans Am Ophthalmol Soc* 1982;**80**:695-757.
- 12 Pulido JS, Folberg R, Carter KD, et al. Histoplasma capsulatum endophthalmitis after cataract extraction. *Ophthalmology* 1990;**97**:217-20.
- 13 Katz BJ, Scott WE, Folk JC. Acute histoplasmosis choroiditis in 2 immunocompetent brothers. *Arch Ophthalmol* 1997;**115**:1470-1472.
- 14 Neubauer MA, Bodensteiner DC. Disseminated histoplasmosis in patients with AIDS. *South Med J* 1992;**85**:1166-70.
- 15 Specht CS, Mitchell KT, Bauman AE, et al. Ocular histoplasmosis with retinitis in a patient with acquired immune deficiency syndrome. *Ophthalmology* 1991;**98**:1356-9.
- 16 Morinelli EN, Dugel PU, Riffenburgh R, et al. Infectious multifocal choroiditis in patients with acquired immune deficiency syndrome. *Ophthalmology* 1993;**100**:1014-21.
- 17 Makley TA, Craig EL, Werling K. Histopathology of ocular histoplasmosis. *Int Ophthalmol Clin* 1983;**23**:1-18.
- 18 Saxe SJ, Grossniklaus HE, Lopez PF, et al. Ultrastructural features of surgically excised subretinal neovascular membranes in the ocular histoplasmosis syndrome. *Arch Ophthalmol* 1993;**11**:88-95.
- 19 Suttorp-Schulten MSA. The etiology of the presumed ocular histoplasmosis syndrome. *Ocul Immunol Inflamm* 1997;**5**:71-2.
- 20 Gass JDM. Presumed ocular histoplasmosis syndrome (POHS). In: *Stereoscopic atlas of macular diseases: diagnosis and treatment*. 4th ed. St Louis: Mosby, 1997:130-47.
- 21 Wheat LJ, Smith EJ, Sathapatayavongs B, et al. Histoplasmosis in renal allograft recipients. *Arch Intern Med* 1983;**143**:703-7.
- 22 Schlaegel TF Jr, Weber JC, Helveston E, et al. Presumed histoplasmic choroiditis. *Am J Ophthalmol* 1967;**63**:919-25.
- 23 Meredith TA, Smith RE, Duquesnoy RJ. Association of HLA-DRw2 antigen with presumed ocular histoplasmosis. *Am J Ophthalmol* 1980;**89**:70-6.
- 24 Godfrey WA, Sabates R, Cross DE. Association of presumed ocular histoplasmosis with HLA-B7. *Am J Ophthalmol* 1978;**85**:854-8.
- 25 Baskin MA, Jampol LM, Huamonte FU, et al. Macular lesions in blacks with the presumed ocular histoplasmosis syndrome. *Ophthalmology* 1980;**89**:77-83.
- 26 BenEzra D, Forrester JV. Fundal white dots: the spectrum of a similar pathological process. *Br J Ophthalmol* 1995;**79**:856-60.



Aetiological study of the presumed ocular histoplasmosis syndrome in the Netherlands

J V Ongkosuwito, L M Kortbeek, A Van der Lelij, et al.

Br J Ophthalmol 1999 83: 535-539

doi: 10.1136/bjo.83.5.535

Updated information and services can be found at:

<http://bjo.bmj.com/content/83/5/535.full.html>

References

These include:

This article cites 24 articles, 5 of which can be accessed free at:

<http://bjo.bmj.com/content/83/5/535.full.html#ref-list-1>

Article cited in:

<http://bjo.bmj.com/content/83/5/535.full.html#related-urls>

Email alerting service

Receive free email alerts when new articles cite this article. Sign up in the box at the top right corner of the online article.

Topic Collections

Articles on similar topics can be found in the following collections

[Eye \(globe\)](#) (543 articles)

Notes

To request permissions go to:

<http://group.bmj.com/group/rights-licensing/permissions>

To order reprints go to:

<http://journals.bmj.com/cgi/reprintform>

To subscribe to BMJ go to:

<http://group.bmj.com/subscribe/>