

Ultrasound biomicroscopic measurement of development of anterior chamber angle

Hiroshi Kobayashi, Hisako Ono, Junichii Kiryu, Kaori Kobayashi, Takehisa Kondo

Abstract

Aim—To establish normative values for the anterior segment in normal infants and children in relation to age.

Methods—Anterior segments were measured in 46 normal infants and children (21 males and 25 females, aged from 1 to 60 months (mean 17.09 (SD 16.99) months)), by use of ultrasound biomicroscopy.

Results—Anterior chamber depth, trabecular-iris angle, angle opening (trabecular-iris) distances at 250 and 500 μm from the scleral spur, and the thickness of the thickest part of the iris were 1724–3473 μm (2505 (SD 480) μm), 15.35–44.79° (28.74 (7.46)°), 116–367 μm (247.4 (65.9) μm), 166–509 μm (349.5 (87.1) μm), and 249–579 μm (434.6 (74.6) μm), respectively. All factors in this study showed a significant correlation with logarithm of age ($r = 0.937$, $p = 0.0001$; $r = 0.867$, $p = 0.0001$; $r = 0.929$, $p = 0.0001$; $r = 0.917$, $p = 0.0001$; $r = 0.748$, $p = 0.0001$), and significantly correlated with each other.

Conclusions—Ultrasound biomicroscopy is a powerful tool for obtaining precise images and measurement of the development of the anterior segment in infants and children. Normative values were established for anterior segment dimensions in relation to age. Anterior chamber depth, trabecular-iris angle, angle opening distances at 250 and 500 μm from the scleral spur, and iris thickness showed linear increases in relation to logarithm of age.

(*Br J Ophthalmol* 1999;83:559–562)

Precise in vivo measurements of the developing anterior segment, in particular of the angle, are essential to understand the mechanism of congenital and developmental glaucoma.^{1,2} Conventional methods of evaluating the anterior chamber angle, such as gonioscopy and ultrasonic biometry, may not accurately assess the dimensions of the anterior chamber, leading to incorrect diagnoses.³ Measurements should be used that are quantitative. The advantage of ultrasound biomicroscopic technology is its accuracy and reproducibility.⁴ High resolution ultrasound biomicroscopy provides precise measurements of the angle as well as information on the mechanism of various types of glaucoma.^{5–13}

We have developed a method for measuring the anterior segment of infants and obtaining live images by use of ultrasound biomicroscopy and a muscle hook with topical

anaesthesia.¹⁴ Ultrasound biomicroscopy allows one to make precise measurements of the anterior segments of even premature neonates. It is encouraging that distinct images of the exact area of interest can be obtained by a simple control of the eyeball with a muscle hook. Even infants in poor medical condition can be examined in this way through the ports of the isolette. Our objective was to measure prospectively, for the first time, anterior chamber depth, angle width, and iris thickness in infants and children in order to develop normative values. Correlation of these variables with age, as well as with each other, was evaluated.

Patients and methods

PATIENTS

Forty six normal infants and children were selected for study. The study protocol and consent forms were approved by the human subjects committee on Amagasaki Hospital. Informed consent for each infant was obtained from at least one parent. Infants with malformations were excluded from the study, as were genetic disorders, suspected intrauterine infections, or retinopathy of prematurity greater than stage II.

ULTRASOUND BIOMICROSCOPIC MEASUREMENTS

Ophthalmic and ultrasound biomicroscopic measurements were made of the right eye of each infant. Ultrasonic biomicroscope 840 (Zeiss-Humphrey, San Leandro, CA, USA) with a 50 Hz transducer and ultrasound biomicroscope UX-02 (Rion, Tokyo, Japan) with a 30 Hz transducer were used. Each infant or child was placed in a supine position. For infants, an infant Bangarter speculum, rather than an eye cup, was used to separate the eyelids after a drop of 0.5% proxymetacaine (proparacaine) had been applied. The palpebral fissure was filled with 2.5% methylcellulose as a coupling medium. Scanning was performed by manipulating the eyeball with a muscle hook without pressure on the eyeball and placing the probe close to the area of interest. We repeated each measurement three times to confirm reproducibility and eliminate artefacts.

Anterior chamber depth (ACD) was measured as an axial distance from the internal corneal surface to the lens surface. Ultrasound biomicroscopic cross sectional views through the angle region were obtained for most of the measurements, which were made in the temporal meridian; views were as vertical as possible, as determined from the screen image. The following variables were measured: ACD,

Department of
Ophthalmology,
Amagasaki Hospital,
Amagasaki, Japan
H Kobayashi
H Ono

Department of
Ophthalmology and
Visual Science,
Graduate School of
Medicine Kyoto
University, Kyoto,
Japan
H Kobayashi
J Kiryu

Department of
Ophthalmology, Osaka
Red Cross Hospital,
Osaka, Japan
K Kobayashi

Department of
Ophthalmology, Kobe
City General Hospital,
Kobe, Japan
T Kondo

Correspondence to:
Hiroshi Kobayashi,
Department of
Ophthalmology, Amagasaki
Hospital, 1-1-1
Higashi-daimotsu-cho,
Amagasaki, Hyogo, 660,
Japan.

Accepted for publication
25 November 1998

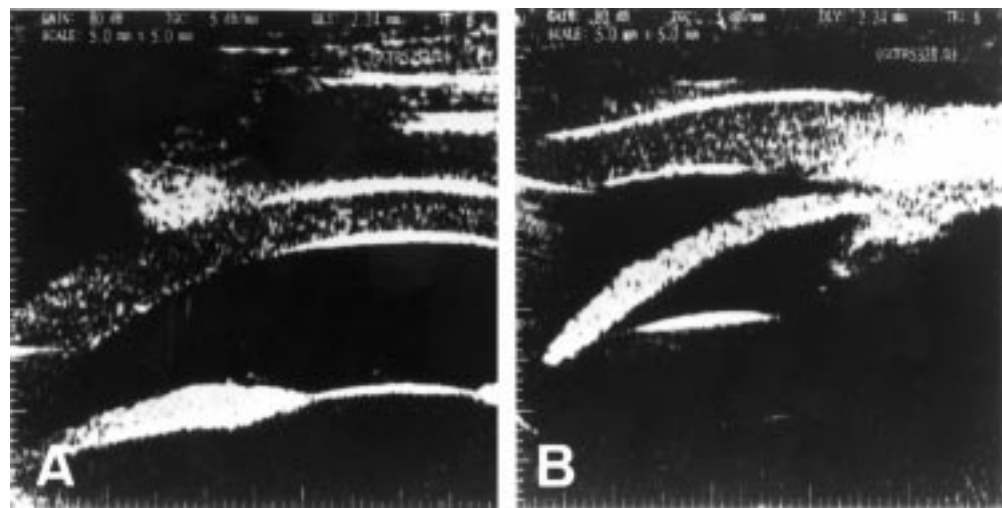


Figure 1 A 1 month old infant. (A) Ultrasound biomicroscopic image of the central anterior chamber. (B) Ultrasound biomicroscopic cross sectional view through the temporal angle region.

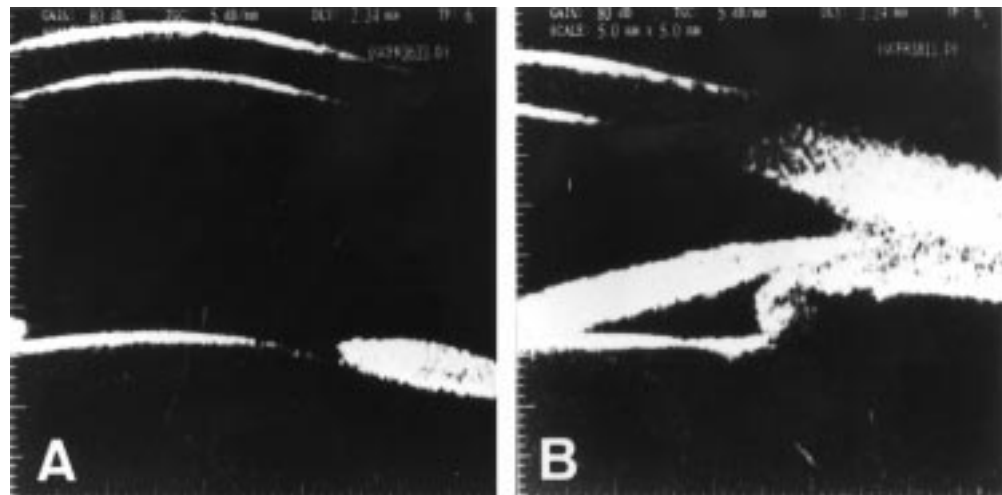


Figure 2 A 13 month old infant. (A) Ultrasound biomicroscopic image of the central anterior chamber. (B) Ultrasound biomicroscopic cross sectional view through the temporal angle region.

Table 1 Summary of the definition of variables in this study

Variables	Definition
Anterior chamber depth (ACD)	Distance between the inner corneal surface and the lens surface
Trabecular-iris angle (TIA)	Angle between the arms passing through a point on the trabecular meshwork 500 μ m from the scleral spur and the point perpendicularly opposite on the iris
Angle opening distance 250 (AOD250)	Length of a perpendicular from the trabecular meshwork on the iris at a point 250 μ m from the scleral spur
Angle opening distance 250 (AOD250)	Length of a perpendicular from the trabecular meshwork on the iris at a point 250 μ m from the scleral spur
Iris thickness	Iris thickness at thickest part of the iris

Table 2 Mean, SD, and range of variables of anterior segment measurements in 46 infants and children

Variables	Mean (SD)	Range
Age (months)	17.09 (16.99)	1 to 60
ACD (μ m)	2505 (480)	1724 to 3473
TIA (degree)	28.74 (7.46)	15.35 to 44.79
AOD250 (μ m)	247.4 (65.9)	116 to 367
AOD500 (μ m)	349.5 (87.1)	166 to 509
Iris thickness (μ m)	434.6 (74.6)	249 to 579

ACD=anterior chamber depth; TIA=trabecular-iris angle; AOD250=angle opening distance at 250 μ m from scleral spur; AOD500=angle opening distance at 500 μ m from scleral spur; iris thickness=thickness at the thickest part of the iris.

trabecular-iris angle (TIA), angle opening distance at 250 and 500 μ m from the scleral spur (AOD250 and AOD500), and iris thickness, as described by Palvin *et al.*^{6,7} Iris thickness was measured at the thickest part of the iris. A summary of the definition of factors is shown in Table 1.

STATISTICS

Values were expressed as mean (SD) and as a range. Regression analysis was performed to determine the precise relation of the ACD, TIA, AOD250, AOD500, and iris thickness to age. Because our interest is in the prediction of

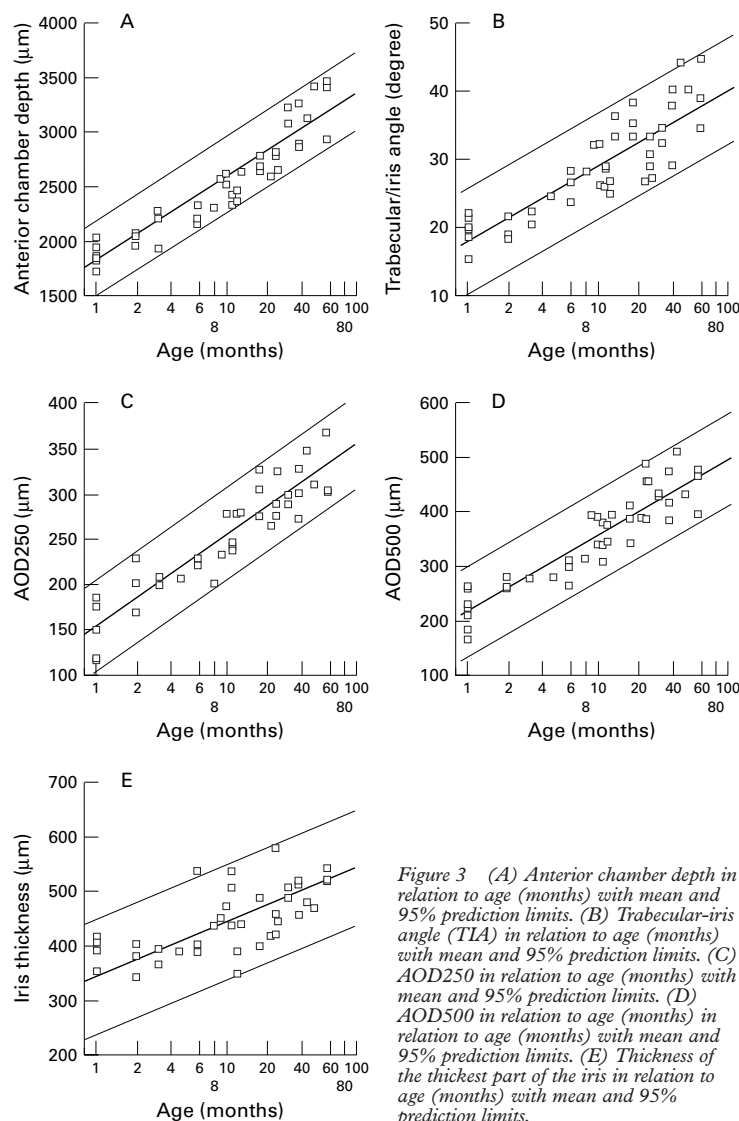


Figure 3 (A) Anterior chamber depth in relation to age (months) with mean and 95% prediction limits. (B) Trabecular-iris angle (TIA) in relation to age (months) with mean and 95% prediction limits. (C) AOD250 in relation to age (months) with mean and 95% prediction limits. (D) AOD500 in relation to age (months) with mean and 95% prediction limits. (E) Thickness of the thickest part of the iris in relation to age (months) with mean and 95% prediction limits.

Table 3 Regression analysis and correlation coefficients of anterior chamber depth (ACD), trabecular-iris angle, AOD250, AOD500, and iris thickness in relation to age

Variable	r	p Value	Regression quotation
ACD	0.937	0.0001	$1779.819 + 769.257 \times \log(\text{age (month)})$
TIA	0.867	0.0001	$18.162 + 11.206 \times \log(\text{age (month)})$
AOD250	0.929	0.0001	$151.539 + 101.528 \times \log(\text{age (month)})$
AOD500	0.917	0.0001	$220.551 + 136.671 \times \log(\text{age (month)})$
Iris thickness	0.748	0.0001	$344.393 + 95.584 \times \log(\text{age (month)})$

ACD=anterior chamber depth; TIA=trabecular-iris angle; AOD250=angle opening distance at 250 μm from scleral spur; AOD500=angle opening distance at 500 μm from scleral spur; iris thickness=thickness at the thickest part of the iris.

Table 4 Regression analysis and correlation coefficients between anterior chamber depth (ACD), trabecular-iris angle, AOD250, AOD500, and iris thickness

	r	p Value	Intercept	Slope
ACD v TIA	0.913	0.0001	-6.918	0.140
ACD v AOD250	0.877	0.0001	-45.379	0.117
ACD v AOD500	0.890	0.0001	-55.646	0.162
ACD v iris thickness	0.667	0.0001	170.641	0.105
TIA v AOD250	0.861	0.0001	36.072	7.352
TIA v AOD500	0.856	0.0001	62.936	9.973
TIA v iris thickness	0.655	0.0001	246.667	6.540
AOD250 v AOD500	0.923	0.0001	38.214	1.259
AOD250 v iris thickness	0.648	0.0001	247.320	0.757
AOD500 v iris thickness	0.673	0.0002	233.087	0.577

ACD=anterior chamber depth; TIA=trabecular-iris angle; AOD250=angle opening distance at 250 μm from scleral spur; AOD500=angle opening distance at 500 μm from scleral spur; iris thickness=thickness at the thickest part of the iris.

the relation for an individual infant, 95% prediction limits were calculated for the eye measurements. These limits are wider than the 95% confidence limits for the mean eye measurement as given levels of predictor variables.

Results

Ultrasound biomicroscopic measurements of the anterior segment were obtained from 46 infants and children, 21 males and 25 females, aged from 1 to 60 months (mean 17.09 (SD 16.99) months).

Figure 1 shows the ultrasound biomicroscopic image of the central anterior chamber and cross sectional view through the temporal angle region of a 1 month old infant. The ACD, TIA, AOD250, AOD500, and thickness of the thickest part of the iris were 1551 μm , 15.35°, 129 μm , 220 μm , and 394 μm , respectively. Figure 2 shows ultrasound biomicroscopic image of the central anterior chamber and cross sectional view of a 13 month old infant. The ACD, TIA, AOD250, AOD500, and thickness of the thickest part of the iris were 2640 μm , 46.38°, 280 μm , 394 μm , and 439 μm , respectively.

The ACD, TIA, AOD250, AOD500 and thickness of the thickest part of the iris for the group of infants and children are shown in Table 2. The ACD, TIA, AOD250, AOD500 and iris thickness were 1724–3473 μm (2505 (SD 480) μm), 15.35–44.79° (28.74 (7.46)°), 116–367 μm (247.4 (65.9) μm), 166–509 μm (349.5 (87.1) μm), and 249–579 μm (434.6 (74.6) μm), respectively. The ACD, TIA, AOD250, AOD500, and iris thickness significantly correlated to age ($r = 0.937$, $p = 0.0001$; $r = 0.867$, $p = 0.0001$; $r = 0.929$, $p = 0.0001$; $r = 0.917$, $p = 0.0001$; $r = 0.748$, $p = 0.0001$) (Fig 3 and Table 3). The slopes and intercepts for the regression analysis, with correlation coefficients with p values, are shown in Table 3.

The ACD was significantly correlated with TIA, AOD250, AOD500, and iris thickness ($r = 0.913$, $p = 0.0001$; $r = 0.877$, $p = 0.0001$; $r = 0.890$, $p = 0.0001$; $r = 0.677$, $p = 0.0001$), as shown in Table 4. The TIA also showed a significant correlation with AOD250, AOD500, and iris thickness ($r = 0.861$, $p = 0.0001$; $r = 0.856$, $p = 0.0001$; $r = 0.655$, $p = 0.0001$). The AOD250 was significantly correlated with AOD500 and iris thickness ($r = 0.923$, $p = 0.0001$; $r = 0.648$, $p = 0.0001$). There was a significant correlation between AOD500 and iris thickness ($r = 0.673$, $p = 0.0002$).

Discussion

We measured the anterior segments of infants and children, and established normative values and 95% prediction limits for anterior chamber depth, trabecular-iris angle, AOD250, AOD500, and iris thickness in relation to age. Anterior chamber depth, trabecular-iris angle, AOD250, and AOD500 showed a significant increase in relation to logarithm of age. Several investigators reported the development of the axial length and the anterior chamber depth.^{1 15–20} Sampolesi and Caruso¹ and Kiskis *et al*²¹ demonstrated a significant correlation of

axial length and corneal diameter with logarithm of age. The growth of the axial length and corneal diameter had been reported to be divided into three growth periods: a rapid natal phase in the first year and a half, the following slower infantile phase from the second to sixth year, and the final slow juvenile phase lasting until the age of 13 years. Our measurements also showed that the development of the anterior segment dimensions had a rapid growth phase from birth to approximately 1.5 years and a following slower growth phase.

General anaesthesia is usually required for a thorough examination of children under 5 years of age.²¹ The general condition of some infants often precludes examination under general anaesthesia. The opacity of anterior media and iridocorneal abnormalities, which are frequently seen in patients with developmental glaucoma, prevent observation with conventional methods such as slit lamp biomicroscopy. To overcome the difficulties, we have developed a method for measuring the anterior segment of neonates and obtaining live images by use of ultrasound biomicroscopy and a muscle hook with topical anaesthesia.¹⁴ Ultrasound biomicroscopy allows one to make precise measurements of the anterior segments even in premature neonates.

It is well known that the diagnosis of congenital glaucoma and the consequent indication of surgical intervention depend on clinical symptoms and intraocular pressure. Sampolesi and Caruso and Reibakdi showed that, in cases with borderline pressure levels that do not show any meaningful deviation from the normal, axial length measurements with ultrasonography are helpful in treating those patients.¹⁹ Kiskis *et al* reported that the corneal diameter was a more reliable guide than the axial length in the assessment of congenital glaucoma.²⁰ In eyes with congenital glaucoma, the corneal diameter increases more than the axial length. In our preliminary study, we measured anterior segments of patients with congenital glaucoma and found that their ACD, TIA, AOD250, and AOD500 were greater than upper 95% prediction limits. The use of the ultrasound biomicroscopy would facilitate the evaluation of anterior segments. However, the measurements of the dimensions of the anterior segments is needed in cases with borderline pressure levels.

We established normative values for anterior segment in infants and children. These data provide the first information on the develop-

ment of the anterior segments. The normative values should greatly aid ophthalmologists in evaluating anterior segment dimensions of infants and children who are suspected of having congenital glaucoma and congenital anomalies.

- 1 Sampolesi R, Caruso R. Ocular echometry in the diagnosis of congenital glaucoma. *Arch Ophthalmol* 1982;100:574-7.
- 2 Tarkkanen A, Uusitalo R, Mianowicz J. Ultrasonographic biometry in congenital glaucoma. *Acta Ophthalmol* 1983; 61:618-23.
- 3 Makabe R. Vergleichende Untersuchungen der Kammerwinkelweite mit Echographie und Gonioskopie. *Klin Monatsbl Augenheilkd* 1989;194:6-9.
- 4 Tello C, Liebmann J, Potash SD, *et al*. Measurement of ultrasound biomicroscopy images: intraobserver and interobserver reliability. *Invest Ophthalmol Vis Sci* 1994;35: 3549-52.
- 5 Pavlin CJ, Sherar MD, Foster FS. Subsurface ultrasound microscopic imaging of the intact eye. *Ophthalmology* 1990; 97:244-50.
- 6 Pavlin CJ, Harasiewicz K, Sherar MD, *et al*. Clinical use of ultrasound biomicroscopy. *Ophthalmology* 1991;98:287-95.
- 7 Pavlin CJ, Harasiewicz K, Foster FS. Ultrasound biomicroscopy of anterior segment structures in normal and glaucomatous eyes. *Am J Ophthalmol* 1992;113:381-9.
- 8 Pavlin CJ, McWhae JA, McGowan HD, *et al*. Ultrasound biomicroscopy of anterior segment tumors. *Ophthalmology* 1992;99:1220-8.
- 9 Pavlin CJ, Ritch R, Foster FS. Ultrasound biomicroscopy in plateau iris syndrome. *Am J Ophthalmol* 1992;113:390-5.
- 10 Tello C, Chi T, Shepps G, *et al*. Ultrasound biomicroscopy in pseudophakic malignant glaucoma. *Ophthalmology* 1993; 100:1330-4.
- 11 Potash SD, Tello C, Liebmann J, *et al*. Ultrasound biomicroscopy in the pigment dispersion syndrome. *Ophthalmology* 1994;101:332-9.
- 12 Aslanides IM, Libre PE, Silverman RH, *et al*. High frequency ultrasound imaging in pupillary block glaucoma. *Br J Ophthalmol* 1995;79:972-6.
- 13 Kobayashi H, Kobayashi K, Kiryu J, *et al*. Ultrasound biomicroscopic analysis of the effect of pilocarpine on the anterior chamber angle. *Graefes Arch Clin Exp Ophthalmol* 1997;235:425-30.
- 14 Kobayashi H, Kobayashi K, Kiryu J, *et al*. Ultrasound biomicroscopic measurements of anterior chamber angle in premature infants. *Br J Ophthalmol* 1997;81:460-4.
- 15 Larsen JS. The sagittal growth of the eye. I. Ultrasonic measurement of the depth of the anterior chamber from birth to puberty. *Acta Ophthalmol* 1971;49:239-62.
- 16 Larsen JS. The sagittal growth of the eye. II. Ultrasonic measurement of the axial diameter of the lens and the anterior segment from birth to puberty. *Acta Ophthalmol* 1971; 49:427-40.
- 17 Larsen JS. The sagittal growth of the eye. IV. Ultrasonic measurement of the axial length of the eye from birth to puberty. *Acta Ophthalmol* 1971;49:873-86.
- 18 Grignolo A, Rivara A. Biometry of the human eye from the sixth month of pregnancy to tenth year of life (measurements of the axial length, retinoscopy refraction, total refraction, corneal and lens refraction). In: Vanysek J, ed. *Diagnostica ultrasonica in ophthalmologica. II Symposium Internationale de Diagnostica Ultrasonica in Ophthalmologica, 1968*. Universita JE Purkyne, Brno, Czechoslovakia (*Opuscula Ophthalmologica, Acta Facultatis Medicae Brunensis* No 35, 251-7).
- 19 Reibakdi A. Biometric ultrasound in the diagnosis and follow-up of congenital glaucoma. *Am Ophthalmol* 1982; 14:807-8.
- 20 Kiskis AA, Markowitz SN, Morin JD. Corneal diameter and axial length in congenital glaucoma. *Can J Ophthalmol* 1985;20:93-7.
- 21 Dickens DJ, Hoskins HDJr. Diagnosis and treatment of congenital glaucoma. In: Ritch R, Shields MB, Krupin T, eds. *The glaucomas*. 2nd ed. St Louis: Mosby, 739-49.



Ultrasound biomicroscopic measurement of development of anterior chamber angle

Hiroshi Kobayashi, Hisako Ono, Junichii Kiryu, et al.

Br J Ophthalmol 1999 83: 559-562

doi: 10.1136/bjo.83.5.559

Updated information and services can be found at:

<http://bjo.bmj.com/content/83/5/559.full.html>

References

These include:

This article cites 18 articles, 4 of which can be accessed free at:

<http://bjo.bmj.com/content/83/5/559.full.html#ref-list-1>

Article cited in:

<http://bjo.bmj.com/content/83/5/559.full.html#related-urls>

Email alerting service

Receive free email alerts when new articles cite this article. Sign up in the box at the top right corner of the online article.

Notes

To request permissions go to:

<http://group.bmj.com/group/rights-licensing/permissions>

To order reprints go to:

<http://journals.bmj.com/cgi/reprintform>

To subscribe to BMJ go to:

<http://group.bmj.com/subscribe/>