

LETTERS TO THE EDITOR

Central serous papillopathy

EDITOR,—Central serous retinopathy is a serous macular detachment that produces central visual loss in one eye. It may occur idiopathically or in conjunction with a pit or coloboma of the optic disc. In idiopathic cases, fluorescein angiography characteristically shows one or more leakage points through which choroidal fluid transgresses the retinal pigment epithelium to enter the subretinal space.¹ This report describes a patient who developed a serous retinal detachment extending from the optic disc to the macula which was associated with a discrete angiographic area of capillary leakage within a non-excavated optic disc.

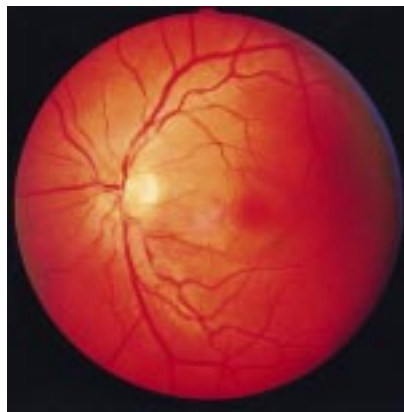

Figure 1 A shallow macular detachment extends from the optic disc to the macula. The disc is tilted and has a prominent temporal crescent.

CASE REPORT

A 32 year old man awoke with blurred vision in his left eye that had persisted over a 4 day period. He denied pain with eye movement or associated headache. He had a history of poor vision in the right eye since early childhood which had not improved with occlusion therapy. Except for a recent upper respiratory infection, he was otherwise healthy.

Visual acuity was hand movements in the right eye and 20/200 in the left eye. Pupillary examination showed a 1+ afferent pupillary defect on the right. Dilated slit lamp examination showed no vitreous cells or other evidence of intraocular inflammation. There was no significant refractive error in either eye. Retinal examination showed a heavily pigmented scar in the macula of the right eye. The retina appeared normal in the left eye. The optic disc in the left eye was normal in size but had a tilted configuration and a prominent temporal crescent (Fig 1). Systemic evaluation included magnetic resonance imaging of the head, chest x ray, complete blood count, erythrocyte sedimentation rate, and serum glucose. He was treated with a 3 day course of intravenous Solumedrol (methylprednisolone, 250 mg, four times a day) for presumed retrobulbar neuritis, which produced no improvement in vision.

The patient returned 2 months later, complaining of persistent visual loss in the left eye. Retinal examination disclosed a shallow transparent retinal detachment extending from macula to the optic disc (Fig 1). Fluorescein angiography showed an abnormal area of hyperfluorescence deep within the temporal aspect of the optic disc, which increased in the mid phase and stained in the late phase (Fig 2). There was no additional retinal pigment epithelial leakage point beneath or surrounding the detachment. Ultrasonographic examination of the optic disc disclosed no notching or depression within the optic disc.

Two years later, the patient returned and stated that his vision had slowly normalised in the left eye. Repeat examination showed a visual acuity of 20/20 in the left eye with a normal appearing optic disc and macula.

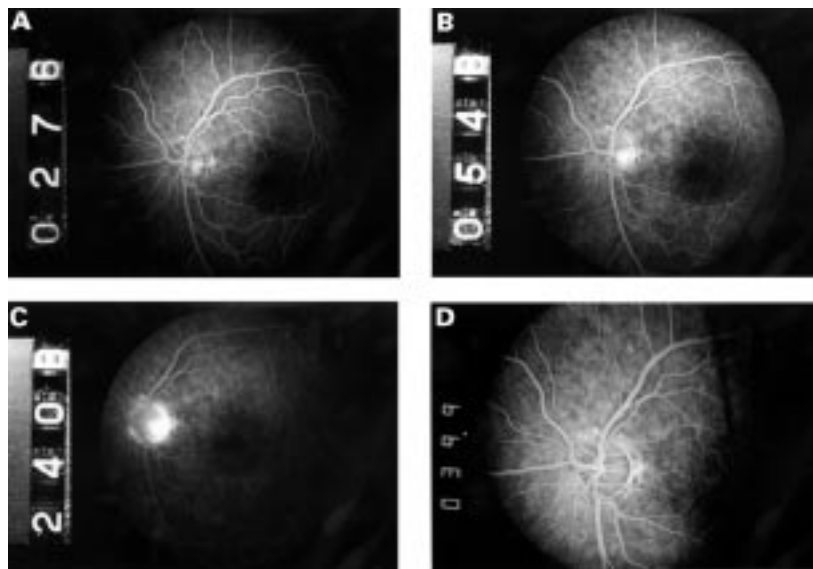


Figure 2 Early phase fluorescein angiogram demonstrates deep hyperfluorescence within the temporal aspect of the left optic disc (A, 27.6 seconds), with increasing hyperfluorescence in the mid-phase (B, 54.8 seconds), and staining in the late phase (C, 240 seconds). Follow up angiogram 2 years later shows no residual abnormality (D, 39.9 seconds).

Fluorescein angiography disclosed no residual abnormality (Fig 2D).

The differential diagnosis of this patient's disorder included occult optic pit, optic disc haemangioma, and a focal capillary leakage deep within the optic disc, with egression of fluid into the subretinal space. Occult optic pit and optic disc haemangioma were ruled out by clinical examination and by the complete resolution of the abnormal hyperfluorescence on fluorescein angiography, suggesting the presence of a focal capillary leakage within the optic disc which may have been inflammatory in origin. Abnormal capillary leakage deep within the optic disc may cause intraretinal fluid accumulation with formation of a macular star in the setting of neuroretinitis²; however, transgression of fluid into the subretinal space is generally prohibited by the intermediary tissue of Kuhnt.^{3,4} In this patient, an anomalous peripapillary area may have disrupted the normal barrier function of the intermediary layer of Kuhnt, providing a non-physiological conduit between the optic disc and the subretinal space.

Supported in part by a grant from Research to Prevent Blindness, Inc.

MICHAEL C BRODSKY

Department of Ophthalmology,
University of Arkansas for Medical Sciences,
Little Rock, Arkansas

Correspondence to: Arkansas Children's Hospital,
800 Marshall, Little Rock, Arkansas 72202.

Accepted for publication 14 January 1999

- 1 Gass JDM. *A stereoscopic atlas of macular diseases*. 3rd ed. St Louis: CV Mosby, 1987:46-59.
- 2 Gass JDM. Diseases of the optic nerve that simulate macular diseases. *Trans Am Acad Ophthalmol Otolaryngol* 1977;83:763-70.
- 3 Anderson DR, Hoyt WF. Ultrastructure of the intraorbital portion of human and monkey optic nerve. *Arch Ophthalmol* 1969;82:506-30.
- 4 Brown GC, Tasman WS. *Congenital anomalies of the optic disc*. New York: Grune and Stratton, 8-10.

Immunohistological findings in a patient with unusual late onset manifestation of ligneous conjunctivitis

EDITOR,—Ligneous conjunctivitis is a rare chronic membranous conjunctivitis with typical woody induration of the conjunctival tissue.^{1,2} It occurs most often bilaterally in female children and is of unknown aetiology.^{1,3} The disease process may involve other mucous membranes, such as the cervix and the trachea, occasionally leading to death by tracheal obstruction.⁴ Few patients with adult onset ligneous conjunctivitis have been seen.^{3,5} They generally experience a milder course and systemic involvement is less common. Autoimmune dysfunction, infection with an unidentified virus, and an inherited predisposition possibly combined with trauma have all been proposed as possible causes for the disease.^{3,5,6} Recent studies have found an inherited defect in the plasminogen system of affected children.⁷ Treatment of the condition is problematic and often unsuccessful.^{8,9}

CASE REPORT

A 69 year old woman presented with recurrent unilateral conjunctivitis. She had dry eyes and foreign body sensation, but no visual impairment. Conjunctival injection with dense membranes and fibrosis of the lids was present (Fig 1). Peripheral corneal vascularisation was

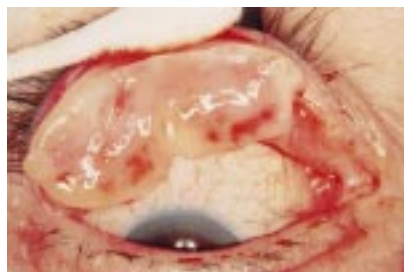

Figure 1 At the initial presentation of the patient a conjunctival injection and dense, membranous fibrosis of the upper lid were seen.

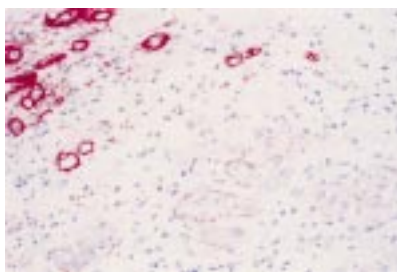


Figure 2 Stain with monoclonal antibodies against CK-MNF (pancytokeratin) (original magnification $\times 256$). Expression of pancytokeratin is positive in vascular endothelial cells and surrounding muscle cells.

identified. Conventional histology confirmed the clinical diagnosis of ligneous conjunctivitis. Immunohistology for CD3, CD4, CD8, CD15, CD20, CD68, CD79a, vimentin, collagen type IV, and cytokeratin according to standard procedures was performed to characterise the inflammatory tissue (Table 1).

Before repeated surgical excision, conservative topical therapy with corticosteroids alone (0.1% dexamethasone five times daily) was unsuccessful. Subsequent topical treatment with the following: disodium cromoglycate 4% combined with 5000 IU/ml heparin eye drops (three times daily each), corticosteroids (0.1% dexamethasone five times daily), 2% cyclosporine A (three times daily), and antibiotics and artificial tears was to no avail. The membranes were excised three times within 8 months, followed by topical corticosteroids (0.1% dexamethasone or prednisolone, 0.5%) and heparin eye drops (5000 IU/ml) that were both slowly tapered from five times daily over 4 weeks.

The membranes recurred within a few weeks of each excision. Immunohistology showed a chronic inflammatory process characterised by plasma cells and lymphocytes. There was a relative shift towards CD 8+ cells in the CD4/8 ratio. Surprisingly, pancytokeratin, a marker for tissue of epithelial origin, was detected in the endothelium of the blood vessels invading the granulomatous tissue (Fig 2).

Serologically, a severe type 1 plasminogen deficiency was detected. Analysis of the plasminogen gene revealed two single base mutations, Lys 19 \rightarrow Glu and Arg 216 \rightarrow His, a compound heterozygotic defect. Plasminogen activity was reduced to 18% (reference blood level 80–120%). Plasma plasminogen as detected by antibodies was less than 0.4 mg/dl (normal range 6–25 mg/dl).

COMMENT

This case represents primary onset of ligneous conjunctivitis in adulthood with the typical histology^{1,2} combined with serological findings that have previously only been seen in paediatric patients.⁷ Immunohistochemical investigations confirmed a chronic inflammatory process, consistent with a possible autoimmune origin, but could not determine the cause of this condition. Surprisingly, the antigen pattern of vascular endothelium in the granulation tissue involved pancytokeratin and was similar to that found in epithelioid angiosarcoma.¹⁰ This result needs further evaluation. Systemic plasminogen deficiency was found for the first time in an adult patient with ligneous conjunctivitis. The incidence of this gene defect in adult patients may be determined investigating more patients. This finding might become important for future treatment developments. Currently, the treatment of ligneous conjunctivitis in these patients remains ineffective.

Presented at the annual meeting of the Deutsche Ophthalmologische Gesellschaft Heidelberg; 96th Congress, Berlin, September, 1998

SONJA KLEBE

Department of Ophthalmology,
Humboldt-University of Berlin,
Charité; Germany, Berlin and
Department of Ophthalmology,
Flinders University;
South Australia, Adelaide

TONY WALKOW

CHRISTIAN HARTMANN
UWE PLEYER
Department of Ophthalmology,
Humboldt-University of Berlin,
Charité; Germany, Berlin, Germany

Correspondence to: Uwe Pleyer, Augustenburger Platz 1, D-13353 Berlin, Germany.

Accepted for publication 15 February 1999

Table 1 Cell surface antigens against which monoclonal antibodies have been used in this study, and their specificity

Antigen	Specificity
CK-MNF	Pancytokeratin, epithelial tissue
Collagen type IV	Basal membranes
Vimentin	Intermediate filament, solely expressed by cells of mesenchymal origin and used as a marker for such
CD 3	Cell surface antigen on all T cells
CD 4	Cell surface antigen expressed on T helper cells and thymocytes; important for stabilisation of the T cell receptor-MHC II interaction
CD 8	Cell surface antigen expressed by cytotoxic T cells, intraepithelial lymphocytes, thymocytes, and some dendritic cells
CD 15	Marker for cell activation predominantly expressed by granulocytes and, to some extent, by macrophages
CD 20	Cell surface antigen found on nearly all B cells except pre-B cells and plasma cells. Represents a transmembraneous ion channel protein and plays an important role in the activation and proliferation processes of the maturing B cell
CD 68	Cell surface antigen found on macrophages and monocytes
CD 79a	Cell surface antigen expressed early in the ontogenesis of B cells, persistent in plasma cells, but not co-expressed with CD20+

- Lütjen-Decroll E, Sames K, Straub W, *et al*. Klinische, elektronenmikroskopische und histochemische Untersuchungen bei Conjunctivitis lignosa. *Graefes Arch Klin Exp Ophthalmol* 1975;194:175–91.
- Holland EJ, Chan, CC, Kuwabara T, *et al*. Immunohistologic findings and results of treatment with cyclosporine in ligneous conjunctivitis. *Am J Ophthalmol* 1989;107:160–6.
- Hidayat A, Riddle P. Ligneous conjunctivitis. A clinicopathologic study of 17 cases. *Ophthalmology* 1987;94:949–59.
- Cooper, TJ, Kazdan JJ, Cutz J. Ligneous conjunctivitis with tracheal obstruction. *Canad J Ophthalmol* 1969;14:57–62.
- Gary S, Schwarz M, Holland EJ. Induction of ligneous conjunctivitis by conjunctival surgery. *Am J Ophthalmol* 1995;113:253–4.
- Baremann JB, Pettit TH, Isenberg, SJ, *et al*. Ligneous conjunctivitis—an autosomal recessive disorder. *J Pediatr Ophthalmol Strabismus* 1986; 23:137–40.
- Schuster V, Mingers A, Seidenspinner S, *et al*. Homozygous mutations in the plasminogen gene of two unrelated girls with ligneous conjunctivitis. *Blood* 1997;90:958–66.
- De Cock R, Ficker LA, Dart JG, *et al*. Topical heparin in the treatment of ligneous conjunctivitis. *Ophthalmology* 1995;102:1654–9.
- Kaan G, Oezden O. Therapeutic use of topical cyclosporine. *Amv Ophthalmol* 1993;25:182–6.
- Sheppard MN, Hansell DM, Du Bois RM, *et al*. Primary epithelioid angiosarcoma of the lung presenting as pulmonary hemorrhage. *Hum Pathol* 1997;28:383–5.

Multifocal electroretinography in patients with occult macular dystrophy

EDITOR.—Occult macular dystrophy (OMD), idiopathic photoreceptor dysfunction, or central cone dystrophy is an unusual form of macular dystrophy where a progressive decline of visual acuity occurs with an essentially normal fundus and normal fluorescein angiography (FA) findings.^{1–3} The topography of the electroretinographic responses in the central visual field in three patients with OMD was examined by means of the multifocal electroretinogram (m-ERG).^{4,5} To evaluate the retinal pigment epithelium (RPE) and the choroidal circulation in OMD, indocyanine green videoangiography (ICG-V) was performed.⁶

CASE 1

A 77 year old pseudophakic woman presented with progressive decreased visual acuity bilaterally of 10 years' duration. The best corrected Landolt visual acuity was 20/250 right eye and 20/300 left eye. Visual field testing revealed central scotomas in both eyes. Fundus photography (Fig 1A), FA, and ICG-V were normal. Photopic ERG showed borderline amplitudes while scotopic ERG was normal. The Farnsworth–Munsell 100 hue tests showed several errors without any specific axis. The m-ERG exhibited markedly diminished responses in a relatively small circumscribed area in the macula (Fig 2A).

CASE 2

A 68 year old patient had blurred visual acuity for 10 years. The best corrected visual acuity was 20/200 right eye and 20/600 left eye. Fundus photography (Fig 2A), FA, and ICG-V were normal. Photopic ERG showed borderline amplitudes while scotopic ERG was normal. The Farnsworth–Munsell 100 hue tests showed several errors without a specific axis. There were central scotomas in the visual fields bilaterally. The m-ERG revealed marked depression of responses only in the macula (Fig 2B).

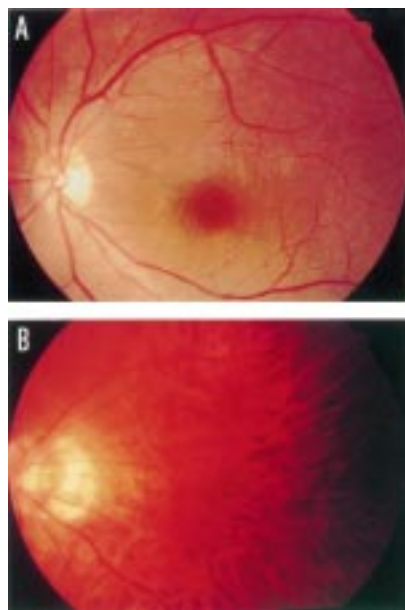


Figure 1 Fundus photographs of cases 1 (A) and 2 (B) showing essentially normal findings.

COMMENT

Focal macular cone ERG is the key to the diagnosis of OMD.^{1,3} In our two patients, m-ERG activity was markedly diminished in a relatively small circumscribed area in the macula, suggesting limited functional defects in the fovea. Since no abnormality was found by ICG-V, or FA, the intact RPE may have a barrier effect to the underlying choroidal circulation.

The pathology of OMD may involve the macular cone system without affecting the RPE and the choroid. m-ERG can be useful for the differential diagnosis of OMD and can help map the topography of cone activity loss more precisely. m-ERG may aid in characterising the functional retinal topography in the near future.

S FUJII
M F T ESCAÑO
K ISHIBASHI
H MATSUO
M YAMAMOTO

Department of Ophthalmology, Kobe University, School of Medicine, Kobe, Japan

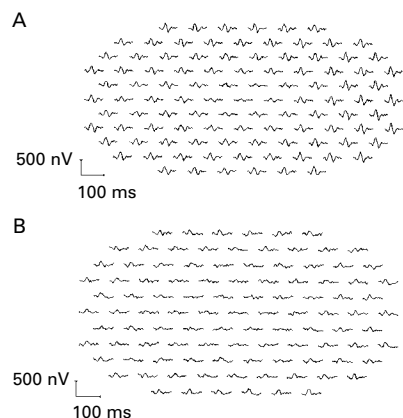


Figure 2 m-ERG of cases 1 (A) and 2 (B) showing decreased amplitudes of the wave patterns in the central 8° and 12° of the macula, respectively.

Correspondence to: Shigeki Fujii, MD, Department of Ophthalmology, Kobe University, School of Medicine, 7-5-2 Kusunoki-cho, Chuo-ku, Kobe 650, Japan.

Accepted for publication 22 January 1999

- Miyake Y, Horiguchi M, Tomita N, *et al.* Occult macular dystrophy. *Am J Ophthalmol* 1996; **122**:644–53.
- Rowe SE, Trobe JD, Sieving PA. Idiopathic photoreceptor dysfunction causes unexplained visual acuity loss in later adulthood. *Ophthalmology* 1990; **97**:1632–7.
- Miyake Y, Ichikawa K, Shiose Y, *et al.* Hereditary macular dystrophy without visible fundus abnormality. *Am J Ophthalmol* 1989; **108**:292–9.
- Sutter ER, Tran D. The field topography of ERG components in man—I. The photopic luminance response. *Vis Res* 1992; **32**:433–46.
- Parks S, Keating D, Williamson TH, *et al.* Functional imaging of the retina using the multifocal electroretinograph: a control study. *Br J Ophthalmol* 1996; **80**:831–4.
- Yannuzzi LA, Slakter JS, Sorenson JA, *et al.* Digital indocyanine green videoangiography and choroidal neovascularization. *Retina* 1992; **12**:191–223.

Kimura's disease: no evidence of clonality

EDITOR.—Kimura's disease is a chronic inflammatory disorder of unknown aetiology.¹ Patients usually present with recurrent painless swellings in the subcutis of the head and neck region, increased serum IgE levels, and peripheral eosinophilia. The disease is described as reactive and data on clonality is absent.

Here we describe a patient with Kimura's disease involving the orbits. Clonality studies were performed by polymerase chain reaction (PCR) for immunoglobulin heavy chain (IgH), T cell receptor gamma (TCR- γ), and delta (TCR- δ) gene rearrangements.^{2–4}

CASE REPORT

A 20 year old man presented with a 2 × 3 cm right eyelid swelling in 1986 with normal visual acuity and absence of diplopia. In 1993, he presented with progressive swelling in the right upper eyelid, which subsided with a short course of prednisolone (50 mg/day × 1 week). He was lost to follow up until May 1997 when he developed recurrent swelling of the right upper eyelid. Excision biopsy of the right upper eyelid mass showed changes consistent with Kimura's disease. DNA was extracted from lacrimal gland biopsy tissue.⁵ Gene rearrangements for IgH gene, TCR γ , and TCR δ genes were tested by PCR^{2–4} but no clonal gene rearrangement was identified (Fig 1). In June 1998, he had recurrence of the right upper eyelid mass without any local or systemic symptoms (fever, night sweats, weight loss) and multiple left cervical lymph nodes measuring 1–2 cm in diameter. A complete blood examination showed haemoglobin 14.1 g/l, platelets 282 × 10⁹/l and leucocytes 18.4 × 10⁹/l (differential: eosinophils 3.68 × 10⁹/l, neutrophils 9.2 × 10⁹/l, lymphocytes 1.5 × 10⁹/l, and monocytes 4.02 × 10⁹/l) (normal range: leucocytes 4–11 × 10⁹/l; eosinophils 0.1–0.4 × 10⁹/l). The IgE level was 10 328 IU/ml (normal range: <100 IU/ml). IgG, A, and M levels were normal. Urea, creatinine, albumin, and transaminase levels were within normal limits. Serology for HIV was negative. Magnetic resonance imaging (MRI) showed an oval mass in the right lacrimal gland and thickening of the right superior rectus muscle (Fig 2). After 3 weeks of prednisolone (50 mg/day), there was almost complete resolution of the lacrimal mass and IgE level and eosinophil count went down to 2860 IU/ml

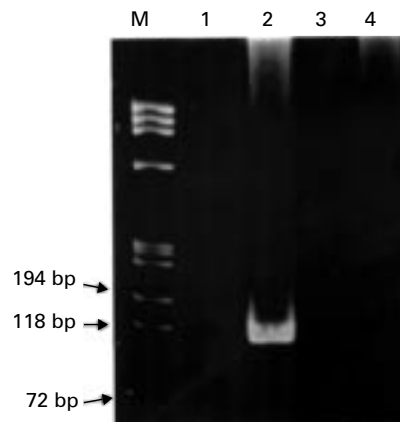


Figure 1 PCR amplification of TCR δ gene rearrangement showing absence of clonal rearrangement in 6% polyacrylamide gel. Lanes: M- Φ X174, HaeIII digest; 1, reagent blank; 2, positive control (B cell lymphoma); 3, water only; 4, patient's lacrimal gland sample.

and 1.2 × 10⁹/l respectively. Computed tomography scan of the abdomen revealed absence of intra-abdominal lymphadenopathy or organomegaly.

COMMENT

Neoplasia is characterised by clonal proliferation of cells and is most often demonstrated in cases of malignant diseases. However, monoclonality has also been demonstrated in some "benign" or "reactive" lymphadenopathy such as angioimmunoblastic lymphadenopathy and Castleman's disease, both of which are associated with a tendency to aggressive lymphoma.^{6,7}

Kimura's disease runs an indolent course and has been described as a chronic inflammatory process reactive to some "unknown" stimuli.¹ Our patient had a typical clinical presentation with recurrent lacrimal swelling and lymphadenopathy in the head and neck region. It ran an extremely indolent course and, despite the recurring nature of the disease, our patient remained so asymptomatic that he was lost to follow up for years. Interleukin-5 has been shown to be constitutively expressed and explains some of the features of the disease such as eosinophilia and elevated IgE level.⁸

TCR δ gene has been shown by PCR amplification to be rearranged not only in clonal T cell disorders, but also in 73% of clonal B cell disorder.² The PCR based methods for the IgH gene rearrangement is positive in 55%–100% of various types of clonal B cell disorders.⁴ In our patient, the absence of

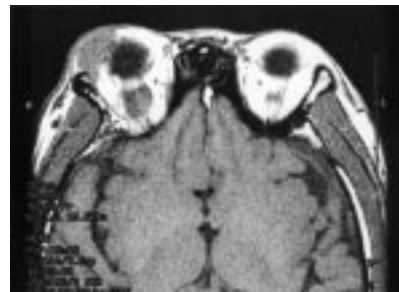

Figure 2 T1 weighted magnetic resonance image of the orbit showing a 2.5 cm diameter mass in the right lacrimal gland with thickening of the right superior rectus muscle.

clonal TCR and IgH gene rearrangements is consistent with the reactive nature of the disease. However, despite the relatively high sensitivity of these PCR based techniques to detect clonality, the finding should be confirmed by testing larger numbers of patients and Southern hybridisation with appropriate probes if DNA from fresh tissue is available.

In conclusion, our patient illustrates the typically indolent, recurring nature of the disease with lymphadenopathy and swelling confined to the head and neck region. The failure to demonstrate clonality is consistent with the reactive nature of the entity and the lack of report of malignant lymphoma transformation.

C S CHIM

University Department of Medicine, Queen Mary Hospital, University of Hong Kong, Hong Kong

W H SHEK

University Department of Pathology, Queen Mary Hospital, University of Hong Kong, Hong Kong

R LIANG

Y L KWONG

University Department of Medicine, Queen Mary Hospital, University of Hong Kong, Hong Kong

Correspondence to: Dr C S Chim, University Department of Medicine, Queen Mary Hospital, University of Hong Kong, Hong Kong.
Accepted for publication 20 January 1999

- 1 Schnitzer B. Reactive lymphadenopathies. In: Knowles DM, eds. *Neoplastic hematopathology*. Baltimore: Williams & Wilkins, 1992:427-57.
- 2 Chan DW, Liang R, Kwong YL. Pattern of T-cell receptor delta gene rearrangement by Southern blotting and polymerase chain reaction technique in Hong Kong Chinese patients with non-T-cell hematological malignancies. *Hematol Oncol* 1996;14:57-66.
- 3 McCarthy KP, Sloane JP, Kabarowski JHS, et al. A simplified method of detection of clonal rearrangements of the T-cell receptor- γ chain gene. *Diag Mol Pathol* 1992;1:173-9.
- 4 Liang R, Chan V, Chan TK, et al. Detection of immunoglobulin gene rearrangement in B-cell lymphoma by polymerase chain reaction gene amplification. *Hematol Oncol* 1992;10:149-54.
- 5 Maniatis T, Fritsch EF, Sambrook J. *Molecular cloning: a laboratory manual*. New York: Cold Spring Harbor Laboratory, 1982, Chap 9:280.
- 6 Frizzera G. Atypical lymphoproliferative disorders. In: Knowles DM, eds. *Neoplastic hematopathology*. Baltimore: William & Wilkins, 1992: 459-95.
- 7 Soulier J, Grollet L, Oksenhendler E, et al. Molecular analysis of clonality in Castleman's disease. *Blood* 1995;86:1131-8.
- 8 Inoue C, Ichikawa A, Hotta T, et al. Constitutive gene expression of interleukin-5 in Kimura's disease. *Br J Haematol* 1990;76:554-9.

Correction of the inadequate lower fornix in the anophthalmic socket

EDITOR.—A well formed inferior fornix in the anophthalmic socket requires an adequate amount of conjunctival tissue and a deep recess. Obliteration of the fornix might occur either secondary to conjunctival shrinkage or as a result of obliteration of the inferior recess and inadequate fixation of the abundant conjunctiva.¹ In the latter condition, the subject of this report, prolapse of the fornical conjunctiva will result in anterior rotation of the inferior edge of the prosthesis and secondary laxity of the lower lid.

This report presents a modification of the technique described previously by Neuhaus and Hawes for the correction of the above condition.¹

CASE REPORT

Twenty patients with an inadequate inferior fornix and sufficient amount of conjunctival tissue who presented over a period of 5 years were managed. They all complained of easy

prolapse of the lower edge of the prosthesis and sagging of the lower lid.

The procedure was done under local anaesthesia except in the two patients who, in addition, underwent secondary insertion of an orbital implant. A canthotomy and cantholysis were performed. An infratarsal conjunctival incision was carried out along the length of the lower lid. Dissection was then performed in the retro-orbicular plane till the orbital rim was reached (Fig 1A). The posterior edge of the conjunctival incision was fixed to the periosteum about 5 mm posterior to the inferior orbital rim with interrupted 5-0 Vicryl sutures. The posterior surface of the lower lid was left to heal by secondary intention (Fig 1B). An adequately sized conformer was inserted. A tarsal strip procedure was performed to tighten the lower lid horizontally.² A prosthesis was fitted at about the second post-operative month. The follow up period ranged from 5 months to 3 years. Nineteen patients had a satisfactory result with adequate retention of the prosthesis, and good lower lid level. Inspection of the lower fornix revealed a deep recess with a well epithelialised inner lower lid surface, and no evidence of symblepharon (Fig 2). One patient had loosening of the tarsal strip suture noted at the 1 week postoperative follow up and was later corrected. However, the final lid level remained unsatisfactory.

COMMENT

Adequate retention of the prosthesis in the anophthalmic socket requires a well formed inferior fornix, which in turn requires sufficient conjunctival length and a deep recess.

Obliteration of the inferior fornix might occur despite having a good amount of conjunctival tissue.¹ This occurs possibly because of dehiscence of lower lid retractors, or development of scar tissue in the inferior recess that ultimately results in prolapse of the fornical conjunctiva and anterior rotation of the lower edge of the prosthesis. The long term effect exerted by the weight and pressure of an improperly accommodated prosthesis will result in secondary laxity of the lower lid.

The traditional solution to the above condition consisted of a lateral canthal tendon tightening and a fornix reformation using an externalised suturing technique in addition to alloplastic stenting material.³ Skin erosion and infection necessitated early removal of the externalised sutures and increased the risk of recurrence.

Another method of repair was described by Neuhaus and Hawes¹ for the correction of the inadequate inferior cul de sac. It consisted of a transconjunctival inferior fornix incision used to gain direct exposure of the periosteum of the inferior orbital rim. Direct suture fixation of the edges of the conjunctival incision to the periosteum is then achieved. Externalised sutures and stents were not required. Out of 12 patients reported in the above paper, two developed mild lower lid retraction and two developed mild lower lid entropion. This is because the vertical length of the conjunctival tissue is not always sufficient to allow for fixation of both edges of the incision down to the periosteum. Lower lid retraction or entropion occurs whenever the anterior edge of the incision is forced down and sutured under tension.

The technique described in this report makes the conjunctival incision just at the infratarsal border so as to save the maximum length of conjunctiva for the posterior flap. By this, the inner lid surface is left to heal by sec-

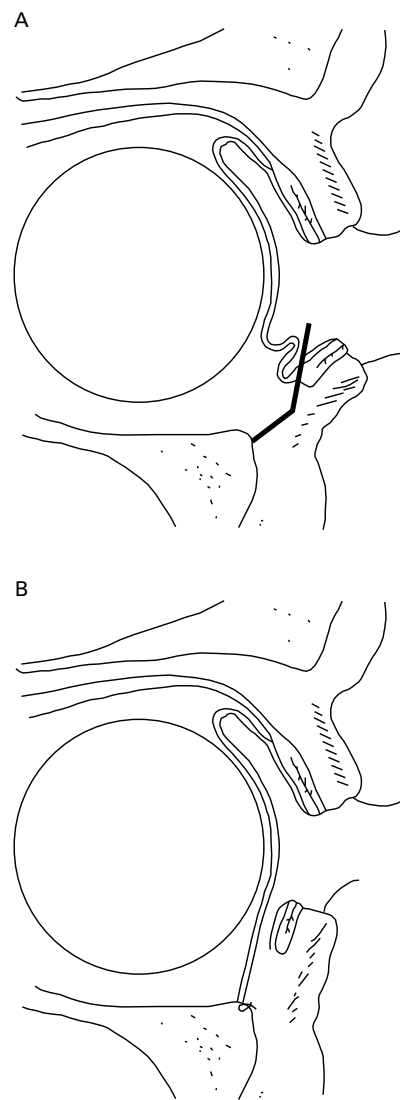


Figure 1 (A) The bold line marks the dissection plane. (B) The posterior conjunctival edge sutured down to the periosteum.

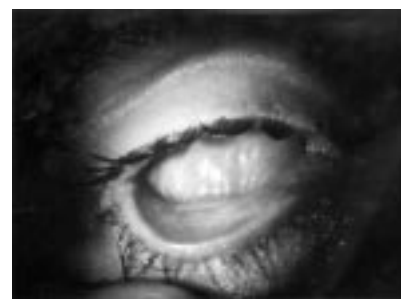


Figure 2 Manual eversion of the lower lid shows a deep fornix with a well epithelialised inner lid surface and no symblepharon.

ondary intention. The tarsal strip procedure performed during the surgery aims to eradicate the lower lid laxity and sag.²

In conclusion, this modified technique allows the use of internal fixation to correct the lower fornix while minimising the risk of lower lid retraction or entropion.

RIAD N MA'LUF

Department of Ophthalmology, American University of Beirut-Medical Center, 113-6044 Beirut, Lebanon
Accepted for publication 8 February 1999

- 1 Neuhaus RW, Hawes MJ. Inadequate inferior cul-de-sac in the anophthalmic socket. *Ophthalmology* 1992;99:153-7.
- 2 Anderson RL, Gordy DD. The tarsal strip procedure. *Arch Ophthalmol* 1979;97:2192.
- 3 Heinz GW, Nunery WR. Anophthalmic socket: evaluation and management. In: McCord CD, Tanenbaum M, eds. *Oculoplastic surgery*. 3rd ed. New York: Raven Press, 1995:609-37.

Lymphocytoma cutis with conjunctival lesions

EDITOR.—Lymphocytoma cutis is a benign lymphoid hyperplasia which typically occurs over the head and neck. We report a case of lymphocytoma cutis with conjunctival lesions; only one other case with lesions affecting the conjunctiva has previously been reported.

CASE REPORT

A 30 year old woman presented with a 10 year history of multiple erythematous papules over her nose, cheeks, and forehead. The papules were more numerous in the summer and the use of sun screens reduced the number of new lesions. Eight years earlier she had developed discrete pink conjunctival lesions. There was no previous history of trauma to the eyes. The lesions were asymptomatic and did not affect her vision. They were surgically excised for cosmetic reasons but reappeared within 2 months.

Examination revealed multiple 1-2 mm erythematous papules over her nose and cheeks. Three flesh coloured lesions were present on the right conjunctiva in the interpalpebral fissure, two medially and one laterally (Fig 1), and one on the left interpalpebral fissure. There was no lymphadenopathy or hepatosplenomegaly and a full blood count, biochemistry profile, and immunoglobulin profile were normal. *Borrelia burgdorferi* antibodies were not detected.

The histology of a papule from both the nose and conjunctiva was similar showing a discrete lymphoid aggregate with germinal centre formation, prominent tingible body macrophages, and a surrounding mantle zone. Immunohistochemical studies of these lesions demonstrated CD20, CD79a, and CD21 positivity; CD23 and CD10 positivity within the germinal centres; and CD5, bcl-2, and cyclin D, negativity. There was no evidence of light chain restriction and immunoglobulin gene rearrangement studies were polyclonal on both cutaneous and conjunctival lesions using polymerase chain reaction (PCR) based techniques.

These histological, immunotypal, and genotypic studies are fully consistent with a diagnosis of lymphocytoma cutis.

The number of cutaneous lesions and prominence of conjunctival lesions increases during the summer and there has been some benefit in reducing the number of new cutaneous lesions with the use of sun screens.

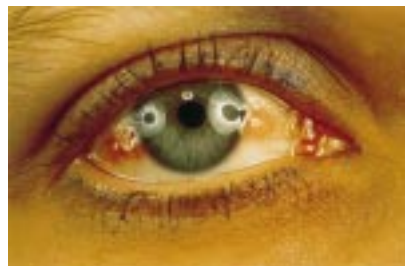

Figure 1 Lesions of lymphocytoma cutis affecting the right conjunctiva.

COMMENT

Lymphocytoma cutis is a reactive lymphoid hyperplasia. Lesions may be papular or nodular, solitary or multiple. Solitary nodular lesions may resemble cutaneous B cell lymphoma both clinically and histologically but behave in a benign manner.¹ The condition most commonly affects the head and neck and, as in our case, may be exacerbated by sun exposure.^{2,3} Other environmental factors have been implemented in the aetiology of lymphocytoma cutis including *Borrelia burgdorferi* infection,⁴ trauma,⁵ and certain drugs⁶; however, most cases of lymphocytoma cutis are of unknown aetiology.

Mucosal membrane involvement with lymphocytoma cutis is extremely rare with only one previously reported case of lymphocytoma cutis affecting the conjunctiva in the German archives in 1935,⁷ although lesions affecting the oral mucosa have been more frequently described.⁸ However, the conjunctiva is a recognised site for primary B cell lymphomas, particularly MALT lymphomas. In our case the histology of both cutaneous and conjunctival lesions showed reactive lymphoid follicles with good preservation of the normal architecture, tingible body macrophages, and lack of bcl-2 positivity. In addition, analysis of the immunoglobulin heavy chain genes showed no evidence of a B cell clone, thus helping to exclude the diagnosis of a primary B cell lymphoma.

A foreign body reaction within the eye may also result in similar lesions both clinically and histologically to those of lymphocytoma cutis. However, there was no preceding trauma to the eyes and the fact the lesions are multiple, affect both eyes, and recurred after surgical excision makes the diagnosis of lymphocytoma cutis of the conjunctiva more likely than a foreign body reaction.

Cases of lymphocytoma cutis with conjunctival lesions are extremely rare. In our patient the conjunctival lesions have persisted for a period of 8 years.

JULIA J SCARISBRICK
GUY ORCHARD
ROBIN RUSSELL-JONES

*Skin Tumour Unit, St John's Institute of Dermatology,
St Thomas's Hospital, London SE1 7EH*

Correspondence to: Dr Scarisbrick.

Accepted for publication 15 February 1999

- 1 Fitzpatrick T, Eisen A, Wolff K. *Dermatology in general medicine*. 4th ed. New York: McGraw-Hill, 1993:1304-5.
- 2 Frain-Bell W, Magnus I. A study of the photosensitivity factor in cutaneous lymphocytoma. *Br J Dermatol* 1971;84:25-31.
- 3 Munro D, Du Vivier A. Lymphocytoma cutis. *Br J Dermatol* 1972;87:288-9.
- 4 Albrecht S, Hofstadter S, Artsob H, et al. Lymphadenitis benigna cutis resulting from *Borrelia* infection. *J Am Acad Dermatol* 1991;24:621-5.
- 5 Demis D. *Clinical dermatology*. 17th ed. Philadelphia: Lippincott Company, 1990:20-2:1-4.
- 6 Magro C, Crowson A. Drug-induced immune dysregulation as a cause of atypical cutaneous lymphoid infiltrates. *Hum Pathol* 1996;27:125-32.
- 7 Epstein S. Lymphocytome der Haut mit Beteiligung der Conjunctiva Bulbi. *Arch Dermatol Syph* 1935;173:181-95.
- 8 Self SJ, Carter VH, Noojin RO. Disseminated lymphocytoma cutis. *Arch Dermatol* 1969;100:459-64.

Acute myelogenous leukaemia in an adult presenting with uveitis

EDITOR.—Ocular involvement has commonly been reported in patients with acute leukaemias.¹⁻³ Although acute lymphoblastic leukaemia (ALL) may present as uveitis, this

presentation has rarely been reported in patients with acute myeloid leukaemia (AML).⁴ We describe an adult male who initially presented with an anterior uveitis followed by the rapid development of orbital involvement who was subsequently diagnosed with AML.

CASE REPORT

A 43 year old man presented to the emergency room with a 5 day history of photophobia and redness of the right eye with a precipitous decrease in vision over the previous 24 hours. He had been seen 2 days earlier by another ophthalmologist and was found to have retinal vasculitis and anterior uveitis. He was started on oral corticosteroids and referred to an internist for systemic examination for the presumptive diagnosis of Behçet's disease. His medical history was remarkable for anal and mouth abscesses, 2 months before his visit.

On examination visual acuity was 6/60 right eye and 6/6 left eye. Ocular examination of the left eye was unremarkable. There was conjunctival injection, keratic precipitates, +2 anterior chamber cells, 360 degrees of iris synechiae, and an inflammatory membrane covering the anterior surface of the lens. The anterior chamber was deep and the intraocular pressure was within the normal range. Examination of the right eye revealed no eyelid swelling or proptosis. Funduscopy examination of the right eye was not possible because of the pupillary membrane. A diagnosis of uveitis was made, an examination was begun including HLA B27 and HLA B51 and the patient was started on frequent topical corticosteroids.

Three days later the patient developed an acute onset of severe eyelid swelling, pain, and proptosis of the right eye (Fig 1). Visual acuity of the right eye was counting fingers and the intraocular pressure was elevated at 44 mm Hg. A complete blood cell count (CBC) and peripheral blood smear revealed predominance of blast cells, and a diagnosis of AML was

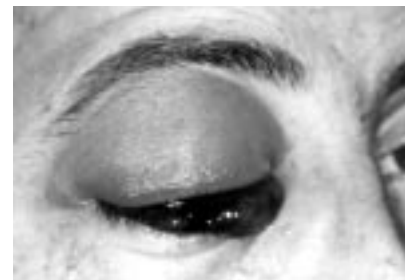

Figure 1 Acute onset of severe eyelid swelling and proptosis 3 days after the initial presentation with anterior uveitis.

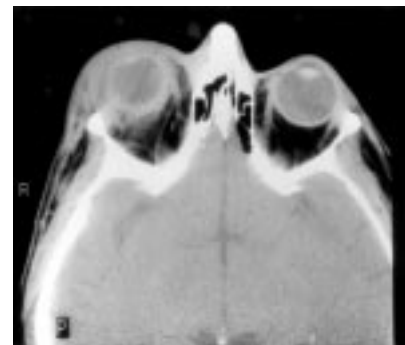


Figure 2 Computed tomograph scan of the orbits demonstrating an infiltrating mass lesion surrounding the right globe.

made. B-scan ultrasonography of the right eye revealed vitreous opacities, a tractional retinal detachment temporally, thickened ocular walls, and a mass lesion in the posterior orbit. An emergent computed tomograph scan confirmed the presence of an infiltrating orbital mass (Fig 2) and an urgent canthotomy, cantholysis, and orbital biopsy were performed. The biopsy demonstrated evidence of focal aggregates of mononuclear cells with cleaved nuclei consistent with leukaemic infiltrate. With a presumptive diagnosis of orbital leukaemic infiltrate, the patient underwent orbital irradiation in conjunction with systemic broad spectrum antibiotics. He responded rapidly with a decrease of lid swelling, proptosis, and the intraocular pressure within 24 hours. Immunohistochemical staining of the orbital biopsy was not able to demonstrate conclusively the presence of leukaemic cells.

The patient subsequently underwent an unsuccessful bone marrow transplant, and died 3 months after the initial presentation. Postmortem examination of the orbital biopsy was not performed.

COMMENT

Although uveitis is commonly reported in children with relapsing acute leukaemias, it rarely is the first presentation of AML.^{4,5} Leukaemic retinopathy, including haemorrhages, cotton wool spots, and retinovascular abnormalities are the most common ocular manifestations in patients with AML.¹⁻⁴ Anterior segment and vitreous findings are rarely described in these patients. In a prospective study of 56 patients with AML, 53% of the patients had ocular manifestations at the time of diagnosis, but none had anterior segment or vitreous involvement.⁶

In our patient, the initial presentation with anterior iridocyclitis did not raise suspicion of malignancy. However, the recent medical history of anal and mouth abscesses in a previously healthy young man was suggestive of an immunocompromised host. The worsening of anterior chamber inflammation despite aggressive topical application of steroid was followed in several days by signs of rapid orbital involvement. Posterior segment involvement was not seen at the time of presentation because of a dense pupillary membrane, but was later documented on B-scan echography. The diagnosis of retinal vasculitis by the previous ophthalmologist most likely represented leukaemic retinopathy secondary to perivascular infiltration by the leukaemic cells. The orbital involvement in this patient may have been due to leukaemic infiltration, orbital haemorrhage, or orbital cellulitis. Although the diagnosis of leukaemic infiltrate was not immunohistochemically confirmed, the rapid response to irradiation, and the pattern of intraocular as well as retrobulbar involvement pointed towards this diagnosis.

The delay in the diagnosis of acute myeloid leukaemia in our patient was minimised by the rapid progression of the disease, quickly leading to further investigations. However, the question arises whether an initial CBC should be performed on all patients with anterior iridocyclitis. In our institution, of 534 adult patients treated for uveitis over the past 3 years, five cases were secondary to intraocular tumours, and only the present case was associated with an acute leukaemia. This low incidence argues against the use of a CBC for screening of previously healthy adults with typical anterior uveitis. However, in cases of worsening inflammation despite frequent

topical steroids a CBC with smear may be recommended.

Presented at the annual meeting of the Canadian Ophthalmological Society on 28 June 1998 in Calgary, Alberta.

HOSSEIN DANESHVAR
WILLIAM HODGE
STEVE GILBERG

The University of Ottawa Eye Institute, 501 Smyth Road, Ottawa, Ontario K1H 8L6, Canada

Correspondence to: Dr William Hodge.

Accepted for publication 19 February 1999

- 1 Rosenthal AR. Ocular manifestations of leukemia: a review. *Ophthalmology* 1983;90:899-905.
- 2 Kincaid MC, Green WR. Ocular and orbital involvement in leukemia. *Surv Ophthalmol* 1983;27:211-32.
- 3 Schachat AP, Markowitz JA, Guyer DR, et al. Ophthalmic manifestations of leukemia. *Arch Ophthalmol* 1989;107:697-700.
- 4 Ayliffe W, Foster CS, Marcoux P, et al. Relapsing acute myeloid leukemia manifesting as hypopyon uveitis. *Am J Ophthalmol* 1995;119:361-4.
- 5 MacLean H, Clarke MP, Strong NP, et al. Primary ocular relapse in acute lymphocytic leukemia. *Eye* 1996;10:719-22.
- 6 Karesh JW, Goldman EJ, Reck K, et al. A prospective ophthalmic evaluation of patients with acute myeloid leukemia: correlation of ocular and hematologic findings. *J Clin Oncol* 1989;7:1528-32.

Subretinal haemorrhage in idiopathic intracranial hypertension

EDITOR.—Haemorrhage into the various spaces and potential spaces of the eye is a not uncommon finding in idiopathic intracranial hypertension (IIH), especially nerve fibre layer haemorrhages, a nearly constant feature of fully developed papilloedema. Less frequently reported are vitreous, subhyaloid, and subretinal haemorrhages. We present a patient with bilateral peripapillary subretinal haemorrhages as the prominent manifestation of IIH, whose haemorrhages resolved as her IIH improved.

CASE REPORT

A 41 year old obese woman was evaluated because of an unusual optic disc appearance bilaterally. One year before evaluation, she developed severe, diffuse headaches which would wake her from sleep. There were no associated visual symptoms. Brain computed tomography (CT) was normal. The headaches resolved spontaneously, only to recur months later, this time accompanied by blurred vision. She was seen by an optometrist, who noted "retinal bleeding".

On examination she was obese but appeared well with a blood pressure of 130/90. Corrected visual acuity was 20/20 in both eyes, and colour vision was normal. Pupils were briskly reactive with no relative afferent pupillary defect. Ocular motility was normal. Automated perimetry revealed enlarged blind spots. There was minimal bilateral disc oedema with prominent surrounding subretinal haemorrhages (Fig 1). The haemorrhages spared the inferotemporal disc in the right eye and the temporal disc in the left. The maculas, periphery, and vessels were normal.

B-scan ultrasonography revealed no evidence of optic nerve drusen. Fluorescein angiogram did not demonstrate neovascularisation. Magnetic resonance image (MRI) of the brain and orbits, with and without gadolinium, was normal. Lumbar puncture demonstrated an opening pressure of 280 mm CSF with normal contents. A diagnosis of IIH was made.

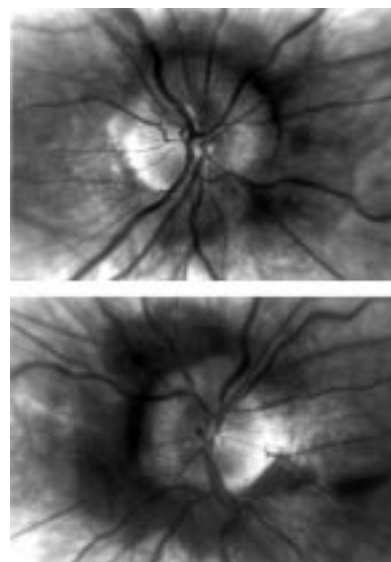


Figure 1 Fundus photographs demonstrating minimal disc oedema with prominent surrounding subretinal haemorrhages.

Over the next 2 years, the patient lost a total of 54 lb (24.5 kg), and took no new medications. On follow up examination, she reported normal vision and no further headaches. Her visual function was stable, and fundus examination showed near complete resolution of the subretinal haemorrhages (Fig 2).

COMMENT

The differential diagnosis of subretinal haemorrhage is extensive. Among the more frequently cited aetiologies are trauma, choroidal tumour, aneurysmal subarachnoid haemorrhage, and retinal vascular disease such as diabetic or hypertensive retinopathy. Infrequently, subretinal haemorrhages have been reported in association with IIH.^{1,2} All of these reports noted the additional features of either small anomalous discs or peripapillary subretinal neovascular membranes, the latter usually associated with chronic papilloedema. In our patient, there was no evidence of neovascular membranes, and the papilloedema itself was not prominent.

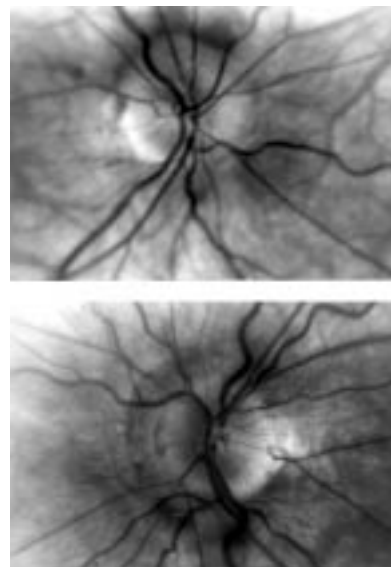


Figure 2 Fundus photographs demonstrating near complete resolution of subretinal haemorrhages.

Ocular haemorrhages are common in cases of aneurysmal subarachnoid haemorrhage, occurring in 17% of cases.³ The haemorrhages may be subretinal, retinal, preretinal, or intravitreal. When subretinal, the haemorrhages are frequently peripapillary. It is now well accepted that the ocular haemorrhages seen in patients with aneurysmal subarachnoid haemorrhage are caused by acute elevations in the intracranial pressure with subsequent retinal venous hypertension. Acute increases in intracranial pressure induce a venous stasis retinopathy, which may result in intraocular bleeding.⁴

Given that the mechanism of disc oedema in IIH is raised intracranial pressure, it would follow that retinal haemorrhages should be common in this disorder. Large vitreous bleeds, however, are very rare in IIH, as are subretinal haemorrhages, probably because of the chronicity and lack of sudden pressure elevation in IIH. Pre-existing communicating vessels between the retinal and choroidal circulations probably dilate in response to long standing papilloedema, creating opticociliary shunt vessels of varying sizes.⁵ Perhaps these shunts unload the increased venous pressure on the retinal circulation, reducing the incidence of large intraocular haemorrhages from venous stasis retinopathy. An acute elevation in intracranial pressure in a patient with IIH may occur with coughing or other variants of the Valsalva manoeuvre. Such a precipitous rise in pressure could produce ocular haemorrhages of the type seen in our patient.

We believe our patient's elevated intracranial pressure probably caused prominent peripapillary subretinal haemorrhages with only mild disc oedema. Subsequent weight loss probably resulted in normalisation of her intracranial pressure, as it paralleled the resolution of her disc oedema as well as her headaches and visual complaints. Near complete resolution of the peripapillary haemorrhages accompanied the improvement in her symptoms. This case serves as yet another confirmation of the proposed mechanism of peripapillary subretinal haemorrhage as occurring secondary to raised intracranial pressure.

This work was supported in part by a departmental grant (ophthalmology) from Research to Prevent Blindness, Inc (NY) and ophthalmology department, National Institutes of health CORE grant no P30-EY0 6360.

BARRY J MCCASLAND
Department of Neurology

MARIA E MENDICINO
Department of Ophthalmology

NANCY J NEWMAN
Departments of Ophthalmology, Neurology, and of
Neurological Surgery, Emory University School of
Medicine, Atlanta, GA 30322, USA

Correspondence to: Dr Newman.

Accepted for publication 22 February 1999

- Coppeto JR, Monteiro MLR. Juxtapapillary subretinal hemorrhages in pseudotumor cerebri. *J Clin Neuro-ophthalmol* 1985;5:45-53.
- Jamison RR. Subretinal neovascularization and papilledema associated with pseudotumor cerebri. *Am J Ophthalmol* 1978;85:78-81.

- Frizzell RT, Kuhn F, Morris R, *et al*. Screening for ocular hemorrhages in patients with ruptured cerebral aneurysms: a prospective study of 99 patients. *Neurosurgery* 1997;41:529-34.
- Rios-Montenegro EN, Anderson DR, David NJ. Intracranial pressure and ocular dynamics. *Arch Ophthalmol* 1973;89:52-7.
- Orcutt JC, Page NGR, Sanders MD. Factors affecting visual loss in benign intracranial hypertension. *Ophthalmology* 1984;91:1303-12.

Accidental instillation of N-butyl cyanoacrylate into the anterior chamber

EDITOR,—Cyanoacrylate adhesive, a relatively inert material, may be very useful in sealing small corneal perforations. We report a case where accidental injection of N-butyl cyanoacrylate (tissue adhesive) through the corneal perforation into the anterior chamber resulted in complications and required surgical removal.

CASE REPORT

A 64 year old man with a history of left sided Bell's palsy of 6 months' duration had difficulty with left eyelid closure, requiring a suture tarsorrhaphy and placement of a gold weight in the left upper lid. He went on to develop a descemetocele of the left cornea which eventually perforated. N-butyl cyanoacrylate was applied using a cannula to the corneal perforation site and a bandage contact lens was placed. After noting that the adhesive had entered into the anterior chamber, he was referred.

On initial examination, best corrected visual acuity was right eye 20/25 and left eye hand movements. On slit lamp examination, the left cornea showed a central perforation with overlying cyanoacrylate adhesive which had extended down into the anterior chamber. The central iris was covered with adhesive (Fig 1), creating pupillary block. The patient was given preoperative intravenous mannitol and a penetrating keratoplasty was performed. At the time of surgery, the cyanoacrylate adhesive was firmly adherent to both the corneal endothelium and iris. After trephination, the adhesive was gently stripped off the iris (blunt dissection) using forceps. The lens had spontaneously expelled from the eye along with vitreous. After removing cortical remnants and performing an open sky anterior vitrectomy, a donor cornea was sutured in place. Eight months after surgery, visual acuity is 20/80 and the graft remains clear.

COMMENT

Tissue adhesives are relatively inert polymers which were first used in 1969 to seal a corneal perforation, thus eliminating the need for ocular surgery.¹ In addition, tissue adhesives have been used in the ophthalmic setting for tarsorrhaphy, punctal occlusion, ptosis, retinal holes, and scleral thinning. With corneal perforations, the adhesive creates an inflammatory reaction and host fibrous tissue grows behind the adhesive filling in the gap. The adhesive should only be applied to perforations that are less than 1.5 mm in diameter

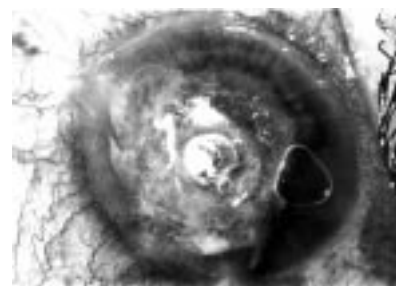


Figure 1 Presurgical photograph showing N-butyl cyanoacrylate in the anterior chamber covering the iris.

and should not be used if there is prolapse of intraocular contents. For flat anterior chambers, air or viscoelastic should be used first.

In animal experiments, small amounts of tissue adhesive injected into the anterior chamber created conjunctival vascular engorgement, mild self limited keratitis/uveitis, and localised corneal scarring; however, there was minimal ocular toxicity after 1 year.² If injected in larger amounts, intense inflammation, corneal neovascularisation and necrosis, were seen. Other reported problems with the use of tissue adhesive include symblepharon, giant papillary conjunctivitis, and retinal toxicity.³ In our case, the tissue adhesive created pupillary block. Because of the corneal perforation, intraocular pressure readings were unobtainable. After surgical intervention (penetrating keratoplasty, dissection of adhesive off the iris, self expulsion of lens, open sky vitrectomy), the patient remains comfortable with a clear corneal graft and a good chance of achieving excellent visual acuity. While accidental injection of tissue adhesive into the anterior chamber may be tolerated well with minimum complications, larger amounts should be removed.

BRUCE M ZAGELBAUM

Department of Ophthalmology, North Shore University Hospital, New York University School of Medicine, Manhasset, NY, and Department of Ophthalmology, Mercy Medical Center, Rockville Centre, NY, USA

BRUCE H SCHWARTZ

Department of Ophthalmology, North Shore University Hospital, New York University School of Medicine, Manhasset, NY, USA

DAVID B NELSON

Department of Ophthalmology, North Shore University Hospital, New York University School of Medicine, Manhasset, NY, NY, and Department of Ophthalmology, Mercy Medical Center, Rockville Centre, NY, USA

Correspondence to: Bruce M Zagelbaum, MD, 333 East Shore Road, Suite 202, Manhasset, NY 11030, USA.

Accepted for publication 8 March 1999

- Arentsen JJ, Laibson PR, Cohen EJ. Management of corneal descemetoceles and perforations. *Ophthalmic Surg* 1985;16:29-33.
- Refojo MF, Dohlman CH, Ahmad B, *et al*. Evaluation of adhesives for corneal surgery. *Arch Ophthalmol* 1968;80:645-56.
- Leahey AB, Gottsch JD, Stark WJ. Clinical experience with N-butyl cyanoacrylate (Nexacryl) tissue adhesive. *Ophthalmology* 1993;100:173-80.



Multifocal electroretinography in patients with occult macular dystrophy

S FUJII, M F T ESCAÑO, K ISHIBASHI, et al.

Br J Ophthalmol 1999 83: 878
doi: 10.1136/bjo.83.7.878b

Updated information and services can be found at:
<http://bjo.bmj.com/content/83/7/878.3.full.html>

These include:

References

This article cites 6 articles, 1 of which can be accessed free at:
<http://bjo.bmj.com/content/83/7/878.3.full.html#ref-list-1>

Email alerting service

Receive free email alerts when new articles cite this article. Sign up in the box at the top right corner of the online article.

Notes

To request permissions go to:
<http://group.bmj.com/group/rights-licensing/permissions>

To order reprints go to:
<http://journals.bmj.com/cgi/reprintform>

To subscribe to BMJ go to:
<http://group.bmj.com/subscribe/>