

Phenotypic variations in a family with retinal dystrophy as result of different mutations in the *ABCR* gene

B Jeroen Klevering, Marc van Driel, Dorien J R van de Pol, Alfred J L G Pinckers, Frans P M Cremers, Carel B Hoyng

Abstract

Aims—To describe two phenotypic variations of autosomal recessive retinal dystrophy occurring in a consanguineous family in a pseudodominant pattern, resulting from mutations in the ATP binding cassette transporter (*ABCR*) gene.

Methods—Patients of this family underwent an extensive ophthalmic evaluation, including fundus photography, fluorescein angiography, and electroretinography (ERG). Genetic analysis comprised sequence analysis of the retina specific *ABCR* gene.

Results—Five patients presented with decreased visual acuity in the second decade, central chorioretinal atrophy associated with a central scotoma, and severely decreased photopic and scotopic ERG responses. This clinical picture, which in our opinion resembles a cone-rod dystrophy (CRD), was associated with compound heterozygosity for IVS30+1g →t and IVS40+5g→a mutations in the *ABCR* gene. The four remaining patients presented with night blindness in the first decade because of a retinitis pigmentosa-like (RP-like) dystrophy. In addition to a pale “waxy” optic disc, attenuated retinal vessels and bone spicule deposits, a widespread chorioretinal atrophy was observed. The scotopic ERG was extinguished and the photopic ERG was severely diminished. Genetic analysis revealed a homozygous 5' splice mutation IVS30+1g →t in the *ABCR* gene.

Conclusion—Mutations in the *ABCR* gene can cause clinical pictures resembling autosomal recessive RP and autosomal recessive CRD.

(Br J Ophthalmol 1999;83:914-918)

and a retinitis pigmentosa-like dystrophy (RP-like). These phenotypes co-segregated with DNA markers flanking the *ABCR* gene and subsequent sequence analysis revealed compound heterozygosity (CRD-like) and homozygosity (RP-like) for *ABCR* mutations.

Patients and methods

PATIENTS

Patients of a consanguineous family with hereditary retinal degeneration originally described by Deutman⁵ as centropertipheral tapetoretinal degeneration resembling STGD were reevaluated. All members of the family were examined by one of the authors (CBH). Two different phenotypes could be distinguished based on the clinical findings only. After consulting with the department of human genetics we collected blood samples for molecular genetic analysis, after informed consent was obtained. Patient IV-3 had to be examined at home because of her poor general condition. Unfortunately she died 3 months later.

CLINICAL AND ELECTROPHYSIOLOGICAL INVESTIGATIONS

After the ophthalmic history was taken, all patients underwent a standard ophthalmological evaluation including detailed fundus examination. In addition, fundus photography, fluorescein angiography, and electroretinography (ERG) were performed. In ERG tests, the patients faced a modified sphere of a Goldmann-Weekers adaptometer, lit by two 40 W incandescent lamps in order to furnish a Ganzfeld adaptation. After a scleral contact lens, equipped with measuring electrodes, was inserted, a reference electrode was placed on the forehead and the patient was earthed by means of two earclip electrodes. A xenon flash-light was used for flash responses (flash luminance 6.85 cd/m²/s photopic and 0.85 cd/m²/s scotopic). Measurements were taken at photopic and adaptation levels. The scotopic ERG was a rod isolated dark adapted scotopic response with white (12 minutes of dark adaptation) and blue stimuli (15 minutes of dark adaptation). This ERG technique⁶ does not precisely meet the ISCEV standard, but for reasons of comparison over a long period of time (patient V-9, follow up 1969-95) the same method was applied. The lower limit of normality with this technique was 100 μV for the photopic b-wave, 150 μV for the scotopic b-wave with a white stimulus, and 170 μV when a blue stimulus was used.

Department of Ophthalmology, University Hospital Nijmegen, Netherlands
B J Klevering
A J L G Pinckers
C B Hoyng

Department of Human Genetics, University Hospital Nijmegen, Netherlands
M van Driel
D R J van de Pol
F P M Cremers

Correspondence to:
Dr B J Klevering,
Department of Ophthalmology, University Hospital Nijmegen, PO Box 9101, 6500 HB Nijmegen, Netherlands.

Accepted for publication
19 March 1999

Stargardt's disease (STGD) presents in the first or second decade of life with a bilateral gradual diminution of vision due to progressive atrophy of the macular retinal pigment epithelium and the choriocapillaris in combination with degeneration of the photoreceptors of the posterior pole.¹ STGD is caused by mutations in the retina specific ATP binding cassette transporter (*ABCR*) gene, which also has been shown to be involved in age related macular degeneration (AMD), although the latter finding has been disputed.²⁻⁴ We describe a single consanguineous family with two different phenotypes: cone-rod-like dystrophy (CRD-like)

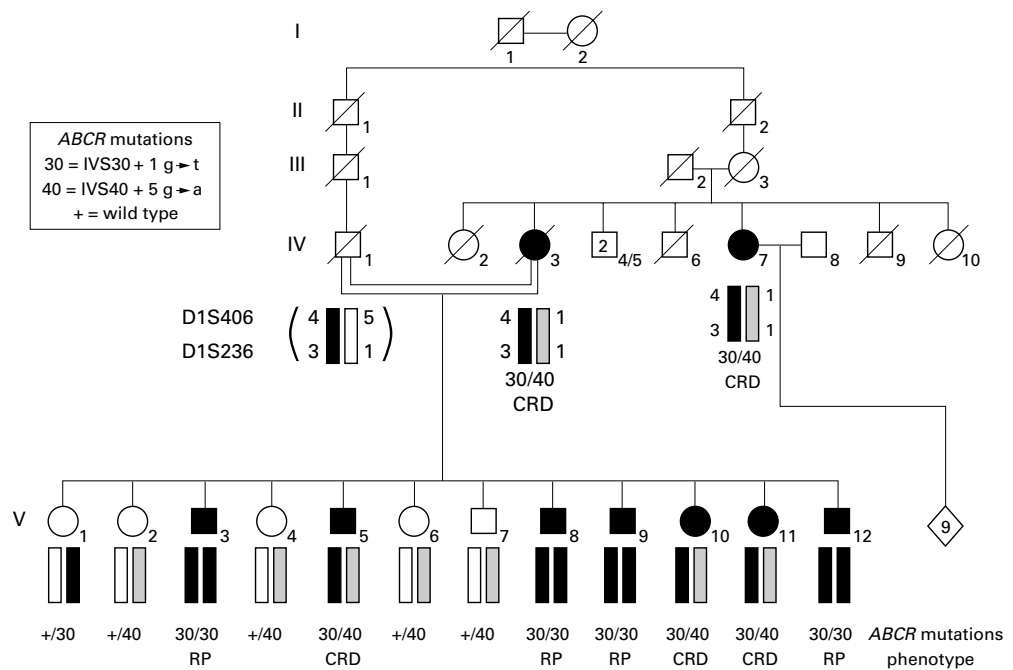


Figure 1 Pedigree of the RP-like/CRD-like family. The black bar represents the *D1S406/D1S236* haplotype carrying *IVS30+1g→t* mutation (30), the shaded bar contains the *IVS40+5g→a* mutation (40) in the *ABCR* gene. The diamond symbol denotes healthy children of IV-7 and IV-8.

GENOTYPING

DNA was extracted from leucocytes as described previously.⁷ *D1S406* (UT2069) and *D1S236* (AFM205ta11) marker analysis was carried out as described elsewhere.⁸ Sequence analysis of the *ABCR* exons was performed as described by Allikmets *et al* and Gerber *et al*.^{2,9}

Results

The pedigree of the RP-like/CRD-like family is depicted in Figure 1. Nine members of the family were affected, two sibs in generation IV and seven sibs in generation V. No abnormalities were found in individuals IV-1, V-1, V-2, V-4, V-6, and V-7. After the ophthalmic history was taken and a full ophthalmic examination was performed (as summarised in Table 1), two different phenotypes could be distinguished.

Five individuals (IV-3, IV-7, V-5, V-10, V-11) presented with initial complaints of decreased central vision or a grey spot in the central field of vision in the second decade. At the time of our examination the visual acuity of these five patients was reduced to counting fingers. Funduscopy disclosed a circumscribed area of central chorioretinal atrophy. Waxy pallor of the optic disc, attenuated retinal vessels, and bone spicule pigment deposition in the mid-periphery were not observed in these patients (Fig 2A, B, C). Contrary to the report of Deutman in 1971 we did not find the temporal paleness he described in patients IV-3 and V-10.⁵ Goldmann kinetic visual fields of patient IV-3, performed in 1967 when she was 54 years of age, showed a large central scotoma and contracted isoptres. The visual field of patient V-5 at age 27 revealed a central scotoma and restriction of the temporal periphery, at that age the photopic ERG was still normal but the scotopic ERG was already

moderately decreased.⁵ At the time of our investigation the photopic ERG responses were moderately subnormal in patient V-11 and severely subnormal or extinguished in the other four patients. The scotopic ERG was extinguished in all patients in this group, except for patients IV-7, V-5, and V-11 when the blue stimulus with 15 minutes of dark adaptation was used (Table 1).

The clinical picture of the other affected sibs (V-3, V-8, V-9, V-12) was altogether different. Initially they presented with complaints of decreased night vision at about the age of 6 years. Gradually the visual acuity of these patients decreased and at the time of our examination their visual acuity was light perception, except for the youngest patient (V-12) who could still perceive hand movements. Ophthalmoscopically they all demonstrated classic aspects of RP, with a waxy optic nerve head, attenuation of the retinal vessels, and pigmentary retinopathy with bone spicule deposits in the (mid) periphery. Furthermore, large areas of poorly demarcated chorioretinal atrophy were noted in these patients, also in the posterior pole (Fig 2D, E, F). Goldmann perimetry of patient V-3 showed a central scotoma and peripheral restriction at the age of 22. Patient V-8 demonstrated restricted visual fields at age 13, the visual field of patient V-9 revealed a constriction nasally at age 21 and patient V-12 showed a central scotoma and concentric impairment of sensitivity at the age of 11.⁵ ERG recordings performed in patients V-8, V-9, and V-12 showed severely decreased photopic ERG responses and an extinguished scotopic ERG (Table 1).

Linkage analysis using highly polymorphic DNA markers from 1p21 showed that all affected sibs in generation V inherited the same chromosomal haplotype from their father

Table 1 Minimal values for ERG recordings: 100 μ V for the photopic ERG, 150 μ V for the scotopic ERG with a white stimulus after 12 minutes of dark adaptation, 170 μ V for the scotopic ERG with a blue stimulus after 15 minutes of dark adaptation

Number	Genotype	Age	Age of onset (years)	Initial symptom	Visual acuity (1995)	Funduscopy	Photopic ERG (μ V)		Scotopic ERG (μ V) white		Scotopic ERG (μ V) blue	
							right eye	left eye	right eye	left eye	right eye	left eye
IV-3	HTZ	84	12	Decrease in visual acuity	CF	Marked central chorioretinal atrophy and mild chorioretinal atrophy in the mid-periphery. No abnormalities of the vessels and the optic disc. No bone spicules.	0	0	0	0	0	0
IV-7	HTZ	74	20	Decrease in visual acuity	CF	Marked central chorioretinal atrophy and irregular hyperpigmentation of the pigment epithelium in the posterior pole. Patchy chorioretinal atrophy in the mid-periphery. Temporal paleness of the optic disc.	20	30	0	0	75	30
V-3	HMZ	59	6	Night blindness	LP	Central and mid-peripheral chorioretinal atrophy, mid-peripheral bone spicules, narrow vessels, and a "waxy" pale optic disc.	NP	NP	NP	NP	NP	NP
V-5	HTZ	56	15	Decrease in visual acuity	CF	Central chorioretinal atrophy with irregular hyperpigmentation of the retinal pigment epithelium. No mid-peripheral abnormalities.	30	20	0	0	50	30
V-8	HMZ	51	7	Night blindness	LP	Marked central chorioretinal atrophy, mid-peripheral bone spicules and diffuse chorioretinal atrophy. Severe narrowing of the retinal vessels and temporal paleness of the optic disc.	20	40	0	0	0	0
V-9	HMZ	50	7	Night blindness	LP	Marked central and mid-peripheral atrophy, with central hyperpigmentation and mid-peripheral bone spicules, narrow vessels, and paleness of the optic disc.	0	80	0	0	0	0
V-10	HTZ	48	12	Decreased visual acuity	CF	Central chorioretinal atrophy with focal hyperpigmentation. No bone spicules and no abnormalities of the vessels and the optic disc.	30	50	0	0	0	0
V-11	HTZ	46	12	Grey spot in the central field of vision	CF	Central chorioretinal atrophy with focal hyperpigmentation. Small round patches of chorioretinal atrophy with mild hyperpigmentation in the mid-periphery. Mild temporal paleness of the optic disc.	80	80	0	0	75	30
V-12	HMZ	43	6	Night blindness	HM	Central chorioretinal atrophy with patchy atrophy in the mid-periphery. Bone spicules, narrow vessels, and a pale optic disc.	20	55	0	0	0	0

HTZ = compound heterozygosity for IVS30+1g→t and IVS40+5g→a mutation; HMZ = homozygosity for IVS30+1g→t mutation; CF = counting fingers; HM = hand movements; LP = light perception; NP = not performed.

(IV-1) indicated by a black bar in Figure 1. Since the mother of these sibs (IV-3), as well as an aunt (IV-7) also harbour this chromosomal segment, the corresponding mutation must have been present in this family at least since generation I. In addition, another genetic defect is present in the mother and the aunt (Fig 1, shaded bar). Four sibs of generation V (V-3, V-8, V-9, V-12) inherited the same haplotype from both parents and consequently are homozygous for this chromosomal region. Sequence analysis revealed a severe 5' splice site mutation IVS30+1g→t at ABCR nucleotide position 4539+1. The other three affected sibs in this generation (V-5, V-10, V-11) received the haplotype from their mother that was not present in their father's DNA, rendering them compound heterozygous, with a genetic profile of the ABCR gene resembling their mother and affected aunt. Sequence analysis revealed the heterozygous presence of the IVS30+1g→t mutation, as well as another 5' splice site mutation (IVS40+5g→a) at nucleotide position 5714+5.

Discussion

In this study we describe a consanguineous family in which the affected members display one of two distinctly different phenotypes, either RP-like or CRD-like. These different disease phenotypes completely match two different genotypes. Apparently, different combinations of gene defects in the ABCR gene

result in different phenotypic effects. The four patients who are homozygous for the IVS30+1g→t mutation present with a clinical picture resembling RP, with an age of onset of approximately 6 years. Although this retinal dystrophy harbours several aspects of a classic RP (night blindness, peripheral restricted visual fields, the ERG findings, and attenuation of the retinal vessels, bone spicule deposits, and a waxy optic nerve head on funduscopy), there are some aspects of this phenotype which are not typically associated with RP. The extensive chorioretinal atrophy and pigmentary changes in the posterior pole, the central scotomas in patients V-3 and V-12, and the substantively more reduction in visual acuity than is normally noted in patients with RP lead us to refer to this entity as RP-like.

The patients displaying compound heterozygosity for the IVS30+1g→t and IVS40+5g→a mutations develop a retinal dystrophy which occurs later in life, with an age of onset varying from 12 to 20 years. In these patients decrease of visual acuity and/or a central scotoma is the presenting symptom and at the time of examination the visual acuity did not exceed counting fingers in all five patients. Ophthalmoscopically, all patients show a circumscribed area of chorioretinal atrophy, especially located in the posterior pole. No ophthalmoscopic abnormalities were observed that could be attributed to RP. Strikingly, the central localisation of the retinal dystrophy in

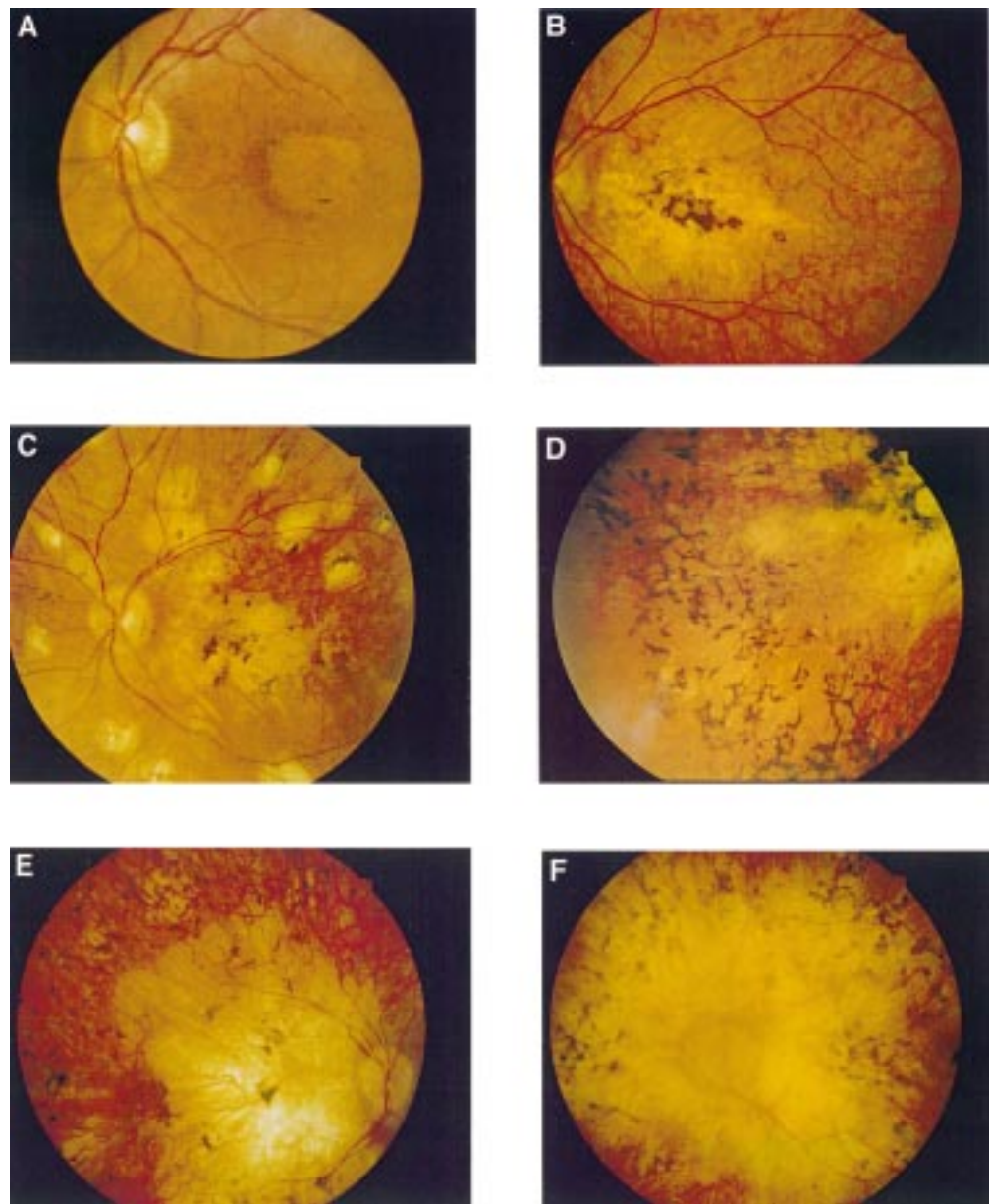


Figure 2 Patient V-5 (A) with CRD-like dystrophy in an early stage (28 years of age) and the same patient (B) at a later stage (54 years of age). Patient V-11 with CRD-like dystrophy in a late stage (C). Three patients with RP-like dystrophy: (D) patient V-9; (E) patient V-12; (F) patient V-3.

patients with compound heterozygosity is not reflected in their ERG recordings, which in general demonstrate a severely affected cone system but an even more affected rod system. This cannot simply be attributed to the fact that most patients have reached an end stage, since early ERG recordings of V-5, at 27 years of age, show the same phenomenon—that is, the scotopic ERG is more affected than the photopic ERG. These ERG responses are very similar to the ERG findings in sibs with homozygous mutations and the resulting RP-like phenotype. It must be mentioned, however, that the measurement of the scotopic responses was unconventional, for reasons stated earlier, and the 12 minute period of dark adaptation when a white stimulus was used, may not have disclosed the entire potential for the development of a rod response. Although the chorioretinal atrophy is far more widespread in

this group compared with the central atrophy observed in the compound heterozygous patients, the results of functional tests such as the ERG are virtually identical. Thus, the retinal disorder in the compound heterozygous patients is more difficult to classify. Since perifoveal yellow spots were never observed and the choroidal fluorescence was never obscured in fluorescein angiography,¹⁰ it is our belief that the original diagnosis of STGD disease is not appropriate. Nevertheless, all these patients initially presented with blurred central vision rather than nyctalopia and the fundus of patient V-5 at 28 years of age shows a well demarcated oval shaped depigmentation of the retinal pigment epithelium in the posterior pole. The visual fields of patients IV-3 and V-5 show a central scotoma or decreased central sensitivity in combination with a mild peripheral restriction. The ERG findings are atypical

and suggest severely affected cone and rod systems with a slight emphasis on damage to the latter. In view of these findings the most likely diagnosis in our opinion is CRD, although the ERG recordings make it difficult to fit this phenotype into previous subtypes of CRD.^{11 12} We therefore have referred to this type of dystrophy as CRD-like. When classified as CRD this phenotype would fit best in the group described by Szlyk *et al* as type 2a CRD.¹¹ It is also possible that these patients have a form of RP which is mainly located centrally, so called central RP or inverse RP,^{13 14} although this entity is not very well defined in literature. The fact that this retinal dystrophy cannot be accurately classified underscores that these diseases need to be defined in genetic terms rather than the current subjective and variable phenotypic terminology.

Allikmets *et al* recently identified mutations in a photoreceptor cell specific ATP binding cassette transporter gene (*ABCR*) in STGD.² Another report from the same group describes alterations in one allele of the *ABCR* gene in some AMD patients, although these findings were not confirmed in a correspondence by Stone *et al*.^{3 4} Our findings suggest that mutations in *ABCR* not only result in STGD but can also cause autosomal recessive CRD-like phenotypes and autosomal recessive RP-like phenotypes. Compound heterozygosity for IVS30+1g→t and IVS40+5g→a mutations results in a clinical picture resembling CRD, whereas homozygosity for the IVS30+1g→t mutation causes a RP-like phenotype. Based on the greater severity of the RP-like phenotype compared with CRD-like phenotype and STGD the IVS30+1g→t mutation can be regarded as a true null allele. A mutation at the +1 position of a 5' splice site invariably inactivates the corresponding splice site. The possible effects of this mutation are discussed in more detail elsewhere.¹⁵ In accordance with our hypothesis we and others thus far have not found two *ABCR* null mutations in STGD patients² (J Kaplan, personal communication; own observation). In addition, Martínez-Mir *et al* recently identified a homozygous 1-bp deletion in the *ABCR* gene of six siblings from a consanguineous RP family.¹⁶ This deletion results in a frameshift early in the coding region and thus represents a true null allele. The IVS40+5g→a mutation lowers, but probably does not abolish, the splice potential of the corresponding splice site, which may explain the less severe phenotype observed in the compound heterozygous CRD-like patients. The fact that both CRD-like and RP-like phenotypes can be caused by mutations in the same gene is not without precedent. Previously, mutations in the RDS/peripherin gene were associated with a myriad of different phenotypes, including autosomal dominant forms of

RP,¹⁷ CRD,¹⁸ macular dystrophy,¹⁹ pattern dystrophies of the retinal pigment epithelium,¹⁹⁻²² and central areolar choroidal dystrophy.²³

This study was supported by the British Retinitis Pigmentosa Society (DvdP), the National Foundation Fighting Blindness (MvD and DvdP), the Rotterdamse Vereniging Blindenbelangen, the Algemene Nederlandse Vereniging ter Voorkoming van Blindheid, the Stichting Blindenhulp, the Stichting de Drie Lichten, the Gelderse Blindenvereniging, and the Landelijke Stichting voor Blinden en Slechtzienden. The research of Frans Cremers was in part made possible by a grant from the Royal Netherlands Academy of Arts and Sciences.

- Deutman AF. Macular dystrophies. In: Ryan SJ, ed. *Retina*. Vol 2. St Louis: CV Mosby, 1989:257-64.
- Allikmets R, Singh N, Sun H, *et al*. A photoreceptor cell-specific ATP-binding transporter gene (*ABCR*) is mutated in recessive Stargardt macular dystrophy. *Nat Genet* 1997;15:236-46.
- Allikmets R, Shroyer NF, Singh N, *et al*. Mutation of the Stargardt disease gene (*ABCR*) in age-related macular degeneration. *Science* 1997;277:1805-7.
- Stone EM, Webster AR, Vandenberg K. Allelic variation in *ABCR* associated with Stargardt disease but not age-related macular degeneration. *Nat Genet* 1998;20:329-30.
- Deutman AF. *The hereditary dystrophies of the posterior pole of the eye*. Assen: Van Gorcum, 1971:150-3.
- Thijssen JM, Pinckers A, Otto AJ. A multipurpose system for ophthalmic electrodiagnosis. *Ophthalmologica* 1974;168:308-14.
- Bach I, Brunner HG, Beighton P, *et al*. Microdeletions in patients with gusher-associated, X-linked mixed deafness (DFN3). *Am J Hum Genet* 1992;50:38-44.
- Hooyng CB, Poppelars F, van de Pol TRJ, *et al*. Genetic fine mapping of the gene for recessive Stargardt disease. *Hum Genet* 1996;98:500-4.
- Gerber S, Rozet JM, van de Pol TRJ, *et al*. Complete exon-intron structure of the retina specific ATP binding transporter gene (*ABCR*) allows the identification of novel mutations underlying Stargardt disease. *Genomics* 1998;48:139-42.
- Gass JDM. *Stereoscopic atlas of macular diseases*. St Louis: CV Mosby, 1987:256.
- Szlyk JP, Fishman GA, Alexander KR, *et al*. Clinical subtypes of cone-rod dystrophy. *Arch Ophthalmol* 1993;111:781-8.
- Yagasaki K, Jacobson SG. Cone-rod dystrophy: phenotypic diversity by retinal function testing. *Arch Ophthalmol* 1989;107:701-8.
- Godel V, Regenbogen L. Functional evaluation in central retinitis pigmentosa. *Ophthalmologica* 1977;174:121-8.
- Niemeyer G, Demant E. Cone and rod ERGs in degenerations of central retina. *Graefes Arch Clin Exp Ophthalmol* 1983;220:201-8.
- Cremers FPM, van de Pol DRJ, van Driel M, *et al*. Autosomal recessive retinitis pigmentosa and cone-rod dystrophy caused by splice site mutations in the Stargardt's disease gene *ABCR*. *Hum Mol Genet* 1998;7:355-62.
- Martínez-Mir A, Paloma E, Allikmets R, *et al*. Retinitis pigmentosa caused by a homozygous mutation in the Stargardt disease gene *ABCR*. *Nat Genet* 1998;18:11-12.
- Farrar GJ, Kenna P, Jordan SA, *et al*. A three-base-pair deletion in the peripherin-RDS gene in one form of retinitis pigmentosa. *Nature* 1991;354:478-80.
- Nakazawa M, Kikawa E, Chida Y, *et al*. Autosomal dominant cone-rod dystrophy associated with mutations in codon 244 (Asn244His) and codon 184 (Tyr184Ser) of the peripherin/RDS gene. *Arch Ophthalmol* 1996;114:72-8.
- Wells J, Wroblewski J, Keen J, *et al*. Mutations in the human retinal degeneration slow (RDS) gene can cause either retinitis pigmentosa or macular dystrophy. *Nat Genet* 1993;3:213-18.
- Nichols BE, Sheffield VC, Vandenberg K, *et al*. Butterfly-shaped pigment dystrophy of the fovea caused by a point mutation in codon 167 of the RDS gene. *Nat Genet* 1993;3:202-7.
- Weleber RG, Carr RE, Murphey WH, *et al*. Phenotypic variation including retinitis pigmentosa, pattern dystrophy, and fundus flavimaculatus in a single family with a deletion of codon 153 and 154 of the peripherin/RDS gene. *Arch Ophthalmol* 1993;111:1531-42.
- Kim RY, Dollfus H, Keen TJ, *et al*. Autosomal dominant pattern dystrophy of the retina associated with a 4-base pair insertion at codon 140 in the peripherin/RDS gene. *Arch Ophthalmol* 1995;113:451-5.
- Hooyng CB, Heutink P, Testers L, *et al*. Autosomal dominant central areolar choroidal dystrophy caused by a mutation in codon 142 in the peripherin/RDS gene. *Am J Ophthalmol* 1996;121:623-9.



Phenotypic variations in a family with retinal dystrophy as result of different mutations in the *ABCR* gene

B Jeroen Klevering, Marc van Driel, Dorien J R van de Pol, et al.

Br J Ophthalmol 1999 83: 914-918

doi: 10.1136/bjo.83.8.914

Updated information and services can be found at:

<http://bjournal.bmj.com/content/83/8/914.full.html>

These include:

References

This article cites 20 articles, 7 of which can be accessed free at:

<http://bjournal.bmj.com/content/83/8/914.full.html#ref-list-1>

Article cited in:

<http://bjournal.bmj.com/content/83/8/914.full.html#related-urls>

Email alerting service

Receive free email alerts when new articles cite this article. Sign up in the box at the top right corner of the online article.

Topic Collections

Articles on similar topics can be found in the following collections

[Vision](#) (499 articles)

[Neurology](#) (1042 articles)

[Retina](#) (1217 articles)

[Eye \(globe\)](#) (543 articles)

Notes

To request permissions go to:

<http://group.bmj.com/group/rights-licensing/permissions>

To order reprints go to:

<http://journals.bmj.com/cgi/reprintform>

To subscribe to BMJ go to:

<http://group.bmj.com/subscribe/>