

Central corneal thickness determined with optical coherence tomography in various types of glaucoma

Martin Bechmann, Martin J Thiel, Bernhard Roesen, Stephanie Ullrich, Michael W Ulbig, Klaus Ludwig

Abstract

Aims—To evaluate central corneal thickness determined by optical coherence tomography (OCT) in various types of glaucoma, and its influence on intraocular pressure (IOP) measurement.

Methods—Central corneal thickness (CCT) was determined by using OCT in 167 subjects (167 eyes). 20 had primary open angle glaucoma (POAG), 42 had low tension glaucoma (LTG), 22 had ocular hypertension (OHT), 10 had primary angle closure glaucoma (AC), 24 had pseudoexfoliation glaucoma (PEX), 13 had pigmentary glaucoma (PIG), and 36 were normal.

Results—CCT was significantly higher in ocular hypertensive subjects (593 (SD 35) μm , $p < 0.0001$) than in the controls (530 (32) μm), whereas patients with LTG (482 (28) μm , $p < 0.0001$), PEX (493 (33) μm , $p < 0.0001$), and POAG (512 (30) μm , $p < 0.05$) showed significantly lower readings. There was no statistically significant difference between the controls and patients with PIG (510 (39) μm) and AC (539 (37) μm).

Conclusions—Because of thinner CCT in patients with LTG, PEX, and POAG this may result in underestimation of IOP, whereas thicker corneas may lead to an overestimation of IOP in subjects with OH. By determining CCT with OCT, a new and precise technique to measure CCT, this study emphasises the need for a combined measurement of IOP and CCT in order to obtain exact IOP readings.

(Br J Ophthalmol 2000;84:1233-1237)

The measurement of intraocular pressure (IOP) using the Goldmann applanation tonometer is an important factor in the diagnosis and follow up of glaucoma. It has been considered the gold standard for IOP measurements, as it is less likely to be biased by variables such as scleral rigidity, which can markedly affect Schiötz tonometer readings.¹ The impact of central corneal thickness (CCT) on applanation tonometry was first discussed by Goldmann.² He assumed that the resistance of the cornea to indentation was compensated by the surface tension of the tear film. This assumption is only true for a central corneal thickness of 520 μm , otherwise the accuracy of applanation tonometry can be considerably impaired.

Recent studies have demonstrated an impact of CCT in diagnosing glaucoma. Increased CCT measurements were found in patients with ocular hypertension, which can lead to falsely elevated IOP readings, and decreased CCT was found in patients with low tension glaucoma, resulting in falsely reduced IOP measurements.³⁻⁸ In line with these results it has been reported that refractive surgical procedures such as excimer photorefractive keratectomy (PRK) and laser in situ keratomileusis (LASIK) tend to lower IOP readings performed with applanation tonometry, and thinning of the central cornea is believed to be the cause.^{9, 10} Apart from one series of eight patients,³ all studies on CCT used ultrasound pachymetry,⁴⁻⁹ as the tool of measurement. In the present study we used optical coherence tomography (OCT) to measure central corneal thickness in different kinds of glaucoma. The capability of OCT to measure CCT has been demonstrated recently.¹¹ This technique allows a two dimensional mapping of corneal thickness by using non-contact, non-invasive, cross sectional visualisation of the human cornea (Fig 1).

Subjects and methods

In all, 131 eyes of 131 consecutive patients with various types of glaucoma and 36 healthy volunteers were examined at the glaucoma unit at the university eye hospital in Munich, Germany. All patients were given a thorough ophthalmic evaluation including best corrected visual acuity, slit lamp examination, stereoscopic disc evaluation using a 78 dioptre lens, Humphrey 30-2 statistic threshold perimetry, CCT measurement using OCT, Goldmann applanation tonometry, and gonioscopy. Eyes

Department of Ophthalmology, Ludwig-Maximilians-University, Munich, Germany
M Bechmann
M J Thiel
B Roesen
S Ullrich
M W Ulbig
K Ludwig

Correspondence to: Martin Bechmann, Universitäts Augenklinik, Mathildenstrasse 8, 80336 München, Germany
mbechman@ak-i.med.uni-muenchen.de

Accepted for publication 16 May 2000

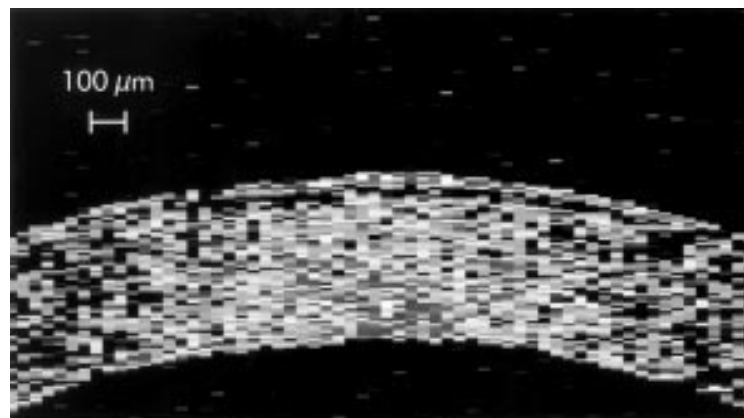


Figure 1 Cross sectional image of the human cornea gained by optical coherence tomography revealing epithelial layer and corneal stroma, allowing a two dimensional mapping of corneal thickness.

with a history of former incisional surgery, corneal disease, diabetic retinopathy, injury, recent contact lens wear, or steroid use were excluded.

The study included six subgroups with various types of glaucoma and a control group of normals. In the primary open angle glaucoma group (POAG) 20 patients were included. Inclusion criteria were: glaucomatous optic nerve damage, glaucomatous visual field defect, and IOP of 22 mm Hg or beyond and an open anterior chamber angle in gonioscopy.

Low tension glaucoma (LTG) was defined as glaucomatous optic nerve damage, glaucomatous visual field defect, intraocular pressure without treatment of 21 mm Hg or below (recorded on a 24 hour diurnal pressure curve as well as in the total history). Forty two patients were enrolled in this group.

IOP of 22 mm Hg or more in the presence of a normal optic nerve head, normal visual field, and normal gonioscopy was classified as presumed ocular hypertension. Twenty two patients were included in the ocular hypertensive group (OHT).

Angle closure glaucoma (AC) was defined as IOP of 22 mm Hg or more on no treatment, optic nerve head damage, glaucomatous visual field defect, and an open but narrow chamber angle ($<30^\circ$) in gonioscopy, or a history of angle closure glaucoma. Ten patients were included in this group.

In the pseudoexfoliative (PEX) glaucoma group 24 patients were enrolled on the basis of the following criteria: IOP above 21 mm Hg without treatment, glaucomatous visual field defect, optic nerve head damage, open anterior chamber angle in gonioscopy, and the observation of the characteristic whitish pseudoexfoliation material on the surface of the anterior lens capsule.

In the pigmentary glaucoma group 13 patients with the following signs were included: endothelial pigmentation (Krukenberg's spindle), iris transillumination defects, massive accumulation of pigment in the trabecular meshwork, elevated IOP readings (>21 mm Hg), and glaucomatous visual field defect and optic nerve head damage. Measurement of central corneal thickness was performed with a commercially available OCT device (Humphrey Instruments, Dublin, CA, USA), which can perform high resolution cross sectional imaging in ocular tissues. Optical coherence tomography is analogous to ultrasonography, except for the use of optical rather than acoustic waves. A superluminescence diode is used as low coherence light source, emitting light with 20–25 nm band width centred at 830 nm. The time delay of reflected light is determined using coherence interferometry. The emitted light is divided into a probe beam incident to the ocular tissue and a reference beam incident on a translating mirror. Both reflected beams are recombined and distance information of the probe beam can be detected.^{12–14} When performing the measurements, care was taken to ensure that the probe beam that passed through the cornea bisected the pupil horizontally (Fig 2A). An average scan length of 6 mm

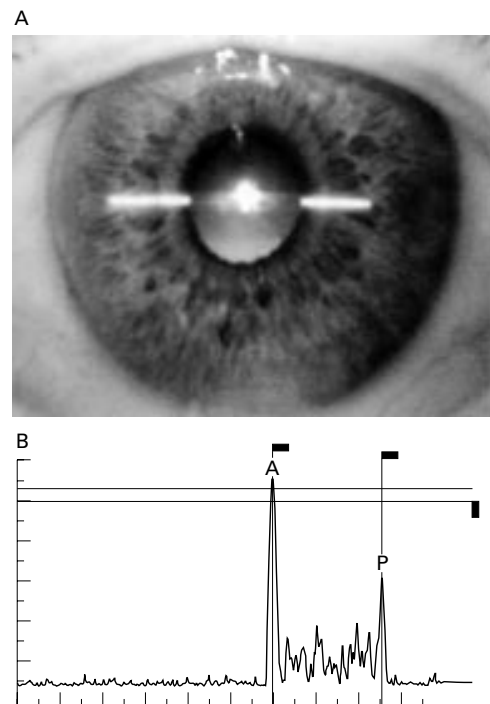


Figure 2 (A) The positioning of the OCT scan on the cornea is shown. The scan is bisecting the pupil, the scan length is 6 mm. (B) One dimensional scan profile display of the centre of the cornea. Cursors are placed on the peaks of reflectivity corresponding to the anterior (A) and posterior (P) corneal surface. The corneal thickness was calculated between the peaks of the reflectivity spikes.

was used. Measurements were performed in the centre of the horizontal section to ensure the precise central position of the cornea. The corneal thickness was determined with the scan profile display of the system. The software controlled cursors were placed manually at the peak of the reflectivity signal corresponding to the anterior and posterior corneal surface (Fig 2B). The corneal thickness was calculated between the peaks of the reflectivity spikes. Three consecutive measurements were recorded. As the OCT technique is a non-contact method, central corneal thickness measurements were performed before applanation tonometry and gonioscopy.

Statistical data analysis was performed with SPSS for windows, version 8.0 (SPSS Inc, Chicago, IL, USA) using *t* tests, Mann-Whitney U tests, χ^2 tests with correction for small sample sizes, and unifactorial variance analysis (ANOVA). *p* Values smaller than 0.05 were considered significant.

Informed consent was obtained from all participating patients and volunteers. Only one eye of each patient or normal subject was selected for statistical analysis to prevent bias. In bilaterally affected patients, a random choice was made between the right and left eyes.

Results

Complete subject characteristics are given in Table 1. There was no statistically significant difference among the seven subgroups for the examined eye, and, except the pigmentary glaucoma group with a significant myopic shift,

Table 1 Subject characteristics

	POAG	LTG	OHT	AC	PEX	PIG	NORM
No of subjects	20	42	22	10	24	13	36
Male	13	11	11	2	8	8	17
Female	7	31	11	8	16	5	19
p Value (χ^2)	0.24	<0.01	1	0.11	0.16	0.58	0.87
Mean age (SD) years	68.4 (9.6)	58.5 (13.1)	30.3 (12.5)	59.6 (13.3)	68.3 (7.5)	29.3 (14.1)	51.5 (19.7)
p Value (Mann-Whitney U)	0.01	0.14	<0.001	0.19	<0.001	<0.01	—
Mean (SD) refraction	-0.2 (2.64)	-0.34 (1.49)	-0.33 (1.52)	+0.8 (1.47)	+0.32 (1.98)	-2.75 (1.88)	-0.33 (2.01)
p Value (Mann-Whitney U)	0.59	0.27	0.583	0.11	0.1	<0.001	—

for refractive error. There were more female subjects in the low tension glaucoma group than in the control group ($p < 0.01$). In other groups, there were also differences for distribution of sex, although these differences did not reach statistical significance. Patients with primary open angle glaucoma (68.4 (SD 9.6) years) and pseudoexfoliation glaucoma (68.3 (7.5) years) were statistically significantly older than controls (51.5 (19.7) years), whereas patients with ocular hypertension (30.3 (12.5) years) and pigmentary glaucoma (29.6 (14.1) years) were significantly younger. For patients with low tension glaucoma (58.5 (13.1) years) and angle closure glaucoma (59.6 (13.3) years) no statistical significant difference from the control group could be found.

CCT results are given in Table 2. Mean CCT of the ocular hypertensive group was statistically significantly higher than in the primary open angle ($p < 0.0001$), or in the control group ($p < 0.0001$). The CCT (mean (SD)) of the OHT group was 593 (35 μm), whereas CCT of the POAG group was 512 (30) μm and of the normal controls 530 (32) μm . With a mean CCT of 482 (28) μm the readings of the low tension glaucoma group were statistically significantly lower compared with the primary open angle glaucoma group ($p < 0.001$), or the control group ($p < 0.0001$). There was also a statistically significant difference between the primary open angle group and the control group ($p < 0.05$), with a mean CCT of the POAG group being 18 μm lower compared with the control group.

In patients with pseudoexfoliation glaucoma mean CCT (493 (33) μm) was statistically significantly lower than in the POAG ($p < 0.05$) and the control group ($p < 0.0001$). There was no statistically significant difference between the pigmentary glaucoma (510 (39) μm) and the angle closure glaucoma group (539 (37) μm) and the POAG and the control group, respectively.

ANOVA analysis demonstrated a significant difference between all groups ($p < 0.001$).

Discussion

The influence of central corneal thickness on the accuracy of IOP measurements has long been recognised.³⁻¹⁵ Goldmann himself first

discussed the influence of CCT on applanation tonometry in his landmark article.² A tonometer tip is pressed against the cornea with a variable force until a circular area of 7.35 mm^2 is flattened, so that a force of 10 g applied to the tonometer tip is equal to an intraocular pressure of 10 mm Hg. The rigidity of the cornea opposes indentation, and he assumed that the surface tension force created by the tear film is drawing the tonometer tip to the opposite direction and will equal that rigid force.² As shown by Ehlers and associates,¹⁵ this assumption is only true for CCT of 520 μm , but as corneal thickness varies widely over the population (from 478 μm to 626 μm in this present study), this can cause an underestimation or overestimation of intraocular pressure readings. By comparing intraocular hydrostatic pressure measured in the anterior chamber (open system) with applanation tonometer readings in humans with different central corneal thickness a positive correlation between CCT and the error of applanation tonometry was found. For a true IOP of 20 mm Hg an underestimation of 5.2 mm Hg is given by applanation tonometry with a CCT of 450 μm , whereas a CCT of 590 μm leads to an overestimation of IOP of 4.7 mm Hg. Ehlers and coworkers interpolated that deviation from the influence of CCT of 520 μm yields an underestimation of IOP by applanation tonometry of approximately 0.7 mm Hg per 10 μm .¹⁵ Other studies confirmed the results published by Ehlers *et al*; however, the average correction found was considerably lower.¹⁰⁻¹⁸ Whitacre *et al* found a correction of 0.18 to 0.23 mm Hg per 10 μm in a direct cannulation study,¹⁶ and these results were very comparable with the Rotterdam Study, in which a regression of 0.19 mm Hg per 10 μm could be demonstrated.¹⁷ When comparing the influence of CCT in IOP measurements before and after LASIK, Emara *et al* found a correlation of 0.32 mm Hg per 10 μm versus 0.27 mm Hg per 10 μm .¹⁰

The importance of central corneal thickness in the discrimination between low tension glaucoma, primary open angle glaucoma, and ocular hypertension has been recognised by other investigators.³⁻⁸ In patients with low tension glaucoma, main central corneal thickness

Table 2 Central corneal thickness (CCT) in various patients and controls

	POAG	LTG	OHT	AC	PEX	PIG	NORM
Mean (SD) CCT (μm)	512 (30)	482 (28)	593 (35)	539 (37)	493 (33)	510 (39)	530 (32)
p Value (t test, compared with norm)	<0.05	<0.0001	<0.0001	0.52	<0.0001	0.10	—
p Value (t test, compared with POAG)	—	<0.001	<0.0001	0.06	<0.05	0.82	<0.05
Range CCT (μm)	457-563	423-563	532-653	488-551	449-557	463-583	478-626
95% CI (μm)	498-526	473-491	577-609	512-565	479-507	485-533	519-541

was markedly reduced, leading to an underestimation of IOP measurements. By contrast, in patients with ocular hypertension, higher central corneal thickness values were obtained, causing an overestimation of IOP readings gained with a standard Goldmann applanation tonometer. In conclusion, the true IOP in low tension glaucoma may not be as low as previously assumed, whereas the true IOP in ocular hypertension may be within the normal range, after taking central corneal thickness and its sources of error into account. In 1971 Hansen and Ehlers reported on eight patients with elevated IOP measurements refractive to antiglaucoma treatment. In all eight patients, the central corneal thickness was markedly increased.³ Johnson and coworkers published a case of an 17 year old girl who had IOP measurements between 30 and 40 mm Hg without glaucomatous optic disc changes.¹⁹ After showing no response to antiglaucomatous therapy, the anterior chamber was cannulated for direct IOP measurement. The IOP measured in this open system was found to be 11 mm Hg. The falsely elevated readings were caused by extremely thick corneas measuring 900 μm in both eyes without corneal oedema. In a series of 129 patients with low tension glaucoma, primary open angle glaucoma, and ocular hypertension Herndorn reported on a case with a history of laser trabeculoplasty referred for fistulating surgery for elevated IOP alone.⁵ The CCT of this patient was beyond 600 μm in both eyes, so the patient was advised to cancel surgery and discontinue glaucoma medications. A further study including 115 glaucoma patients recently found that after taking central corneal thickness into account 31% of the patients thought to have low tension glaucoma actually met the criteria for primary open angle glaucoma after correcting the applanation tonometer readings.⁴ In addition, 56% of the patients with the original diagnosis of ocular hypertension in fact had normal values of corrected intraocular pressure. This phenomenon could explain why only a minority of patients with OHT develop visual field loss.²⁰

Our findings are in line with these results. The CCT values measured by optical coherence tomography reported in this study are consistent with the findings of earlier studies using ultrasonic pachymetry. We have found that CCT is increased in eyes with ocular hypertension and decreased in eyes with low tension glaucoma when compared with normal eyes and eyes with primary open angle glaucoma. When comparing CCT of patients with primary open angle glaucoma with normal controls, CCT of the POAG group was significantly lower. Although this has been reported by other investigators,⁴⁻⁸ this difference did not reach statistical significance. The mean difference between the two groups was 18 μm , compared with approximately 9 μm described by other investigators.⁴⁻⁸ We also found a statistically significant reduction of CCT in pseudoexfoliation glaucoma, both when compared with POAG patients and with the control group. To the best of our knowledge, this has never been demonstrated before.

Reports in the literature regarding CCT in pseudoexfoliation glaucoma are controversial. A former study found higher CCT values for pseudoexfoliation glaucoma, although this difference did not reach statistical significance.²¹ Herndon and coworkers reported almost identical values of CCT for pseudoexfoliation glaucoma and POAG, with the PEX glaucoma patients being a subset of the POAG group.⁵ The reason for the significant reduction of CCT in PEX glaucoma in this study remains unclear and requires further investigation. In pigmentary glaucoma as well as in primary angle closure glaucoma no statistically significant difference could be found between the POAG group and the control group, respectively.

Except for one study using optical pachymetry,³ all reports cited in this article were performed with ultrasonic pachymetry,⁴⁻⁹ which is believed to be more reliable than optical pachymetry. Although ultrasonic pachymetry is a widely spread, reliable technique to measure corneal thickness, some problems remain. When performing an examination a probe tip has to be placed straight on the centre of the cornea. As corneal thickness increases peripherally, lateral displacement of the probe may cause elevated readings as well as shift of the probe out of the perpendicular. To avoid this problem, Bron and coworkers performed 10 measurements in the centre of the cornea, but selected only the three lowest readings.⁸ Other investigators did not measure in the exact centre of the cornea. The probe tip was placed 1.5 mm temporal to the cornea light reflex.⁶ Furthermore, it is difficult to control the patients gaze during repeated measurements, so that the placement of the probe is difficult to reproduce. Furthermore, the exact points of sound reflection in ultrasonic pachymetry are ill defined²² and the applanation force may disturb the anterior reflecting surface by pushing away the precorneal tear film²³ and by the thinning of the epithelium.²² None of these problems exists with the described OCT technique. OCT is a non-invasive, non-contact, monitor controlled method of excellent reproducibility, with the monitor based magnification allowing precise positioning of the probe beam in the centre of the cornea. Accordingly, OCT results cannot be biased by incorrect placement of a probe. Its possible application for CCT measurements has recently been demonstrated in a comparison between ultrasonic and OCT pachymetry in normal and oedematous human corneas.¹¹ By using the OCT technique to measure CCT in different kinds of glaucoma, we demonstrate the influence of corneal thickness on glaucoma, independently from the pachymetric technique previously used. We believe that OCT is an excellent method of measuring CCT, and it is much more independent from bias compared with ultrasonic pachymetry.

In conclusion, although the results of the present study are not entirely new, it seems important to confirm the results of previous studies by using OCT, a new, precise technique to measure CCT. As OCT allows an exact

measurement of CCT without the multiple sources of bias known from ultrasonic pachymetry, this study confirms the hypothesis that corneal thickness plays an important part in the diagnosis and understanding of various types of glaucoma. It emphasises the need for a combined measurement of IOP and CCT in order to be able to classify the different types of glaucoma.

The authors do not have any commercial or proprietary interest in any of the products mentioned in this article.

The authors thank Aljoscha S Neubauer for his statistical advice.

- 1 Drance SM. The coefficient of scleral rigidity in normal and glaucomatous eyes. *Arch Ophthalmol* 1960;**79**:668–74.
- 2 Goldmann H, Schmidt T. Über Applanationstonometrie. *Ophthalmologica* 1957;**134**:221–42.
- 3 Hansen KF, Ehlers N. Elevated tonometer readings caused by a thick cornea. *Acta Ophthalmol (Copenh)* 1971;**49**:775–8.
- 4 Copt RP, Thomas R, Mermoud A. Corneal thickness in ocular hypertension, primary open-angle glaucoma, and normal tension glaucoma. *Arch Ophthalmol* 1999;**117**:14–16.
- 5 Herndon LW, Choudhri SA, Cox T, et al. Central corneal thickness in normal, glaucomatous, and ocular hypertensive eyes. *Arch Ophthalmol* 1997;**115**:1137–41.
- 6 Argus WA. Ocular hypertension and central corneal thickness. *Ophthalmology* 1995;**102**: 1810–12.
- 7 Morad Y, Sharon E, Hefetz L, et al. Corneal thickness and curvature in normal-tension glaucoma. *Am J Ophthalmol* 1998;**125**:164–8.
- 8 Bron AM, Creuzot-Garcher C, Goudeau-Boutillon S, et al. Falsely elevated intraocular pressure due to increased central corneal thickness. *Graefes Arch Clin Exp Ophthalmol* 1999;**237**:220–4.
- 9 Abbasoglu OE, Bowman WR, Cavanagh DH, et al. Reliability of intraocular pressure measurements after myopic excimer photorefractive keratectomy. *Ophthalmology* 1998;**105**: 2193–6.
- 10 Emará B, Probst LE, Tingey DP, et al. Correlation of intraocular pressure and central corneal thickness in normal myopic eyes and after laser in situ keratomileusis. *J Cataract Refract Surg* 1998;**24**:1320–5.
- 11 Bechmann M, Thiel MJ, Neubauer AS, et al. Central corneal thickness measurements with optical coherence tomography and ultrasonic pachymetry [ARVO Abstract]. *Invest Ophthalmol Vis Sci* 1999;**40**:902 (Abstract no 4754).
- 12 Izatt JA, Hee MR, Swanson EA, et al. Micrometer-scale resolution imaging of the anterior eye in vivo with optical coherence tomography. *Arch Ophthalmol* 1994;**112**:1584–9.
- 13 Puliafito CA, Hee MR, Schuman JS, et al. *Optical coherence tomography of ocular diseases*. Thorofare, NJ: Slack Inc, 1996.
- 14 Huang D, Swanson EA, Lin CP, et al. Optical coherence tomography. *Science* 1991;**254**:1178–81.
- 15 Ehlers N, Bramsen T, Sperling S. Applanation tonometry and central corneal thickness. *Acta Ophthalmol (Copenh)* 1975;**53**:34–43.
- 16 Whitacre MM, Stein RA, Hassanein K. The effect of corneal thickness on applanation tonometry. *Am J Ophthalmol* 1993;**115**:592–6.
- 17 Wolfs RC, Klaver CC, Vingerling JR, et al. Distribution of central corneal thickness and its association with intraocular pressure: the Rotterdam study. *Am J Ophthalmol* 1997;**132**:767–72.
- 18 Brubaker RF. Tonometry and corneal thickness. *Arch Ophthalmol* 1999;**117**:104–5.
- 19 Johnson M, Kass MA, Moses RA, et al. Increased corneal thickness simulating elevated intraocular pressure. *Arch Ophthalmol* 1978;**96**:664–5.
- 20 Sommer A, Tielsch JM, Katz J, et al. Relationship between intraocular pressure and primary open angle glaucoma among white and black Americans. *Arch Ophthalmol* 1991;**109**:1090–5.
- 21 Ehlers N, Kruse Hansen F, Aasved H. Biometric correlations of corneal thickness. *Acta Ophthalmol (Copenh)* 1975;**53**:652–9.
- 22 Nissen J, Hjortdal J, Ehlers N, et al. A clinical comparison of optical and ultrasonic pachometry. *Acta Ophthalmol (Copenh)* 1991;**69**:659–63.
- 23 Ehlers N. The precorneal film. *Acta Ophthalmol (Copenh)* Suppl 81, 1965. 1 1



Central corneal thickness determined with optical coherence tomography in various types of glaucoma

Martin Bechmann, Martin J Thiel, Bernhard Roesen, et al.

Br J Ophthalmol 2000 84: 1233-1237

doi: 10.1136/bjo.84.11.1233

Updated information and services can be found at:

<http://bjo.bmj.com/content/84/11/1233.full.html>

These include:

References

This article cites 21 articles, 7 of which can be accessed free at:

<http://bjo.bmj.com/content/84/11/1233.full.html#ref-list-1>

Article cited in:

<http://bjo.bmj.com/content/84/11/1233.full.html#related-urls>

Email alerting service

Receive free email alerts when new articles cite this article. Sign up in the box at the top right corner of the online article.

Topic Collections

Articles on similar topics can be found in the following collections

[Angle](#) (788 articles)

[Glaucoma](#) (776 articles)

[Intraocular pressure](#) (786 articles)

Notes

To request permissions go to:

<http://group.bmj.com/group/rights-licensing/permissions>

To order reprints go to:

<http://journals.bmj.com/cgi/reprintform>

To subscribe to BMJ go to:

<http://group.bmj.com/subscribe/>