

Mooren's ulcer in China: a study of clinical characteristics and treatment

Jiaqi Chen, Hanping Xie, Zhen Wang, Bing Yang, Zuguo Liu, Longshan Chen, Xiangming Gong, Yuesheng Lin

Abstract

Aims—To investigate the clinical characteristics and compare the effects of several methods of treatment of Mooren's corneal ulcer.

Methods—550 consecutive cases of Mooren's corneal ulcer were analysed in patients, including age, sex, laterality of eye, ulcer location, perforative rate, cure rate of surgeries, recurrent rate, the effects of conjunctiva excision, lamellar keratoplasty (LKP), and LKP plus 1% cyclosporin A eye drops.

Results—The average age of onset was 48.4 years of age. The ratio of males to females was 1:0.74. 165 (30%) cases had the disease bilaterally, of which 52 (31.5%) occurred in the young age group and 113 (68.5%) in the old age group. Ulcers of 501 eyes (70.1%) were located at the limbus of the palpebral fissure. The perforation rate was 13.3%, with perforation of 41 eyes (43.2%) occurring in the young age group and 54 (56.8%) in the old age group. Post-operative recurrence rate was 25.6%. The cure rate of the first procedure of LKP plus 1% cyclosporin A eye drops was 73.7%. The final cure rate was 95.6%, and the postoperative preservation rate of the eye globe was 99.7%.

Conclusion—This primary study provided the clinical characteristics of patients with Mooren's corneal ulcer in China. LKP plus 1% cyclosporin A eye drops was an effective treatment.

(Br J Ophthalmol 2000;84:1244-1249)

Mooren's ulcer is a chronic, painful ulceration of the cornea with a steep, overhanging central and leading edge that starts in the periphery and may progress centrally or circumferentially to involve the entire cornea. It may be an autoimmune corneal disease¹⁻³ that is hard to manage and can cause blindness. It was reported that the incidence of Mooren's ulcer in China was 0.03%.⁴ Between 1960 and 1996, 550 consecutive cases of Mooren's ulcer were seen in our hospital. The clinical characteristics of the disease and the effects of LKP surgery were retrospectively analysed as follows.

Patients and methods

PATIENTS

Between 1960 and 1996, 550 consecutive cases (715 eyes) of Mooren's ulcer inpatients coming from different parts of China to our hospital were analysed. Of 550 patients, none of their relatives had Mooren's corneal ulcer. The geo-

Table 1 Geographical distribution of the patients

Place	Cases
South China	180
North China	19
North western China	73
South western China	105
Central China	137
North eastern China	36

Table 2 Occupation of the patients

Occupation	Cases
Peasants	328
Workers	69
Drivers	34
Fishermen	41
Teachers	31
Artists	28
Others	19

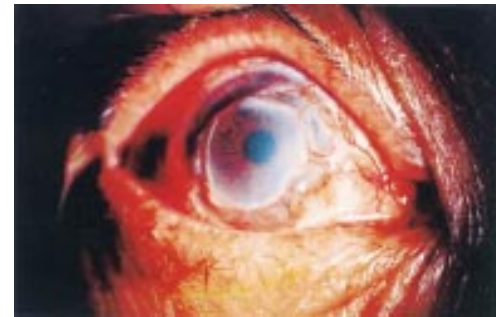

Figure 1 Mooren's ulcer (slit lamp microscopic photograph).

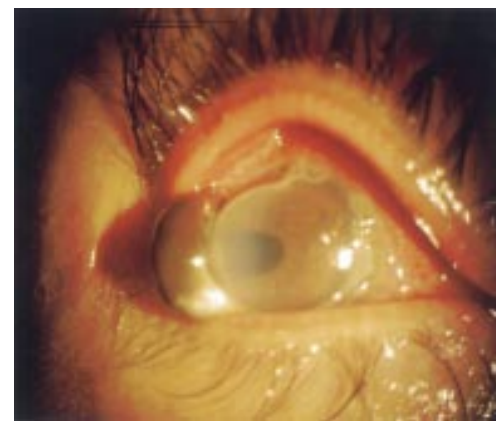

Figure 2 Mooren's ulcer with a limbal perforation and iris herniation (slit lamp microscopic photograph).

graphic distributions of the patients are listed in Table 1 and their occupations in Table 2.

METHODS

Diagnosis of Mooren's ulcer

The diagnosis was established by the typical ulcer morphology (Fig 1, Fig 2), detailed case

Zhongshan
Ophthalmic Center,
Sun Yat-sen University
of Medical Sciences,
Guangzhou, PR China

J Chen
H Xie
Z Wang
B Yang
Z Liu
L Chen
X Gong
Y Lin

Correspondence to:
Dr Jiaqi Chen, Zhongshan
Ophthalmic Center, Sun
Yat-sen University of
Medical Sciences,
Guangzhou 510060, PR
China
zoc@gzsums.edu.cn

Accepted for publication
8 May 2000

Table 3 The patients with topical and systemic histories

Topical history	No of cases	Systemic history	No of cases
Cornea foreign body	20	Wegener's granulomatosis	4*
Chemical burns of eye	13	Rheumatoid arthritis	2*
Cornea abrasion by tree leaves	7	Systemic lupus erythematosus	1*
Cornea penetrating wound	3		
Cataract extraction	7		
Pterygium extraction	6		
Penetrating keratoplasty	1		
Lagophthalmos caused by cut off facial nerve	2		

*Excluded from study.

history taking, physical examination, and comprehensive laboratory tests (erythrocyte suspension rate, antistreptolysin O, rheumatoid factor, and antinuclear antibody). Patients who had systemic diseases such as Wegener's granulomatosis, rheumatoid arthritis, and systemic lupus erythematosus, which could cause peripheral corneal ulcer, were excluded from

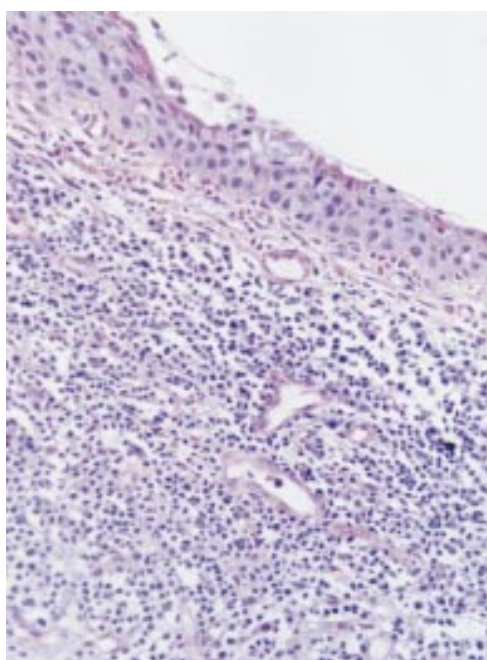


Figure 3 Lymphocyte infiltration and new blood vessels of the cornea near Mooren's ulcer (haematoxylin and eosin, original magnification $\times 20$).

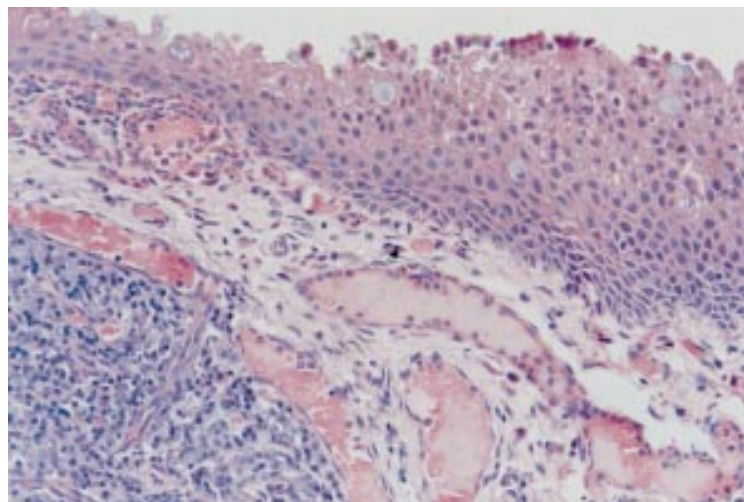


Figure 4 Lymphocyte infiltration, blood vessel dilatation, and oedema of the adjacent conjunctiva of Mooren's ulcer (haematoxylin and eosin, original magnification $\times 20$).

the study. Patients who had a history of ocular trauma or surgeries were included (see Table 3). After samples of corneal lesions of 330 cases were pathologically examined, no infectious keratitis was found (Fig 3, Fig 4).

Analysis of general condition of the patients—age, sex, and laterality of eye

The patients were divided into two groups according to age of onset; patients of 35 and younger were in the young age group, and those over 35 were in the old age group.

Analysis of the clinical characteristics and therapy effect of Mooren's ulcer

Analysis of the ulcer location, perforative rate, ocular complication, preoperative and postoperative vision, and recurrence of the ulcer was carried out. The effect of LKP was valued according to the three different stages of the surgery design. (1) From 1960 to 1975, the procedure was topical resection of the ulcer plus LKP. (2) From 1976 to 1989, the procedure was extensive excision of the ulcer and the corneal infiltrate, and episclera and conjunctiva adjacent to the ulcer plus LKP. In this stage, 2–3 mm sclera rim with the lamellar graft was used and fresh donor cornea was available for the patients. Crescent shape (Fig 5), doughnut shape (Fig 6), full lamellar graft (Fig 7), and double lamellar grafts (Fig 8) were adopted according to the shape of the corneal ulcer. Limbal sparing procedures were carried out for the crescent lamellar graft, but not for the doughnut and full lamellar grafts. (3) From 1990 to 1996, the procedure was LKP (same as that of (2)) plus topical 1% cyclosporin A eye drops, two to four times a day for 6 months

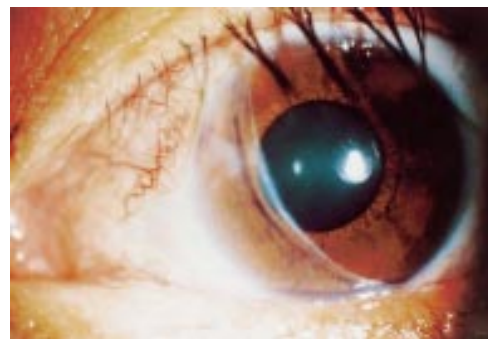


Figure 5 Crescent shaped lamellar keratoplasty (slit lamp microscopic photograph).

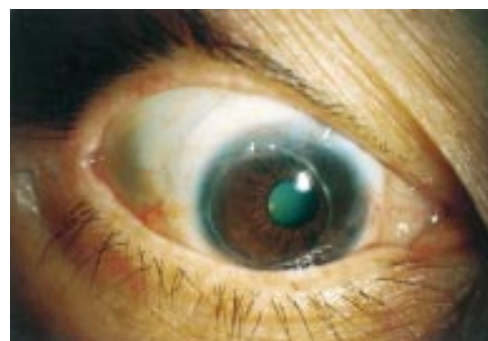


Figure 6 Doughnut shaped lamellar keratoplasty (slit lamp microscopic photograph).

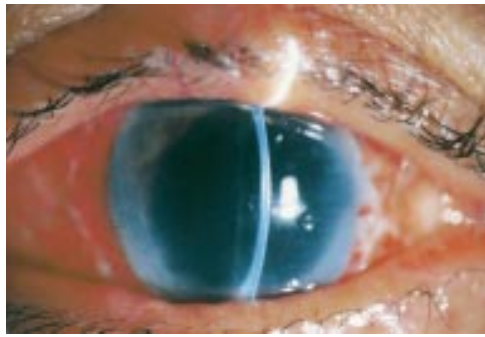


Figure 7 Full lamellar keratoplasty (slit lamp microscopic photograph).

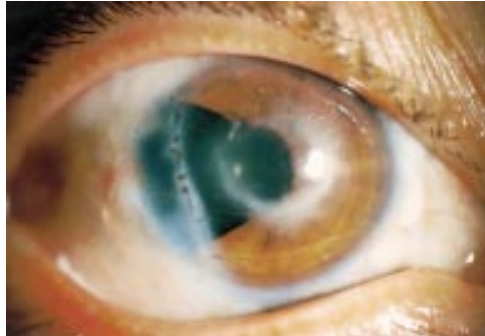


Figure 8 Double lamellar keratoplasty (slit lamp microscopic photograph, note inner graft with interrupted sutures).

to 1 year postoperatively. Cyclosporin A was provided by Sandoz Com, Switzerland. Cyclosporin A 1% eye drops were prepared by mixing cyclosporin A 30 ml (100 mg/ml) with olive oil solution, 270 ml, under sterile condition. The effect of conjunctival excision was analysed. Prednisolone 0.1% or dexamethasone 0.1% eye drops were given to all cases postoperatively for 3–6 months, two to four times a day. Antibiotic eye drops were given to all cases postoperatively for 2 weeks. Systemic immunosuppressants were not given to the patients for their Mooren's ulcer because they were expensive and also had some systemic side effects. We adopted topical immunosuppressants for the treatment of Mooren's ulcer.

Table 4 General conditions of the patients and clinical characteristics of Mooren's ulcer

	General conditions and clinical characteristics	Group	
		Young	Old
Total	550 cases	113 cases	437 cases
Age	Youngest 14 years Oldest 79 years Average age 48.4 years		
Sex	M: 318, F: 232 M: F=1:0.74		
Laterality of eye	RE: 218 cases LE: 167 cases Both eyes: 165 cases	52 cases	113 cases
Location of the ulcer	Affected half of limbus: 332 eyes Affected whole limbus: 150 eyes Involved interpalpebral limbus: 501 eyes		
Perforation	13.3% (95/715 eyes) 62 eyes in bilateral cases 33 eyes in unilateral cases	41 eyes	54 eyes
Location of perforation	Peripheral cornea: 32 eyes Limbal cornea: 48 eyes Central cornea: 15 eyes		
Complication	AU: 42 eyes Com cata: 14 eyes		

AU=anterior uveitis; Com cata=complicated cataract.

Follow up

The period of follow up was 1–7 years. When the patients were discharged they stayed in hotels near the hospital for 3–4 weeks so that they could conveniently come back to the hospital once a week for a check up. After that they went back to the central hospital (slit lamp microscope available) of their home town for eye examinations once a month during the first 6 months after the surgery. Six months later, they went to the central hospital every 3 months for eye examinations. Three monthly examinations lasted 1 year postoperatively.

Statistical method

The χ^2 test was used to compare the treatments, while Mann–Whitney test to compare the effect on preoperative and postoperative vision.

Results

The general conditions of the patients and clinical characteristics of the ulcer was summarised in Table 4. The symptoms, signs, and treatment of the patients in 10 year steps are summarised in Table 5.

AGE OF ONSET

Of 550 cases, the youngest patient was 14 years old while the oldest was 79 with the average age of the first onset being 48.4 years: 113 cases (20.6%) were in the young age group, 453 (79.4%) in the old age group.

SEX

Altogether 318 cases were male, and 232 cases female. The ratio of the male to the female was 1:0.74.

LATERALITY OF EYE

In all, 218 cases (39.6%) involved the right eye, 167 cases (30.4%) the left eye, and 165 cases (30%) both eyes. Fifty two cases (31.5%) of the bilateral disease occurred in the young age group, with 113 (68.5%) in the old age group.

LOCATION OF THE ULCER

Among the ulcerative eyes, in 332 eyes (45%) the corneal lesion covered half the limbus and in 150 ulcerative eyes (21%) it extended to the entire limbus. In 501 eyes the lesion (70.1%) involved either the medial or the lateral quadrant of the limbus. The degree of ulceration reached approximately from one third to one half of the corneal stroma.

PERFORATION RATE

Out of 715 eyes there were 95 eye perforations, of which 62 eyes (65.3%) were bilateral and 33 eyes (34.7%) unilateral; 41 perforated eyes (43.2%) occurred in the young age group, and 54 perforated eyes (56.8%) in the old age group.

LOCATION OF PERFORATION

Perforations occurred in the limbal cornea (48 eyes), in the peripheral cornea (32 eyes), and in the central cornea (15 eyes).

Table 5 Symptoms, signs, and treatment effect on patients in 10 year steps

Age (years)	Precipitating cause (No of eyes)	Laterality (No of cases)		Perforation (No of eyes)		Effect of therapy (%)			
		Bi	Uni			First procedure	Second procedure	Third and more procedures	Final
14-24	Cornea foreign body 5, chemical burns of eye 2, corneal abrasion 2, corneal penetrating wound 3	23	42	17		61.3	11.5	8.7	81.5
25-34	Cornea foreign body 9, chemical burns of eye 4, corneal abrasion 3	29	77	24		65.1	8.9	5.3	79.3
35-44	Cornea foreign body 6, chemical burns of eye 7, lagophthalmos 2, corneal abrasion 2	37	95	19		72.8	9.3	3.6	85.7
45-54	Cataract extraction 3, pterygium extraction 4	33	82	16		69.4	13.7	4.1	87.2
55-64	Cataract extraction 2, pterygium extraction 2, penetrating keratoplasty 1	25	61	10		58.5	12.1	6.7	77.3
65-74	Cataract extraction 2	11	16	7		74.6	10.8	4.4	89.8
75-79	None	7	12	2		67.5	9.6	5.5	82.6

Bi = bilateral; Uni = unilateral.

COMPLICATIONS

Of the 620 unperforated eyes, 42 eyes (6.8%) had mild anterior uveitis with fine dusty keratic precipitate and local posterior synechiae of the iris; 14 eyes (2.3%) had complicated cataract.

TREATMENT EFFECT

In all, 116 ulcerative eyes were treated with conjunctiva excision and corneal ulcer resection. Among the 116 eyes, 78 eyes were involved in one to two quadrants of the limbus, with cure rate of the first procedure being 51.3% (40 eyes); 38 eyes were involved in three to four quadrants of the limbus, with cure rate of the first procedure being 36.8 (14 eyes). Of the uncured 62 eyes, 23 eyes were given the second procedure, with four eyes being healed. The other 58 eyes were treated with LKP. The treatment effects of the three different stages are listed in Table 6.

Two eyes were enucleated because of endophthalmitis and secondary glaucoma due to the perforation (in the 1960s). The anatomical structure of 713 ulcerative eyes was preserved. The preservation rate was 99.7%. Nine cases did not undergo any surgery because of intestinal tract bleeding and other systemic diseases.

Table 6 The treatment effect of the three different stages

Time	Surgery design	No of eyes	Cure rate (%)			
			First procedure	Second procedure	Third and more procedure	Final
1960-75	(1) Topical resection of corneal ulcer + LKP	235	51.1	12.8	8.5	72.4*
1976-89	(2) Topical resection of corneal ulcer, episclera, and conjunctiva adjacent to the ulcer, and plus LKP	296	69.3	15.9	4.4	89.6*
1990-6	(3) Same as the surgery design of (2) and plus topical 1% cyclosporin A	114	73.7	15.8	6.1	95.6*

* χ^2 test, $p < 0.05$.

Table 7 Comparison of preoperative and postoperative visual acuity (number of eyes)

Visual acuity	<0.02	0.02-0.09	0.1-0.2	0.3-0.4	0.5-0.6	0.7-0.9	1.0-1.5
Preoperative	148	155	145	123	71	37	22*
Postoperative	91	105	161	147	98	61	38*

*Mann-Whitney test, $p < 0.01$.

Visual acuity

Visual acuity was, to some extent, improved postoperatively. The comparison of preoperative and postoperative visual acuity is listed in Table 7.

ULCER RECURRENCE

Of 550 cases, 141 cases had one or several postoperative ulcer recurrences and the postoperative recurrence rate was 25.6%; 99 cases (70.2%) had the first recurrence within 2-6 months after the surgery. The period of the multiple recurrence varied from 2 weeks to 15 years postoperatively. The location of the first recurrence was found to be the same as that before operation, and could also be found at the interface of the donor graft and the lamellar bed. The location of the multiple recurrence varied from the original ulcer location to that of normal cornea. From 1991 to 1996, one female patient experienced 10 recurrences, including two perforations. After 10 LKP surgeries, the anatomical structure of her eyes was preserved with visual acuity of the right eye being 0.05, and the left eye being 0.02. Of 141 cases of recurrence, 89 (63.1%) were bilateral and 52 (36.9%) unilateral; 46 (32.6%) of recur-

Table 8 Recurrence of Mooren's ulcer

Recurrence		Group	
		Young	Old
Recurrence rate	25.6% (141/550 cases)	46	95
Time of recurrence	FR 2–6 months		
After surgery	MR 2 weeks–15 years		
Location of recurrence	FR At the same location as before the operation or at the interface of the donor graft and the lamellar bed		
	MR At the same location of the ulcer or normal area of the cornea		
Laterality	89 recurrent cases of bilateral cases, 52 recurrent cases of unilateral cases		

FR = first recurrence; MR = multiple recurrence.

rence occurred in the young age group, and 95 (67.4%) in the old age group. Recurrence of the ulcer is summarised in Table 8.

Discussion

CLINICAL CHARACTERISTICS OF MOOREN'S ULCER Wood and Kaufman⁵ classified the disease into two groups according to the age of onset, clinical characteristics, and prognosis of nine cases. Type I was benign and usually unilateral with mild to moderate symptoms. This type was believed to occur in old people (over 35 years) and usually responded well to medical and surgical treatments. In contrast, the second type was more likely to be bilateral with relatively more pain and generally a poor response to the therapy. The second type was believed to occur in young patients (younger than 35), and became known as malignant Mooren's ulcer. Schanzlin⁶ reported that a bilaterality rate of 25% of cases of the benign type was found mostly in patients over the age of 35 and no difference of races was observed. The bilaterality rate of 75% of cases of the malignant type was discovered mostly in black patients younger than 35. Watson⁷ divided the disease into three types based on the clinical presentation and the low dose anterior segment fluorescein findings—that is, unilateral Mooren's ulcer, bilateral aggressive Mooren's ulcer, and bilateral indolent Mooren's ulcer. Lewallen and Courtright⁸ reviewed the literature on 287 cases of Mooren's ulcer and found that men were 1.6 times more likely to have Mooren's ulcer than women, and that 43% of older patients had bilateral disease, whereas bilateral disease was present in only one third of patients younger than 35. They pointed out that the data available did not support the clinical types of Mooren's ulcer classified by Wood and Kaufman. The clinical characteristics of Mooren's ulcer, the ratio of men to women patients, the liable age, laterality of eye, and the prognosis need to be further researched.

We retrospectively analysed 550 consecutive cases of Mooren's ulcer and found that the average age of the first attack was 48.4; 437 cases (79.5%) were over the age of 35, indicating that Mooren's ulcer was predominantly a disease of adults, and that the ratio of men to women was 1:0.74—that is, men were 1.35 times more likely to have the disease than women, which is similar to what was reported abroad—1.6 times.⁸ The right eye was involved

in 39.6% of cases; the left eye was involved in 30.4% of cases, and the other 30% of cases had the disease bilaterally. Five hundred and one eyes (70.1%) had ulcers in the location of the limbus of palpebral fissure. The reason was not clear and probably related to the exposure of the limbus of palpebral fissure and fewer limbal stem cells in that position. Perforative rate of the disease was 13.3%, which was lower than the 36% reported by Keitzman.⁹ Ocular complications were mild anterior uveitis and complicated cataract. Taking initial recurrence as a standard, the postoperative recurrence rate was 25.6%. Initial recurrence occurred mostly within 6 months after the surgery. The ulcerative limbus of preoperation and the interface of the donor graft and the lamellar bed were the recurring positions. The period of multiple recurrence varied from 2 weeks to several years postoperatively. The location of the multiple recurrence was vastly different. The immunological mechanisms of the initial and multiple recurrence may be different and need to be studied. The data, to some extent, reflect the clinical characteristics of Mooren's ulcer in China as they were collected from patients of different provinces of the country.

Mooren's ulcer has occurred after corneal trauma and eye surgery.¹⁰ Zegans *et al* reported that the patients who had a history of corneal trauma, surgery, or infection made up 68% (13/21) of patients with Mooren's ulcer.¹¹ Lewallen and Courtright reported that the patients who had a history of corneal trauma or surgery accounted for 29.6% (85/287).⁸ Our results showed that 10.7% of the patients had ocular trauma or surgery before they got Mooren's ulcer. It is not clear yet why there is such a great difference in reported ratios of patients with Mooren's ulcer who had a history of corneal trauma or surgery. The difference in the effect of ocular trauma on Mooren's ulcer is not clear either. From the above, we consider that the relation between ocular trauma and Mooren's ulcer needs to be further studied.

Based on the facts of bilaterality, perforation, and recurrence, our results do not support the classification proposed by Wood *et al*⁵—that is, the old age group was benign, and the young age group was malignant. Our results show that in both young and old age groups the perforation rate and recurrence rate of the bilateral cases are much higher than those of unilateral ones. We believe that the bilateral disease is the malignant type of Mooren's ulcer.

EVALUATION OF EFFECT OF LKP SURGERY OF MOOREN'S ULCER AND FACTORS INFLUENCING CURE RATE OF THE DISEASE

The main approaches to the management of Mooren's ulcer include conjunctival excision, keratoepithelioplasty,¹² of which, fresh donor corneal lenticules are placed near the distal side of the ulcerated area and securely sutured on the bare sclera, LKP, and immunosuppressive treatment. Among them, LKP is widely used at present.

LKP surgery of Mooren's ulcer removes antigenic targets of the cornea, prevents immunological reactions, reconstructs the ana-

tomical structure, prevents it from perforating, and improves vision. The results indicate that the final healing rate of Mooren's ulcer treated with resection of the corneal lesion and adjacent conjunctiva combined with LKP surgery is 89.6%, and the final healing rate of LKP plus topical 1% cyclosporin A is 95.6%. The anatomical structure of cornea of 99.7% of the ulcerative eyes is preserved. We consider LKP surgery to be the most effective treatment of Mooren's ulcer at present.

The principle of LKP surgery of Mooren's ulcer is to remove necrotic ulcerative cornea thoroughly and to reconstruct anatomical structure of the cornea. The designs for surgery depend on the shape of the ulcer and infiltrate of the cornea. If the ulcer is smaller than a half circle of the limbus and the central area of the cornea, 7–8 mm in diameter, is not involved, crescent shaped lamellar graft is used so as to prevent the cornea from perforation. If the ulcer is larger than two thirds of a circle of the limbus, and the central 7–8 mm of the cornea is intact, then a doughnut shaped lamellar graft is used to maintain the refractive power of the central cornea. If the central cornea is involved, a full lamellar graft is used to maintain useful visual acuity. Double lamellar grafts are used for perforation of the peripheral cornea—that is, a fresh thin inner graft with corneal endothelial cells is used to repair the perforation, on the upper part of the inner graft is another lamellar graft whose shape depends on the shape of the ulcer. The anterior chamber is reformed for fresh perforation in the course of the operation. If the perforation lasts for 5–7 days, the herniated iris should be cut off to prevent implanted epithelial cyst. If the entire cornea is involved and with its central perforation, a full thickness graft and a penetrating keratoplasty are used to reconstruct the anterior segment of the eye. In all the four types of LKP surgery cornea lamellar graft with 2–3 mm sclera rim should be used and fresh donor graft should also be used for transplantation of allograft corneal limbal stem cells to the recipient to reconstruct the corneal surface and the “base” of the stem cells¹³ (which is beneficial to the reduction of ulcer recurrence due to inadequate epithelialisation). We used fresh donor cornea graft mostly for doughnut and full lamellar keratoplasties, and epithelial failure as a result of stem cell failure was hardly observed.

Since 1960 we have experienced three stages of design.^{14–17} The treatment effect, healing rate of the first procedure, and the final healing rate (more than one procedure) are significantly improved. The improvement in the treatment has something to do with the following: (1) thorough removal of corneal ulcer and infiltrate; (2) excision of conjunctiva and episclera adjacent to the corneal ulcer combined with LKP surgery; (3) application of fresh lamellar graft with sclera rim (having the limbal stem cells); (4) a good host-graft junction; and (5) topical use of steroids and 1% cyclosporin A postoperatively. LKP surgery plus 1% topical cyclosporin A is an effective treatment of Mooren's ulcer when these five principles are practised. Even if one procedure fails, regrafting can give patients the chance of ulcer healing and maintaining visual acuity.

- 1 Lopez, JS, Price FW Jr, Whitcup SM, *et al.* Immunohistochemistry of Terrien's and Mooren's corneal degeneration. *Arch Ophthalmol* 1991;109:988–92.
- 2 Brown SI, Mondino BJ, Rabin BS. Autoimmune phenomenon in Mooren's ulcer. *Am J Ophthalmol* 1976;82:835–40.
- 3 Gottsch JD, Liu SH, Minkovitz JB, *et al.* Autoimmunity to a cornea-associated stromal antigen in patients with Mooren's ulcer. *Invest Ophthalmol Vis Sci* 1995;36:1541–7.
- 4 Zulian Zhou. Mooren's ulcer—analysis of 30 cases. *Chin J Ophthalmol* 1965;12:423–4.
- 5 Wood T, Kaufman H. Mooren's ulcer. *Am J Ophthalmol* 1971;71:417–22.
- 6 Schanzlin DJ. Mooren's ulceration. In: Smolin G, Thoft RA, eds. *The cornea*. Boston: Little, Brown, 1987:323.
- 7 Watson PG. Management of Mooren's ulceration. *Eye* 1997;11:349–56.
- 8 Lewallen S, Courtright P. Problems with current concepts of the epidemiology of Mooren's corneal ulcer. *Am Ophthalmol* 1990;22:52–5.
- 9 Keitzman B. Mooren's ulcer in Nigeria. *Am J Ophthalmol* 1968;65:679–85.
- 10 Mondino BJ, Hofbauer JD, Foos RY. Mooren's ulcer after penceatrating keratoplasty. *Am J Ophthalmol* 1987;103:53–6.
- 11 Zegans ME, Srinivasan M, Mchugh T, *et al.* Mooren's ulcer in south India: serology and clinical risk factors. *Am J Ophthalmol* 1999;128:205–10.
- 12 Kinoshita S, Ohashi Y, Ohji M, *et al.* Long-term results of keratoepithelioplasty in Mooren's ulcer. *Ophthalmology* 1991;98:438–45.
- 13 Zioeske JD, Bukusoglu G, Yankauckas MA. Characterization of potential marker of corneal epithelial stem cells. *Invest Ophthalmol Vis Sci* 1992;33:143–52.
- 14 Nianzu Du, Yuzhen Huang. Treatment of Mooren's ulcer with lamellar keratoplasty. *Chin J Ophthalmol* 1964;11:275–7.
- 15 Nianzu Du, Jiaqi Chen, Xiangming Gong, *et al.* Treatment of Mooren's ulcer with lamellar keratoplasty. *Chin J Ophthalmol* 1979;15:290–4.
- 16 Nianzu Du, Jiaqi Chen, Xiangming Gong, *et al.* Treatment of Mooren's ulcer with lamellar keratoplasty. *Academic Journal of Sun Yat-sen University of Medical Sciences* 1980;1:107–9.
- 17 Zeng wang, Jiaqi Chen, Longshan Chen, *et al.* Treatment of Mooren's ulcer with lamellar keratoplasty and plus topical cyclosporin A eye drop. *Chinese Journal of Practical Ophthalmology* 1996;14:283–5.



Mooren's ulcer in China: a study of clinical characteristics and treatment

Jiaqi Chen, Hanping Xie, Zhen Wang, et al.

Br J Ophthalmol 2000 84: 1244-1249

doi: 10.1136/bjo.84.11.1244

Updated information and services can be found at:

<http://bjo.bmj.com/content/84/11/1244.full.html>

References

These include:

This article cites 14 articles, 3 of which can be accessed free at:

<http://bjo.bmj.com/content/84/11/1244.full.html#ref-list-1>

Article cited in:

<http://bjo.bmj.com/content/84/11/1244.full.html#related-urls>

Email alerting service

Receive free email alerts when new articles cite this article. Sign up in the box at the top right corner of the online article.

Topic Collections

Articles on similar topics can be found in the following collections

[Cornea](#) (383 articles)

[Eye \(globe\)](#) (543 articles)

[Ocular surface](#) (455 articles)

[Ophthalmologic surgical procedures](#) (971 articles)

Notes

To request permissions go to:

<http://group.bmj.com/group/rights-licensing/permissions>

To order reprints go to:

<http://journals.bmj.com/cgi/reprintform>

To subscribe to BMJ go to:

<http://group.bmj.com/subscribe/>