

Congenital progressive polymorphic cataract caused by a mutation in the major intrinsic protein of the lens, MIP (AQP0)

Peter Francis, Vanita Berry, Shomi Bhattacharya, Anthony Moore

Institute of Ophthalmology, London, UK
P Francis
V Berry
S Bhattacharya

Moorfields Eye Hospital, London, UK
P Francis
A Moore

Addenbrooke's Hospital, Cambridge, UK
A Moore

Correspondence to:
Mr A T Moore, Moorfields Eye Hospital, City Road, London EC1V 2PD, UK
atm22@hermes.cam.ac.uk

Accepted for publication 22 June 2000

Table 1 (a) Mapped loci for human autosomal dominant congenital cataract, (b) identified human congenital cataract mutations

(a) Phenotype	Locus	Inheritance	Reference
Volkman (pulverulent)	1p36	AD	20
Posterior polar	1p36	AD	12
Nuclear	12q12-14.1	AD	21
Anterior polar	14q24	Translocation	22
Unknown	16p13.3	Translocation	23
Märner	16q22.1	AD	24
Posterior polar	16q22.1	AD	24
Anterior polar	17p13	AD	25
Zonular sutural (lamellar)	17q11-12	AD	26
Cerulean	17q24	AD	27
Unknown	I-blood group locus	AR	28
Sutural (lamellar)	Xpter-Xqter	XR	29 30 31

(b) Locus	Gene	Protein	Mutation	Reference
1q21-q25	<i>GJA8</i>	Connexin 50	missense	7
2q33-q35	<i>CRYGD</i>	γ D crystallin	missense	32
2q33-q35	<i>CRYGC</i>	γ C crystallin	missense	33
10q24-25	<i>PITX3</i>	Pitx3	missense	34
12q14	<i>MIP</i>	MIP/AQP0	missense	10
13q11-q13	<i>CX46</i>	Connexin 46	missense	9
17q11.1-q12	<i>CRYBA1</i>	BA1, crystallin	splice site	26
21q22.3	<i>CRYAA</i>	α crystallin	missense	5
22q11.2	<i>CRYBB2</i>	β crystallin	chain termination	35
22q11.2	<i>CRYBB2</i>	β crystallin	missense	36

Abstract

Background—Congenital cataract, when inherited as an isolated abnormality, is phenotypically and genetically heterogeneous. Although there is no agreed nomenclature for the patterns of cataract observed, a recent study identified eight readily identifiable phenotypes.

Methods—The Moorfields Eye Hospital genetic eye clinic database was used to identify a four generation family with isolated autosomal dominant congenital cataracts. All individuals (affected and unaffected) underwent a full ophthalmic assessment.

Results—The results of the molecular linkage study identifying a missense mutation in the gene encoding the major intrinsic protein of the lens (MIP) have been published elsewhere. Affected individuals had bilateral discrete progressive punctate lens opacities limited to mid and peripheral lamellae with additional asymmetric polar opacification. One young female had predominantly cortical cataract and another had serpiginous nuclear opacities.

Conclusions—This phenotype has not been recorded in human families before and has been termed polymorphic. The pattern of opacification appears to reflect the distribution of MIP in the lens.

Furthermore, this is the first clear evidence of allelic heterogeneity in this condition following the identification of a family with lamellar cataracts who have a different mutation within the MIP gene.

(Br J Ophthalmol 2000;84:1376-1379)

Inherited cataract is the most common treatable cause of visual loss in children.¹ When it occurs in isolation, it is most often transmitted as an autosomal dominant trait.² Many different phenotypes are recognised but as yet no agreed classification exists. A recent study of families with isolated non-syndromic human inherited cataract³ recorded eight clearly distinguishable phenotypes— anterior polar, posterior polar, nuclear, lamellar, blue dot, coralliform, cortical, and pulverulent.

Inherited cataract is also genetically heterogeneous. Independent chromosomal loci have been mapped to 1p36, 1q21-25, 2q33-35, 13q, 16q22.1, 17p, 17q11-12, 17q24, 21q, and 22q. A recessive form has been linked with the I-blood group locus and characterisation of balanced chromosomal translocations has identified further loci on 2p22.3, 14q24, and Xp (Table 1a). Underlying mutations are now known in the crystallin genes at the loci on 2q,⁴ 21q,⁵ and 22q,⁶ the connexin genes on 1q⁷ and 13q⁹ and the developmental regulator gene *PITX3* on 10q (Table 1b).

We have identified a family with autosomal dominant progressive lamellar opacification of the lens associated with anterior and posterior polar cataract. This “polymorphic” phenotype has not previously been recorded in human pedigrees. We have genetically linked this family to the long arm of chromosome 12, to the locus 12q14, and have shown that in this and another genetically unrelated family, a mutation in the *MIP* gene underlies cataractogenesis.¹⁰ In this paper, we describe the clinical spectrum of the disease.

Spontaneously occurring dominant mutations in major intrinsic protein (MIP) have already been shown to produce heritable cataract traits in mice. The *Cat^{fr}* mouse has a splice site mutation that leads to cataract and wrinkling of the capsule. The *lop* mouse (*lens opacity*) has a missense mutation which leads to mistargeting of the protein and accumulation in the endoplasmic reticulum of the lens fibre cell.¹¹ The underlying mechanisms by which each results in cataractogenesis remain to be elucidated.

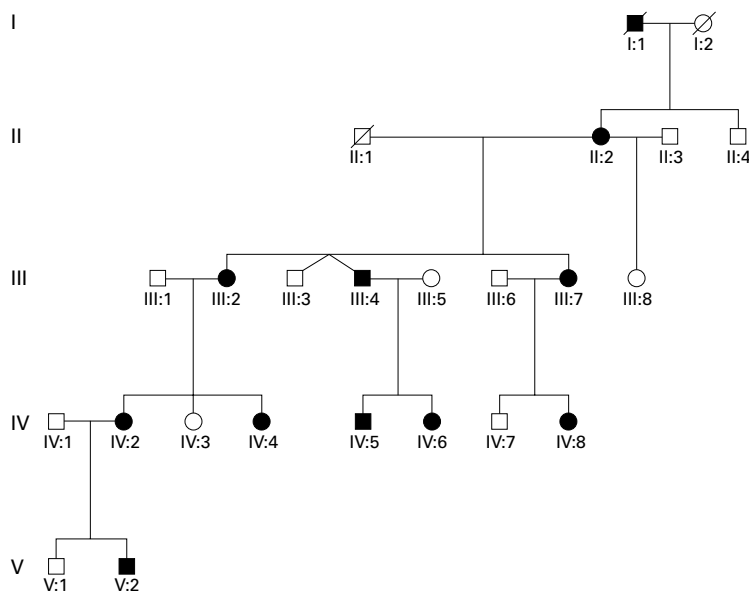


Figure 1 Abridged pedigree of family with polymorphic congenital cataract.

Patients and methods

The genetic database at Moorfields Eye Hospital provided details of the proband, from whom the pedigree was constructed and the family was invited to participate in the study. Ten affected and six unaffected members (Fig 1) underwent ophthalmological examination. Peripheral blood samples were taken for DNA extraction and the linkage study undertaken as previously described.¹² Ethics committee approval was obtained for this study and patients gave their written consent to participate.

Results

The results of the molecular linkage study mapping the polymorphic cataract in this family to chromosome 12q14 and the subsequent detection of a mutation in the *MIP* gene have already been published.¹⁰

In the family, autosomal dominant inheritance was supported by the presence of affected male and female individuals in each generation and male to male transmission. The disease showed complete penetrance and highly variable expressivity.

Opacification of the lens was bilateral in all affected cases and consisted of discrete progressive punctate lens opacities limited to mid and peripheral lamellae. In addition, some of those affected had asymmetric anterior and posterior polar opacification. One young female had predominantly cortical cataract and another had serpinginous nuclear opacities. The clinical spectrum of the phenotype is shown in Figure 2. Hospital records indicated that the opacity was present at birth or developed within the first year of life. Visual acuity in the unoperated eyes of those affected ranged from 6/6 to 6/24 (Table 2). No affected individuals have developed strabismus or retinal detachment. There was no evidence of other ocular or systemic abnormalities.

Three individuals had undergone bilateral lensectomy in childhood, aged 1 month (left and right best corrected visual acuities 6/9,

6/12 respectively), 4 months (6/6, 6/9; subsequently developed well controlled aphakic glaucoma), and 15 years (HM, 6/9). Right extracapsular cataract extraction had been performed on two patients in adulthood (aged 55 and 72 years, each achieving best corrected visual acuity of 6/6).

Discussion

In this paper, we document a new inherited cataract phenotype resulting from a mutation in the gene that encodes the major intrinsic protein of the lens (MIP), the most abundant membrane protein in the mature lens fibre cell.

A number of roles have been suggested for MIP but it is now known to be one of a number of sequence related proteins known as aquaporins, which form channels to selectively transport water molecules across cell membranes.¹³ The missense mutation we have described substitutes an amino acid thought critical for this specialised function.

Ten mammalian aquaporins are now known.¹⁴ Often more than one is expressed in a single tissue. The proteins are suggested to have important functions in the eye, being involved in aqueous humour dynamics and lacrimation. Aquaporins also have significant roles in renal water reabsorption, cerebrospinal fluid secretion, and the generation of pulmonary secretions have been suggested.¹⁵

To date, only aquaporin-2 has been implicated in human disease. It is found abundantly in kidney collecting duct epithelium, where its function is regulated by ADH (antidiuretic hormone). Several missense mutations (recessive and dominant) have been identified that result in the development of nephrogenic diabetes insipidus.¹⁶ Interestingly, polymorphisms of aquaporin-1 (present on the red blood cell membrane, the Colton blood group antigens) have been documented that produce a non-functional protein (the null phenotype) but whose effects are subclinical.¹⁷ Such evidence has suggested that other mechanisms are able to compensate for aquaporin dysfunction. Our evidence that mutations in aquaporin-0 underlie cataract formation confirm the critical role of these proteins in certain tissues.

The phenotype of the cataract in this family has not previously been observed as an inherited trait¹⁸ and to reflect the variable appearance between eyes and among individuals has been termed "polymorphic".

The discrete punctate opacities are similar to the pulverulent phenotype, which is characterised by fine dust-like opacification. However, the opacities in this pedigree are larger and, critically, their position within the lens is consistent contrasting markedly with the variable distribution of pulverulent opacities. Polar opacification is also not a feature of the pulverulent phenotype.

The phenotype observed in our family is also clearly distinct from the incompletely penetrant non-progressive polymorphic cataract mapped to chromosome 2q33-35 by Rogaeve *et al*⁹ in the Turkmen populations of the former

Soviet Union. In this cataract opacities resembled lumps of grapes or cotton anywhere from the fetal nucleus to the equator. Polar opacification was also not observed.

Although the mature lens fibre cell is metabolically inert, aquaporin water transport would be expected to continue as it is not energy dependent. Thus, the progressive na-

ture of the cataract might well be explained as the cumulative effect of cellular dysfunction over time. The presence of polar cataract is less easily explained but parallels the distribution observed in the *Cat^{Pr}* mouse.

Screening our panel of other families with isolated inherited congenital cataract identified a second pedigree with a different dominant

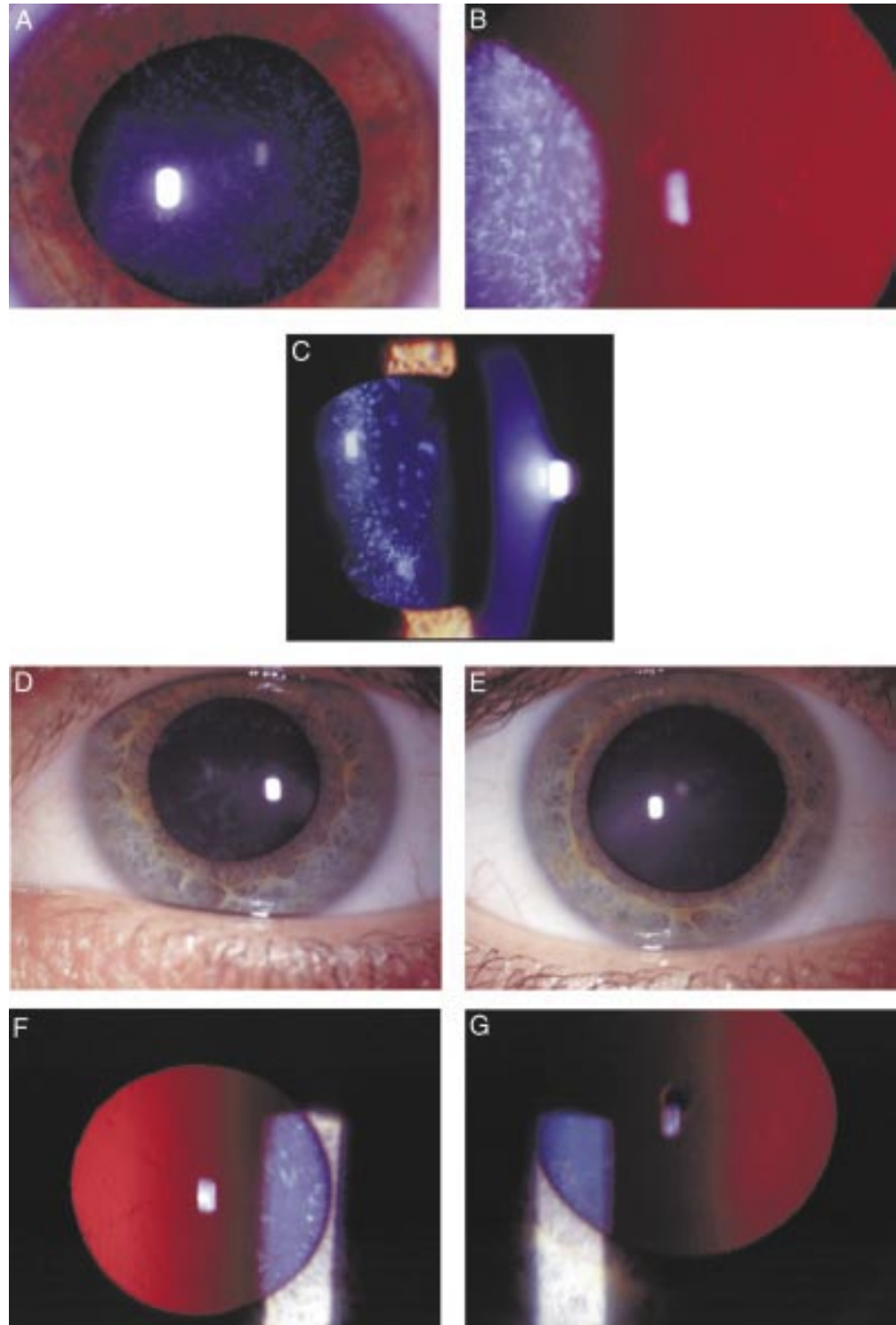


Figure 2 Punctate mid and peripheral opacities in: (A) direct illumination (34 year old female); (B) retroillumination (same patient as (A)); (C) slit beam illumination (17 year old female); (D) serpiginous nuclear opacities (24 year old female); (E) anterior polar cataract (same patient as in (D)); (F) retroillumination view of serpiginous nuclear opacities (same patient as in (D)); (G) retroillumination view of anterior polar cataract in patient with predominantly cortical opacification.

Table 2 Clinical data

Affected individual	Age (years)	Best corrected visual acuity	
		Right	Left
II:2	72	6/12	6/6 (pseudophakic)
III:2	55	6/24	6/6 (pseudophakic)
III:4	45	6/9 (aphakic)	HM (aphakic)
III:7	45	6/9	6/9
IV:2	35	6/6	6/12
IV:4	27	6/6	6/9-
IV:5	15	6/12 (aphakic)	6/9
IV:6	11	6/9 (aphakic)	6/6 (aphakic)
IV:8	16	6/6	6/6
V:2	1	—	—

missense mutation in the *MIP* gene.¹⁰ Lens opacification in this family was non-progressive and confirmed a perinuclear lamella. Such an observation is intriguing because it is not clear why two missense mutations in similar parts of the gene would produce such strikingly different phenotypes. Furthermore, this provides the first confirmation of allelic heterogeneity in this condition.

In conclusion, we have reported the identification of a new congenital cataract phenotype that results from a missense mutation in the major intrinsic protein of the lens. Studies of the implications of the mutation for the function of the protein will provide further understanding of how the underlying genotype relates to the phenotype observed.

The authors thank the family for their participation in this project and Mr Philip Ball (senior medical illustrator, Addenbrooke's Hospital, Cambridge) for his help in preparing the illustrations. This work was supported by a grant from the Wellcome Trust, 053416 to ATM and SSB.

- Evans J, Rooney C, Ashwood F, *et al.* Blindness and partial sight in England and Wales: April 1990–March 1991. *Health Trends* 1996;28:5–12.
- Francois J. Genetics of cataract. *Ophthalmologica* 1982;184:61–71.
- Ionides A, Francis P, Berry V, *et al.* Clinical and genetic heterogeneity in autosomal dominant congenital cataract. *Br J Ophthalmol* 1999;83:802–8.
- Lubsen N, Renwick J, Tsui L-C, *et al.* A locus for human hereditary cataract is closely linked to the gamma-crystallin gene family. *Proc Nat Acad Sci USA* 1987;84:489–92.
- Litt M, Kramer P, LaMorticella D, *et al.* Autosomal dominant congenital cataract associated with a missense mutation in the human alpha crystallin gene *CRYAA*. *Hum Mol Genet* 1998;7:471–4.
- Litt M, Carrero-Valenzuela R, LaMorticella D, *et al.* Autosomal dominant congenital cataract is associated with a chain termination mutation in the human beta-crystallin gene *CRYBB2*. *Hum Mol Genet* 1997;6:665–8.
- Shiels A, Mackay D, Ionides A, *et al.* A missense mutation in the human connexin 50 gene (*GJA8*) underlies autosomal dominant “zonular pulverulent” cataract, on chromosome 1q. *Am J Hum Genet* 1998;62:526–32.
- Berry V, Mackay D, Khaliq S, *et al.* Connexin 50 mutation in a family with congenital “zonular nuclear” pulverulent cataract (CZNP) of Pakistani origin. *Hum Genet* 1999;105:168–70.
- Mackay D, Ionides A, Kibar Z, *et al.* Connexin46 mutations in autosomal dominant congenital cataract. *Am J Hum Genet* 1999;64:1357–64.

- Berry V, Francis P, Kaushal S, *et al.* Missense mutations in the human *MIP* gene, encoding the major intrinsic protein of the lens, underlie autosomal dominant “polymorphic” and lamellar cataracts on 12q. *Nat Genet* 2000;25:15–17.
- Shiels A, Bassnett S. Mutations in the founder of the *MIP* gene family underlie cataract development in the mouse. *Nat Genet* 1996;12:212–15.
- Ionides A, Berry V, Mackay D, *et al.* A locus for autosomal dominant posterior polar cataract on chromosome 1p. *Hum Mol Genet* 1997;6:47–51.
- Heymann J, Agre P, Engel A. Progress on the structure and function of aquaporin 1. *J Struct Biol* 1998;121:191–206.
- Echevarria M, Ilundain A. Aquaporins. *J Physiol Biochem* 1998;54:107–18.
- Lee M, King L, Agre P. The aquaporin family of water channel proteins in clinical medicine. *Medicine (Baltimore)* 1997;76:141–56.
- Tamarappoo B, Yang B, Verkman A. Misfolding of mutant aquaporin-2 water channels in nephrogenic diabetes insipidus. *J Biol Chem* 1999;274:34825–31.
- Daniels G. Functional aspects of red cell antigens. *Blood Rev* 1999;13:14–35.
- Yanoff M, Duker J. *Ophthalmology*. St Louis: Mosby International, 1999.
- Rogaev E, Rogaeva E, Korovaitseva G, *et al.* Linkage of polymorphic congenital cataract to the gamma-crystallin locus on human chromosome 2q33–35. *Hum Mol Genet* 1996;5:699–703.
- Eiberg H, Lund A, Warburg M, *et al.* Assignment of congenital cataract Volkmann-type (CCV) to chromosome 1p36. *Hum Genet* 1995;96:33–8.
- American Society of Genetics. Identification of an autosomal dominant cataract locus on chromosome 12q12–12q14.1. 1998.
- Moross T, Vaithilingam S, Styles S, *et al.* Autosomal dominant anterior polar cataracts associated with a familial 2;14 translocation. *J Med Genet* 1984;21:52–3.
- Yokoyama Y, Narahara K, Tsuji K, *et al.* Autosomal dominant congenital cataract and microphthalmia associated with a familial t(2;16) translocation. *Hum Genet* 1992;90:177–8.
- Eiberg E, Marner E, Rosenberg T, *et al.* Marner's cataract (CAM) assigned to chromosome 16: linkage to haptoglobin. *Clin Genet* 1988;34:272–5.
- Berry V, Ionides A, Moore A, *et al.* A locus for autosomal dominant anterior polar cataract on chromosome 17p. *Mol Genet* 1996;5:415–19.
- Padma T, Ayyagari R, Murty J, *et al.* Autosomal dominant zonular cataract with sutural opacities localised to chromosome 17q11–12. *Am J Hum Genet* 1995;57:850–5.
- Armitage M, Kivlin J, Ferrel R. A progressive early onset cataract gene maps to human chromosome 17q24. *Nat Genet* 1995;9:37–40.
- Ogata H, Okubo Y, Akabara T. Phenotype i associated with congenital cataract in Japanese. *Transfusion* 1979;19:166–8.
- Krill A, Woodbury G, Bowman J. X-chromosomal-linked sutural cataracts. *Am J Ophthalmol* 1969;68:867–72.
- Shambolian D, Lewis R, Buctow K, *et al.* Nance-Horan syndrome: localisation within the region Xp22.1–22.3 by linkage analysis. *Am J Hum Genet* 1990;47:13–19.
- Warburg M. X-linked cataract and X-linked microphthalmos: how many deletion families? *Am J Med Genet* 1989;34:451–3.
- Stephan D, Gillanders E, Vanderveen D, *et al.* Progressive juvenile-onset punctate cataract characterised by mutation of the gamma-D-crystallin gene. *Proc Natl Acad Sci USA* 1999;96:1008–12.
- Heon E, Priston M, Schorederer D, *et al.* The gamma-crystallins and human cataracts: a puzzle made clearer. *Am J Hum Genet* 1999;65:1261–7.
- Semina E, Ferrell R, Mintz-Hittner H, *et al.* A novel homeobox gene *PITX3* is mutated in families with autosomal dominant cataracts and ASMD. *Nat Genet* 1998;19:167–70.
- Kramer P, Yount J, Michell T, *et al.* A second gene for cerulean cataract maps to the beta-crystallin region on chromosome 22. *Genomics* 1996;35:539–42.
- Gill D, Klose R, Munier F, *et al.* Genetic heterogeneity of the Coppock-like cataract: a mutation in *CRYBB2* on chromosome 22q11.2. *Invest Ophthalmol Vis Sci* 2000;41:159–65.



Congenital progressive polymorphic cataract caused by a mutation in the major intrinsic protein of the lens, MIP (AQP0)

Peter Francis, Vanita Berry, Shomi Bhattacharya, et al.

Br J Ophthalmol 2000 84: 1376-1379

doi: 10.1136/bjo.84.12.1376

Updated information and services can be found at:

<http://bjo.bmj.com/content/84/12/1376.full.html>

These include:

References

This article cites 33 articles, 10 of which can be accessed free at:

<http://bjo.bmj.com/content/84/12/1376.full.html#ref-list-1>

Article cited in:

<http://bjo.bmj.com/content/84/12/1376.full.html#related-urls>

Email alerting service

Receive free email alerts when new articles cite this article. Sign up in the box at the top right corner of the online article.

Topic Collections

Articles on similar topics can be found in the following collections

[Lens and zonules](#) (638 articles)

Notes

To request permissions go to:

<http://group.bmj.com/group/rights-licensing/permissions>

To order reprints go to:

<http://journals.bmj.com/cgi/reprintform>

To subscribe to BMJ go to:

<http://group.bmj.com/subscribe/>