

Diode laser treatment of posterior retinopathy of prematurity

Ruth Axer-Siegel, Moshe Snir, Dan Cotlear, Ayala Maayan, Ronit Frilling, Irit Rosenbaltt, Dov Weinberger, Israel Kremer, Lea Sirota

Abstract

Aims—To study the efficacy of infrared diode laser for the treatment of posterior retinopathy of prematurity (ROP).

Methods—48 eyes of 25 premature babies (mean birth weight 779 (SD 127.7) g; mean gestational age 25.5 (SD 1.47) weeks) with threshold ROP in zone I and posterior zone II were treated by the indirect infrared (810 nm) diode laser. Confluent burns were applied to the avascular retina. In 18 eyes, an additional row of laser burns was added posterior to the ridge.

Results—Favourable anatomical results were noted in 41 eyes (85.4%). ROP stage 5 developed in two eyes, ROP stage 4A developed in four eyes, and ROP stage 4B in one eye. Three of the eyes with stage 4A eyes were successfully buckled; the fourth was not operated on and remained demarcated by laser scars. No complications were noted.

Conclusion—In this series, the diode laser was found to be a safe and effective treatment for posterior ROP.

(Br J Ophthalmol 2000;84:1383–1386)

The 1990 publication of the Cryotherapy for Retinopathy of Prematurity Cooperative Group (CRYO-ROP)¹ showed that cryoablation of the avascular retina in zone I retinopathy of prematurity (ROP) reduces the very high unfavourable anatomical outcome (92%), but only to 75%. These poor results have been partly attributed to the technical difficulties of reaching the border of the posteriorly located ridge and the large area of avascular retina that has to be destroyed. In a further report, the same group² noted that babies with regressed ROP following successful cryotherapy may have atrophic changes in the macula which result in decreased visual acuity despite a favourable anatomical outcome. Some of these degenerative changes are caused by the uncontrollable extension of the treatment scars in the avascular retina, which is located anterior to the ridge near the macula in zone I ROP.

Data accumulated over recent years have indicated that laser treatment may be superior to cryotherapy for threshold ROP. Eyes treated with the binocular indirect ophthalmoscopic diode laser were found to be less myopic than cryo treated eyes, and the functional outcomes were better.^{3–9} Both treatment modalities had a similar effect on the structure of the retina,^{3–9} except in infants with posteriorly located ROP, in whom cryotherapy was successful in only

20–40% of cases^{2–4} compared with 80–88% for diode laser therapy.^{4 10–12}

The aim of the present study was to report on our experience with the infrared diode laser for the treatment of threshold ROP in zone I or posterior zone II.

Subjects and methods

All consecutive premature infants with threshold ROP hospitalised in our centre, as well as premature neonates referred from other hospitals, between December 1996 and December 1999 were treated with the diode indirect laser (Iris Medical Instruments, Inc, Mountainview, CA, USA). Threshold ROP was classified according to the CRYO-ROP Study Group as 5 or more contiguous or 8 cumulative clock hours of stage 3 ROP in zone I or II in the presence of “plus” disease.¹ The anterior border of posterior zone II was defined for the purpose of our study as 1 disc diameter peripheral to the outer border of zone I (Fig 1). This definition was formulated prospectively and used rigidly throughout the study. The zone of disease was determined according to the most posteriorly located neovascularisation. The location of the retinopathy was documented as zone I when a sector of at least 1 clock hour of neovascularisation was present within zone I. The number of sectors within the posterior zone was not assessed. The identification of the zone and the staging were performed by two independent ophthalmologists. In cases of disagreement, a third observer was consulted and the majority ruled.

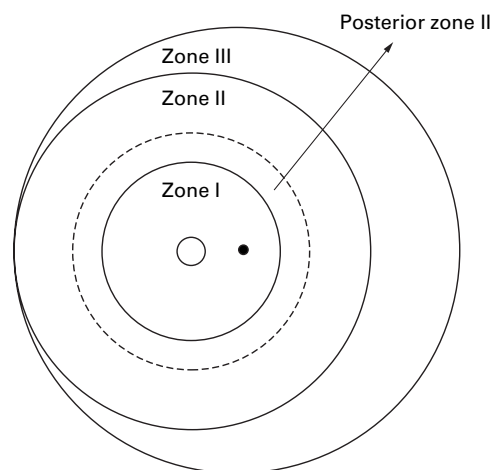


Figure 1 Schematic drawing showing the zones of the premature fundus, according to the CRYO-ROP study.¹ The broken circle represents the anterior border of posterior zone II, located one disc diameter peripheral to the anterior border of zone I.

Department of
Ophthalmology, Rabin
Medical Center,
Beilinson Campus,
Petah Tiqva, Israel

R Axer-Siegel
M Snir
D Cotlear
R Frilling
I Rosenbaltt
D Weinberger
I Kremer

Neonatal Intensive
Care Unit, Schneider
Children's Medical
Center of Israel, Petah
Tiqva, Israel
A Maayan
L Sirota

Correspondence to:
Dr Ruth Axer-Siegel,
Department of
Ophthalmology, Rabin
Medical Center, Beilinson
Campus, Petah Tiqva,
49101, Israel
seegs@netvision.net.il

Accepted for publication
1 June 2000

Table 1 Patients with unfavourable anatomic outcome

Patient no	Zone		Stage		Laser to vascular retina		Operation		Outcome	
	RE	LE	RE	LE	RE	LE	RE	LE	RE	LE
1	II	II	5	4A	No	No	Open sky vitrectomy	Buckle	Detached	Attached
2	I	I	4A	—	No	No	Buckle	—	Attached	—
3	I	I	—	4A	Yes	Yes	—	Laser barrage	—	Retina posterior to laser attached
4	I	I	5	4B	Yes	No	Lens sparing vitrectomy	Lens sparing vitrectomy	Detached	Detached
5	II	II	—	4A	Yes	No	—	Buckle	—	Attached

All the neonates from our hospital were first examined 3 weeks after birth and at weekly intervals thereafter. If ROP developed, the examinations were performed twice a week. When threshold disease was diagnosed, laser treatment was administered within 48 hours; all procedures were conducted in the neonatal intensive care unit. The pupils were dilated by three instillations of Mydriacyl drops (tropicamide, Alcon) every 15 minutes, and the neonates were pretreated with intravenous midazolam (100 µg/kg) and fentanyl (3 mg/kg) by a neonatologist, who monitored them throughout the procedure. Local anaesthetic drops were added. Both eyes were treated simultaneously. Tight scatter of laser applications was performed, with a half burn diameter between burns, from the ridge up to the ora serrata. The whole circumference of the avascular retina was treated with moderate white burns. In eyes that had a large amount of extraretinal fibrovascular proliferation on the ridge which caused local traction on the retina in the area of the ridge for 1½–2 ridge widths, extending for at least 2 clock hours temporal to the macula, an additional row of laser applications was delivered posterior to the ridge, avoiding the blood vessels. This was done, however, only when laser treatment of the area temporal to the fovea was safe, owing to the posterior location of the ridge. The laser treatment was not delivered closer than 1 disc area away from the fovea. Postoperatively all eyes were treated with cyclopentolate 0.5% and dexamethasone drops twice daily for 3 days. The babies were re-examined every 3 days until regression occurred. Supplemental treatment was added on skip areas when plus disease persisted or if fibrovascular proliferation persisted for 2 weeks following the primary treatment. In patients with an increased tractional component accompanying persistent plus disease with active extraretinal fibrovascular proliferations who had not received the laser applications posterior to the ridge during the primary procedure, one to two rows of photocoagulation were added posterior to the ridge between blood vessels. Follow up examinations to assess the anatomical result were performed biweekly until 4 months after treatment, and every 2–3 months thereafter. The criteria for unfavourable outcome were identical to those of the CRYO-ROP study, and included retinal detachment, macular fold or retrolental fibroplasia.¹

Results

During the period between December 1996 and December 1999, 33 consecutive neonates underwent photocoagulation with the diode laser for threshold ROP. Of these, eight were excluded from the study, seven with ROP in the anterior zone II and one neonate with zone I disease who died of sepsis 3 weeks after laser treatment. The remaining 25 included seven patients referred from other hospitals and 18 from our medical centre. There were 16 males and nine females. Birth weight was less than 915 g in all but one patient with hydrops, and ranged from 540–1130 g, with a median of 732.5 g and an average of 779 (SD 127.7) g. Gestational age ranged from 23–27 weeks, with an average of 25.5 (1.47) weeks. Mean gestational age at diagnosis of ROP was 33.2 (1.08) weeks and at laser treatment, 36 (1.93) weeks. Both eyes were treated in 23 patients and one eye in two, for a total of 48 eyes, including 23 with zone I ROP and 25 with posterior zone II ROP. The preretinal neovascularisation extended from 5 to 12 hours circumferentially, with a mean of 7.75 (2.4) hours. Plus disease was noted in all eyes.

The laser variables were as follows: power level 0.3 to 0.5 W, exposure time 0.2–0.5 seconds, and number of applications 800–1550, with an average of 1243 (SD 283). Retreatment was performed in 11 eyes (23%); however, the retreatment rate decreased from 29% during the first 2 years of performance of the procedure to 12% in the third year.

In 18 eyes, we added one to two rows of photocoagulation spots posterior to the ridge, avoiding the blood vessels and the area closer than 1 disc area to the fovea. Ten of the 18 eyes underwent the supplementary posterior laser treatment 2–3 weeks after the first treatment.

Three patients had intraoperative bradycardia and pulmonary distress; two were successfully intubated and ventilated during treatment. In the third patient, the session was stopped after treatment of one eye was completed and resumed for the second eye 2 days later. The only intraoperative ocular complication was a small local preretinal bleeding in two patients. The follow up period ranged from 3–25 months with a mean of 14 months.

An unfavourable anatomical outcome was observed in seven eyes (14.6%) of five patients. The data are shown in Table 1. Four eyes of four babies had 4A detachment; three were successfully buckled, and one was not operated

on because of parental refusal. In the latter patient, the eye remained stable with attached macula after posterior laser barrage, for a period of 20 months. One eye with stage 5 retinal detachment underwent open sky vitrectomy which failed. Two eyes in one baby (patient 4, Table 1) with stage 4B and 5 retinal detachment underwent lens sparing vitrectomy, and the retinas are still detached at 1 month postoperatively.

Of the 18 eyes that received laser treatment to the vascular retina posterior to the ridge two developed retinal detachment—the eye with stage 5 ROP in patient 4 and the eye with 4A detachment in patient 3 that was not operated on. In this patient, the partial retinal detachment remained demarcated by the posterior rows of laser scars.

Discussion

Posterior ROP carries a high risk of unfavourable anatomical outcome. According to several reports, the natural history of zone I ROP is associated with a poor anatomical outcome in 92% of eyes.^{1 13-15} In the CRYO-ROP study,¹ treatment of zone I disease with cryotherapy had a 75% chance of an unfavourable result, compared to 22% for zone II disease. As the results for anterior and posterior zone II ROP have not been examined separately, the chance of an unfavourable outcome for posterior zone II disease would be expected to range between 22% and 75%. Although many researchers believe that the clinical course of posterior zone II disease is similar to that of zone I,¹¹ the behaviour of threshold ROP in posterior zone II disease is not known.

Eighteen of the 26 neonates (69%) in our study had posterior zone ROP. In the series of Noonan and Clark⁴ 30/64 cryo treated eyes (47%) had posterior ROP and only 14/59 (24%) laser treated eyes. This difference may have been due to differences in postnatal care or differences in the definition of the posterior zone. We defined the anterior border of the posterior zone II as 1 disc diameter peripheral to the outer border of zone I, even when this area extended for 1 clock hour. The identification of the zone was performed during the clinical examination. By contrast, Noonan and Clark⁴ classified theirs retrospectively, based on a review of the medical records; eyes were diagnosed as having anterior zone ROP if there was doubt as to whether the ROP was posterior or mid-zone II. This method may have led to an underestimation of the number of cases of posterior zone ROP. In the recent series of Banach *et al.*,¹⁶ zone I ROP was reported in 4/56 (7.1%) patients in cohort 1 and 18/51 (35.3%) in cohort 2. A possible explanation for this disparity was that some of the patients in cohort 2 were treated in a different hospital, with differences in oxygen administration, surfactant treatment, and related factors. In our series, zone I disease occurred in 23 eyes of 12 babies, nine of whom were hospitalised in our centre. The rate of nine babies out of 26 (34.6%) (19 posterior zone and seven anterior zone II) corresponds roughly to that of cohort 2 in the series of Banach *et al.*¹⁶

These data indicate that the zone of threshold ROP varies in different studies. These differences may play a part in the natural history as well as in the anatomical and functional results of laser treatment.

Recent reports have shown that laser treatment for ROP is at least as effective as cryotherapy, and for zone I disease probably even superior.^{3-11 13 16-20} Capone *et al.*¹⁰ noted a favourable outcome in 83.3% of 30 eyes with zone I threshold ROP that were treated with diode laser, and Fleming *et al.*¹¹ reported successful results with diode laser photocoagulation for prethreshold posterior ROP. In the latter study, 10 eyes had zone I disease and eight had posterior zone II disease, which was defined as ROP located in the posterior half of zone II. All eyes showed complete regression of the retinopathy after treatment; however, the authors' criterion for treatment was the presence of plus disease, and none of the eyes had neovascularisation at the time of laser application. Noonan and Clark⁴ reported an 87.5% success rate in a series of 14 eyes with posterior ROP treated with diode or argon laser. These results compare favourably with the authors' 40% success rate with cryotherapy in 30 eyes with posterior zone ROP. The authors attributed the good results to a combination of the change in treatment modality and the treatment of prethreshold disease in some cases. They stated that they now treat zone I disease as soon as plus disease develops. Vander *et al.*¹² reported on a series of 36 eyes of 19 patients with posterior ROP. Seventeen babies were treated with the diode laser and two with the argon laser. The posterior zone was defined as the field seen with a Volk 25 dioptre indirect condensing lens. The edge of the optic disc was placed at the edge of the field of view, and the extent of the vascularisation at the opposing edge of the lens was defined as being within the posterior zone. This posterior zone is roughly comparable with zone I, though judging from their illustration it may have been slightly larger. The eyes were randomised for treatment at prethreshold or threshold disease. An unfavourable anatomical structural outcome was noted in 16% of the 19 early treatment eyes and in 18% of the 17 eyes treated at threshold. All these series showed better results than those of the CRYO-ROP study for posteriorly located disease.¹

ROP occurs in two phases. The first phase is characterised by vaso-obliteration which causes hypoxia of the non-perfused avascular retina. In the second phase, retinal neovascularisation occurs. According to Pierce *et al.*,²¹ vascular endothelial growth factor (VEGF) is produced just anterior to the developing blood vessels. Using a rat model of ROP, Dorey *et al.*²² showed that the inner nuclear layer of oxygen exposed retinas exhibited messenger RNA of VEGF expression in the peripheral avascular area, which sharply diminished in the vascular retina. Neovascularisation occurred adjacent to the regions of greatest expression. In a cat model of ROP, Stone *et al.*²³ found that VEGF expression was maximal where vessels were about to form. They suggested that therapeutic ablation of the ischaemic avascular retina suppresses the abnor-

mal angiogenesis which is stimulated by VEGF and other growth factors. Moreover, it probably promotes chorioretinal adhesions that may contribute to the favourable anatomical outcome. This was supported by the study of Banach *et al*⁶ demonstrating that dense confluent diode laser treatment of the avascular retina significantly reduces the progression of threshold ROP compared with a less dense laser pattern. However, a significant proportion of eyes still progress to retinal detachment.

Treatment of the retina posterior to the ridge was reported already in 1978 by Hindle and Leyton.²⁴ These authors performed cryotherapy on the ridge and the adjacent areas anterior and posterior to it, using one or two rows of cryoapplications. They reported regression of the mesenchymal ridge and no scarring in most of the treated eyes. In 1995, O'Keefe *et al*²⁵ performed diode laser photocoagulation posterior to the ridge in eight eyes of five infants—six eyes with stage 4A ROP and two eyes (in one premature baby) with advancing stage 3+ ROP. Total regression was noted in six eyes of four patients and a flat macula with peripheral retinal detachment in two eyes of two patients. The authors suggested that diode laser photocoagulation of the vascular retina posterior of the ridge may be useful in progressive stage 3 and stage 4A ROP after failed treatment of the avascular retina. The laser was recommended for the area posterior to the ridge because it creates a chorioretinal adhesion by its relatively deep burn.²⁶

We treated the vascular retina posterior to the ridge by application of one to two rows of laser burns either during the primary procedure or 2–3 weeks later, during supplementary treatment. The ridge itself was not treated. In the cases that received supplementary treatment, the axial growth of the eye caused anterior displacement of the laser scars away from the macula, thereby enabling additional laser treatment at least 1 disc diameter temporal to the fovea. When regression occurred, the laser scars grew and became almost confluent. The fibrovascular ridge remained as an atrophic white extraretinal tissue, surrounded by laser scars. One eye with 4A detachment had an area of 2 clock hours of temporal retinal detachment, demarcated by two rows of laser scars posteriorly.

Our 85.4% rate of favourable anatomical results is similar to the rates reported in previous series of posterior threshold ROP treated with the diode laser.^{4 10 18–20} Furthermore, in four of the seven eyes with an unfavourable outcome, the macula remained attached throughout the entire follow up period. However, caution must be exercised when comparing our series with others, owing to the difference in the methodology and in the definition of the posterior zone. Since some cases of stage 4 disease are self limiting, the possible role of the laser scars as a barrier against traction retinal detachment should probably be studied in a randomised trial.

In conclusion, diode laser treatment of posterior ROP yielded a favourable anatomical outcome in 41/48 eyes (85.4%). Four additional

eyes had attached macula after buckling procedure. The role of laser treatment posterior to the ridge remains controversial, and randomised clinical trials are needed to test its efficacy.

Presented in part at the American Academy of Ophthalmology Meeting, Orlando, Florida, October 1999.

We are grateful for the editorial and secretarial help of Mrs Gloria Ginzach and Mrs Melanie Kawe.

- 1 Cryotherapy for Retinopathy of Prematurity Cooperative Group. Multicenter trial of cryotherapy for retinopathy of prematurity: three-month outcome. *Arch Ophthalmol* 1990;108:195–204.
- 2 Cryotherapy for Retinopathy of Prematurity Cooperative Group. Multicenter trial of cryotherapy for retinopathy of prematurity. Snellen visual acuity and structural outcome at 5½ years after randomization. *Arch Ophthalmol* 1996;114:417–24.
- 3 McGregor ML, Wherley AJ, Fellows DD, et al. A comparison of cryotherapy versus diode laser retinopathy in 100 consecutive infants treated for threshold retinopathy of prematurity. *JAAPOS* 1998;2:360–4.
- 4 Noonan CP, Clark DI. Trends in the management of stage 3 retinopathy of prematurity. *Br J Ophthalmol* 1996;80:278–81.
- 5 O'Keefe M, O'Reilly J, Lanigan B. Longer-term visual outcome of eyes with retinopathy of prematurity treated with cryotherapy or diode laser. *Br J Ophthalmol* 1998;82:1246–8.
- 6 Pearce IA, Pennil FC, Cannon LM, et al. Three year visual outcome for treated stage 3 retinopathy of prematurity: cryo versus laser. *Br J Ophthalmol* 1998;82:1254–59.
- 7 White JE, Repka MX. Randomized comparison of diode laser photocoagulation versus cryotherapy for threshold retinopathy of prematurity: 3-year outcome. *J Pediatr Ophthalmol Strabismus* 1997;34:83–7.
- 8 Connolly BP, McNamara JA, Sharma S, et al. A comparison of laser photocoagulation with trans-scleral cryotherapy in the treatment of threshold retinopathy of prematurity. *Ophthalmology* 1998;105:1628–31.
- 9 McNamara JA, Tasman W, Brown GC, et al. Laser photocoagulation for stage 3+ retinopathy of prematurity. *Ophthalmology* 1991;98:576–80.
- 10 Capone AJR, Diaz-Rohena R, Sternberg P Jr, et al. Diode laser photocoagulation for zone I threshold retinopathy of prematurity. *Am J Ophthalmol* 1993;116:444–50.
- 11 Fleming TN, Runge PE, Charles ST. Diode laser photocoagulation for prethreshold posterior retinopathy of prematurity. *Am J Ophthalmol* 1992;114:589–92.
- 12 Vander JF, Handa J, McNamara JA, et al. Early treatment of posterior retinopathy of prematurity. A controlled trial. *Ophthalmology* 1997;104:1731–6.
- 13 Tasman W. Zone I retinopathy of prematurity. *Arch Ophthalmol* 1985;103:1693–4.
- 14 Cryotherapy for Retinopathy of Prematurity Cooperative Group. Multicenter trial of cryotherapy for retinopathy of prematurity: one-year outcome—structure and function. *Arch Ophthalmol* 1990;108:1408–16.
- 15 Cryotherapy for Retinopathy of Prematurity Cooperative Group. Multicenter trial of cryotherapy for retinopathy of prematurity: 3½-year outcome—structure and function. *Arch Ophthalmol* 1993;111:339–44.
- 16 Banach MJ, Ferrone PJ, Trese MT. A comparison of dense versus less dense diode laser photocoagulation patterns for threshold retinopathy of prematurity. *Ophthalmology* 1999;107:324–7.
- 17 Landers MB III, Semple HC, Ruben JB, et al. Argon laser photocoagulation for advanced retinopathy of prematurity. *Am J Ophthalmol* 1990;110:429–31.
- 18 McNamara JA, Tasman W, Vander JF, et al. Diode laser photocoagulation for retinopathy of prematurity. Preliminary results. *Arch Ophthalmol* 1992;110:1714–6.
- 19 Tsitisis T, Tasman W, McNamara JA, et al. Diode laser photocoagulation for retinopathy of prematurity. *Trans Am Ophthalmol Soc* 1997;95:231–6.
- 20 Seiberth V, Linderkamp O, Vardarli I. Transscleral vs transpupillary diode laser photocoagulation for the treatment of threshold retinopathy of prematurity. *Arch Ophthalmol* 1997;115:1270–5.
- 21 Pierce EA, Foley D, Smith LEH. Regulation of vascular endothelial growth factor by oxygen in a model of retinopathy of prematurity. *Arch Ophthalmol* 1996;114:1219–28.
- 22 Dorey CK, Aouididi S, Reynaud X, et al. Correlation of vascular permeability factor/vascular endothelial growth factor with extraretinal neovascularization in the rat. *Arch Ophthalmol* 1996;114:1210–17.
- 23 Stone J, Chang-Ling T, Pe'er J, et al. Roles of endothelial growth factor and astrocyte degeneration in the genesis of retinopathy of prematurity. *Invest Ophthalmol Vis Sci* 1996;37:290–9.
- 24 Hindle NW, Leyton J. Prevention of cicatricial retrolental fibroplasia by cryotherapy. *Can J Ophthalmol* 1978;3:277–82.
- 25 O'Keefe M, Burke J, Algavvi K, et al. Diode laser photocoagulation to the vascular retina for progressively advancing retinopathy of prematurity. *Br J Ophthalmol* 1995;79:1012–4.
- 26 Menchini U, Trabucchi G, Brancato A, et al. Can diode laser (810 nm) effectively produce chorioretinal adhesion? *Retina* 1992;12:580–6.



Diode laser treatment of posterior retinopathy of prematurity

Ruth Axer-Siegel, Moshe Snir, Dan Cotlear, et al.

Br J Ophthalmol 2000 84: 1383-1386

doi: 10.1136/bjo.84.12.1383

Updated information and services can be found at:

<http://bjo.bmj.com/content/84/12/1383.full.html>

These include:

References

This article cites 26 articles, 14 of which can be accessed free at:

<http://bjo.bmj.com/content/84/12/1383.full.html#ref-list-1>

Email alerting service

Receive free email alerts when new articles cite this article. Sign up in the box at the top right corner of the online article.

Topic Collections

Articles on similar topics can be found in the following collections

[Retina](#) (1217 articles)

[Paediatrics](#) (278 articles)

Notes

To request permissions go to:

<http://group.bmj.com/group/rights-licensing/permissions>

To order reprints go to:

<http://journals.bmj.com/cgi/reprintform>

To subscribe to BMJ go to:

<http://group.bmj.com/subscribe/>