

ORIGINAL ARTICLES—Laboratory science

Variable R1 region in varicella zoster virus in fulminant type of acute retinal necrosis syndrome

Toshiaki Abe, Masami Sato, Makoto Tamai

Abstract

Background/claims—Varicella zoster virus (VZV) is a causative agent in acute retinal necrosis (ARN) syndrome. However, in spite of aggressive antiviral therapy, clinical characteristics among patients have varied. Different viral strains were examined to determine their respective role in producing clinical characteristics. The viral strains were also compared with those of previously reported ones.

Methods—To differentiate VZV strains R1 and R5, variable regions of VZV were amplified by nested polymerase chain reaction (PCR) in 11 eyes of 10 patients. Sequence analysis was also performed.

Results—Four cases had strains diverted only at the tip of the 3' end of the R1 variable region, similar to that of the H-N3 strain, which was previously reported. Conversely, other cases were diverted to other regions. Interestingly, some of the latter cases showed multiple PCR products in the R1 region that were generated by the truncation of either the 5' or 3' R1 region. Final visual acuities of these patients were less than 0.2. The former cases showed final visual acuities more than 0.4. Only two variants were from the R5 region. No patient had the same viral strain as the European Dumas type.

Conclusion—These results showed that variable VZV strains participated in ARN. Using PCR of the R1 variable region, it was estimated that patients with a more fulminant type of ARN may have diverse viruses with extensive replication in the affected eyes.

(Br J Ophthalmol 2000;84:193–198)

Varicella zoster virus (VZV) is a human herpes virus that belongs to the *Alphaherpesvirinae* family.¹ The complete genome sequence of VZV, which was first reported in the European strain (Dumas) by Davison and Scott,² comprises 124 884 base pairs, and is about 80×10⁶ daltons in size.³ VZV causes chickenpox in susceptible individuals, and 95% of the population is immune to the childhood infection.⁴ After reactivation from latency in the dorsal root ganglia, VZV may also cause shingles, and is becoming more prevalent as the average age

of the general population increases.⁵ The virus may also play an important part in the cause of acute retinal necrosis syndrome (ARN) and related disorders. These findings have been confirmed by direct viral detection, local antibody production,⁶ and viral genome detection by polymerase chain reaction (PCR).^{7–10} Results of these methods have been comparable.¹¹ Detection of viruses and antiviral therapy have dramatically improved the prognosis of patients with the disease,¹² when compared with those originally described by Urayama and coworkers.¹³ However, in spite of the same regimen of antiviral therapy, the clinical course and severity of the disease differ widely among patients with ARN syndrome. Some authors have reported that patients with ARN syndrome show mild clinical appearance and retain good visual function, while others described patients with a more fulminant clinical course and deteriorating visual function.¹⁴ One report also stated that the more fulminant type of ARN had statistically significant amounts of virus in the ocular fluids, in contrast with mild cases¹⁵; however, no reports have indicated what kinds of factors may have influenced those findings.

Previous attempts have been made to determine VZV strains by the restriction endonuclease digestion pattern, using cell culture systems to distinguish the wild type strain from the vaccine strain, or as methods for an epidemiological tool.^{5 16 17} However, more recently, PCR methods have been developed to differentiate VZV strains by using the repeated elements of the VZV genome or the specific site for several restriction enzymes, because variation in the number of repeats has been observed over time.^{4 18 19} In this report, we examined the differences of the VZV strains by using PCR of the R1 and R5 variable regions to assess if differences influenced the clinical appearances in patients with ARN.

Materials and methods**PATIENTS**

We studied 11 eyes from 10 patients from the Miyagi prefecture, where the university medical centre is located, or just adjacent to it. We collected vitreous or aqueous samples from these patients (Table 1). In cases 5 and 7 (see Figs 2 and 4), we collected samples two or three times during follow up examination. All

Department of
Ophthalmology,
Tohoku University
School of Medicine,
Sendai, Japan

T Abe
M Sato
M Tamai

Correspondence to:
T Abe, Department of
Ophthalmology, Tohoku
University School of
Medicine, 1-1 Seiryomachi
Aobaku Sendai, Miyagi,
980-8574 Japan

Accepted for publication
6 September 1999

Table 1 Characteristics of patients with acute retinal necrosis

Patient	Sex/age/ laterality	Visual acuity			Immunosuppressive illness	Amount of DNA for PCR (ng)
		Initial	Final	Zone*		
1	53/F/R	0.7	1.2	I	—	11
2	36/F/L	0.3	1.2	I	—	10
3	69/M/R	0.4	0.4	I	—	ND
4	24/M/L	0.4	1.0	IIp	—	7
5	69/F/R	0.1	0.1	IIp	—	11
6	69/F/L	0.1	0.6	I	—	6
7	68/F/R	0.5	0.1	II _t	VZV dermatitis†	9
8	81/F/R	0.1	0.2	I	VZV dermatitis	10
9‡	13/M/L	NLP	NLP	III	Fibrous dysplasia in left sphenoidal sinus (postop)	7
10	69/F/L	CF	0.04	IIp	VZV dermatitis	ND
11	30/F/R	0.04	LS	III	—	11

*Extension of retinal exudates.¹² (I) Indicates exudates restricted to the area between the ora serrata and vortex vein; (II) exudates between vortex vein and vascular arcades; (III) exudates beyond vascular arcades; II_t, exudates involving the entire 360° area II; and II_p, partial degree of area II. Visual acuity: initial/final, visual acuities when patients first consulted us and most recent. †VZV dermatitis indicated the previous history of the presence of VZV dermatitis. ‡Patient 9 had had surgery for fibrous dysplasia in his left sphenoid sinus and showed optic atrophy postoperatively.

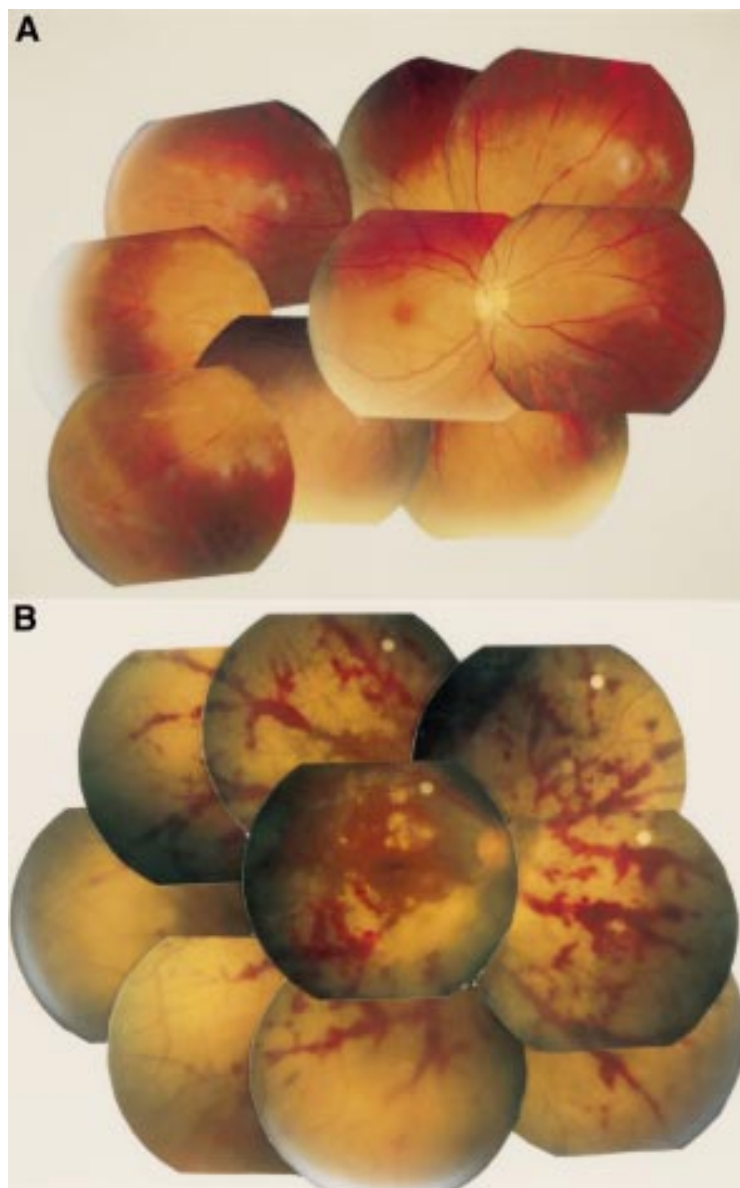


Figure 1 Fundus photographs of patients 1 and 11. Mild arteritis close to the optic disc and mid-peripheral areas are seen in patient 1. Mild retinal exudates occur at the far periphery of the temporal region, which is not clearly visible (A). Conversely, the fundus of case 11 shows extensive retinal exudates with retinal haemorrhages in almost all the retinal regions except the macular area (B).

patients had demonstrated amplified VZV genome by primers of VZV-1 and VZV-2. We excluded patients who did not show amplified R1 and R5 variable regions by these primers, in spite of repeated examinations, or who refused to receive antiviral therapy or surgical treatment. All patients were well matched to the American Uveitis Society's criteria for the diagnosis of ARN,²⁰ even though severity of the disease varied. Patients demonstrated extension of retinal exudates from I to III, according to the classification of Matsuo *et al*¹⁴ (Table 1). Informed consent was obtained from all subjects who participated in this study. In the patients with bilateral infection (cases 5 and 6), the second eye was affected 7 days after the first. All other patients had unilateral infection, and no infection was observed in the second eye during the follow up period. Cases 7, 8, and 10 had a history of VZV dermatitis before the onset of ARN. Case 9 underwent removal of fibrous dysplasia of the left sphenoidal sinus at age 9 years, and has been followed up by us for optic atrophy of the left eye (best corrected visual acuity was 0.1).

No patient had received antiviral treatment before the first anterior chamber tap. All were treated with the systemic antiviral drug aciclovir, 30 mg/kg²¹ and a local and systemic steroid (dexamethasone, 60 mg/day, tapered weekly) until vitreous surgery was performed, if necessary. For cases 2 and 10, we examined only the vitreous. Case 1 had very mild focal retinal necrosis and focal arteritis, which reacted promptly to aciclovir and steroid therapy. The surgical patients (10 eyes) were treated with scleral buckling, a three port vitrectomy with intravitreal administration of aciclovir (40 µg/ml) and dexamethasone (6 µg/ml),²² and endophotocoagulation. None of the final visual acuities was thought to be influenced by secondary cataract or surgical complications.

CONDITION OF PCR

We used the same methods for PCR as previously reported.¹¹ Briefly, with the use of a thermocycler (Perkin Elmer, Norwalk, CT, USA), PCR was carried out in 50 µl of reaction mixture containing 1 µl of the treated vitreous or aqueous humour (described below), 20 µM of each primer (VZV-1 and VZV-2, VZV-1R1 and VZV-1R2, and VZV-5R1 and VZV-5R2); 200 µM each of dATP, dCTP, dGTP, and TTP; 50 mM of KCl; 10 mM of TRIS Cl (pH 8.3); 1.5 mM of MgCl₂ and 0.001% gelatin; and 2.5 units of Taq polymerase. The DNA concentrations of the samples were adjusted following measurement by spectrophotometry (Ultrospec 4000, Pharmacia Biotech, Cambridge). The concentrations used in the study are shown in Table 1. There were 35 reaction cycles. The temperature settings for PCR were 94°C for 1 minute of denaturation, 60°C for 2 minutes of annealing, and 72°C for 2 minutes of polymerisation. For the negative control, we performed PCR without samples under the same conditions as described. The PCR products were further examined by nested primer sets (VZV-1R3 and VZV-1R4 or VZV-5R3 and VZV-5R4), which were designed from the

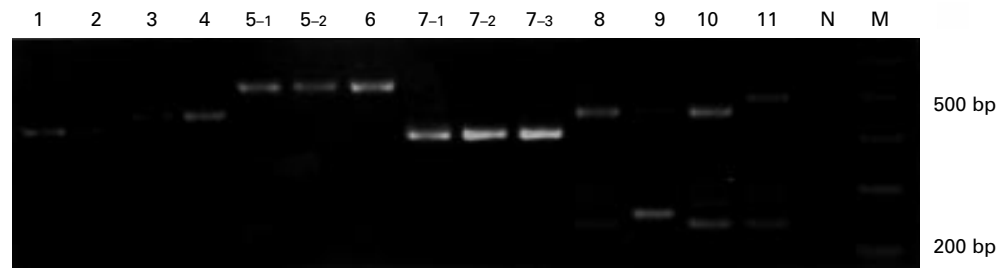


Figure 2 The results of the PCR of the R1 variable region are shown. Each number of the upper lane indicates the patient number, N; negative control, M; 100 base pair marker. Patients 5 and 6 represent both eyes of one patient who had bilateral infection. Repeated aqueous taps were performed in cases 5 (5-1 and 5-2) and 7 (7-1, 7-2, and 7-3) during their follow up examination. Exact amplification size of each PCR product in patients 1, 2, 3, 4, 5, 6, 7, 8, 9, 10, and 11 (larger bands) were 464, 464, 497, 497, 509, 509, 416, 464, 464, 461, and 497 base pairs, respectively.

inner sequences of VZV-1R1 and VZV-1R2 or VZV-5R1 and VZV-5R2, respectively; 20 cycles of PCR under the same condition as described here, except for 65°C for annealing, were performed using 1 µl of each PCR

product.²² In each case, amplified DNA was separated in 2% agarose gel (SeaKem, FMC BioProducts, Rockland, ME, USA) containing 0.05 µg/ml ethidium bromide. DNA was visualised with use of an ultraviolet transilluminator.

Construction of R1 variable region

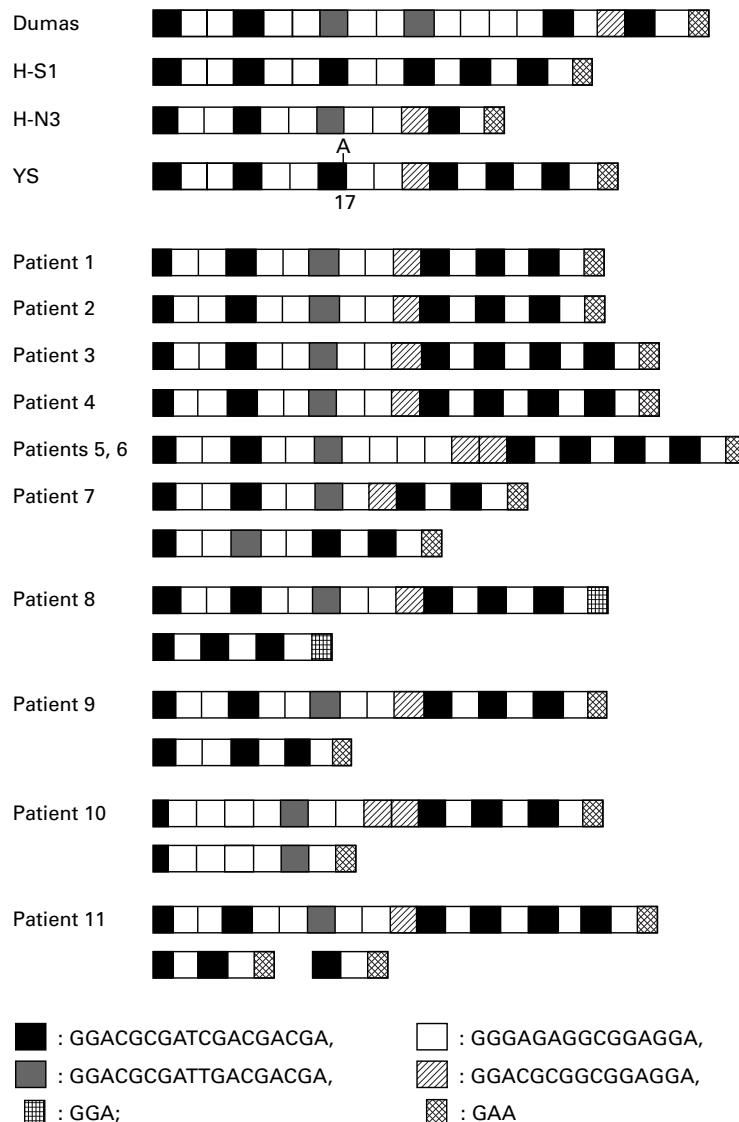


Figure 3 Construction of R1 variable region²³; for each element see key. Dumas type was reported by Davison and Scott² and H-S1, H-N3, and YS strains were reported by Kinoshita and coworkers.³

PRIMERS

Primers for amplifying the R1 and R5 variable regions of VZV genome were determined from the sequence by Davison and Scott² using computer DNA analysing software:

VZV-1; 5'-CAGTTCATCCGCAGACTCCA
ACGC-3' and

VZV-2; 5'-TACGGACATGAACTTTATCG
TACC-3'

VZV-1R1 5'-GAACTCCGAGATGGATCA
GG-3' and

VZV-1R2 5'-ATACCGCAGGCTCCATAAC
C-3' and for nested PCR

VZV-1R3 5'-ACAGCAGTTCTGACGCAT
CG-3' and

VZV-1R4 5'-TAAACCTCATCCGCGTCT
CG-3'

VZV-5R1 5'-TTATGTGATGCCATGACG
C-3' and

VZV-5R2 5'-ATGCCAACTGGATAGTCT
GC-3' and for nested PCR

VZV-5R3 5'-TTATATTATACCTCTCGCG
G-3' and

VZV-5R4 5'-GATATTTTAAGCACGCTG
CC-3'

The primer sets of VZV-1 and VZV-2, VZV-1R1 and VZV-1R2, VZV-1R3 and VZV-1R4, VZV-5R1 and VZV-5R2, and VZV-5R3 and VZV-5R4 amplified VZV genome DNA for 126, 598, 508, 801, and 324 bp, respectively, from the original sequence described by Davison and Scott.²

PREPARATION OF VITREOUS AND AQUEOUS HUMOUR SAMPLES

The vitreous samples were collected, as reported previously,²³ and were never diluted by infusion fluid. About 100 µl of aqueous humour was aspirated from the limbus with use of a 27 gauge needle. An aliquot of the sample (about 40 µl) was frozen and thawed four times and boiled for 9 minutes at 100°C.¹¹ One µl of this sample was added directly to the PCR mixture.




Figure 4 The results of PCR of the R5 variable region demonstrated two types of PCR products. The amplification sizes were 548 (patient 4) and 436 (other patients) base pairs. The R5 variable region was never amplified in case 2, in spite of repeated examinations. Abbreviations are the same as in Figure 2.

CHEMICALS

Taq polymerase was purchased from Takara (Kyoto, Japan), and other chemicals were supplied by Sigma (St Louis, MO, USA) or Wako (Tokyo, Japan).

Results

The characteristics of all patients who participated in this study have been summarised in

Table 1. As we reported previously, final visual acuities appeared to fall into two groups. Six patients had final visual acuities of 0.2 or less, and five patients had visual acuities of 0.4 or better (Table 1). Figure 1 showed the panel of fundus photographs for cases 1 (Fig 1A) and 11 (Fig 1B) from their initial visit to us. Case 1 had mild arteritis close to the optic disc and in the mid-periphery, with mild retinal exudates at the far periphery of the temporal region. Conversely, the fundus of case 11 (Fig 1B) showed extensive retinal exudates with retinal haemorrhages in almost all the retinal regions except the posterior pole.

We could amplify the VZV genome by the primers of VZV-1 and VZV-2 in all of these patients (data not shown). We could also amplify the R1 variable region of VZV genome in all the samples by nested PCR (Fig 2). We found various sized PCR products from these regions in our patients. Cases 1–6 showed only one PCR product while cases 7–11 showed multiple PCR products. Although the patient in case 7 appeared to show only one PCR product, sequence analysis revealed that multiple PCR products were included in the first sample (7-1 in Fig 2) (Fig 3). We also amplified the other variable region, called R5, by the indicated primer sets (Fig 4). We found that the PCR products were divided into two sizes. In spite of repeated analysis, we could not amplify the R5 region in case 2. We also found multiple PCR products in cases 5, 7, 8, and 9, although they were faint.

After subcloning into the T vector, we performed sequence analysis in the PCR products. The size differences were derived from different constructions of the repeated elements in the regions, which consisted of five different elements (A, B, C, D, and X) in R1^{3,25} and two (A and B) in R5.²⁶ The sequence of each element was determined (Figs 3 and 5). Cases 1, 2, 3, and 4, and parts of PCR products of cases 8, 9, and 11 showed the same construction in the R1 variable region as that of H-N3 strain, with diversion only at the tip of 3' end—namely, ABBABBCBBDABABABX in cases 1 and 2 and parts of case 9; ABBABB-CBBDABABABABX in cases 3 and 4 and parts of case 11; ABBABBCBBDABABABX' (X' indicate GAA instead of GGA (X) in the last three nucleotides in the region) in case 8, compared with the H-N3 strain ABBABB-CBBDABABABX reported by Kinoshita and coworkers³ (Fig 3). Case 8 also had additional, smaller PCR products, which were constructed from extremely small amounts of R1 repeat




Figure 5 Construction of R5 variable region²⁴; for each element see key. Dumas type was reported by Davison and Scott² and H-S1, H-N3, and YS strains were reported by Honda and coworkers.²³

elements (Fig 3). Cases 5 and 6, the patient with bilateral ARN, had the largest and most diverse construction of the region (Fig 3). Cases 7, 9, 10, and 11 also showed additional PCR products, similar to those of case 8, with an extremely diverted arrangement (Figs 2 and 3). No patient had the same arrangement in the R1 region as those of the European Dumas type or H-S1, H-N3, and YS strains. The arrangements of R5 repeat elements showed either ABABABA in case 4 and parts of PCR products of cases 5, 7, 8, and 9 or ABABA in other patients. These arrangements were coincidental with previously reported arrangements²⁶ (Fig 5). The arrangements of the R5 region were not as diverse as those of the R1 repeat region. The sequences flanking these regions were completely matched to the previously reported sequences.² There were no sequences with more than one primer binding site in these flanking and repeated regions.

Discussion

By using restriction endonuclease digestion, several authors have tried to differentiate VZV strains by size in variable regions.²⁷ Especially since the establishment of the live attenuated VZV vaccine, which was developed in Japan,²⁸ vesicular disease has been studied to determine if it is due to a wild strain or a vaccine strain.⁵ The results were obtained through studies of in vitro culture of the virus and endonuclease digestion system.^{5 26 27} From those studies, several portions were suspected to be diverse among the viral strains. Five variable regions (from R1 to 5) have been characterised so far,³ and these regions also were reported to be stable.^{5 26 27} The regions from R1 to 3 were in the open reading frames. Hawrami and coworkers⁴ reported that R2, R3, and R4 loci were not informative, having only a single VZV specific allele. Conversely, R1 and R5 were helpful to differentiate strains. However, because the methodology for clinical application of the endonuclease analysis was so complex, additional PCR methods have been developed to differentiate the VZV strain by using repeated elements of the VZV genome.^{4 19}

We found the PCR method to be quick and specific, especially if our results were compared with those of the in vitro culture and restriction endonuclease analysis.⁴ We also tried to grow the viruses in tissue culture (cases 4, 5, 6, 8, and 11) but failed. Several studies also stated that only 20%–35% of strains can be isolated from varicella or zoster vesicle for tissue culture.^{4 29} These failures may have been due to the lability of the virus, fastidious growth requirement, or inability of some strains to adapt to all in vitro cultures. The features of each strain will have to be revealed through other methods.

By using PCR of the R1 and R5 variable regions in the VZV genome, we analysed the VZV strain, which was detected in the ocular fluids in patients with ARN, to see if they had any influence on the patients' clinical characteristics. We also compared the strains with those of previously reported ones. R1 regions were diverse in patients with ARN syndrome,

when compared with those reported by Kinoshita and coworkers³ and the European Dumas type. Cases 1, 2, 3, and 4 closely resembled strains that were diverse only at the tip of the 3' end, similar to the H-N3 strain, which was reported previously³—namely, the elements of AB or ABAB were added to the 3' end of the region. These changes were also observed in in vitro passages in one of 14 clones by Kinoshita and coworkers.³ As the authors discussed, the minor difference may have been generated during viral transmission between human hosts, so the origin of these viruses may have been same. These results also were coincident with the previous report that R1 regions among the VZV strains varied only at the 3' end and that the 5' end was almost identical. The extension of retinal exudates of these patients were either I or IIp, when they initially visited us, and they showed good visual prognosis.

Conversely, other cases have had diverse R1 regions or have shown multiple PCR products of the R1 region. When we consider the strain type by only its longest allele, patients 8, 9, and 10 all have the same length R1 region as those of patients 1 and 2. The results of sequence analysis demonstrated that the smaller PCR products in the R1 region of our patients appeared as miniature models of the larger PCR products, as if they had been truncated at the 5' or 3' end. If we consider the peptide constructed from these variable regions, the viruses with the smaller R1 region may have extensively diverse function. Interestingly, smaller PCR products of the R1 variable region were never observed in our patients whose final visual acuities were more than 0.4. We also reported previously¹⁵ that patients whose final visual acuities were less than 0.2 showed statistically significant amounts of virus in the ocular fluids. The viruses may be extensively replicative in affected eyes. The higher viral load in patients with a more fluminate type of ARN may be responsible for the appearance of artefacts by PCR. However, we adjusted the DNA concentrations of the samples as much as possible (Table 1). We believe that the results were not influenced by the DNA concentration.

We also could not exclude the possibility that these multiple bands were derived from multiple VZV strains that may have been reactivated during the course of the disease. Hondo and coworkers²⁷ also reported that more than one latent virus may have been reactivated, but only a subset of whole viruses were recovered owing to an inefficiency in isolating VZV from clinical samples. The sensitive methods of nested PCR may amplify almost all of the VZV genome in the ocular samples, which have failed to be amplified by any previous culture system.

As shown in Table 1, four of six patients with final visual acuities less than 0.2, had a history of VZV dermatitis (cases 7, 8, and 10) or surgery of the sphenoidal sinus (case 9) resulted in optic atrophy in the affected eye (Table 1). Immunosuppression may have affected the amount of viral replication.

Divergences were prominent in the R1 variable region when the results were compared with those of the R5 elements. Hondo and coworkers speculated that each component of the R5 region was longer than that of R1 (88 and 24 in R5 and 18, 15 and 3 in R1 regions, respectively), so the R5 region may be more stable than the shorter R1 region. Our results also appeared to support this theory.

The sensitivity of the primer sets of the R1 region was determined by limiting dilution using a T vector containing the target sequences of VZV-1R1, VZV-1R2, VZV-1R3, and VZV-1R4. The primer sets amplified the VZV genome down to about 10^4 copies. Conversely, the primer sets of VZV-1 and VZV-2 amplified the VZV genome down to 6×10^2 copies (data not shown). Patients who could not show amplification in the variable regions, in spite of successful amplification by VZV-1 and VZV-2, may be re-examined through an arrangement of the primer preparation.

The patients in this study were from either Miyagi prefecture or an adjacent region. If we separate the strains using both R1 and R5 variable regions in combination with the multiple PCR products in the R1 region, almost all of the patients in our study showed different strains. Interestingly, no patient had the same strain as the European Dumas type or the H-S1, H-N3, and YS strains from Japan. Although we could distinguish no clinical characteristics from the VZV strain, the results suggested that patients with a more fulminant type of ARN may have diverse virus with extensive replication in the ocular fluids than those with mild clinical appearance.

The authors would like to thank Ms Maxine A Gere for checking the manuscript.

- Herpesvirus Study Group of the International Committee for the Nomenclature of Viruses. Provisional classification of herpesviruses. IARC Scientific Publications. 1978;1079-82.
- Davison AJ, Scott JE. The complete DNA sequence of varicella-zoster virus. *J Gen Virol* 1986;67:1759-816.
- Kinoshita H, Hondo R, Taguchi F, et al. Variation of R1 repeated sequence present in open reading frame 11 of varicella-zoster virus strains. *J Virol* 1988;62:1097-100.
- Hawrami K, Harper D, Breuer J. Typing of varicella zoster virus by amplification of DNA polymorphisms. *J Virol Methods* 1996;57:169-74.
- Martin JH, Dohner DE, Wellinghoff WJ, et al. Restriction endonuclease analysis of varicella-zoster vaccine virus and wild-type DNAs. *J Med Virol* 1982;9:69-76.
- De Boer JH, Luyendijk L, Rothova A, et al. Detection of intraocular antibody production to herpesviruses in acute retinal necrosis syndrome. *Am J Ophthalmol* 1994;117:201-10.
- Gerling J, Neumann-Haefelin D, Seuffert HM, et al. Diagnosis and management of the acute retinal necrosis syndrome. *Ger J Ophthalmol* 1992;1:388-93.
- Nishi M, Hanashiro R, Mori S, et al. Polymerase chain reaction for the detection of the varicella-zoster genome in ocular samples from patients with acute retinal necrosis. *Am J Ophthalmol* 1992;114:603-9.
- Livir-Rallatos C, El-Shabrawi Y, Zairakis P, et al. Recurrent nodular scleritis associated with varicella zoster virus. *Am J Ophthalmol* 1998;126:594-7.
- Beards G, Graham C, Pillay D. Investigation of vesicular rashes for HSV and VZV by PCR. *J Med Virol* 1998;54:155-7.
- Abe T, Tsuchida K, Tamai M. A comparative study of the polymerase chain reaction and local antibody production in acute retinal necrosis syndrome and cytomegalovirus retinitis. *Graefes Arch Clin Exp Ophthalmol* 1996;34:419-24.
- Peyman GA, Goldberg MF, Uninsky E, et al. Vitrectomy and intravitreal antiviral drug therapy in acute retinal necrosis syndrome. Report of two cases. *Arch Ophthalmol* 1984;102:1618-21.
- Urayama A, Yamada N, Sasaki T, et al. Unilateral acute uveitis with retinal periarthritis and detachment. *Jpn J Clin Ophthalmol* 1971;25:607-17.
- Matsuo T, Morimoto K, Matsuo N. Factors associated with poor visual outcome in acute retinal necrosis. *Br J Ophthalmol* 1991;75:450-4.
- Abe T, Sato M, Tamai M. Correlation of varicella-zoster virus copies and final visual acuities of acute retinal necrosis. *Graefes Arch Clin Exp Ophthalmol* 1998;36:747-52.
- Buchman TG, Roizman B, Adams G, et al. Restriction endonuclease fingerprinting of herpes simplex virus DNA: a novel epidemiological tool applied to a nosocomial outbreak. *J Infect Dis* 1978;138:488-98.
- Buchman TG, Roizman B, Nahmias AJ. Demonstration of exogenous genital reinfection with herpes simplex virus type 2 by restriction endonuclease fingerprinting of viral DNA. *J Infect Dis* 1979;140:295-304.
- Shoji H, Honda Y, Murai I, et al. Detection of varicella-zoster virus DNA by polymerase chain reaction in cerebrospinal fluid of patients with herpes zoster meningitis. *J Neurol* 1992;239:69-70.
- Takada M, Suzutani T, Yoshida I, et al. Identification of varicella-zoster virus strains by PCR analysis of three repeat elements and a PstI-site-less region. *J Clin Microbiol* 1995;33:658-60.
- Holland GN. Standard diagnostic criteria for the acute retinal necrosis syndrome. Executive Committee of the American Uveitis Society. *Am J Ophthalmol* 1994;117:663-7.
- Schaeffer HJ, Beauchamp L, de Miranda P, et al. 9-(2-Hydroxyethoxymethyl) guanine activity against viruses of the herpes group. *Nature* 1978;272:583-5.
- Rochat C, Polla BS, Herbolt CP. Immunological profiles in patients with acute retinal necrosis. *Graefes Arch Clin Exp Ophthalmol* 1996;34:547-52.
- Tamai M, Nakazawa M. A collection system to obtain vitreous humor in clinical cases. *Arch Ophthalmol* 1991;109:465-6.
- Ostrove JM. Molecular biology of varicella zoster virus. *Adv Virus Res* 1990;38:45-98.
- Hondo R, Yogo Y. Strain variation of R5 direct repeats in the right-hand portion of the long unique segment of varicella-zoster virus DNA. *J Virol* 1988;62:2916-21.
- Hayakawa Y, Toriogoe S, Shiraki K, et al. Biologic and biophysical markers of a live varicella vaccine strain (Oka): identification of clinical isolates from vaccine recipients. *J Infect Dis* 1984;149:956-63.
- Hondo R, Yogo Y, Kurata T, et al. Genome variation among varicella-zoster virus isolates derived from different individuals and from the same individuals. *Arch Virol* 1987;93:1-12.
- Takahashi M, Okuno Y, Otsuka T, et al. Development of a live attenuated varicella vaccine. *Biken J* 1975;18:25-33.
- Schirm J, Meulenber JJ, Pastoor GW, et al. Rapid detection of varicella-zoster virus in clinical specimens using monoclonal antibodies on shell vials and smears. *J Med Virol* 1989;28:1-6.



Variable R1 region in varicella zoster virus in fulminant type of acute retinal necrosis syndrome

Toshiaki Abe, Masami Sato and Makoto Tamai

Br J Ophthalmol 2000 84: 193-198

doi: 10.1136/bjo.84.2.193

Updated information and services can be found at:

<http://bjo.bmj.com/content/84/2/193.full.html>

These include:

References

This article cites 27 articles, 9 of which can be accessed free at:

<http://bjo.bmj.com/content/84/2/193.full.html#ref-list-1>

Article cited in:

<http://bjo.bmj.com/content/84/2/193.full.html#related-urls>

Email alerting service

Receive free email alerts when new articles cite this article. Sign up in the box at the top right corner of the online article.

Topic Collections

Articles on similar topics can be found in the following collections

[Retina](#) (1217 articles)

Notes

To request permissions go to:

<http://group.bmj.com/group/rights-licensing/permissions>

To order reprints go to:

<http://journals.bmj.com/cgi/reprintform>

To subscribe to BMJ go to:

<http://group.bmj.com/subscribe/>