

# Genetic heterogeneity in familial exudative vitreoretinopathy; exclusion of the EVR1 locus on chromosome 11q in a large autosomal dominant pedigree

M A Bamashmus, L M Downey, C F Inglehearn, S R Gupta, D C Mansfield

## Abstract

**Background/claims**—Familial exudative vitreoretinopathy (FEVR) is associated with mutations in the Norrie disease gene in X linked pedigrees and with linkage to the EVR1 locus at 11q13 in autosomal dominant cases. A large autosomal dominant FEVR family was studied, both clinically and by linkage analysis, to determine whether it differed from the known forms of FEVR.

**Methods**—Affected members and obligate gene carriers from this family were examined by slit lamp biomicroscopy, indirect ophthalmoscopy, and in some cases fluorescein angiography. Patient DNAs were genotyped for markers at the EVR1 locus on chromosome 11q13.

**Results**—The clinical evaluation in this family is consistent with previous descriptions of FEVR pedigrees, but linkage analysis proves that it has a form of FEVR genetically distinct from the EVR1 locus on 11q.

**Conclusion**—This proves that there are at least three different loci associated with comparable FEVR phenotypes, a situation similar to that existing for many forms of retinal degeneration.

(Br J Ophthalmol 2000;84:358-363)

Familial exudative vitreoretinopathy (FEVR) is a hereditary ocular disorder first described by Criswick and Schepens in 1969.<sup>1</sup> The disease is characterised by bilateral deficient vascularisation of the peripheral retina, although the phenotype is variable. Retinal traction may occur in a mild form with straightening of the temporal retinal vasculature, or in a moderate form which distorts and displaces the macula and large retinal blood vessels around the optic disc, or it may be severe enough to cause retinal folds and detachment. There can be subretinal or intraretinal exudation, and fibrovascular proliferation may occur at the junction between vascularised and non-vascularised retina. Other possible features include rhegmatogenous retinal detachments, peripheral “snowflake vitreous changes and “white without (and with) pressure”.<sup>1-4</sup> FEVR is frequently asymmetrical and the eye with the milder phenotype may show an avascular area at the extreme periphery as the only abnormal finding.<sup>2-6</sup> Patients with these mild changes in both eyes are asymptomatic and careful fundus

examination together with peripheral fundus fluorescein angiography are required before an individual can be classified as normal.<sup>5</sup>

Little is known of the pathogenesis of the condition, although failure of peripheral vascularisation is a consistent feature. Even patients with subtle phenotypes exhibit this, suggesting that the underlying genetic defect prevents normal induction of developing vasculature.<sup>5</sup> The phenotypic similarities between FEVR and retinopathy of prematurity (ROP) have been extensively documented.<sup>1</sup> The latter is a condition thought to result in part from high oxygen tension during the neonatal period, causing defective peripheral retinal vascularisation, which in turn leads to fibrovascular proliferation and retinal traction. Similarity between the two conditions further implicates genes related to normal vasculogenesis in FEVR.

Following the initial description of FEVR in 1969, Gow and Oliver demonstrated autosomal dominant inheritance<sup>7</sup> and for some time this was thought to be the only pattern of inheritance. More recently, FEVR pedigrees with X linked inheritance have been documented<sup>8-9</sup> and mutations in the Norrie disease gene (Xp11.4-p11.3) have been identified in some of these.<sup>10-11</sup> However, all pedigrees with an autosomal dominant pattern have to date been linked to one locus, designated EVR1, on 11q13-23, immediately adjacent to marker D11S873.<sup>12-13</sup> In a letter to the editor in the *American Journal of Medical Genetics* Shastry and Trese described an autosomal recessive FEVR pedigree in which linkage analysis excludes both the 11q13 and Xp11.3 loci.<sup>14</sup> Unfortunately, the pedigree described was small, the mode of inheritance was unclear, and the letter did not give details of the linkage studies performed so it is difficult to assimilate the data from these authors with the current literature. De Crecchio *et al* recently confirmed the existence of autosomal recessive inheritance in two pedigrees with FEVR and noted an earlier onset and more severe phenotype in these patients, but genetic analysis was not performed.<sup>15</sup>

The region of 11q implicated by linkage studies in autosomal FEVR pedigrees is notoriously gene rich<sup>16-17</sup> and is known to harbour genes involved in a range of retinal diseases. The genes for Best's disease (bestrophin<sup>18</sup>), oculocutaneous albinism (tyrosinase<sup>19</sup>), autosomal dominant/digenic retinitis pigmentosa (ROM1<sup>20-21</sup>), and Usher's

Molecular Medicine Unit, CSB, St James's University Hospital, Leeds University, Leeds

M A Bamashmus  
L M Downey  
C F Inglehearn

Department of Ophthalmology, Inverclyde Royal Hospital, Greenock  
M A Bamashmus  
S R Gupta  
D C Mansfield

Correspondence to:  
Dr Chris Inglehearn,  
Molecular Medicine Unit,  
Clinical Sciences Building,  
St James's University  
Hospital, Leeds LS9 7TF

Accepted for publication  
8 December 1999

syndrome (myosin 7A<sup>22</sup>), together with loci for Bardet Biedel syndrome<sup>23</sup> and autosomal dominant inflammatory vitreoretinopathy (ADNIV<sup>24</sup>), all map to a region spanning approximately 40 cM of 11q13–14. The latter condition is characterised by peripheral retinal arteriolar occlusion with coexistent retinal pigmentation and neovascularisation. Vitreous cells and a reduced B wave amplitude of the electroretinogram are also prominent features.<sup>25</sup> It shares some vascular features with FEVR and the proximity of the loci has led to speculation that these two diseases may be allelic.<sup>13 24</sup>

We have been able to demonstrate exclusion of the FEVR locus on 11q (designated EVR1) by linkage analysis in a large autosomal dominant FEVR pedigree. Linkage analysis examines the pattern of inheritance of variable portions of DNA known as microsatellite markers which derive from the region of interest (in this case chromosome 11q). The microsatellites are amplified using the polymerase chain reaction (PCR) then size fractionated on an acrylamide gel. Linkage analysis then tests the hypothesis that each person carrying the mutation has inherited the same copy of each respective variable microsatellite marker. If the answer is positive then it is likely that the mutated gene is located close to that particular marker. If, on the other hand, the answer is negative then this proves that mutation and marker lie far apart or on different chromosomes. Two point linkage analysis compares pattern of inheritance of the disease with a single microsatellite

marker, while multipoint analysis tests for co-inheritance of the disease with a series of such markers covering a known chromosomal region. A detailed description of the methodology is available in *Human Molecular Genetics*.<sup>26</sup>

In the case of this family we have provided the first conclusive evidence for genetic heterogeneity in autosomal FEVR using linkage analysis. Clinical evaluation of this pedigree shows features typical of FEVR and this finding therefore has significance for the genetic counselling of patients, as well as for our understanding of the aetiology of FEVR.

### Materials and methods

The entire pedigree of this autosomal dominant FEVR family is shown in Figure 1A. Individuals were included for genetic analysis if a comprehensive ocular examination had taken place and a blood sample had been obtained by informed consent. This subset of both affected and unaffected individuals is shown in Figure 1B with haplotypes for 11q markers displayed beneath each symbol. Individuals included in this subset were examined by slit lamp biomicroscopy and indirect ophthalmoscopy, often at sequential visits and in some cases over a period of 15 years. Fluorescein angiography was performed on several individuals with informed consent, but was not routinely carried out on all family members studied. Its usage was mainly confined to individuals in the family with a mild phenotype where the diagnosis would otherwise have been in doubt.

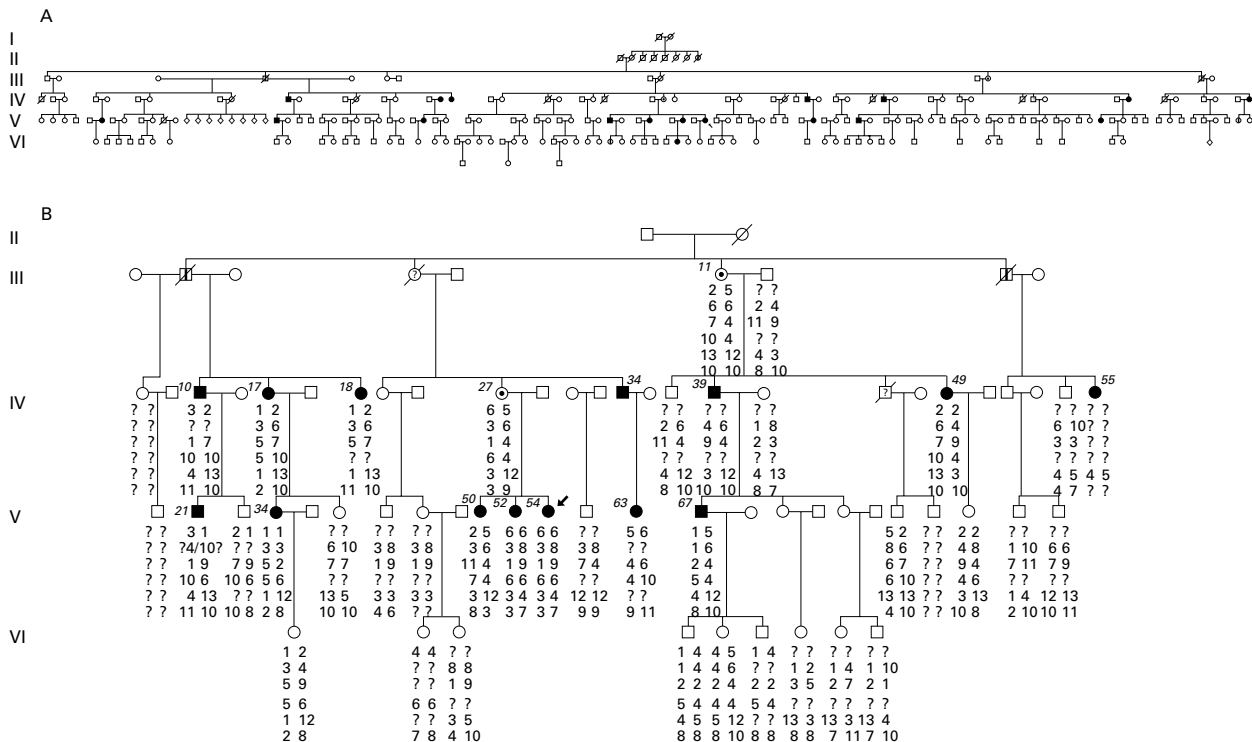


Figure 1 The pedigree of the familial exudative vitreoretinopathy (FEVR) family described, segregating autosomal dominant FEVR, drawn using the program CYRILLIC 2. (A) A complete family tree, but many of the apparently normal individuals have not been examined by an ophthalmologist and the subtle nature of the FEVR phenotype in some cases is such that carrier status cannot be excluded. Solid symbols are confirmed as affected by clinical examination, those marked with a vertical line are said to be or to have been affected, those marked with a dot are asymptomatic obligate carriers, and those marked with a question mark have an uncertain diagnosis which is being investigated further. (B) A subset of (A) which has been subject to genetic analysis, and haplotypes for 11q markers are given below each symbol (reading downwards the haplotypes are obtained from markers D11S916, D11S527, D11S937, D11S1396, D11SS873, and D11S876). Affected individuals are also numbered (*italics*) to correspond with (A) and with Table 1.

Genomic DNA was extracted from peripheral blood lymphocytes of family members. Microsatellite markers spanning the 11q13–14 region were typed in these genomic DNA samples by PCR with incorporation of  $^{32}\text{P}$  labelled cytosine, followed by size fractionation on 6% polyacrylamide denaturing gels. For most markers a standard cycling profile of 30–35 cycles at 94°C, 55°C, and 72°C was used, with 30 seconds at each step. Allele frequencies were estimated from panels of 10 or more normal individuals including normal partners of patients. Penetrance was assumed to be 80% to allow for the possibility that some apparently normal individuals might in fact be carriers. Lod scores were calculated from data files prepared on the LINKSYS (version 3.1) data management package then transferred to the LINKAGE (version 5.1) suite of programs where two separate multipoint linkage analyses were performed using the program LINKMAP. Marker order and positioning were derived from several mapping sources<sup>12 13 24 27–29</sup> and were taken as fixed while the position of any mutated gene was queried. Linkage analysis was carried out both on a PC and on the Human Genome Mapping Project Resources Centre computing facility.

## Results

### CLINICAL EVALUATION

The autosomal dominant pedigree studied here is shown in full in Figure 1A. This family includes six males who are known to be or to have been affected, and 12 clinically affected females plus two asymptomatic females (obligate carriers). Both males and females exhibit a spectrum of abnormalities from mild to severe, and four instances of male to male transmission are seen excluding X linked inheritance. The proband (V54) was initially examined with a small right convergent squint together with mild hypermetropia at the age of 3½.

Aged 7 she had visual acuities of 6/12 (right) and 6/6 (left). Retinal traction subsequently developed and 6 months later she had inferior displacement of the right macula and a peripheral retinal mass inferotemporally in the same eye. Bilateral pseudoptosis aged 8 years was suggestive of inferior traction at both maculae. At 9 years, bilateral retinal folds were present, worse in the left eye, followed by deterioration in visual acuity to 6/36 over the next 2 years. Aged 15 she managed acuities of 6/18 with the right eye but could only count fingers with the left. A diagnosis of FEVR without exudation was made at age 19 years. Tractional retinal detachment was present in both eyes and was progressive in the right. This was treated by vitrectomy, segmentation of the retinal fold, and endophotocoagulation. Her visual acuity postoperatively has remained stable in this eye at 6/9 for the past 10 years. Figure 2 shows recent retinal photographs of the proband. The proband's elder brother had previously been noted to have similar retinal traction and recurrent vitreous haemorrhage but FEVR was not diagnosed at the time of his consultation.

The clinical appearance of FEVR in this family was found to vary greatly from individual to individual, with some patients manifesting only mild abnormalities of the peripheral retinal vasculature while others progressed rapidly to rhegmatogenous and/or tractional retinal detachment. A summary of the fundus appearance of all affected individuals can be seen in Table 1.

In general, the phenotype concurred closely with descriptions of FEVR in the literature.<sup>1 5 6</sup> Several severely affected individuals presented in childhood with decreased visual acuity due to macula traction. One female child (V34) had an extensive retrolenticular fibrovascular mass that resulted in enucleation to exclude retinoblastoma. Fluorescein angiography was not performed routinely on apparently

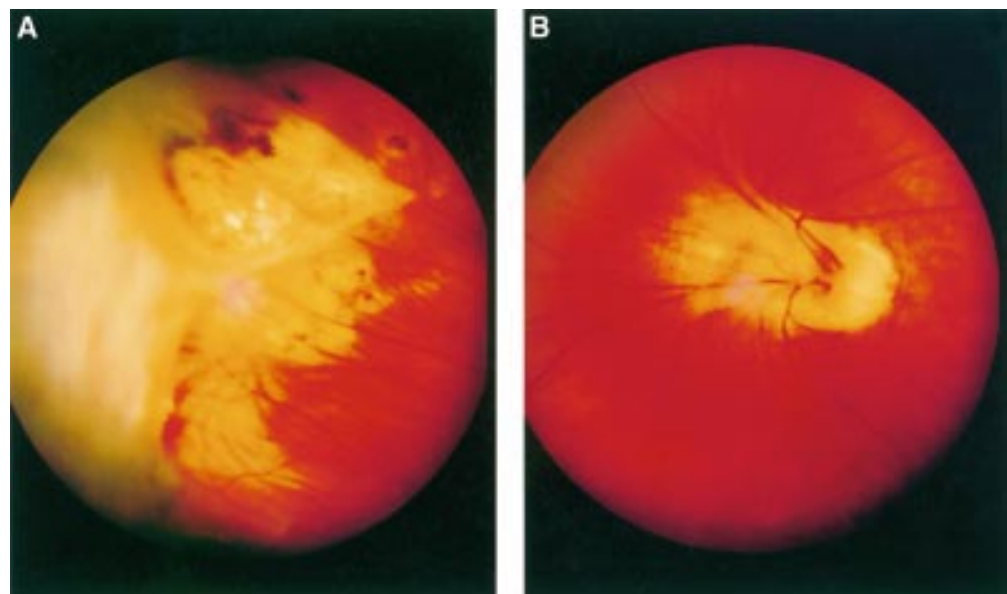


Figure 2 Fundus photographs of the left and right eyes of the proband. (A) Right eye: temporal periphery shows white preretinal mass with retinal traction. This eye has previously undergone a pars plana vitrectomy together with endophotocoagulation (the scars from which can also be seen here). (B) Left eye: distortion of major retinal vessels at the optic disc due to vitreoretinal traction.

Table 1 Summary of clinical features of the affected family members (examined to date)

Pedigree No	Age	Sex	VA RE LE	Exudate	Vitreous bands	Fibrovascular mass	Retinal				Dragged disc/ macula
							Holes	Detachment	Schisis	Peripheral avascularity	
IV17	61	F	6/60 6/24		+	+		+		+	
IV18	64	F	POL 6/18					+			
IV39	70	M	1/60 POL			+					
IV49	43	F	6/18 HM	+	+	+			+		+
IV34		M	6/6 6/18						+		
IV55	54	F	POL 6/18				+	+			
V6	56	F	CF 6/36		+	+					
V34	38	F	A/E 6/36	+	+	+	+	+			+
V50	41	F	6/6 6/6				+		+		+
V52	37	F	6/6 6/6				+				
V54	30	F	6/6 6/60		+	+		+			+
V63	29	F	6/6 6/9	+		+				+	+
V88	33	F	6/6 6/6		+			+			
VI39	11	F	1/60 6/60			+					+
V47		M			+	+					+
V67	49	M	6/36 HM	+				+		+	

unaffected individuals with the consequence that the allocation of a normal phenotype is difficult. Allowance for this was made during subsequent genetic analysis. One obligate female carrier (V52) showed no signs of peripheral avascularity, nor of traction, to direct examination (fluorescein angiography was declined). She did however have several holes in each retina, a feature seen in four other affected family members with other features of FEVR. The appearance of retinal holes in iso-

lation would not normally meet the usual diagnostic criteria for FEVR and this may be an unusually prevalent feature of FEVR in this family.

#### LINKAGE ANALYSIS

A subset of the complete pedigree (Fig 1B), was subjected to linkage analysis with markers from the 11q region previously implicated in FEVR. Haplotypes for polymorphic markers spanning a 25 cM region of chromosome 11q

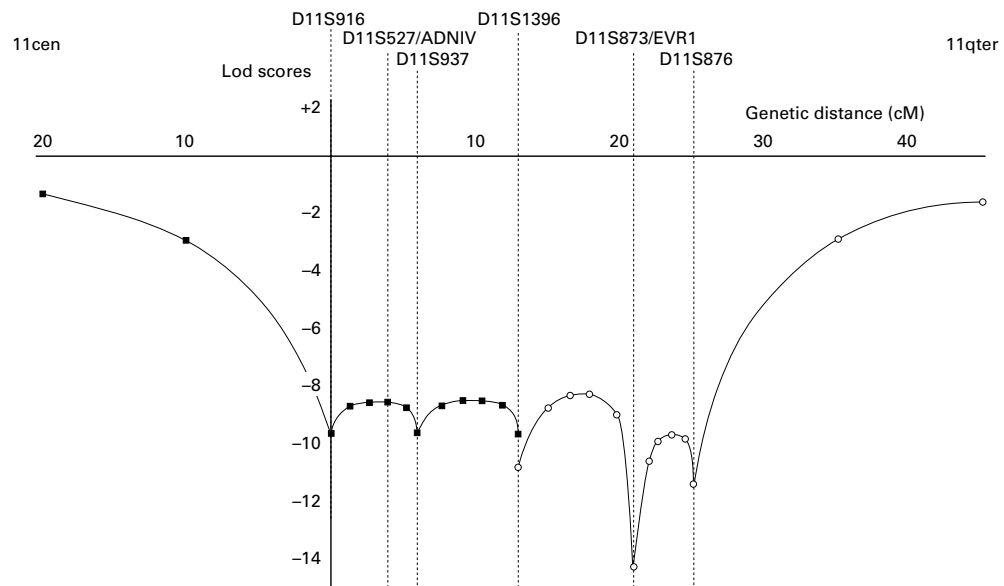


Figure 3 Multipoint lod scores from two separate analyses carried out on data from this pedigree, using the program LINKMAP, from the LINKAGE suite of programs. Penetrance was assumed to be 80% to allow for the possibility that some apparently normal individuals might in fact be carriers. The first analysis (points for which are marked as solid squares) used data from markers D11S916, D11S937, and D11S1396 against disease status. The second, which overlaps the first and is marked as a series of open circles, uses data from D11S1396, D11S873, and D11S876. Approximate positions of the EVR1 FEVR locus and the VRN1 ADNIV locus are shown above. Distances are a composite of those derived from several mapping sources.<sup>12 13 24 27-29</sup> Genetic distances along the Y axis are given in centimorgans (cM) from marker D11S916.

are shown in Figure 1. Markers and distances used are as follows; CEN, D11S916, 4 cM; D11S527, 2 cM; D11S937, 7 cM; D11S1396, 8 cM; D11S873, 4 cM; D11S876, TEL. These distances are composites derived from several sources.<sup>12 13 24 27-29</sup> Two point lod scores for these markers show convincing exclusion of linkage (data not shown). Multipoint analysis with all of these markers was too complex to compute. However, two overlapping multipoint analyses, plotted in Figure 3, show statistically significant exclusion (lod score of  $<-8$ ) across the entire interval spanned by these markers, as well as excluding linkage (lod score  $<-2$ ) for 15 cM proximal to D11S916 and 16 cM distal to D11S876 (using the Kosambi mapping function). These analyses exclude both the EVR1 (FEVR) and VRN1 (ADNIV) loci in this family.

### Discussion

The clinical evaluation in this family is consistent with previous descriptions of FEVR pedigrees.<sup>1 5 6</sup> However, we present evidence that this family has a form of FEVR that is genetically distinct from both the EVR1 and ADNIV loci on 11q13. The latter condition was initially considered in view of previous speculation that this disorder and FEVR may prove to be allelic.<sup>13 24</sup> However, a close review of the literature makes this appear unlikely. ADNIV has been shown to link closely to D11S527 (Zmax 9.86 at theta = 0).<sup>24</sup> Initial results for the FEVR locus suggested a location between D11S527/D11S533 and D11S35 with a multipoint linkage analysis pointing to a location approximately 10 cM south of D11S527.<sup>12</sup> This result was published as linkage to D11S527 at a time when markers across the region were scarce. The same group later placed the locus more accurately by publishing close linkage with D11S873 (lod score of 8.34 with no recombination). This refinement, together with the multipoint linkage data already cited suggests that the published FEVR locus is actually some 15 cM south of that for ADNIV.<sup>27</sup>

The discovery of an autosomal dominant pedigree excluding the known locus at 11q provides important evidence for the genetic heterogeneity of FEVR. As a result there are now known to be at least three different loci (and now this pedigree<sup>8 9 12 13</sup>) associated with comparable FEVR phenotypes, a situation similar to that existing for many forms of retinal degeneration.<sup>30</sup> In our opinion there are only two possible phenotypic variations from the "classic" description of FEVR in this pedigree. The first is the relatively infrequent occurrence of retinal exudation in affected individuals. While deficient vascularisation of the peripheral retina is a constant feature of FEVR even in asymptomatic individuals only a proportion of patients go on to develop hyper-permeable vessels with subsequent exudation.<sup>6</sup> The staging system developed by Gow and Oliver<sup>7</sup> describes exudation as an occasional feature in stage 1 FEVR (relatively mild) and a common feature in stage 2 (moderate) disease. Given that several affected individuals in our

pedigree have an eye with visual acuity of 6/36 or less the phenotype here seems relatively severe and exudation would be expected as a more frequent finding. This however remains a clinical impression.

Patients with FEVR commonly experience both rhegmatogenous and non-rhegmatogenous retinal detachments.<sup>31</sup> The causative breaks are frequently small round holes reported in association with avascular retina<sup>32</sup> or areas of traction. A second variation from classic FEVR in this pedigree was that such holes were often noted in peripheral retina when this appeared otherwise normal; indeed in one individual (V52), they were the only positive finding in an obligate carrier. Three other affected individuals had similar retinal holes and these were not seen in any of the normal family members examined. The appearance of retinal holes in isolation would not normally meet the usual diagnostic criteria for FEVR. It may be that retinal holes are an unusually prevalent feature of FEVR in this family. However, a comparison with other pedigrees published is problematic as these are often much smaller than the family described here. It is therefore possible that other studies have not examined many apparently "normal" asymptomatic family members and that to do so would increase the frequency with which these types of holes are documented.

Candidate genes at the FEVR loci would be expected to have a role in vasculogenesis or possibly play a role in photoreceptor differentiation, which subsequently induces vasculogenesis.<sup>9</sup> Further studies of this and other FEVR pedigrees, including ongoing clinical examination, further DNA sampling, and whole genome linkage analysis, will help to identify new genes with important functions in retinal vasculogenesis or retinal development. These in turn will facilitate a greater understanding of normal eye development and may have implications for other more common diseases of the retinal vasculature such as retinopathy of prematurity and diabetic retinopathy.

We gratefully acknowledge the contributions made by Dr P N Paramanatham, Professor D McLeod, Dr J Dudgeon, Mr N C Andrew, and Mr R C Pearce to the clinical care of patients from the family. Thanks also to Professor Kirkness for research support to MAB and to Miss R Wood for secretarial assistance to DCM. Finally, our thanks the Wellcome Trust (grant numbers 055145/Z/98) and 035535/Z/96) for funding this research.

M A Bamashmus and L M Downey contributed equally to this work.

- 1 Criswick VG, Schepens CL. Familial exudative vitreoretinopathy. *Am J Ophthalmol* 1969;68:578-94.
- 2 Ebert EM, Mukai S. Familial exudative vitreoretinopathy. *Int Ophthalmol Clinics* 1993;33:237-47.
- 3 Boldrey EE, Egbert P, Gass DM, et al. The histopathology of familial exudative vitreoretinopathy. *Arch Ophthalmol* 1985;103:238-41.
- 4 Miyakubo H, Hashimoto K, Miyakubo S. Retinal vascular pattern in familial exudative vitreoretinopathy. *Ophthalmology* 1984;91:1524-30.
- 5 Ober RR, Bird AC, Hamilton AM, et al. Autosomal dominant exudative vitreoretinopathy. *Br J Ophthalmol* 1980;64:112-20.
- 6 Benson WE. Familial exudative vitreoretinopathy. *Trans Am Ophthalmol Soc* 1995;93:473-521.
- 7 Gow J, Oliver GL. Familial exudative vitreoretinopathy. *Arch Ophthalmol* 1971;86:150-5.
- 8 Shastry BS, Hejmanik JF, Plager DA, et al. Linkage and candidate gene analysis of X-linked familial exudative vitreoretinopathy. *Genomics* 1995;27:341-4.

- 9 Fullwood P, Jones J, Bunday S, *et al*. X-linked exudative vitreoretinopathy: clinical features and genetic linkage analysis. *Br J Ophthalmol* 1993;77:168-70.
- 10 Chen Z-Y, Battinelli EM, Fielder A, *et al*. A mutation in the Norrie disease gene (NDP) associated with X-linked familial exudative vitreoretinopathy. *Nat Genet* 1993;5:180-3.
- 11 Shastry BS, Hejtmancik JF, Trese MT. Identification of novel missense mutations in the Norrie disease gene associated with one X-linked and four sporadic cases of familial exudative vitreoretinopathy. *Hum Mut* 1994;9:396-401.
- 12 Li Y, Muller B, Fuhrmann C, *et al*. The autosomal dominant familial exudative vitreoretinopathy locus maps on 11q and is closely linked to D11s533. *Am J Hum Genet* 1992;51:749-54.
- 13 Muller B, Orth U, Van Nouhuys, *et al*. Mapping of autosomal dominant exudative vitreoretinopathy locus (EVR1) by multipoint linkage analysis in four families. *Genomics* 1994;20:317-9.
- 14 Shastry BS, Trese MT. Familial exudative vitreoretinopathy: further evidence for genetic heterogeneity. *Am J Med Genet* 1997;69:217-8.
- 15 De Crecchio G, Simonelli F, Nunziata G. Autosomal recessive familial exudative vitreoretinopathy: evidence for genetic heterogeneity. *Clin Genet* 1998;54:315-20.
- 16 <http://www.ncbi.nlm.nih.gov/genemap/>
- 17 Inglehearn CF. Intelligent linkage analysis using gene density estimates. *Nat Genet* 1997;16:15.
- 18 Stone EM, Nichols BE, Streb LM, *et al*. Identification of the gene responsible for Best macular dystrophy. *Nat Genet* 1998;19:241-7.
- 19 Gershonibaruch R, Rosenmann A, Droetto S, *et al*. Mutations of the tyrosinase gene in patients with oculocutaneous albinism from various ethnic groups in Israel. *Am Hum Genet* 1994;54:586-94.
- 20 Kajiwarra K, Berson EL, Dryja TP. Digenic retinitis pigmentosa due to mutations at the unlinked peripherin/RDS and ROM1 loci. *Science* 1994;264:1604-8.
- 21 Bascom RA, Liu L, Heckenlively JR, *et al*. Mutation analysis of the ROM1 gene in retinitis pigmentosa. *Hum Mol Genet* 1995;4:1895-902.
- 22 Smith RJH, Lee EC, Kimberling WJ, *et al*. Localisation of 2 genes for Usher syndrome type-1 to chromosome 11. *Genomics* 1992;14:995-1002.
- 23 Leppert M, Baird L, Anderson KL, *et al*. Bardet-Biedel syndrome is linked to DNA markers on chromosome 11q and is genetically heterogenous. *Nat Genet* 1994;7:108-10.
- 24 Stone EM, Kimura A, Folk JC, *et al*. Genetic linkage of autosomal dominant neovascular inflammatory vitreoretinopathy to chromosome 11q13. *Hum Mol Genet* 1992;1:685-9.
- 25 Bennett SR, Folk JC, Kimura AE, *et al*. Autosomal dominant neovascular inflammatory vitreoretinopathy. *Ophthalmology* 1990;97:1125-37.
- 26 Strachan T, Read AP. *Human molecular genetics*. USA: Bios Scientific Publishers, 1997;Ch 12.
- 27 [www.marshmed.org/genetics](http://www.marshmed.org/genetics)
- 28 <http://www.genethon.fr/genethon>
- 29 Espinos C, Najera C, Millan JM, *et al*. Linkage analysis in Usher syndrome type 1 (USH1) families from Spain. *J Med Genet* 1998;35:391-8.
- 30 Inglehearn CF. Molecular genetics of human retinal dystrophies. *Eye* 1998;12:571-9.
- 31 Miyakubo H, Inohara N, Hashimoto K. Retinal involvement in familial exudative vitreoretinopathy. *Ophthalmologica* 1982;185:125-35.
- 32 Van Nouhuys CE. Dominant exudative vitreoretinopathy and other vascular developmental disorders of the peripheral retina. *Doc Ophthalmol* 1982;54:1-414.



## Genetic heterogeneity in familial exudative vitreoretinopathy; exclusion of the EVR1 locus on chromosome 11q in a large autosomal dominant pedigree

M A Bamashmus, L M Downey, C F Inglehearn, et al.

*Br J Ophthalmol* 2000 84: 358-363

doi: 10.1136/bjo.84.4.358

---

Updated information and services can be found at:

<http://bjo.bmj.com/content/84/4/358.full.html>

---

### References

*These include:*

This article cites 26 articles, 7 of which can be accessed free at:

<http://bjo.bmj.com/content/84/4/358.full.html#ref-list-1>

Article cited in:

<http://bjo.bmj.com/content/84/4/358.full.html#related-urls>

### Email alerting service

Receive free email alerts when new articles cite this article. Sign up in the box at the top right corner of the online article.

---

### Topic Collections

Articles on similar topics can be found in the following collections

[Retina](#) (1217 articles)

---

### Notes

---

To request permissions go to:

<http://group.bmj.com/group/rights-licensing/permissions>

To order reprints go to:

<http://journals.bmj.com/cgi/reprintform>

To subscribe to BMJ go to:

<http://group.bmj.com/subscribe/>