

LETTERS TO THE EDITOR

Thyroid eye disease associated with athyria

EDITOR,—The pathogenesis of thyroid eye disease is believed to derive from fibroblast stimulation by cytokines released by activated T lymphocytes. There is evidence of abnormal cell mediated autoimmunity and humoral autoimmunity resulting in infiltration of lymphocytes and adipocytes into the extraocular muscles.¹ The success of therapeutic immunosuppressants (steroids/azathioprine/radiotherapy) strengthens this hypothesis. A single definitive cross reacting (thyroid/retro-orbital) autoantibody has not been identified. Zhang *et al* found that sera from 50% of patients with thyroid eye disease reacted with an eye muscle specific protein of 55 kDa relative molecular weight.² Pittsburgh data showed 67% patients with active Graves' ophthalmopathy have antibodies against a 67 kDa mitochondrial flavoprotein subunit although it has been subsequently found in 20% of controls.³ They also identified a 220 kDa cell membrane specific protein known as G2S specific to eye muscle and thyroid tissue, but antibodies to this have been demonstrated in both thyroid eye disease patients and normal people.⁴ No autoantibody has been demonstrated in every case and all lack specificity. Our case demonstrates that whatever the autoimmune process may be, the presence of normal thyroid tissue or autoimmune disease afflicted thyroid is not essential at the time of onset and development of clinical disease.

CASE REPORT

At age 30, this woman underwent partial thyroidectomy for papillary thyroid cancer. At 36 years she underwent radioactive ablation (2.2 GBq iodine-131) of the residuum for sus-

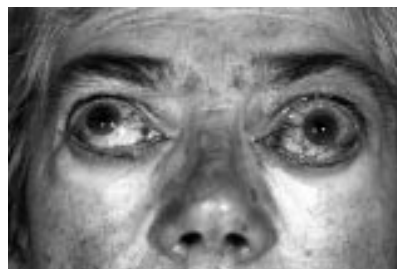

Figure 1 Frontal photograph of patient demonstrating the typical clinical features of thyroid eye disease. Proptosis, lid retraction, chemosis, and ophthalmoplegia are obvious.




Figure 2 Coronal computed tomogram of orbits demonstrating typical hypertrophied ocular muscles, more marked on the left, the more proptotic eye (Fig 1).

pected recurrence. At this time there was no evidence of orbital disease.

At 70 years, she presented with 6 months' diplopia and "puffy, gritty" eyes.

She was clinically euthyroid on thyroxine, with bilateral proptosis (worse on the left) with conjunctival congestion, periorbital oedema, a divergent strabismus (Fig 1) and limitation of upward gaze. A clinical diagnosis of thyroid eye disease was made, which was confirmed by orbital computed tomography (Fig 2).

Both her sister and paternal grandmother had goitres without thyroid eye disease. Her sister had thyroid microsomal antibodies.

INVESTIGATIONS

Normal triiodothyronine 1.44 nmol/l (range 1.2-2.2), mildly elevated thyroxine (174 nmol/l, normal range 58-140) in an attempt to suppress the thyroid stimulating hormone (0.9 mU/l, normal range 0.3-4.0). A technetium-99 uptake scan showed no thyroid remnant. An iodine-123 tracer scan showed borderline evidence of uptake in the thyroid bed but avid uptake in the lower thoracic spine suggesting residual thyroid cancer with a vertebral metastasis. Her serum thyroglobulin was elevated at 28 ng/ml (normal range <1 in athyria) but there were no antithyroglobulin antibodies. Thyroid stimulating hormone antibodies were negative, as were her thyroglobulin antibodies and thyroid microsomal antibodies. All human and porcine retrobulbar autoantigens were negative including the aforementioned 55, 67, and 220 kDa protein antibodies despite the presence of metastatic thyroid tissue. Her general autoantibody profile was negative for antinuclear antibodies, gastric parietal cell, smooth muscle, liver/kidney microsomal, mitochondrial and reticulin. The RA latex was weakly positive and the Rose-Waaler was <1:32.

Her thyroid eye disease was treated with radiotherapy to good effect. Her asymptomatic metastatic thyroid cancer is being treated with radioiodine.

COMMENT

This woman, with a family history of thyroid disease and whose sister has thyroid autoantibodies, has developed thyroid eye disease while possessing no significant normal thyroid tissue for 36 years. She was negative for the full array of routine and experimental thyroid autoantibodies and no other autoimmune disease were demonstrable.

If a humoral mechanism is relevant, than there are several possible explanations; firstly the autoantibody could be related to the sodium-iodine symporter in the thyroid cancer cells. That the recurrent thyroid cancer took up iodine may suggest the sodium-iodine symporter protein was present. An antibody to this protein may be a candidate for the cross reacting autoantibody but is not measured. Against this hypothesis is the fact that her sera

did not cross react with porcine and human thyroid tissue screening test. Secondly, this observation could be explained by a separate or non-specific, non-thyroid specific immune response cross reacting with the orbital muscles to instigate the pathogenic process. More than one autoantibody may be able to produce thyroid eye disease or this may be part of a multifactorial immune process. Further, it is known that the severity of thyroid eye disease is not related to autoantibody titres but rather to environmental factors such as smoking and iatrogenic factors such as radioiodine treatment of thyrotoxicosis.^{5,6}

While we accept that much current interest in the pathogenesis of this disease lies, not with humoral mechanisms, but with a T cell mediated cellular immune response, it is equally pertinent that any such event was initiated and progressed in a patient with athyria.

Our observations in this case are relevant to the understanding of the aetiology of thyroid eye disease in so far as the disease occurred in the presence of differentiated thyroid cancer but in the absence of any normal thyroid tissue or thyroid currently afflicted by autoimmune disease (and absence of any detectable amounts of the panoply of currently measurable serum autoantibodies)—this dissociation has not hitherto been recognised.

P B ROGERS

N GUPTA

Department of Radiotherapy, St Bartholomew's Hospital, London EC1A 7BE

G E ROSE

Moorfield's Eye Hospital, City Road, London EC1V 2PD

P N PLOWMAN

Department of Radiotherapy, St Bartholomew's Hospital, London EC1A 7BE

Correspondence to: Dr P N Plowman

Accepted for publication 8 November 1999

- Jacobson DH, Gorman CA. Endocrine ophthalmopathy: current ideas concerning etiology, pathogenesis, and treatment. *Endocr Rev* 1984;5:200-20.
- Zhang SG, Medeiros-Neto G, Iacona A, *et al*. Studies of cytotoxic antibodies against eye muscle antigens in patients with thyroid-associated ophthalmopathy. *Acta Endocrinol* 1989;121(Suppl 2):23-30.
- Kubota S, Gunji K, Ackrell BAC, *et al*. The 64 kilodalton eye muscle protein is the flavoprotein subunit of mitochondrial succinate dehydrogenase: the corresponding serum autoantibodies are good markers of an immune mediated damage to the eye muscle in patients with Graves' hyperthyroidism. *J Clin Endocrinol Metab* 1998;8:442-7.
- McGregor AM. Has the autoantigen for Graves' ophthalmopathy been found? *Lancet* 1998;352:595-6.
- Prummel MF, Wiersinga WM. Smoking and the risk of Graves' disease. *JAMA* 1993;269:479-82.
- Bartelena L, Marcocci C, Bogazzi F, *et al*. Relation between therapy for hyperthyroidism and the course of Graves' ophthalmopathy. *N Engl J Med* 1998;338:73-8.

Leber's hereditary optic neuropathy and maturity onset diabetes mellitus: is there a metabolic association?

EDITOR,—Leber's hereditary optic neuropathy (LHON) is a maternally inherited mitochondrial disease that results in bilateral visual loss. It primarily affects young men. The typical optic nerve head appearance is one of circum-papillary telangiectatic microangiopathy, swelling of the nerve fibre layer around the optic disc, and the absence of capillary leakage on fluorescein angiography.¹

The mitochondrial inheritance of the disease was confirmed in 1988 by Wallace *et al* who identified a mitochondrial DNA replace-

ment mutation at nucleotide position 11778.² Further mutations have been identified at positions 3460, 14484, and 15257.^{3,4} The 11778 mutation is responsible for 31–89% of LHON pedigrees in Europe, North America, and Australia, while the 3460 and 14484 mutations each account for approximately 10–15% of cases.⁵ The discovery of the molecular basis of LHON has provided insights into the heterogeneous clinical spectrum of disease that may result. Although the causal mutations are established, the pathophysiology of the optic nerve damage is not known. The relation between metabolic dysfunction, such as diabetes mellitus, and the development of Leber's hereditary optic neuropathy has been described only rarely.

Du Bois and Feldon described a case of a 9 year old girl with juvenile onset diabetes mellitus and LHON whose vision recovered once the diabetes was well controlled.⁶ In their series of 49 Leber's pedigrees, Newman *et al* described the case of another 9 year old girl with visual loss due to LHON in the setting of 6 months of unrecognised diabetes mellitus.⁷ These authors suggest that diabetes mellitus may have placed overdue stress on mitochondrial function.

The following case report suggests a relation between the development of non-insulin dependent diabetes mellitus in an adult patient and the expression of Leber's hereditary optic neuropathy.

CASE REPORT

In February 1998, a previously healthy 50 year old man presented with a 5 week history of progressive deterioration of vision in both eyes. He had recently been diagnosed with non-insulin dependent diabetes mellitus. No family history of visual disturbance was elicited. At the time of presentation, his best corrected visual acuities were 3/60 right and 1/60 left. Anterior segment examination was normal and fundal examination revealed subtle swelling of the optic discs. Pupil reactions were normal and there was no nystagmus. He was unable to identify any of the Ishihara pseudoisochromatic plates. Visual field analysis revealed bilateral small central scotomas.

A provisional diagnosis of diabetic optic neuropathy was made. The patient's vision continued to deteriorate and by May 1998, the visual acuities were counting fingers (CF) right and left and he was unable to identify the food on his plate. Anterior segment examination was again normal and fundal examination revealed slight superior disc swelling in both eyes associated with surface capillary dilatation. The visual fields now showed superior defects on both sides in addition to the central scotomata. Magnetic resonance imaging of the brain did not reveal any abnormalities and lumbar puncture was also normal. ERG showed normal photoreceptor function and the VEP results were consistent with his reduced visual acuity. DNA analysis was carried out and the patient was found to be a carrier of the Leber's hereditary optic neuropathy 11778 mutation.

Table 1 Clinical characteristics of the case series

No	Sex	Age (years)	Eye	Indication for LEC	LEC to repairing	Site for LEC	Harvested site	Graft size (DP×DV mm)	Follow up (months)	Last IOP (mm Hg)
1	F	55	R	POAG	10 days	upper	upper	6×5	12	14
2	F	64	L	POAG	4 years	upper	upper	6×5	9	8
3	M	65	R	POAG	4 years	upper nasal	upper	9×5	9	15*
			L	POAG	4 years	upper temporal	upper temporal	9×7	9	15
4	M	63	R	secondary	4 years	upper nasal	upper temporal	10×6	9	17*
			L	secondary	4 years	upper temporal	upper temporal	6×5	6	16

LEC = trabeculectomy, POAG = primary open angle glaucoma, DP = diameter parallel to the limbus, DV = diameter vertical to the limbus, IOP = intraocular pressure. *β blocker treatment.

COMMENT

Leber's hereditary optic neuropathy is known to segregate in a non-mendelian, maternal pattern. It is also evident that other determinants, whether genetic or epigenetic, play a part in disease expression. All the mtDNA mutations associated with LHON alter polypeptides of the mitochondrial oxidative phosphorylation chain which may lead to inhibition of cellular energy production.⁸ Epigenetic factors that may play a part in the expression of LHON include tobacco use,⁸ alcohol abuse,⁹ metabolic disease (especially diabetes mellitus),⁸ and trauma.⁴ Other systemic illnesses including hypertriglyceridaemia and Crohn's disease have also been associated with the disease.^{3,4} It has been hypothesised that these conditions serve to reduce the energy for the cellular requirements of the optic nerve leading to inhibition of the functions which repair and maintain the cell, such as DNA and RNA synthesis and protein turnover. Diabetic optic neuropathy is a recognised, though rare, condition, which must be distinguished from Leber's hereditary optic neuropathy. Diabetic optic neuropathy has been described as a distinct circumscribed syndrome. Patients typically experience mild to moderate visual loss.⁹ The nature of the disc swelling ranges from minimal oedema without haemorrhages to florid swelling with capillary telangiectasia, haemorrhages, and exudates.^{9,10} The neuropathy may be unilateral or bilateral. Fluorescein angiography shows capillary dilatation and extravasation of dye in the region of the disc.^{10,11} Visual field tests may be normal, show enlarged blind spots, or central scotomas.^{10,11} The disc oedema clears with time and vision typically returns to normal or near normal within 6–12 months^{9,11} leaving residual nerve fibre bundle field defects and/or optic atrophy. In cases of suspected diabetic optic neuropathy, with progressive visual loss and circumpapillary capillary dilatation which does not leak on fluorescein angiography, a diagnosis of LHON warrants consideration. This case highlights the possibility that patients labelled in the past as having diabetic optic neuropathy may have had an additional unrecognised Leber's genetic predisposition.

ABOSEDE COLE
GORDON N DUTTON

Department of Ophthalmology, Southern General
Hospital NHS Trust, 1345 Govan Road,
Glasgow G51 4TF

Correspondence to: Dr Cole

Accepted for publication 8 November 1999

- Smith JL, Hoyt WF, Susac JO. Ocular fundus in acute Leber optic neuropathy. *Arch Ophthalmol* 1973;90:349–54.
- Wallace DC, Singh G, Lott MT, *et al*. Mitochondrial DNA mutation associated with Leber's hereditary optic neuropathy. *Science* 1988;242:1427–30.
- Johns DR, Smith KH, Miller NR. Leber's hereditary optic neuropathy, clinical manifestations of the 3460 mutation. *Arch Ophthalmol* 1992;110:1577–81.
- Johns DR, Heher KL, Miller NR, *et al*. Leber's hereditary optic neuropathy, clinical manifesta-

tions of the 14484 mutation. *Arch Ophthalmol* 1993;111:495–8.

- Kerrison JB, Newman NJ. Clinical spectrum of Leber's hereditary optic neuropathy. *Clin Neurosci* 1997;4:295–301.
- Du Bois LG, Feldon SE. Evidence for a metabolic trigger for Leber's hereditary optic neuropathy. *J Clin Neuro-ophthalmol* 1992;12:15–16.
- Newman NJ, Lott M-T, Wallace DC. The clinical characteristics of pedigrees of Leber's hereditary optic neuropathy with the 11778 mutation. *Am J Ophthalmol* 1991;111:750–762.
- Cullom ME, Heher KL, Miller NR, *et al*. Leber's hereditary optic neuropathy masquerading as tobacco-alcohol amblyopia. *Arch Ophthalmol* 1993;111:1482–5.
- Barr CC, Glaser JS. Acute disc swelling in juvenile diabetes, clinical profile and natural history of 12 cases. *Arch Ophthalmol* 1980;98:2185.
- Yanko L, Ticho U, Ivry M. Optic nerve involvement in diabetes. *Acta Ophthalmol* 1972;50:556–64.
- Pavan PR, Aiello LM, Wafai Z, *et al*. Optic disc oedema in juvenile onset diabetes. *Arch Ophthalmol* 1980;98:2193–5.

Free conjunctival autograft harvested from the fornix for repair of leaking blebs

EDITOR,—In a previously reported technique of free conjunctival autograft for the repair of leaking blebs,^{1,2} the distance from the limbus to the harvesting site was not specified. In these reports, the paralimbal conjunctiva could have been excised, which makes future filtration surgery difficult at that site. We believe that even in the contralateral eye or the inferior quadrant of the same eye, paralimbal conjunctiva are sites for potential future filtration surgery in most cases. Buxton *et al* stated that grafts should not be taken from the fornix because this can induce foreshortening and lid malposition if both palpebral and bulbar conjunctiva are excised.¹ We found that grafts can be harvested from the fornix with no complications, thus preserving the potential filtration sites.

CASE REPORTS

In six eyes of four patients, we repaired persistent leaking blebs after trabeculectomy by transplanting free conjunctival autografts harvested from the fornix. Grafts were harvested from the fornix side of the leaking blebs when possible. When the intact conjunctiva of the fornix side of a leaking bleb was very narrow, the graft was harvested from the other quadrant, 5–6 mm away from the limbus. The procedure followed the previously reported technique,^{1,2} except for the site from which the graft was harvested. The aqueous leaks were repaired successfully, and filtering function was maintained in all cases. Two eyes of two patients required β blocker treatment to maintain satisfactory intraocular pressure after the repair surgery. Over an average follow up of 9 months (range 6–12 months), none of the six eyes had any significant complications including either adhesion between palpebral and bulbar conjunctiva or lid malposition. The case series are described in Table 1.

COMMENT

We believe that the optimal site for harvesting conjunctival autografts is the fornix side of the leaking bleb, because it has almost no potential as a future filtration site. The paralimbal conjunctiva of the contralateral eye is often a potential future filtration site, since glaucoma is often bilateral. Even with a diagnosis of "unilateral glaucoma" at the time of bleb reconstruction, the potential for development of glaucoma in the contralateral eye cannot be completely excluded. A persistent bleb leak that requires total reconstruction is frequently encountered in eyes that have undergone multiple procedures² and treatment with adjunctive antimetabolites.^{1,3,4} These situations are mostly encountered in eyes with refractory glaucoma, which often have little intact paralimbal conjunctiva remaining but have a high potential for multiple filtration surgeries. We believe that intact conjunctiva within 5 mm from the limbus is needed to perform a successful filtration surgery. The reported distances of the conjunctival fornix from the limbus are as follows⁵: upper, 8–10 mm; temporal, 14 mm; lower, 8–10 mm; nasal, 7 mm. These data indicate that conjunctiva may be taken from the upper or lower quadrant, and is most easily taken from the temporal quadrant when harvesting a graft 5 mm away from the limbus. No special attention was required to avoid excising the palpebral conjunctiva during this procedure. Excising the palpebral conjunctiva may be technically difficult during this procedure. We conclude that harvesting a graft from the fornix should be considered when reconstruction surgery is performed with free conjunctival autografts for leaking blebs.

DAISUKE MIYAZAWA
TAKEHISA KONDO

Department of Ophthalmology, Kobe City General Hospital, 4-6 Minatogima-nakamachi, Kobe 650-0046, Japan

Correspondence to:

Daisuke Miyazawa, MD, Department of Ophthalmology, Kobe City General Hospital, 4-6 Minatogima-nakamachi, Kobe 650-0046, Japan
Accepted for publication 8 December 1999

- Wilson MR, Kotas-Neumann R. Free conjunctival patch for repair of persistent late bleb leak. *Am J Ophthalmol* 1994;117:569-74.
- Buxton JN, Lavery KT, Liebmann JM, et al. Reconstruction of filtering blebs with free conjunctival autografts. *Ophthalmology* 1994;101:635-9.
- Rockwood EJ, Parrish RK II, Heuer DK, et al. Glaucoma filtering surgery with 5-fluorouracil. *Ophthalmology* 1987;94:1071-8.
- Shields MB, Scroggs MW, Sloop CM, et al. Clinical and histopathologic observations concerning hypotony after trabeculectomy with adjunctive mitomycin C. *Am J Ophthalmol* 1993;116:673-83.
- Duke-Elder S, Wybar KC. *System of ophthalmology: the anatomy of the visual system*. 2nd ed. London: Kimpton, 1961:541-55.

Five cases of thelaziasis

EDITOR.—We report five cases of thelaziasis, including a rare case of infection of a hospital inpatient. Thelaziasis is a nematode infection

of ocular tissue that is caused by *Thelazia callipaeda*, which is found in China, India, Thailand, Korea, and Japan. This parasite has been identified in the conjunctival sac, and lacrimal gland and canal of dogs, cats, cows, badgers, rabbits, foxes, and monkeys in Asia.¹

Thelaziasis results when flies ingest embryonated eggs in the ocular tissue of an infected host; the eggs develop into larvae and are deposited onto the conjunctiva of a new host. *Drosophilae*—namely, *Amioto okadai*, *A magna*, and *A nagatai*, are the intermediate hosts.²

To our knowledge, with the exception of Japan 157 cases have been reported worldwide (China, 124; Korea, 24; Thailand, 5; India, 2; Russia and Indonesia, 1 each). In Japan, approximately 100 cases have been reported, mostly in the western regions, especially in Kyushu (66 cases).^{3,4} To date, there have been no reported cases of inpatient infections.

CASE REPORTS

The clinical features of the five patients are summarised in Table 1. Patients (three men, two women; ages, 57 to 83 years) were examined at Muikaichi Hospital and Tuwanokyouzon Hospital from 1989 to 1999. Patients 1, 2, 3, 4 were outpatients, but patient 5 was an inpatient who had been hospitalised for more than a year. There were no other cases in the same hospital ward or infection of medical personnel. All patients were infected unilaterally (three right eyes, two left eyes). The patients' subjective symptoms were foreign body sensation, visual disorder, and ocular pain. Patient 5 had senile dementia and her symptoms are unknown. Clinical findings were conjunctival congestion, follicles, and whitish worms in the conjunctiva. Patients did not report having had flies in their eyes, but do keep animals such as dogs, cats, and cows. They had never visited the Kyushu region of Japan. The worms were removed (two to five worms per patient) with forceps using topical anaesthesia and antibiotic eye drops (Fig 1). The patients' symptoms resolved and there were no recurrences. The presence of the *Thelazia callipaeda* worms was confirmed by parasitologists.

COMMENT

Kirschner *et al* reported a case of conjunctivitis caused by *Thelazia californiensis* and a fly was believed to have been the possible mode of transmission in the Sierra Mountain foothills of California.⁵ Mimori *et al* reported *Thelazia callipaeda* infection in a man in Kumamoto Prefecture, Japan, who resided in the mountains.⁶ The hospitals in which our patients were examined are located in a remote mountainous region of Shimane Prefecture in western Honshu. Patients lived in the suburbs in which the hospitals were

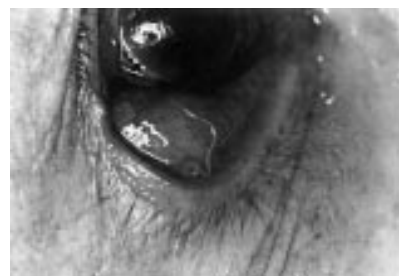

Figure 1 Patient 5. Slight conjunctival congestion and a worm in the right conjunctival sac.

located; the infections might have occurred in their places of residence.

In the case of the infection of the inpatient, the infection route is unclear. Some farms that raise beef cattle are located near the hospital, and it is possible that flies from these farms transported the parasite to the hospital.

The authors have no proprietary interest in any aspect of this report.

YASUROU KOYAMA

Division of Ophthalmology, Muikaichi Hospital, Muikaichi, Shimane, Japan

AKIHIRO OHIRA

Department of Ophthalmology, Shimane Medical University, Izumo, Shimane, Japan

TATSURO KONO

Division of Ophthalmology, Tsuwanokyouzon Hospital, Tsuwano, Shimane, Japan

TOSHIMI YONEYAMA

KUNINORI SHIWAKU
Department of 2nd Environment Medicine, Shimane Medical University, Izumo, Shimane, Japan

Correspondence to: Dr Akihiro Ohira, Department of Ophthalmology, Shimane Medical University, 89-1, Enya, Izumo, Shimane, 693-8501, Japan
Accepted for publication 8 December 1999

- Fraunfelder FT, Roy FH, eds. *Current ocular therapy*. 4th ed. Philadelphia: Saunders, 1995:136-7.
- Miyazaki I. *An atlas of zoonosis*. Fukuoka: Kyushu University Shupankai, 1988:633-9 (in Japanese).
- Kitano H, Uni S, Iseki M, et al. Case of human thelaziasis in Nara Prefecture. *Jpn Ganka Rinsyou Hou* 1996;90:1551-4 (in Japanese).
- Singh TS, Singh KN. Thelaziasis: report of two cases. *Br J Ophthalmol* 1993;7:528-9.
- Kirschner BI, Dunn JP, Ostler HB. Conjunctivitis caused by *Thelazia californiensis*. *Am J Ophthalmol* 1990;110:573-4.
- Mimori T, Korenaga M, Hirai H, et al. *Thelazia callipaeda* infections in Kumamoto Prefecture. *Jpn Kumamoto Med J* 1991;42:101-5.

Fish hook injury of the eyelid: an unusual case

EDITOR.—Reports of ocular fish hook injuries are uncommon in the literature. In the context of a recent case report by Krott and co-authors,¹ I would like to add my experience with a rather unusual case of fish hook injury to the eyelid.

A 44 year old man presented to the casualty department with a fish hook embedded in his

Table 1 Details of five cases of thelaziasis

Patient No	1	2	3	4	5
Sex	Male	Male	Male	Female	Female
Age (years)	70	65	83	57	80
Year examined	1988	1995	1996	1998	1999
Infected eye	Left	Right	Right	Left	Right
No of worms	3	3	2	3	5
Symptoms and ocular pain	Visual disorder	Foreign body sensation	Foreign body sensation	Foreign body sensation	—
Clinical findings and follicles	Conjunctival congestion	Conjunctival congestion	Conjunctival congestion	Conjunctival congestion	Conjunctival congestion
History	—	—	—	—	—

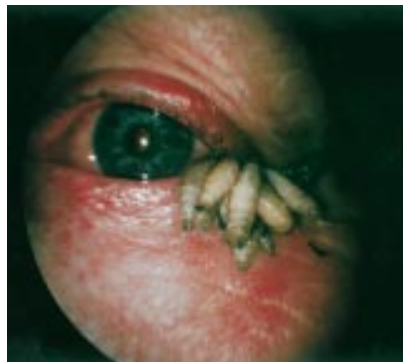

Figure 1 Fish hook loaded with nine live maggots embedded in the left upper eyelid.

left upper eyelid. He had cut off the line but made no attempt to remove the hook. The fish hook had pierced the eyelid from its conjunctival aspect near the outer canthus. It was loaded with nine live maggots that were used as bait (Fig 1). The left eye showed a small superficial linear abrasion of the cornea but was otherwise unremarkable and the visual acuity was 6/6. Under local anaesthesia after removal of the maggots, the hook was rotated so that the barb emerged through the eyelid skin. The barb was snipped off using a wire cutter and the hook was rotated back and removed. The patient was treated with saline irrigation of the conjunctival sac and a topical antibiotic and he made an uneventful recovery.

Even in the absence of serious ocular injury, this case is interesting for the presence on the fish hook of live maggots that were kissing the conjunctiva and eyelid skin!

GIRISH G KAMATH

Department of Ophthalmology, Arrowe Park Hospital,
Upton, Wirral CH49 5PE

Accepted for publication 8 December 1999

1 Krott R, Bartz-Schmidt KU, Heimann K. Laceration of the eye with fishing hook. *Br J Ophthalmol* 1999;83:1194.

Methaemoglobinaemia after peribulbar blockade: an unusual complication in ophthalmic surgery

EDITOR.—Peribulbar blockade is frequently used for anaesthesia in ophthalmic surgery. Owing to its short onset time and low incidence of cardiac and central nervous system toxicity, the local anaesthetic prilocaine is a popular choice for peribulbar blockade. Prilocaine is, however, the most potent methaemoglobin forming local anaesthetic. We report a case of prilocaine induced methaemoglobinaemia after peribulbar blockade for ophthalmic surgery.

CASE REPORT

A 27 year old Romanian woman presented with a detached retina requiring surgical repair. Her medical history was significant for insulin dependent diabetes mellitus compli-

cated by chronic renal failure, anaemia, and diabetic retinopathy. Her daily medication included captopril 25 mg, verapamil 240 mg, isosorbide dinitrate 40 mg, and frusemide 40 mg. A mixture of prilocaine 80 mg, bupivacaine 30 mg, hyaluronidase, and naphazoline was used to perform a peribulbar anaesthesia. Vital signs at the beginning of the operation were normal, oxygen saturation (SpO₂) was 96% on room air. Sixty minutes after the peribulbar block was performed, the patient became tachypnoeic, somnolent, and the SpO₂ decreased to 87% despite receiving 10 l/min of oxygen via facemask. There were no indications of myocardial ischaemia on the ECG and the breath sounds were clear. Arterial blood gas analysis demonstrated a Pao₂ 236 mm Hg, Paco₂ 32 mm Hg, pH 7.31, base excess of -5.1, Sao₂ 98.4%, haemoglobin 5.3 g/dl, and methaemoglobin level of 11.2%. Surgery was interrupted, methylene blue (1.5 mg/kg) was administered, and the patient improved rapidly. She was discharged home without further incident a week later.

COMMENT

Oxygen normally binds reversibly to the sixth coordination position of haem iron in haemoglobin. Partial transfer of an electron from ferrous iron to oxygen leads to the formation of superoxo-ferrahaem (Fe³⁺O⁻). Failure of the electron to transfer back to oxygen results in methaemoglobin (HbFe³⁺) formation.¹ Methaemoglobin formation in vivo is normally limited by NADH dependent methaemoglobin reductase, which serves as an electron donor for methaemoglobin. NADPH dependent methaemoglobin reductase plays a minor part (approx 5% of methaemoglobin reduction) but transfers the electron taken from methylene blue to the methaemoglobin. When methaemoglobin formation exceeds >1% of total haemoglobin, tissue oxygen transport is compromised.² Furthermore, the severity of tissue hypoxaemia may be underestimated by pulse oximetry which may constantly read 85% despite increasing methaemoglobin levels.^{3,4} Thus, arterial blood-gas determinations are necessary in order to confirm the diagnosis of methaemoglobinaemia and to fully appreciate the degree of hypoxaemia.

Methaemoglobinaemia may be the result of primary or secondary (acquired) causes. Genetic conditions resulting in methaemoglobinaemia include mutagenic defects of haemoglobin and congenital reductase enzyme deficiency.⁵ Acquired methaemoglobinaemia may be caused by oxidant drugs that overwhelm the body's ability to limit methaemoglobin formation via enzymatic reduction. Local anaesthetics are the most common cause of perioperative methaemoglobinaemia.⁶ Prilocaine is the most potent methaemoglobin forming local anaesthetic. Methaemoglobin formation is dose dependent and correlates with the rate of systemic absorption. In general, doses less than 600 mg in adults are thought not to increase the patient's risk of methaemoglobinaemia.⁷ De-

spite this, the administration of only 80 mg in the present case resulted in methaemoglobinaemia. However, several predisposing factors may have contributed to the enhanced formation of methaemoglobin. Firstly, the risk of prilocaine induced methaemoglobinaemia in patients with renal failure may be increased as metabolic acidosis increases ionised prilocaine serum levels. Further, the unbound fraction of prilocaine may be elevated in renal failure as a result of decreased serum proteins.⁸ Additionally, regular intake of isosorbide dinitrate which is also associated with methaemoglobin formation may have already predisposed this patient to the development of methaemoglobin formation.⁹ Finally, it is possible that our patient may also have suffered from an undiagnosed genetic predisposition to methaemoglobin formation. Although an abnormal haemoglobin pattern was ruled out by electrophoresis, we did not rule out a deficiency in methaemoglobin reducing enzymes such as NADH dependent methaemoglobin reductase. Thus, this patient had several underlying factors that may have predisposed her to prilocaine induced methaemoglobinaemia.

In conclusion, small concentrations of prilocaine can cause methaemoglobinaemia when used for peribulbar blockade in patients with reduced tolerance to oxidant drugs.

HOLGER ELTZSCHIG
MARTIN ROHRBACH
TORSTEN HANS SCHROEDER

Department of Anaesthesiology and Department of
Ophthalmology, Eberhard-Karls-University Tuebingen,
Germany

Correspondence to: Torsten H Schroeder, MD, Channing Laboratory, Brigham and Women's Hospital, Harvard Medical School, 181 Longwood Avenue, Boston, MA 02115, USA

Accepted for publication 8 December 1999

- 1 Wittenberg JB, Wittenberg BA, Preiach J, *et al*. On the state of the iron and the nature of the ligand in oxyhaemoglobin. *Proc Natl Acad Sci USA* 1970;67:1846-53.
- 2 Mansouri A. Review: Methemoglobinemia. *Am J Med Sci* 1985;289:200-9.
- 3 Schroeder TH, Dieterich H-J, Mühlbauer B. Methemoglobinemia after axillary block with bupivacaine and additional injection of lidocaine in the operative field. *Acta Anaesthesiol Scand* 1999;43:480-2.
- 4 Barker SJ, Tremper KK, Hyatt J. Effects of methemoglobinemia on pulse oximetry and mixed venous oximetry. *Anesthesiology* 1989;70:112-17.
- 5 Sugahara K, Sadohara T, Kawaguchi T, *et al*. NADH-diaphorase deficiency identified in a patient with congenital methaemoglobinemia detected by pulse oximetry. *Intensive Care Med* 1998;24:706-8.
- 6 Olson ML, McEvoy GK. Methemoglobinemia induced by local anaesthetics. *Am J Hosp Pharm* 1981;38:89-93.
- 7 Hjeltn M, Holmdahl MM. Clinical chemistry of prilocaine and clinical evaluation of methemoglobinemia induced by this agent. *Acta Anaesthesiol Scand* 1965;16:161-70.
- 8 Chauvin M. Acute adverse effects of local anaesthetics according to the patient's condition. *Ann Fr Anesth Reanim* 1988;72:16-23.
- 9 Arsurra E, Lichstein E, Guadagnino V, *et al*. Methemoglobin levels produced by organic nitrates in patients with coronary artery disease. *J Clin Pharmacol* 1984;24:160-4.



Fish hook injury of the eyelid: an unusual case

GIRISH G KAMATH

Br J Ophthalmol 2000 84: 439
doi: 10.1136/bjo.84.4.439d

Updated information and services can be found at:
<http://bjo.bmj.com/content/84/4/439.5.full.html>

These include:

References

This article cites 1 articles, 1 of which can be accessed free at:
<http://bjo.bmj.com/content/84/4/439.5.full.html#ref-list-1>

Email alerting service

Receive free email alerts when new articles cite this article. Sign up in the box at the top right corner of the online article.

Notes

To request permissions go to:
<http://group.bmj.com/group/rights-licensing/permissions>

To order reprints go to:
<http://journals.bmj.com/cgi/reprintform>

To subscribe to BMJ go to:
<http://group.bmj.com/subscribe/>