

LETTERS TO THE EDITOR

Conjunctival tumour as the primary manifestation of infectious mononucleosis in a 12 year old girl

EDITOR.—Infectious mononucleosis (IM), a common disease in childhood, is an acute lymphoproliferative disease caused by Epstein-Barr virus (EBV),¹ a member of the herpes virus family. The association of EBV infection with benign and malignant lymphoproliferative diseases, as well as its role in the pathogenesis of nasopharyngeal carcinoma, is well known.^{2,3} The course of IM is usually self limiting but can be extremely variable, ranging from asymptomatic to a fatal outcome. Fever, pharyngitis, lymphadenopathy, and hepatosplenomegaly are typical systemic manifestations. Essential for the diagnosis is an increase in relative and absolute numbers of lymphocytes and monocytes, including 20–40% atypical forms. Ocular involvement of IM is unusual and occurs often as a mild unilateral follicular conjunctivitis simultaneously with these other symptoms.⁴ We describe a girl with a conjunctival tumour as the first manifestation of IM; systemic symptoms of the disease occurred some days later.

CASE REPORT

A previously healthy 12 year old girl with a 10 day history of a painless red left eye was treated with antibiotic eye drops. Despite these, a unilateral conjunctival swelling developed, and the girl was admitted for further ophthalmological consultation. On examination, a 5 × 5 mm red coloured mass in the upper nasal conjunctiva of the left eye was observed. The globe was not displaced, the ocular motility and visual acuity were normal, and funduscopy was unremarkable. At this time, there were no palpable cervical lymph nodes. An excisional biopsy of the conjunctival tumour was performed. The initial histological diagnosis was "high grade malignant B cell lymphoma" and, consequently, the patient was referred to the department of oncology. On examination some days later, the girl was in a good general condition. Conjunctival vessel injection of the left eye and a mobile tumour of the upper nasal conjunctiva were observed (Fig 1). A 2 cm large left preauricular lymph node was visible, and some enlarged, tender, and mobile submandibular lymph nodes were palpable. A pharyngitis and moderate splenomegaly were also apparent. The remaining physical examination was unremarkable. Abdominal ultrasonography

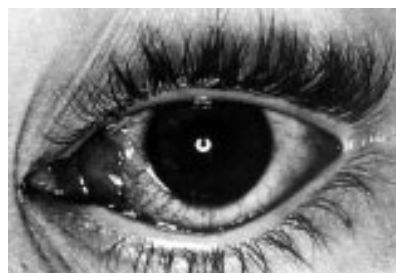

Figure 1 Conjunctival tumour of the left eye (after incisional biopsy).

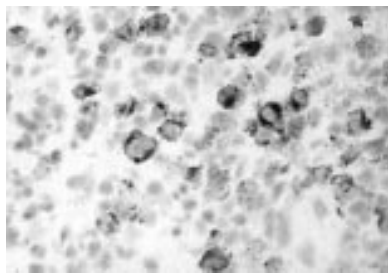


Figure 2 Epstein-Barr virus infection detected by antibodies against the latent membrane protein (Cs1-4) (APAAP, original magnification x40).

showed mildly enlarged para-aortal lymph nodes. The peripheral blood count revealed a relative and absolute lymphocytosis (WBC $13 \times 10^9/l$, 76% lymphocytes) with 33% atypical lymphocytes. Elevated levels of lactate dehydrogenase (658 U/l), aspartate aminotransferase (79 U/l), alanine aminotransferase (151 U/l), and bilirubin (1.1 mg/dl) were also detected. Serological tests confirmed the clinical diagnosis of an acute EBV infection.

Re-evaluation of the pathological findings by a lymphoma referral centre was undertaken. An extensive lymphocytic infiltrate and large necrotic areas were seen below an ulcerated conjunctival epithelium. The infiltrate mainly consisted of large polyclonal B immunoblasts, smaller mixed lymphocytes and polytypical plasma cells. Occasional immunoblasts, particularly those close to necrotic areas, expressed the latent membrane protein of the EBV (Cs1-4) (Fig 2) and were also positive for the EBV related proteins PE2 and BZ1. In addition, in situ hybridisation for EBV encoded early nuclear RNA (EBER) showed positive reaction in some immunoblasts. The growth fraction of the infiltrating cells was 60–80%, using the antibody Ki-67. On the basis of the conventional histology and immunohistology, in particular the polytypic nature of the immunoblasts and plasma cells as well as the demonstration of EBV infection, a diagnosis of IM involvement of the conjunctiva could be made; a malignant lymphoma was excluded. During the subsequent several weeks, all symptoms and signs of the IM resolved spontaneously.

COMMENT

Manifestations of IM in ocular tissues are rare, with the conjunctiva being the commonest tissue involved and then usually in the form of a follicular conjunctivitis.⁴ In general, the conjunctivitis occurs in parallel with the systemic symptoms of IM described above. Conjunctival involvement in the form of a swelling or a tumour has been reported previously.⁵⁻⁷ These occurred in 11, 38, and 14 year old patients, respectively, with the latter case being similar to ours in that the conjunctival tumour was the initial manifestation of the disease.⁷ As with our patient, all patients recovered within a few to several weeks. The main differential diagnosis of a unilateral salmon coloured conjunctival swelling without obvious systemic symptoms of an EBV infection is a malignant lymphoma; however, these infections are very rare in ocular tissues in children.⁸ The conventional histological picture with a dense lymphocytic infiltration consisting predominantly of lymphoblasts with areas of necrosis can appear similar to a high grade lymphoma. These diagnostic difficulties can be further exacerbated with the coexistence of, or subsequent development of,

a malignant lymphoma following infectious mononucleosis.^{9,10} In the present case, the initial histological diagnosis made was malignant lymphoma. This diagnosis could be subsequently refuted on the basis of the immunohistochemistry and in situ hybridisation which demonstrated a polyclonal lymphocytic infiltrate and the detection of EBV associated antigens on the surface and within the nucleus of the infiltrating cells. The subsequent clinical progression with a self limiting course and the positive serology for EBV support the diagnosis of a lymphoproliferative process associated with an acute EBV infection and infectious mononucleosis. In conclusion, infectious mononucleosis should be considered in the differential diagnosis in patients with conjunctival lymphoid tumours.

P HUNDSDOERFER
U SCHULTE OEVERBERG
G HENZE

Department of Paediatric Oncology/Haematology,
Charité Virchow-Klinikum, Humboldt Universität
Berlin, Germany

S E COUPLAND

Department of Pathology, Universitätsklinikum
Benjamin Franklin, Freie Universität Berlin, Germany

M SCHULTE

H BLECKMANN

Department of Ophthalmology, Schlosspark Klinik
Berlin, Germany

Correspondence to: Dr Patrick Hundsdorfer, Universitätsklinikum Charité, Campus Virchow Klinikum, Kliniken für Kinderheilkunde und Kinderchirurgie, Klinik für Pädiatrie mit Schwerpunkt Onkologie/Hämatologie, Augustenburger Platz 1, 13353 Berlin, Germany
phundsdoerfer@hotmail.com
Accepted for publication 8 December 1999

- Henle G, Henle W, Diehl V. Relation of Burkitt's tumor-associated herpes-type virus to infectious mononucleosis. *Proc Natl Acad Sci USA* 1968;59:94-101.
- De-The G, Geser A, Day NE, et al. Epidemiological evidence for causal relationship between Epstein-Barr virus and Burkitt's lymphoma from Ugandan prospective study. *Nature* 1978;274:756-61.
- Henle G, Henle W. Epstein-Barr virus-specific IgA serum antibodies as an outstanding feature of nasopharyngeal carcinoma. *Int J Cancer* 1976;17:1-7.
- Tanner OR. Ocular manifestations of infectious mononucleosis. *Arch Ophthalmol* 1952;51:229-41.
- Meisler DM, Bosworth DE, Krachmer JH. Ocular infectious mononucleosis manifested as Parinaud's oculoglandular syndrome. *Am J Ophthalmol* 1981;92:722-6.
- Gardner BP, Margolis TP, Mondino BJ. Conjunctival lymphocytic nodule associated with the Epstein-Barr virus. *Am J Ophthalmol* 1991;112:567-71.
- Urbak SF. Infectious mononucleosis presenting as a unilateral conjunctival tumour. *Acta Ophthalmol (Copenh)* 1993;71:133-5.
- Coupland SE, Krause L, Delecluse HJ, et al. Lymphoproliferative lesions of the ocular adnexa. Analysis of 112 cases. *Ophthalmology* 1998;105:1430-41.
- Robinson JE, Brown N, Andiman W, et al. Diffuse polyclonal B-cell lymphoma during primary infection with Epstein-Barr virus. *N Engl J Med* 1980;302:1293-7.
- Morgan-Capner P, Morris JA, McIlmurray MB, et al. Immunohistological studies of lymphoproliferative lesions in a fatal case of Epstein-Barr virus infection. *J Clin Pathol* 1986;39:1317-22.

Ultrasound biomicroscopy in the diagnosis of a foreign body simulating iris melanoma

EDITOR.—Several lesions of the iris can clinically resemble melanoma.^{1,2} Failure to recognise a simulating condition could lead to misdirected therapy. The most common iris pseudomelanomas include primary iris cyst,

iris naevus, essential iris atrophy, iris foreign body, peripheral anterior synechia, and iris metastasis.²

An iris foreign body can occasionally pose a diagnostic challenge, especially in the absence of a history of ocular trauma. We present a case of an iris foreign body that resembled a melanoma, in which ultrasound biomicroscopy (UBM) was instrumental in the diagnosis.

CASE REPORT

In June 1999, a 70 year old man was found on routine examination to have a brown lesion in the inferior part of his left iris. Two months later the lesion showed a possible increase in size, prompting a referral to the oncology service of the Wills Eye Hospital to rule out iris melanoma.

His visual acuity was 20/20 in both eyes and the intraocular pressures were normal. There was no melanocytosis, heterochromia, corneal pigmentation, corneal scar, endothelial defect, cells in the anterior chamber, or pupillary abnormalities. There was an irregular brown lesion in the left iris inferiorly, measuring 2 × 1 mm in diameter (Fig 1A). There were a few light brown refractile deposits on the surface of the lesion. Gonioscopy showed the lesion extending onto the trabecular meshwork without trabecular seeding but with adjacent peripheral anterior synechiae (Fig 1B). There was no intrinsic vascularity, feeder vessel, iris or angle neovascularisation, or pigment dusting. The lens was clear and the fundus in each eye was normal.

Although the lesion superficially resembled a melanoma, we felt it could be a foreign body based on the presence of focal brown deposits over the lesion, which resembled rust particles. On repeated specific questioning, the patient recalled trauma to the left eye over 50 years earlier, while hammering metal.

Ultrasound biomicroscopy² demonstrated a highly reflective structure in the iris and anterior chamber angle, with absence of echoes posterior to the lesion, characteristic of a foreign body (Fig 2A). In addition, a defect in Descemet's membrane was noted in the upper part of cornea just off the pupillary axis (Fig 2B). Subsequent slit lamp biomicroscopy with high magnification confirmed the minute defect in Descemet's membrane. Electroretinography was not performed because there was no clinical evidence of siderosis.

COMMENT

Several conditions can simulate iris melanoma.^{1,2} In a study from the Armed Forces Institute of Pathology, Ferry reported 24 pseudomelanomas among 69 eyes that were enucleated for suspected iris melanoma, a diagnostic error of 35%.¹ The lesions that most commonly simulated iris melanoma in his series included anterior staphyloma, inflammatory mass, iris stromal atrophy, and corneal perforation.¹ Additionally, he noted one enucleated eye with a metallic foreign body misdiagnosed as an iris melanoma. In a clinical study of 200 patients referred for an iris lesion suspected to be melanoma, Shields and associates found that 76% were pseudomelanomas.² Iris foreign body accounted for 4.5% of pseudomelanomas in that series, and in each instance, the patient was unaware of the foreign body and could not recall ocular trauma. However, a defect in Descemet's membrane was detected on slit lamp biomicroscopy in each case.

Diagnosis of a foreign body may sometimes be difficult in the absence of a history of injury, especially when slit lamp biomicroscopy of the anterior segment does not reveal any sign of ocular trauma. Imaging modalities such as computed tomography and ultrasonography may help in such situations. However, magnetic resonance imaging is contraindicated in cases where a ferromagnetic foreign body is suspected. Standard B-scan ultrasonography has been replaced at many centres by UBM for the evaluation of anterior segment foreign bodies.³⁻⁵ We used UBM to confirm our clinical impression of an

iris foreign body in this case. In addition to characterising the foreign body, UBM detected a subtle irregularity in Descemet's membrane.

It is of interest that a seemingly metallic foreign body could remain inert for 50 years without causing ocular inflammation, siderosis or secondary glaucoma, which prompted us to choose to observe this patient rather than to intervene surgically.

When the ophthalmologist is confronted with a dark iris lesion, an intraocular foreign body is a possibility, irrespective of a negative history of trauma. Slit lamp biomicroscopy coupled with gonioscopy provides excellent diagnostic clues. We believe that UBM is a sensitive imaging technique for confirmation of the diagnosis.

SANTOSH G HONAVAR
JERRY A SHIELDS
CAROL L SHIELDS

Oncology Service, Wills Eye Hospital, Thomas Jefferson University, Philadelphia, PA, USA

Correspondence to: Jerry A Shields, MD, Oncology Service, Wills Eye Hospital, 900 Walnut Street, Philadelphia, PA 19107, USA

jas.cls@ix.netcom.com

Accepted for publication 21 January 2000

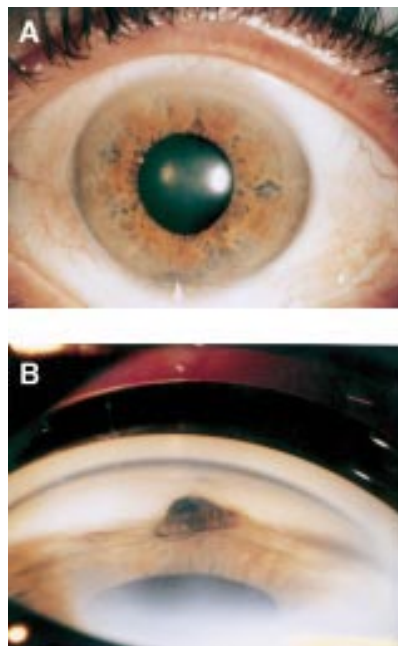


Figure 1 (A) Anterior segment photograph showing a dark brown lesion in the iris inferiorly (white arrow). (B) Goniophotograph showing the lesion in the iris with superficial rust coloured deposits. Note the adjacent peripheral anterior synechia.

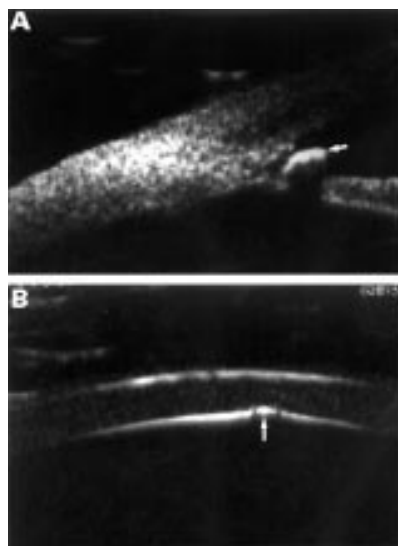


Figure 2 (A) Ultrasound biomicroscopy image showing a highly reflective intraocular foreign body over the peripheral iris and extending into the angle recess (white arrow). The foreign body shadows the underlying iris. (B) Ultrasound biomicroscopy image showing a discontinuity of Descemet's membrane (white arrow).

- 1 Ferry AP. Lesions mistaken for malignant melanoma of the iris. *Arch Ophthalmol* 1965;74:9-18.
- 2 Shields JA, Sanborn GE, Augsburger JJ. The differential diagnosis of malignant melanoma of the iris: a clinical study of 200 patients. *Ophthalmology* 1983;90:716-20.
- 3 Pavlin CJ, Harasiewicz K, Sherar MD, et al. Clinical use of ultrasound biomicroscopy. *Ophthalmology* 1991;98:287-95.
- 4 Deramo VA, Shah GA, Bauml CR, et al. Ultrasound biomicroscopy as a tool for detecting and localizing occult foreign bodies after ocular trauma. *Ophthalmology* 1999;106:301-5.
- 5 Nouby-Mahmoud G, Silverman RH, Coleman DJ. Using high-frequency ultrasound to characterize intraocular foreign bodies. *Ophthalmic Surg* 1993;24:94-9.

Optical coherence tomography findings in early solar retinopathy

EDITOR.—Visual deterioration caused by watching a solar eclipse has been recognised from the time of Plato. The aetiology of solar retinopathy has been attributed to photochemical effects, which may be enhanced by elevated tissue temperature.¹ Typically, a small yellow spot may be noted in the foveolar area immediately after exposure. Histopathological studies of solar retinal lesions revealed retinal pigment epithelium (RPE) and photoreceptor damage.^{1,2} We present two patients with acute, severe solar retinopathy after observation of the total eclipse on 11 August 1999. Funduscopic findings were accompanied by optical coherence tomography (OCT) investigation of the macula.

CASE REPORTS

Case 1

An 18 year old man presented 24 hours after watching the total eclipse without appropriate protection. Total exposure time was approximately 20 minutes. During direct viewing the patient kept his right eye closed. One hour after observation he noted blurred vision and a central scotoma on the left eye. Best corrected visual acuity was 0.8 in the right and 0.1 in the left eye. Fundus examination of the right eye did not show any pathology. Funduscopy of the left eye revealed a yellow lesion in the fovea, surrounded by a circular red area

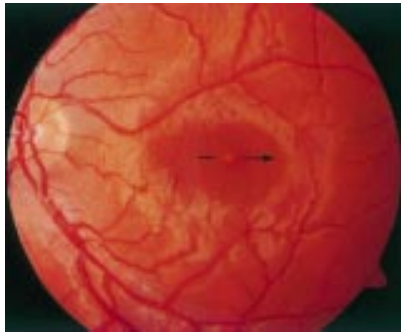


Figure 1 Acute stage of solar retinopathy showing a yellow lesion surrounded by a circular red area (patient 1, left eye).

(Fig 1). OCT was performed 48 hours after exposure. OCT examination of the right eye showed no pathology. In the left eye, a hyperreflective area in the fovea was found (Fig 2A). All retinal layers in the fovea were affected. The hyperreflective area closely resembled the yellow spot seen funduscopically. There was no significant difference in retinal thickness between the right and the left eye (106 μm /110 μm). Nine days after exposure visual acuity was 0.8 in the right eye and 0.16 in the left eye. Funduscopy showed the yellow lesion of the left fovea resolving and its margins beginning to fade. An OCT scan revealed that the previously hyperreflective foveal area converted to a normal reflectivity (Fig 2B).

Case 2

A 26 year old woman complained of blurred vision and central scotoma after watching the eclipse without eye protection. Total exposure time was 5 minutes. Forty eight hours after exposure visual acuity was 1.0 in the right and 0.8 in the left eye. Fundus examination showed a small yellow round lesion in the fovea of both eyes. On OCT, a hyperreflective

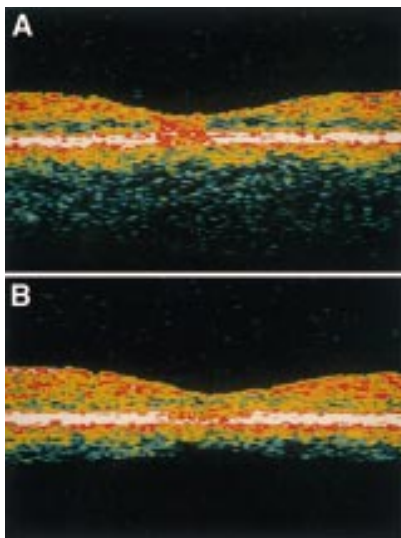


Figure 2 (A) OCT examination of the same eye 48 hours after exposure revealed a hyperreflective area in the fovea affecting all retinal layers. No increase in retinal thickness could be demonstrated. The location of the OCT scan is shown on the corresponding fundus photograph (Fig 1). (B) OCT examination 9 days after exposure. The hyperreflective area in the fovea was no longer visible, whereas an increasing alteration of the RPE and choriocapillary layer could be demonstrated. Visual acuity increased from 0.1 to 0.16. Still no change in retinal thickness occurred.

area in the centre of the fovea was demonstrated in both eyes. Similar to case 1, all layers of the fovea were affected. Retinal thickness (110 μm /118 μm) was within the normal range.

COMMENT

Solar retinopathy is characterised by a yellow foveolar dot and a central scotoma.³ For the first time we describe OCT findings of patients suffering from solar retinopathy. The main finding was a hyperreflective area involving all foveolar retinal layers without showing any sign of retinal oedema. It correlated in size and location with the characteristic funduscopically visible yellow dot. At present, the origin of this well delineated area of hyperreflectivity is unclear. Moreover, histopathological analysis^{1,2} of solar retinopathy has demonstrated that mainly the pigment epithelium and outer segments of the photoreceptor layer are damaged. The OCT scan however showed pathological appearance of all retinal layers. In one patient we have been able to repeat OCT investigation 9 days after solar exposure, revealing that the retinal changes were reversible, but delineating increasing pathology in the RPE and choriocapillary layer.

In addition, macular oedema, which has been described in the literature before,^{4,5} could not be demonstrated by OCT. On OCT examination, no significant increase in retinal thickness could be observed when comparing the affected and unaffected eye (case 1) or absolute values of both affected eyes (case 2). To the best of our knowledge, none of these OCT findings have been published before by other investigators.

The authors do not have any commercial or proprietary interest in any of the products mentioned in this article

MARTIN BECHMANN
OLIVER EHRT
MARTIN J THIEL
NADINE KRISTIN
MICHAEL W ULBIG
ANSELM KAMPIK

Department of Ophthalmology,
Ludwig-Maximilians-University, Munich, Germany

Correspondence to: Martin Bechmann, Universitäts-Augenklinik, Mathildenstrasse 8, 80336 München, Germany

mbechman@ak-i.med.uni-muenchen.de

Accepted for publication 8 December 1999

- 1 Hope-Ross MW, Mahon GJ, Gardiner TA, *et al*. Ultrastructural findings in solar retinopathy. *Eye* 1993;7:29–33.
- 2 Tso MOM, La Piana FG. The human fovea after sun-gazing. *Trans Am Acad Ophthalmol Otolaryngol* 1975;79:788–95.
- 3 Ehrh O, Tavcar I, Eckl-Titz G. Mikroperimetrie und Lesesakkaden bei Retinopathia solaris. *Ophthalmologie* 1999;96:325–31.
- 4 Schatz H, Mendelblatt F. Solar retinopathy from sun-gazing under the influence of LSD. *Br J Ophthalmol* 1973;57:270–3.
- 5 Hope-Ross M, Travers S, Mooney D. Solar retinopathy following religious rituals. *Br J Ophthalmol* 1988;72:931–4.

Granulomatous uveitis, CREST syndrome, and primary biliary cirrhosis

EDITOR.—There is a well known link between different autoimmune diseases. Up to 84% of patients with primary biliary cirrhosis (PBC) may have at least one other autoimmune disease, such as thyroiditis, scleroderma, rheumatoid arthritis, or Sjögren's syndrome.¹ The association between uveitis and scleroderma although rare is well recognised,² but we failed

to find a single report of the association of uveitis and CREST syndrome (calcinosis cutis, Raynaud's phenomenon, oesophageal dysmotility, sclerodactyly, and telangiectasia), a more benign variant of scleroderma in the form of limited cutaneous sclerosis. The simultaneous occurrence of PBC and uveitis is probably also very unusual as we could only find one such case report in our literature search.³ We report the case of a patient with uveitis whose investigation disclosed PBC and CREST.

CASE REPORT

A 48 year old woman with a longstanding history of Raynaud's phenomenon complained of blurred vision in the right eye over the past 3 months for which she had not sought medical attention. Ophthalmological examination revealed diminished visual acuity (VA) in the right eye to counting fingers. VA in the left eye was normal. Pupillary light reflexes were normal. A 5 minute basal tear production test was 5 mm in the right eye and 12 mm in the left. Slit lamp examination showed mutton fat keratic precipitates, flare, and cells (1+) in the anterior chamber and vitreous (anterior and posterior) of both eyes, and a right eye posterior subcapsular cataract accounting for the visual loss. The fundi were normal without any signs of vasculitis or pars planitis. General clinical examination revealed microstomia, facial telangiectasias, sclerodactyly, and multiple finger pulp cutaneous infarcts.

Laboratory investigations showed raised serum aspartate aminotransferase (131 U/l, normal 0–40 U/l), alanine aminotransferase (154 U/l, normal 7–56 U/l), γ glutamyltransferase (274 U/l, normal 8–78 U/l), and alkaline phosphatase (471 U/l, normal 38–126 U/l). Serum bilirubin, calcium, and angiotensin converting enzyme levels were normal. The serum albumin was also normal (38.6 g/l) as was the prothrombin time (12.4 seconds). The serum IgM was 3.66 g/l (normal 0.60–2.63 g/l) whereas IgG and IgA levels were normal. RA test was 46.2 U/ml (normal 0–20 U/ml), Waaler-Rose was negative, and circulating immune complexes were detected at a level of 2.80 mg/l (normal <1.5 mg/l). Complement levels were normal. Antinuclear antibodies were positive (>1:1280) with a speckled pattern. Anticentromere, antimitochondrial (>1:100), and anti-M2 antibodies were also positive. There was no evidence of past or present hepatitis C or hepatitis B infection. The VDRL was non-reactive and Lyme, toxoplasma, CMV, and HIV serologies were negative. The HLA phenotype was A1, A9, B17, Bw4, Cw4, Cw6, DR5, DR52, DR8, DQ4, DQ7.

A chest x ray was normal and a radiograph of the hands revealed subcutaneous calcinosis. The Mantoux test (2 units) was anergic. There was no evidence of pathology. The liver biopsy showed stage III PBC.

This patient was treated with ursodeoxycholic acid, calcium, vitamin A and D supplements. Topical corticosteroids and oral prednisolone 60 mg/day were also started. Systemic steroids were tapered to 10 mg/day after 2 months, and then slowly tapered over the next 4 months until they were discontinued. There was a temporary increase in liver enzymes (AST, 167 U/l; ALT, 313 U/l; GGT, 774 U/l) which returned to baseline values soon after steroids were stopped. The uveitis resolved and 5 months later, on no eye medication, she underwent cataract surgery successfully, significantly regaining vision in that eye (best corrected visual acuity = 1.0).

COMMENT

In PBC, CREST, and uveitis abnormalities of the humoral and cellular immune systems are common. These include increased levels of serum immunoglobulins, the presence of circulating autoantibodies, increased turnover of complement, the presence of activated T and B cells in the peripheral blood and impaired T cell regulation.¹⁻⁴ Despite the high frequency of these immunological abnormalities, a definite immunopathogenetic mechanism has not yet been clearly established for any of these disorders. Furthermore, no single mechanism seems to provide a link between these clinical entities. A mouse model for the development of liver damage through the intrahepatic inoculation of mycoplasma-like organisms, which cause human chronic uveitis, has recently been developed,⁵ but it remains a hypothetical concept. Our case report illustrates an association between ocular and hepatic diseases, which may be entirely coincidental but could, nevertheless, encourage further investigation for a common immunological pathway.

P S SANTOS

Serviço Universitário de Oftalmologia,
Hospital de Egas Moniz, Lisbon, Portugal

L OLIVEIRA

M F MORAES

J PIMENTA DA GRAÇA

Serviço de Medicina II, Hospital de Egas Moniz,
Lisbon, Portugal

E MONTEIRO

Consulta de Hepatologia, Hospital Curry Cabral,
Lisbon, Portugal

P ABECASIS

Serviço de Medicina II, Hospital de Egas Moniz,
Lisbon, Portugal

L N FERRAZ DE OLIVEIRA

Serviço Universitário de Oftalmologia,
Hospital de Egas Moniz, Lisbon, Portugal

Correspondence to: Paulo S Santos, Serviço Universitário de Oftalmologia, Hospital de Egas Moniz, Rua da Junqueira, 126 P-1300 Lisboa, Portugal
Accepted for publication 14 January 2000

- 1 Kaplan MM. Primary biliary cirrhosis. *N Engl J Med* 1996;335:1570-80.
- 2 Martenet AC. Uveitis in connective tissue disorders. *Trans Ophthalmol Soc UK* 1981;101:376-9.
- 3 Nakajima K, Komatsu M, Hoshino T, et al. A case of primary biliary cirrhosis accompanied by uveitis. *Nippon Shokakybio Gakkai Zasshi* 1991;88:2686-90.
- 4 Mitchell H, Bolster MB, LeRoy EC. Scleroderma and related conditions. *Med Clin N Am* 1997;81:129-49.
- 5 Johnson LA, Wirotko E, Wirotko BM. Experimental murine chronic hepatitis: results following intrahepatic inoculation of uveitis mycoplasma-like organisms. *Int J Exp Pathol* 1993;74:325-31.

Vitreous basket sign in dislocation of the lens

EDITOR.—We describe a new ultrasonographic sign dubbed “vitreous basket sign” (looks like a basketball caught at the bottom of a basket) found in eyes with posteriorly dislocated lenses. Identifying this pattern can contribute to the diagnosis and differential diagnosis of dislocated lens.

We used the Acuson 128x p/o linear array 7 MHz probe instrument.

CASE REPORT

The patient was 65 years old white woman with a painful traumatic blind eye and a large leucoma adherens. Ultrasonographic examination demonstrated a hyperechogenic mass on the retina at the posterior pole, with a pos-

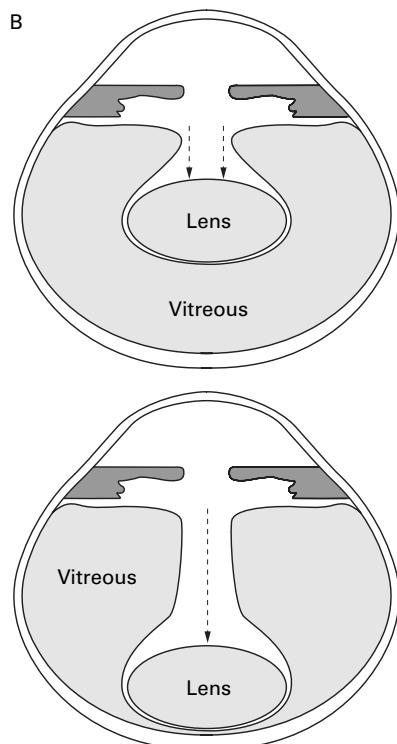
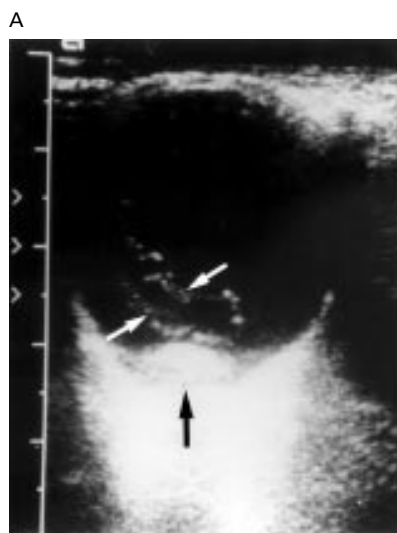

Figure 1 (A) B scan of the case presented. Dragged anterior vitreous face (white arrows) creating an empty tunnel above an oval-shaped hyperechogenic mass (black arrow).

(B) Schematic representation of the process of lens dislocation. The anterior vitreous surface is dragged by the dislocated lens towards the retina creating an empty tunnel above it with the dragged anterior vitreous face acting as the wall of the tunnel.

teriorly dragged anterior vitreous face, creating a hypoechogenic central tunnel (Fig 1A). The mass and tunnel changed location with ocular movements.

COMMENT

A similar ultrasonographic pattern has been seen in seven eyes of six patients. Dislocated lens or nucleus should always be in the differential diagnosis of an intraocular mass. Alward *et al*¹ described three cases of pseudophakic

patients with dropped nuclei during extracapsular cataract extraction suspected to be choroidal melanomas later.

There are several ultrasonographic signs cited as characteristic of dislocated lenses²: a hyperechogenic mass with an oval shape, which can become highly reflective as cataract develops, and vitreal strands adherent to the mass which is mobile and changes location with eye movements.

We believe this particular ultrasonographic sign can be ascribed to the following process. The lens detaches, encounters the anterior vitreous face, and pushes it posteriorly by its weight towards the retina. The anterior vitreous face, vitreous gel, and collagen fibres within the vitreous are pushed back by the lens creating the wall of an aqueous filled tunnel with the lens at its bottom (Fig 1B).

In most cases this sign is easy to demonstrate, and we recommend it as a useful new clue to the ultrasonographic diagnosis of dislocation of the lens.

TALI ROCK

HAGGAY AVIZEMER

Department of Ophthalmology, Edith Wolfson Medical Center, Holon, Israel

RAMA KATZ

GABRIELA GVIRTZ

Department of Radiology

ELISHA BARTOV

Department of Ophthalmology

Correspondence to: Dr Tali Rock, Department of Ophthalmology, Edith Wolfson Medical Center and Sackler Faculty of Medicine, Tel-Aviv University Holon, Israel 58100

ebartov@netvision.net.il

Accepted for publication 4 January 2000

- 1 Alward WL, Byrne SF, Hughes JR, et al. Dislocated lens nuclei simulating choroidal melanomas. *Arch Ophthalmol* 1989;107:1463-4.
- 2 Byrne SF, Green RL. *Ultrasonnd of the eye and orbit*. St Louis: CV Mosby, 1992:195-6.

Combined central retinal vein occlusion and cilioretinal artery occlusion in a patient on hormone replacement therapy

EDITOR.—Combined occlusion of the central retinal vein and the central retinal artery or a cilioretinal artery is unusual. There have been many previously reported systemic and ocular associations. The pathogenesis of this condition, however, is not established and remains controversial. Whether the venous obstruction or the arterial blockage acts as the initiating event is unknown. We describe a patient with combined central retinal vein occlusion (RVO) and cilioretinal artery occlusion occurring 6 weeks after starting hormone replacement therapy (HRT). We observed the evolution of the arterial occlusion. This suggests that the initiating event was the RVO.

CASE REPORT

A 46 year old patient presented with a 2 day history of decreased vision in the left eye noticed on waking. She reported no previous visual disturbances. She had been started on cyclical combined HRT 6 weeks before presentation. She was taking no other medication and had previously used the combined oral contraceptive pill with no adverse effects. She was a non-smoker. There was no past or family history of venous thromboembolism.

Visual acuities were right eye 6/5 and left eye 6/60. Right intraocular pressure (IOP) was elevated (22 mm Hg). There was a left relative afferent pupillary defect. Gonioscopy showed open angles. Blood pressure was 140/90 mm

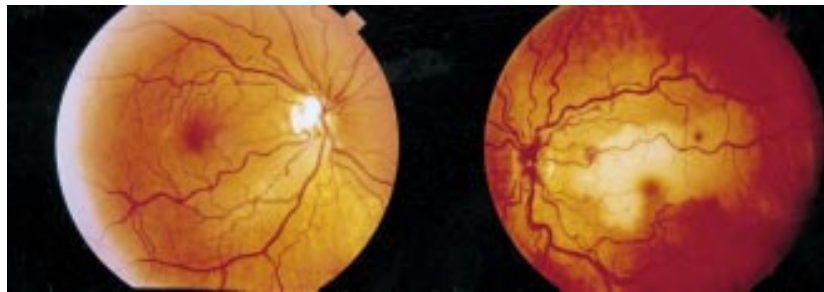

Figure 1 (Left) The right fundus at presentation showing dilated retinal veins and a pathologically cupped optic disc. (Right) The left fundus at presentation showing a swollen, haemorrhagic optic disc, dilated veins in all four quadrants and scattered perivenous retinal haemorrhages. There is retinal whitening corresponding with the distribution of a cilioretinal artery.

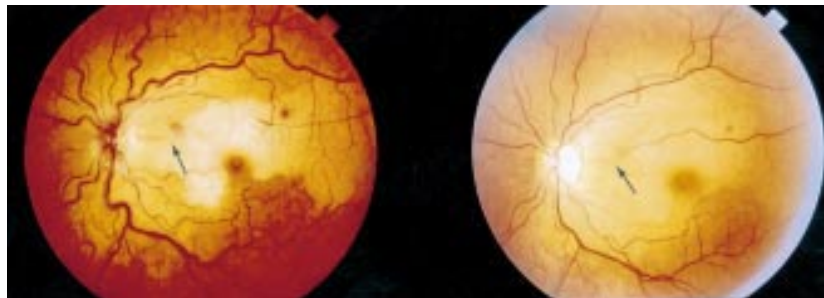


Figure 2 (Left) The left fundus 1 week after presentation. The cilioretinal artery supplying the superior macula is narrow and irregular in calibre with fractionation of the blood column (arrow). (Right) The left fundus 2 months after presentation. The calibre of the cilioretinal artery has returned to normal (arrow) and most retinal haemorrhages have resolved.

Hg. Pulse rate was 72 beats per minute and regular. There was no cardiac murmur and no carotid bruit. On the right there was pathological cupping of the optic disc and venous dilatation (Fig 1). Examination of the left fundus showed dilated, tortuous retinal veins in all four quadrants, with scattered retinal haemorrhages and a swollen, haemorrhagic optic disc. There was retinal whitening in the territory of a cilioretinal artery. No intra-arterial embolus was seen (Figs 1 and 2). She was diagnosed, on clinical grounds, with left combined central retinal vein and cilioretinal artery occlusion and right primary open angle glaucoma.

One week later, the cilioretinal artery had become narrow and irregular in calibre, with fractionation of the blood column (Fig 2). Two months after presentation, the perivenous haemorrhages and optic disc swelling had resolved, the calibre of the cilioretinal artery had returned to normal (Fig 2), and visual acuity had improved to 6/12.

She had no identifiable risk factors for venous thromboembolism. Laboratory studies consisting of full blood count, erythrocyte sedimentation rate, blood glucose, urea and electrolytes, liver function tests, serum protein, serum protein electrophoresis, serum lipids, angiotensin converting enzyme, rheumatoid factor, double stranded DNA, antinuclear antibody, antimitochondrial antibody, anti-smooth muscle antibody, antineutrophil cytoplasmic antibody, antineutrophil factor, anti-cardiolipin antibody, lupus anticoagulant, VDRL, TPHA, serum urate and thrombophilia screen including protein C, protein S, activated protein C resistance (Factor V Leiden), DNA analysis for a genetic variation in the prothrombin gene (prothrombin 20210A), thrombin time, antithrombin III, fibrinogen, factor VIII, and plasma homocysteine were normal. Chest x ray was also

normal. Hormonal profile confirmed the patient's postmenopausal status.

She was managed with timolol 0.25% drops to the right eye. She was advised to discontinue the HRT since a causal relation with the retinal vascular disease could not be excluded. Low dose aspirin was commenced.

COMMENT

The pathogenesis of combined retinal venous and arterial occlusion is not established. Whether the venous obstruction or the arterial blockage acts as the initiating event is unknown.^{1,2} Carotid artery disease has never been described as a cause of simultaneous retinal arterial and venous occlusion. Evolution of the arterial occlusion has been documented in this case. This suggests that the initiating event was the RVO, with subsequent stagnation of blood flow, elevation of intraluminal capillary pressure caused by a patent central retinal artery and ultimately cilioretinal artery occlusion secondary to the high intravascular pressure.

There have been many reported systemic and ocular associations of combined retinal arterial and venous occlusion including temporal arteritis,² migraine, systemic lupus erythematosus,² lupus anticoagulant, syphilis,² optic neuritis,² and various causes of retinal vasculitis. Relevant investigations excluded any of these as an underlying cause. Elevated IOP probably plays some part in the development of some central RVOs.³ Left IOP was normal at presentation but elevated IOP may have preceded the RVO. RVO has been reported in association with the oral contraceptive pill.⁴ In one study,⁵ five of 588 patients who had sustained RVOs were HRT users, but four of the five had other potential risk factors. With the ever increasing use of HRT, it is important that any possible adverse effects be reported. To the best of our knowl-

edge, this is the first report of combined retinal arterial and venous obstruction associated with HRT.

DESIRÉE C MURRAY
DINA CHRISTOPOULOU
MARK HERO

Coventry and Warwickshire Hospital, Stoney Stanton
Road, Coventry CV1 4FH

Correspondence to: D C Murray, Birmingham and
Midland Eye Centre, City Hospital NHS Trust,
Dudley Road, Birmingham B18 7QU
desiree@mcmail.com

Accepted for publication 14 January 2000

- 1 Keyser BJ, Duker JS, Brown GC, *et al*. Combined central retinal vein occlusion and cilioretinal artery occlusion associated with prolonged retinal arterial filling. *Am J Ophthalmol* 1994; 117:308–13.
- 2 Duker JS, Cohen MS, Brown GC, *et al*. Combined branch retinal artery and central retinal vein obstruction. *Retina* 1990;10:105–12.
- 3 Fong ACO, Schatz H. Central retinal vein occlusion in young adults. *Surv Ophthalmol* 1993;37: 393–417.
- 4 Vessey MP, Hannaford P, Mant J, *et al*. Oral contraception and eye disease: findings in two large cohort studies. *Br J Ophthalmol* 1998;82:538–42.
- 5 Kirwan JF, Tsaloumas MD, Vinall H, *et al*. Sex hormone preparations and retinal vein occlusion. *Eye* 1997;11:53–6.

Histological examination of the pigment epithelium-Bruch membrane-choriocapillaris complex after macular translocation

EDITOR,—Macular degeneration is the leading cause of blindness in the older population, and it is becoming more and more prevalent.¹ At present there is no treatment for the dry type of macular degeneration; for treatment of the wet form, several medical and surgical therapies have been tried, with varying results.^{2–6}

Photodynamic therapy with verteporfin had a significant treatment benefit in predominantly classic choroidal neovascularisation (CNV) lesions.⁷

Surgical removal of the subretinal membrane is a promising method, but in many cases the visual acuity does not improve. A new technique has been proposed by Machemer and Steinhorst, where after surgical removal of the subretinal membrane the fovea is translocated to an area with healthier pigment epithelium, Bruch's membrane, and choroid.^{8,9}

Variants have been described where only the temporal part of the retina was detached, or the retinal detachment was created in the temporal side through the sclera, without retinotomy. Here the scleral resection will ultimately shift the relation of the pigment epithelium to the fovea.

CASE REPORT

In this case we performed a macular translocation using the Machemer and Steinhorst technique, with some modifications from Eckardt (personal communication, 24 October 1997), and from our experience. After surgery usually we see a retinal fold starting from the optic disc and extending to the periphery, but this fold usually disappears after 5–7 days.

Our patient died (from intracranial haemorrhage) on the fifth day after the operation, and it was possible to examine the operated eye pathologically.

At gross examination we found that rotation had been achieved through an angle of 25–30 degrees. The next step was to perform

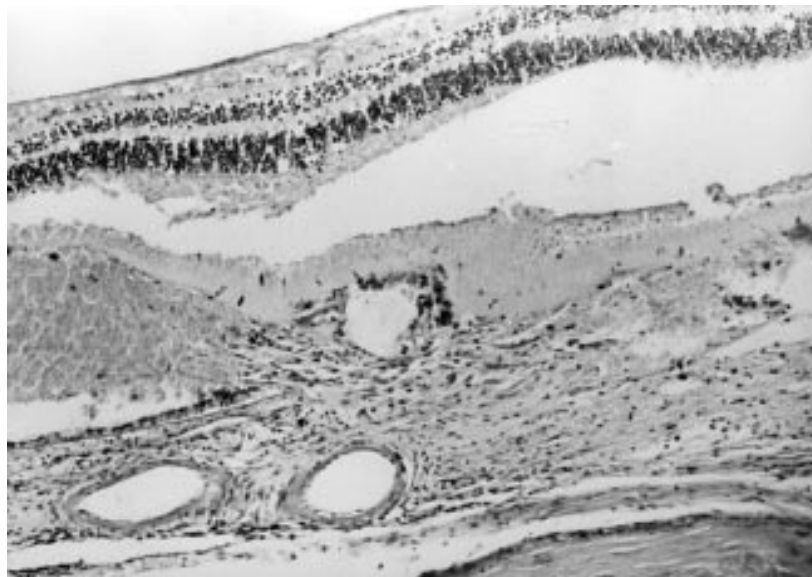

Figure 1 The choroidal neovascular membrane breaks through the Bruch's membrane and retinal pigment epithelium in the macular area. Haematoxylin and eosin, original magnification $\times 6.3$.

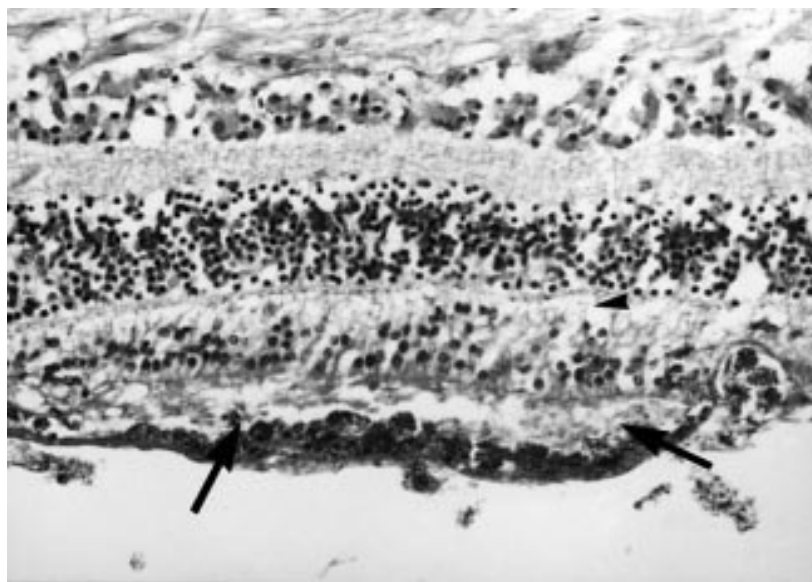


Figure 2 Cross section in the translocated macular area, showing massive fibroblastic pigment epithelium (arrows) attachment to the neuroretina which shows stunted photoreceptors (arrowhead). Haematoxylin and eosin, original magnification $\times 16$.

sections of the translocated macula and in the region of the former subretinal membrane, and our findings are discussed below.

COMMENT

As we expected we found a thickened Bruch's membrane, few points of calcification, some remnants from the surgically removed subretinal membrane underneath and above the pigment epithelium (Fig 1),¹⁰ and choriocapillaris atrophy. The outer retina seems not to be affected at the time of surgery.

From our point of view it was of interest to examine the attachment of the pigment epithelium to the retina or Bruch's membrane along the temporary postoperative retinal fold. We found that the pigment epithelium was attached mainly to the retina (Fig 2) and not to the Bruch's membrane; we were able to follow this from the optic disc through the macular region, up to the temporal periphery. Even at the site of one of our retinotomies,

which happened to be on the line of the retinal fold, we found basically the same picture.

This can be caused by the presence of subretinal proliferation before surgery, or more probably occurred during surgery; this is supported by the wide extent of this finding.

We know that in some cases after surgery there is no improvement in visual acuity, and we hypothesise that this is because a significant part of the pigment epithelium has been translocated along with the retina.

From our histological sections, we see that some part of membrane remains in place even after surgical "removal" and from the membrane remaining we were able to see that this is a mixed membrane with extension underneath and above the pigment epithelium.

We tentatively believe that this may be connected with the fact that the pigment epithelium remained attached to the retina in such a drastic manipulation; in a type 1 subretinal membrane situated only above the pigment

epithelium this will not occur. We think that more research is needed to discover if there is any connection between the type of membrane, related to the condition of the pigment epithelium, and the apparent stronger adhesion between the pigment epithelium and retina (or relatively weaker adhesion to the Bruch's membrane).

A BEREZKI

J TOTH

I SUVEGES

1st Department of Ophthalmology, Tomo u25-29,
H-1083 Budapest, Hungary

Correspondence to: Dr Bereczki

Accepted for publication 13 January 2000

- 1 Macherer R. Macular translocation. (Editorial.) *Am J Ophthalmol* 1998;125:698-700.
- 2 Macular Photocoagulation Study Group. Argon laser photocoagulation for neovascular maculopathy: five-year results from randomised clinical trials. *Arch Ophthalmol* 1991;109:1109-14.
- 3 Macular Photocoagulation Study Group. Laser photocoagulation of subfoveal neovascular lesions in age-related macular degeneration: results of a randomised clinical trial. *Arch Ophthalmol* 1991;109:1220-31.
- 4 Macular Photocoagulation Study Group. Subfoveal neovascular lesions in age-related macular degeneration: guidelines for evaluation and treatment in the macular photocoagulation study. *Arch Ophthalmol* 1991;109:1242-57.
- 5 Macular Photocoagulation Study Group. Laser photocoagulation of subfoveal neovascular lesions of age-related macular degeneration: updated findings from clinical trials. *Arch Ophthalmol* 1993;111:1200-9.
- 6 Ulbig MW, McHugh DA, Hamilton AMP. Photocoagulation of choroidal neovascular membranes with a diode laser. *Br J Ophthalmol* 1993;77:218-21.
- 7 TAP Study Group. Photodynamic therapy of subfoveal choroidal neovascularization in age-related macular degeneration with verteporfin. *Arch Ophthalmol* 1999;117:1329-45.
- 8 Macherer R, Steinhorst UH. Retinal separation, retinotomy, and macular relocation, I: experimental studies in the rabbit eye. *Graefes Arch Clin Exp Ophthalmol* 1993;31:629-34.
- 9 Macherer R, Steinhorst UH. Retinal separation, retinotomy, and macular relocation, II: a surgical approach for age related macular degeneration? *Graefes Arch Clin Exp Ophthalmol* 1993;31:635-41.
- 10 Grossniklaus H E, Gass J M D. Clinicopathologic correlations of surgically excised type 1 and type 2 submacular choroidal neovascular membranes. *Am J Ophthalmol* 1998;126:59-69.

Optic neuropathy as the presenting feature of HIV infection: recovery of vision with highly active antiretroviral therapy

EDITOR,—We describe a rare case of bilateral optic neuropathy caused by HIV which responded to highly active antiretroviral therapy (HAART).

CASE REPORT

In March 1996, a 52 year old man presented with a 6 month history of slowly deteriorating vision in both eyes. By the time he sought medical help he had difficulty reading the newspaper and watching television. He was otherwise well except for a chronic productive cough.

He had worked for many years as a teacher in Botswana. He was heterosexual. His only risk factor for HIV transmission was a single encounter with an African woman in the mid 1980s. In 1988 he had dengue fever and malaria. The latter was treated in the UK with quinine and fansidar. In 1995 he was treated in Botswana for a pneumonic illness. He was known to be hypertensive and was taking




Figure 1 (A) The patient's Humphrey fields central 24-2 threshold test at presentation. (B) The mean deviations show a marked improvement from -21.76 dB and -22.60 dB to -8.98 dB and -12.48 dB in the left and right eyes respectively.

nifedipine, bendrofluazide, and atenolol. There was nothing else of relevance in his history.

On examination he was clubbed and had bilateral coarse crepitations. General examination was otherwise normal. Higher mental function was normal. Visual acuities were 6/18 on the right and 6/9 on the left. He had marked colour desaturation being able to read 2/17 Ishihara plates with the right eye and 3/17 with the left. Both visual fields showed a marked concentric constriction (Fig 1A). Funduscopy revealed bilateral optic disc pallor (Fig 2). Intraocular pressures were normal. Eye movements were normal. His visual evoked response was virtually extinguished on the right and was delayed and of small amplitude on the left. No pattern evoked responses were seen on the ERG. The

remainder of the neurological examination was normal.

Full blood count, electrolytes, glucose, B₁₂, folate and folate levels were all normal. Autoantibody screen and syphilis serology were negative. *Haemophilus influenzae* was grown from his sputum but neither acid fast bacilli nor *Pneumocystis carinii* were detected. Toxoplasma serology showed no significant titres. Other viral serology including cytomegalovirus (CMV) antibody, hepatitis B surface antigen, and hepatitis C antibody were negative.

A chest radiograph showed bilateral basal shadowing. A high resolution computed tomograph scan confirmed bronchiectasis. A magnetic resonance imaging scan of head and orbits was normal. His CSF contained 28 white cells all of which were lymphocytes. The

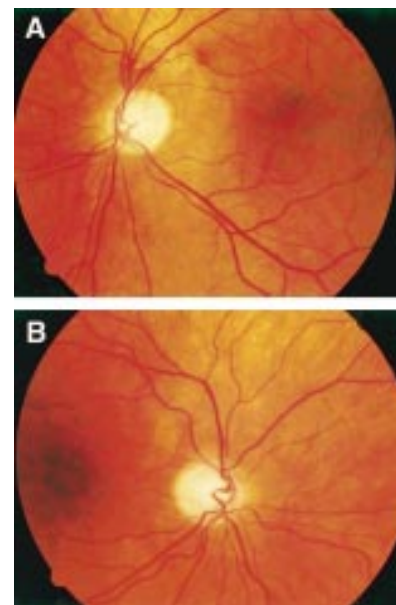


Figure 2 (A) Right and (B) left colour fundus photographs showing bilateral optic disc pallor.

CSF protein was 0.73 g/l (normal <0.4 g/l) and glucose of 2.5 mmol/l (plasma 5.5 mmol/l). No organisms were detected. CSF cryptococcal antigen test (latex agglutination) was negative.

The lymphocyte subsets showed a T helper cell count (CD4) of 100 cells $\times 10^9/l$ (normal 700–1100) and T suppressor cell count of 2232 cells $\times 10^9/l$ (normal 500–900). In view of his history he was counselled and consented to HIV testing. HIV-1 antibody test was positive.

He was commenced on triple therapy zidovudine 200 mg three times daily, lamivudine 150 mg twice daily, indinavir 800 mg three times daily (HAART or highly active antiretroviral therapy) with co-trimoxazole prophylaxis for *Pneumocystis carinii*. He responded well clinically and on review at 6 months his vision had improved to 6/9 and 6/6 in his right and left eyes respectively with a concomitant improvement in his visual fields at 24 months (Fig 1B). His CD4 count rose to 170 cells $\times 10^9/l$ and HIV viral load (Roche Amplicor) was below 400 copies/ml 6 months after initiating HAART. Unfortunately, the HIV viral load at presentation was not available.

COMMENT

Visual deterioration in HIV is a common problem. Ocular manifestations of HIV include retinal microangiopathy, opportunistic retinal infections, Kaposi's sarcoma of the conjunctiva and eyelids, and herpes zoster ophthalmicus. Retinal disease occurs frequently, sometimes in association with optic nerve disease. Occasionally the optic nerve is selectively involved. The commonest aetiology is opportunistic infection. Most case reports have focused on the role of opportunistic infections such as syphilitic optic perineuritis, CMV papillitis, varicella zoster optic neuritis, or cryptococcal retrobulbar neuritis.¹ Other causes include toxoplasmosis and tuberculosis. Indeed, a search for these aetiological agents is the priority when faced with an HIV positive patient with an optic neuropathy. However, sometimes no opportunistic infection is found and the HIV virus itself is assumed to be causing the optic neuropathy.

In our case funduscopy excluded CMV and toxoplasma retinopathy. The other infective aetiologies were excluded by serological testing. Magnetic resonance imaging excluded a compressive lesion. It is possible that our patient had idiopathic bilateral optic neuropathy with spontaneous improvement. However, it is exceedingly rare for simultaneous, rather than stepwise, bilateral visual deterioration to occur with progressive deterioration for months and then a slow delayed recovery. One of the best series of bilateral optic neuropathy remains that by Hierons and Lyle in 1959.² They reported 47 cases of bilateral optic neuritis, seven of which developed simultaneous bilateral visual disturbance. Two of these seven patients regained their vision over 6–12 months. Therefore, given the rarity of such an idiopathic presentation and the temporal relation of the improvement to HAART it is very likely that our patient had a primary HIV related optic neuropathy.

Primary HIV infection is well known to cause neurological disease. However, there has only been one case report of bilateral retrobulbar optic neuropathy in whom the presumed aetiology was the HIV virus itself.³ Newman and Lessell reported two patients who were already known to be HIV positive. The first patient was a 39 year old man who awoke with bilateral blurred vision and slight retrobulbar pain. His vision continued to deteriorate to 5/200 right eye and hand movement perception in the left eye. Funduscopy was normal. Four weeks into his illness he was commenced on AZT. Within 10 days his vision was beginning to improve. Eight months later his acuity was 20/70 right eye and 20/40 left eye. He was left

with bilateral optic atrophy. The second patient did not improve with AZT but did show improvement with prednisolone. The only other case of optic neuropathy due to primary HIV infection was of a man with sudden monocular blindness.⁴ This was clinically due to an anterior ischaemic optic neuropathy, presumed to be secondary to an optic nerve microangiopathy.

What is the mechanism of the optic neuropathy? There is a significant loss of cortical neurons and optic nerve axons in patients with AIDS.^{5,6} Also far fewer AIDS patients have ocular signs than have ocular lesions discovered on post mortem. Therefore, it is not surprising that changes were noted in the optic nerves of eight AIDS patients who did not have visual signs or symptoms before death as well as those who did. Patchy axonal degeneration, oligodendrocyte, and myelin degeneration were noted in association with mononuclear cell infiltration, suggesting that optic nerve degeneration may be mediated by HIV infected macrophages.⁷ The HIV virus infects mononuclear phagocytic cells rather than neurons or oligodendrocytes so the neuronal losses must occur through a secondary mechanism. A more recent study has shown that optic nerve astrocytes in four patients with primary HIV related optic neuropathy stain strongly for tumour necrosis factor α (TNF α). No comparable staining was seen in control optic nerves.⁸ TNF α , an immunomodulatory agent, thus appears to be a major player in HIV induced neuronal apoptosis.

In conclusion, HIV may directly cause an optic neuropathy. The improvement of our patient's vision with HAART is suggestive that

much of the optic nerve failure is due to a reversible dysfunction of the optic neurons rather than their death.

P GOLDSMITH
R E JONES

*Department of Neurology, Sunderland Royal Hospital,
Sunderland*

G E OZUZU
J RICHARDSON
Sunderland Eye Infirmary

E L C ONG
*Department of Infection and Tropical Medicine,
Newcastle General Hospital*

Correspondence to: Dr E L C Ong, Department of Infection and Tropical Medicine, Newcastle General Hospital, Newcastle upon Tyne NE4 6BE

e.l.c.ong@ncl.ac.uk

Accepted for publication 13 January 2000

- 1 Winward KE, Hamed LM, Glaser JS. The spectrum of optic nerve disease in human immunodeficiency virus infection. *Am J Ophthalmol* 1989;107:373–80.
- 2 Hierons R, Lyle TK. Bilateral retrobulbar optic neuritis. *Brain* 1959;82:56–67.
- 3 Newman NJ, Lessell S. Bilateral optic neuropathies with remission in two HIV positive men. *J Clin Neuro-ophthalmol* 1992;12:1–5.
- 4 Brack MJ, Cleland PG, Owen RI, et al. Anterior ischaemic optic neuropathy in the acquired immune deficiency syndrome. *BMJ* 1987;295:696.
- 5 Tenhule WN, Xu XZ, Heller K, et al. Optic nerve axonal nerve losses in AIDS: morphometric comparisons. *Am J Ophthalmol* 1992;113:14–20.
- 6 Wiley CA, Masliah E, Morey M, et al. Neurocortical damage during HIV infection. *Ann Neurol* 1991;29:651–7.
- 7 Sadun AA, Popose JS, Madigan MC, et al. AIDS related optic neuropathy: a histological, virological and ultrastructural study. *Graefes Arch Clin Exp Ophthalmol* 1995;233:387–98.
- 8 Lin X-H, Kashima Y, Kahn M, et al. An immunohistochemical study of TNF α in optic nerves from AIDS patients. *Curr Eye Res* 1997;12:1064–8.



Optic neuropathy as the presenting feature of HIV infection: recovery of vision with highly active antiretroviral therapy

P GOLDSMITH, R E JONES, G E OZUZU, et al.

Br J Ophthalmol 2000 84: 546
doi: 10.1136/bjo.84.5.546g

Updated information and services can be found at:
<http://bjo.bmj.com/content/84/5/546.8.full.html>

These include:

References

This article cites 6 articles, 1 of which can be accessed free at:
<http://bjo.bmj.com/content/84/5/546.8.full.html#ref-list-1>

Email alerting service

Receive free email alerts when new articles cite this article. Sign up in the box at the top right corner of the online article.

Notes

To request permissions go to:
<http://group.bmj.com/group/rights-licensing/permissions>

To order reprints go to:
<http://journals.bmj.com/cgi/reprintform>

To subscribe to BMJ go to:
<http://group.bmj.com/subscribe/>